



Journal Homepage: [-www.journalijar.com](http://www.journalijar.com)

## INTERNATIONAL JOURNAL OF ADVANCED RESEARCH (IJAR)

Article DOI:10.21474/IJAR01/23559  
DOI URL: <http://dx.doi.org/10.21474/IJAR01/23559>



### RESEARCH ARTICLE

## DIGITAINER – PRECISION IN PRACTICE

T P Athira<sup>1</sup>, Anoop Harris<sup>2</sup>, Anjana G<sup>3</sup>, Amrutha Joy<sup>2</sup>, Snisha M.G<sup>1</sup> and Gaana V.T<sup>1</sup>

1. Postgraduate Student, Royal Dental College, Chalissery.
2. Professor, Royal Dental College, Chalissery.
3. Head of Department and Professor, Royal Dental College, Chalissery.

### Manuscript Info

#### Manuscript History

Received: 16 March 2026  
Final Accepted: 18 April 2026  
Published: May 2026

#### Key words:-

Digitainer, Digital space maintainer,  
Space maintainer, Pediatric dentistry.

### Abstract

**Background:** Maintaining arch integrity following the premature loss of primary teeth is a cornerstone of pediatric dentistry. While traditional fixed space maintainers (e.g., band and loop, lingual arch) are clinically proven, they often present challenges regarding patient compliance, chairside time, periodontal health, and aesthetic acceptance.

**Case Description:** This study reports on two pediatric cases—an 8-year-old male requiring a lingual arch and a 5-year-old male requiring a band and loop appliance. Transitioning from conventional metal-based fabrication, both appliances were produced using a CAD-CAM (Computer-Aided Design and Computer-Aided Manufacturing) workflow. Following extraction and initial healing, digital data was acquired via scanning of dental casts. The appliances were virtually designed for optimal fit and thickness using CAD software and subsequently milled from Polymethyl Methacrylate (PMMA) blocks. The final "digitainers" were luted using self-adhesive resin cement.

**Results:** Clinical reviews at the second week, first month, and third month demonstrated successful space preservation with high durability. The CAD-CAM approach significantly enhanced patient and parent satisfaction due to the appliances' superior aesthetics and comfortable fit compared to stainless steel alternatives. Furthermore, the use of PMMA offered a cost-effective solution with reduced chairside adjustment time.

**Conclusion:** The integration of digital dentistry into space management offers a precise, hygienic, and patient-friendly alternative to traditional methods. By utilizing CAD-CAM technology, practitioners can deliver highly customized pediatric appliances that improve the clinical experience and maintain dental development with greater accuracy.

"© 2026 by the Author(s). Published by IJAR under CC BY 4.0. Unrestricted use allowed with credit to the author."

### Introduction:-

Effective space management during transitional phase is critical for maintaining proper occlusion and preventing long-term complications. Primary teeth play a critical role in the growth and development of a child. In addition to

their role in esthetics, mastication, speech, encouraging normal growth and function, it maintains the arch integrity and provides a guiding path for the succedaneous tooth to erupt in normal occlusion<sup>(1)</sup>. Space management is a fundamental aspect of pediatric dentistry, as the early loss of primary teeth can lead to adjacent teeth migrating into the extraction space, reducing the arch perimeter and compromising the eruption of permanent teeth<sup>(2)</sup> and supraeruption of opposing teeth.

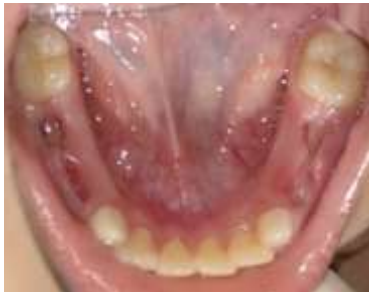Although conventional space maintainers have proven effective, their unesthetic appearance, difficulty in fabrication and poor retention have often led to patient non-compliance. As the dentistry is slowly evolving into digital phase conventional appliance fabrication being replaced by digital fabrication which gives more accurate and precise results. Digital fabrication techniques have gained popularity recently and have efficiently substituted for conventional ones. These techniques allow for the fabrication of restorations with virtual models and dies using the CAD software, along with digital manufacturing (CAM). Space maintainers that use CAD-CAM or 3D print technology with modern and biocompatible materials are called "Digital Space Maintainers".

In this article we are discussing of digital space maintainers, space maintainers fabricated using CAD-CAM or 3D printing technology.

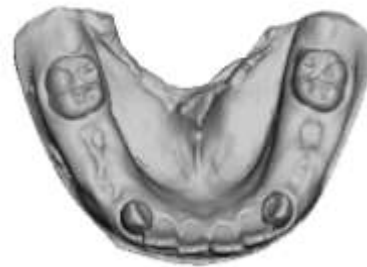**Case Report:-**

**Patient 1:-**

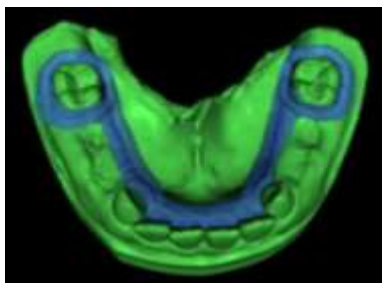
A 8 year old male patient came to the Department of Pediatric and Preventive Dentistry with a chief complaint of grossly decayed tooth in lower right and left back tooth region. There was no relevant medical and dental history. On examination, multiple grossly decayed non restorable tooth was noticed. After clinical and radiographic examination it was decided to extract primary first and second molars of both the sides and stabilize the arch by giving a lingual arch.



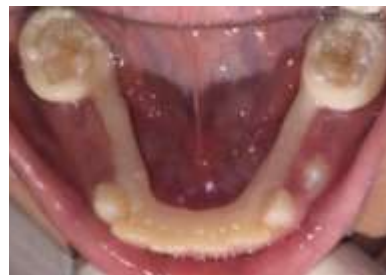Pre-operative intraoral photograph



Intraoral scanning photograph



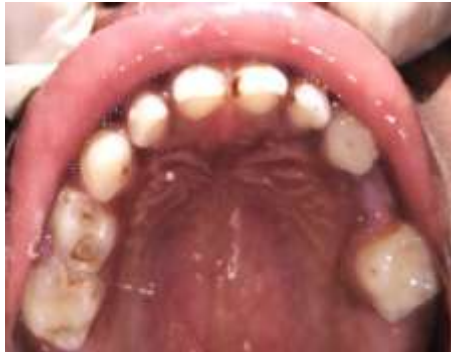Digital design in CAD



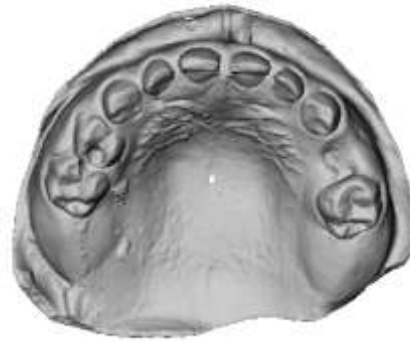Appliance delivery

**Patient - 2**

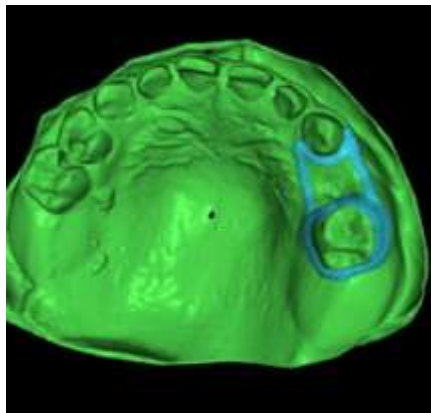
A 5 year old male patient, came to the Department of Pediatric and Preventive dentistry with a chief complaint of grossly decayed tooth in upper right back tooth region since 3 months. Patient has no relevant medical history. After examination, extraction was planned in left upper primary first molar as the tooth was non restorable and to give a band and loop space maintainer.



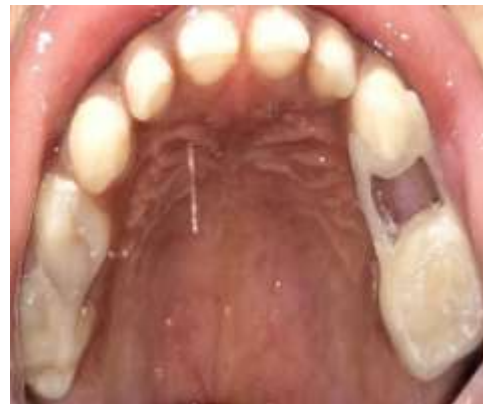Digital design in CAD



Intraoral scanning photograph



Digital design in CAD



Appliance delivery

The fabrication of space maintainer was done using CAD-CAM technology for both cases which combines computer-aided design and computer-aided manufacturing to produce highly accurate space maintainers. In both cases, the impression of the arches was recorded using polyvinyl siloxane impression material and the cast was poured using Type IV Die stone which is then digitized using an intraoral scanner. The digital data is used to construct a virtual model through CAD software. This virtual model allows for extensive manipulation and analysis, enabling the precise design of the space maintainer. Using the CAD software, the appliance was designed with accurate specifications for material thickness, retention, and cementation space, ensuring a perfect fit and optimal function. The final design file is transferred to a CAM system, where an automated milling machine carves the space maintainer from a solid block of Polymethyl Methacrylate (PMMA) material, producing a highly accurate and durable appliance. The appliance was tried on the patient and minor modifications which were needed were rectified and luted on the abutment teeth using resin GIC. Review was done on 2<sup>nd</sup> week, 1<sup>st</sup> month and 3<sup>rd</sup> month of delivery.

### Discussion:-

The premature loss of a primary tooth can cause psychological, functional, aesthetic concerns, along with space loss, which may later lead to loss of arch length. This loss of arch length can lead to crowding, extrusion of opposing tooth eventually leading to malocclusion. A study by Shamahy et al. in 2021 found that the prevalence of malocclusion among school children was 81.1% following the premature extraction of a primary tooth<sup>(8)</sup>. The complications which can arise due to the inevitable loss of primary teeth can be minimized through proper planning and the use of space maintainers.

As stated by the American Academy of Pediatric Dentistry (AAPD), space maintenance is the preservation of present dentition placement to avoid loss of arch length, width, and perimeter. Depending on factors such as the child's age, dental arch development, and cooperation level the clinician can choose appropriate space maintainer.

After using the term “Space maintenance”, in 1941, JC Brauer went on to explain that space maintainer as the process of preserving a space in the mouth that had previously been filled with one or more teeth<sup>(11)</sup>. Space maintainers are generally categorized into removable and fixed types. Removable maintainers offer the advantage of being functional and easy to clean, simplifying hygiene maintenance. As patient cooperation plays a major role in space maintainers which can be challenging with younger children, fixed space maintainers are often preferred<sup>(12)</sup>. Commonly used fixed unilateral space maintainers include the band–loop (BL) and its modifications, crown and loop (CL), lingual arch (LA), Nance arch (NA), and transpalatal bar (TB)<sup>(13)</sup>. The conventional space maintainers usually consists of metallic band banded to the abutment tooth and a loop/wire design soldered to the band.

In this study, we have designed the appliance fabrication in CAD-CAM technology. CAD/CAM milling/machining technology is a digital technique in which different complex shapes, crowns, frameworks, or working models are fabricated by grinding resin blocks to achieve the desired geometry, designed by the CAD software<sup>(14)(15)</sup>. The first system introduced was developed by Duret and colleagues in 1971, but was not widely used, mostly because of the lack of accuracy of digitizing, computer power, materials, etc<sup>(16)</sup>. The CAD/CAM process can be divided into three different steps: data acquisition, indirect restoration design and construction of the prosthesis itself<sup>(17)</sup>. Each step requires special care to optimize the results. In addition, it is important to emphasize that the steps work independently, although the images captured will determine the construction of the digital model, making it possible to design the appliance to be built<sup>(18)</sup>. In recent years, CAD/CAM technology has expanded the options for dental prosthetic materials, offering access to new, highly reliable ceramic materials. The stability of zirconium oxide ceramics makes it a viable alternative to metal frameworks for permanent prostheses in many clinical applications<sup>(19)</sup>.

The present clinical report describes the use of CAD/ CAM metal-free milled PMMA. A study conducted by Rodrigues et al in 2022 introduced a fully digital workflow for manufacturing fixed esthetic space maintainers in growing patients and he reported satisfactory patient cooperation with minimal chairside adjustment and lower cost. Improved time efficacy and possibility of immediate replacement in case of fracture or failure was additional benefit of this space maintainer<sup>(20)</sup>. The results of this study align with the findings of Guo et al. (2020), who conducted a comparative analysis of the fit accuracy of space maintainers manufactured using two different methods: milling PMMA and conventional techniques<sup>(21)</sup> and concluded that digitally designed and integrated Removable Space maintainers were found to be superior to those produced using the conventional method<sup>(22)</sup>. In this case report, we have found better patient acceptance and lesser chair side time, patient and parent acceptance was higher comparing to the conventional stainless steel space maintainer. The cost of the PMMA was similar to stainless steel space maintainer which makes it more affordable comparing to the other materials which is used for fabrication of digitainer like PEEK, Bruxzir etc. Long term follow ups are necessary to conform these results and other possible benefits over a longer period of time.

### **Conclusion:-**

The present study proposes a fully digital framework for creating pediatric unilateral space maintainers. The feasibility of integrating intraoral scanning, generative design, finite element analysis, and additive manufacturing to provide customized and personalized solutions was verified. The proposed methodology demonstrated to be a promising approach to improve patient-specific treatments with the aim of enhancing adaptability, hygiene, and patient comfort<sup>(23)</sup>.

### **Reference:-**

1. Peter Schopf. Indication for and Frequency of Early Orthodontic Therapy or Interceptive Measures. Journal of Orofacial Orthopedics. March 2003, Volume 64, Issue 3, pp 186-200.
2. Ramadhani R, Hidayat S, Primarti RS. Compliance evaluation of removable space maintainer or space regainer usage. Padjadjaran J Dent. 2012;24:53-8.
3. Weihua G, Jun W, Xu C, Xiaojing W, Wei Z, Guangtai S, Li'an W, Beizhan J, Qiong Z, Yu L, Ning Z. Experts' consensus on space management of mixed dentition. West China Journal of Stomatology. 2022 Jun 1;40(3).
4. Kundu R, Tripathi AM, Jaiswal JN, Ghoshal U, Palit M, Khanduja S. Effect of fixed space maintainers and removable appliances on oral microflora in children: An: in vivo: study. Journal of Indian Society of Pedodontics and Preventive Dentistry. 2016 Jan 1;34(1):3-9.
5. Feasby WH, Ecclestone ER, Grainger RM. Nickel sensitivity in pediatric dental patients. Pediatric dentistry. 1988 Jun 1;10(2):127-9.

6. Setia V, Pandit IK, Srivastava N, Gugnani N, Sek hon HK. Space maintainers in dentistry: Past to present. *J Clin Diagn Res* 2013;7:2402-5.
7. Ahmad, A.J., Parekh, S. and Ashley, P.F., 2018. Methods of space maintenance for premature loss of a primary molar: A review. *Eur. Arch. Paediatr. Dent.*, 9(5), pp.311–320.
8. Al-Shamahy HA, Al-Dossary OAE, Al-Haddad K, et al. Malocclusion and premature teeth loss: its prevalence and association among Yemeni school children in Sana'a. *J Oral Med Dent Res* 2021;2:14. DOI: 10.52793/JOMDR.2020.2(2)-18
9. Choonara, S.A. Orthodontic space maintenance—A review of current concepts and methods. *SADJ J. South Afr. Dent. Assoc.* **2005**, 60, 115–117.
10. Casaña-Ruiz, M.; Aura-Tormos, J.I.; Marques-Martinez, L.; Garcia-Miralles, E.; Perez-Bermejo, M. Effectiveness of Space Maintainers in Pediatric Patients: A Systematic Review and Meta-Analysis. *Dent. J.* **2025**, 13, 32. <https://doi.org/10.3390/dj13010032>
11. Dhanotra KG, Bhatia R. Digitainers-digital space maintainers: A review. *Int J Clin Pediatr Dent* 2021; 14 Suppl 1:S69-75.
12. Kang ES. Space maintainer using CAD/CAM system without a band: a case report. *Journal of Dental Rehabilitation and Applied Science.* 2024 May 31;40(2):100-6.
13. Watt, E.; Ahmad, A.; Adamji, R.; Katsimbali, A.; Ashley, P.; Noar, J. Space maintainers in the primary and mixed dentition—A clinical guide. *Br. Dent J.* **2018**, 225, 293–298
14. Alghazzawi, T.F. Advancements in CAD/CAM technology: Options for practical implementation. *J. Prosthodont. Res.* 2016, 60, 72–84.
15. Presotto, A.G.C.; Barão, V.A.R.; Bhering, C.L.B.; Mesquita, M.F. Dimensional precision of implant-supported frameworks fabricated by 3D printing. *J. Prosthet. Dent.* 2019, 122, 38–45.
16. Miyazaki T, Hotta Y. CAD/CAM systems available for the fabrication of crown and bridge restorations. *Aust Dent J* [Review]. 2011 June;56 Suppl 1:97-106. <https://doi.org/10.1111/j.1834-7819.2010.01300.x>
17. Miyazaki T, Hotta Y, Kunii J, Kuriyama S, Tamaki Y. A review of dental CAD/ CAM: current status and future perspectives from 20 years of experience. *Dent Mater J* [Review]. 2009 Jan;28(1):44-56. <https://doi.org/10.4012/dmj.28.44>
18. Van Noort R. The future of dental devices is digital. *Dent Mater* [Review]. 2012 Jan;28(1):3-12. <https://doi.org/10.1016/j.dental.2011.10.014>
19. Vult von Steyern P, Carlson P, Nilner K. All-ceramic fixed partial dentures designed according to the DC-Zirkon technique. A 2-year clinical study. *J Oral Rehabil* 2005; 32: 180-187.
20. Rodrigues, L.P.; Dourado, P.H.N.; de Araújo, C.A.R.; No-Cortes, J.; Pinhata-Baptista, O.H. Digital workflow to produce esthetic space maintainers for growing patients. *J. Prosthet. Dent.* 2022, 2022, S0022-3913
21. Guo, H.; Zhao, Y.; Feng, S.; Liu, H. Laser Medical Image Reconstruction and Computer Aided Design of Polymethyl Methacrylate for Pediatric Removable Space Maintainer Applications. *J. Med. Imaging Health Inform.* 2020, 10, 2842–2848.
22. Zarean P, Zarean P, Sendi P, Neuhaus KW. Advances in the manufacturing process of space maintainers in pediatric dentistry: A systematic review from traditional methods to 3D-printing. *Applied Sciences.* 2023 Jun 9;13(12):6998.
23. Tamburrino F, Chiocca A, Aruanno B, Paoli A, Lardani L, Carli E, Derchi G, Giuca MR, Razionale AV, Barone S. A novel digitized method for the design and additive manufacturing of orthodontic space maintainers. *Applied Sciences.* 2023 Jul 18;13(14):8320.