Journal Homepage: -www.journalijar.com

INTERNATIONAL JOURNAL OF ADVANCED RESEARCH (IJAR)

Article DOI:10.21474/IJAR01/24567
DOI URL: http://dx.doi.org/10.21474/IJAR01/24567

ISSN (O): 2320-5407
ISSN (P): 3107-4928

RESEARCH ARTICLE

STUDY OF THE EFFECTS OF THE EPICARP OF THE FRUIT OF KIGELIA AFRICANA ON THE FERTILITY OF MALE MICE (MUS MUSCULUS)

Blaise Wokapeu Kpan[1], Maïmouna Coura Koné[2], Yao Konan[4], Kone Mamidou Witabouna[3] and Koffi Kouakou[1]

1. Laboratory of Natural Environments and Biodiversity Conservation, Botanical Research and Training Unit, Felix HOUPHOUËT-BOIGNY University, Abidjan, Côte d'Ivoire.
2. Laboratory Biology and Health, Biology of Development and Reproduction Unit, Biosciences UFR, Felix HOUPHOUËT-BOIGNY University, Abidjan, Côte d'Ivoire.
3. Laboratory of Botany and Valorization of Plant Diversity, Natural Sciences Training and Research Unit, Nangui ABROGOUA University, Abidjan, Côte d'Ivoire.
4. National Floristic Center (CNF), Abidjan, Côte d'Ivoire

Manuscript Info

Manuscript History
Received: 12 September 2026
Final Accepted: 24 October 2026
Published: 30 November 2026

Key words:-
Kigeliaafricana, peel, spermatogenesis, motility, testis.

Abstract

Background: This work consisted of studying the effects of the epicarp of the fruit of Kigeliaafricana on the fertility of male mice (Mus musculus).

Methods: We first described the phytochemical composition of the bark of the fruit of Kigeliaafricana alone. Then, we analyzed the variation of total weight, testicular weight, sperm parameters and testicular organization after administration of the extract.

Results: It appears from the results obtained that the aqueous extract of the bark of Kigeliaafricana regulates muscle mass gain and improves sperm motility and morphology. Regarding the quantity of sperm and testicular sections, the bark extract does not block spermatogenesis, but seems to affect its progression as well as its quality. It nevertheless maintains the integrity of the testicular tissue. The effects of Kigelia bark on sperm parameters would be linked to the different secondary metabolites detected.

Conclusion: The results presented in this work show that in males, the aqueous extract of Kigeliaafricana bark regulates muscle mass gain and improves sperm motility and morphology. Regarding sperm quantity and testicular sections, the bark extract does not block spermatogenesis, but seems to affect its progression as well as its quality. However, it maintains the integrity of testicular tissue. The effects of Kigelia bark on sperm parameters are related to the various secondary metabolites detected.

"© 2026 by the Author(s). Published by IJAR under CC BY 4.0. Unrestricted use allowed with credit to the author."

Corresponding Author: Maïmouna Coura Koné
Address:Laboratory Biology and Health, Biology of Development and Reproduction Unit, Biosciences UFR, Felix HOUPHOUËT-BOIGNY University, Abidjan, Côte d'Ivoire

Introduction:-

Plants have great medicinal value because of bioactive molecules that they contain. Thus, studies on the chemical compounds and pharmacological properties of plants for developing new efficient traditional medication are of major interest. In developing countries, where some drugs and care have hight cost and are inaccessibility, using plants for primary health care is very common (1).Kigeliaafricana(Lam.) Benth commonly called Cucumber or Sausage tree is distributed in West and South Africa (2).Kigeliaafricana (Lam.) Benth from Bignognacae family, is widely find in tropical regions and grown as an ornamental plant for itsdecorative flowers and unusual fruit hence the name 'sausagetree' (2). The tree is also widely exploited for their several medicinal advantages (3). Indeed, previous studies showed some anti-inflammatory effects (4,5), anticancer activity (6, 7, 4) and hepatoprotective effect (8, 9).K.africanahave also a molluscicidal(10), and antimicrobial (Akunyili etal., 1991) activities. In the particular case of reproduction, fruits and flowers are mixed with alcohol or water andused by traditional healers for fertility treatment among women and men of childbearing age (11).Whole fruit has been shown to have androgenic and antioxidant effect (12,13). Other study in have shown that the whole fruit of Kigeliaafricana stimulates spermatogenesis, improves sperm motility and morphology (14). The fruit also shows efficacy against the short- and long-term reproductive toxicity of cisplatin on the testis (12,13,15,16).

Whole fruit phytochemicals composition of K. africana and pharmacological activities associated have already been described. Indeed, fruit contain compounds such as flavonoids, polyphenols, alkaloids, saponosides, quinones, tannins (17, 18). It also contains enzymatic and non-enzymatic antioxidants (19,20).Despite available knowledges about phytochemical composition and pharmacological activity of whole fruit extracts, his mechanism of fertility improvement remains unclear. Indeed, specific identification of secondary metabolites involved in the increasing of sperm parameters as well as the specific parts of the fruit containing these metabolites and causing these effects are not well known. In this context, recent work carried out by our laboratory (21) has compared aqueous extract of fruit without the peel with whole fruit. The data shown that these two extracts have a different composition and the relative effects of the two extracts on sperm parameters. Whole fruit was more efficient in increasing sperm density, while extract of fruit without peel was more effective in improving sperm motility and morphology. However, data on fruit peel alone phytochemical composition and effects on reproduction are poorly described. Knowing the mechanisms and specific parts containing the metabolites involved in the improvement of male fertility by the whole fruit are of great therapeutic interest. This would allow a better valorization of whole fruit's differents parts and his better using in different forms of male infertility treatments. In this work, we aimed to study effects of Kigeliaafricana fruit peel on mice (Mus musculus) male fertility. We first described the phytochemical composition of Kigeliaafricana fruit peel alone. Then, we analyzed variation of weight, testicular weight, sperm parameters and testicular organisation after administration of the extract.

Methods:-

Plant Matérial: Matured fruit of Kigeliaafricana, collected in the forests around Ayama was obtained from the local market of this city. The fruit was authenticated at the Floristic National Center of Felix HOUPHOUET-BOIGNY University of Ivory Coast. The reference number is UCJ001955. After identification, the fruits were washed and the peel was carefully removed. Peel was then cuted into small pieces and dried under air conditioning at 18˚C during 2 weeks. Drying lasted 2 weeks followed by spraying. Peel powder were weighted and kept for further phyto-chemical analysis/ extraction.

Extraction of Plant Material: From the peel powder obtained, we carried out an aqueous extraction according to the protocols of (22). Indeed, one hundred grams (100 g) of fine powders were dissolved in one liter (1 L) of distilled water by grinding in a Blinder Mixer for 10 to 15 minutes. The homogenate obtained was drained in a square of cloth, then filtered successively twice through cotton wool and once through Whatman 3 mm paper. The filtrate obtained was dried by evaporation in a Venticell type oven at 50˚C. The evaporate recovered as a powder constituted the total aqueous extract of peel (AqP).

Phytochemical Screening:

Identification of Alkaloids: The detection of alkaloids consists of precipitating them using precipitation reagents. To 2 ml of plant extract, 5 drops of each reagent are added. Depending on the nature of the reagent, various colors are obtained in the presence of alkaloids. Three reagents were used to characterize the alkaloids.

These are:
- Dragendorff's reagent (orange-yellow precipitate);
- Valsner Mayer reagent (white or white-yellow precipitate);
- Bouchardat's reagent (brown-black, brown-dull or yellow-brown precipitate).

Demonstration of Flavonoids: The flavonoids were first identified by a general reaction to soda. In a tube containing 2 ml of plant extract solution, a few drops of a 1/10 soda solution were added. The yellow-orange color made it possible to characterize the presence of flavonoids.

Demonstration of Sterols and Polyterpenes: In a tube containing 2 ml of plant extract solution, a drop of concentrated sulfuric acid and a triperpene solution in choroform were added. The appearance of a color that is first yellow, then dark red indicates the presence of sterols and polysterols.

Identification of Polyphenols:a drop of 2% alcoholic ferric chloride solution was added to 2 ml of was added. Ferric chloride causes in the presence of polyphenolic derivatives appearance of a more or less dark blackish-blue or green color.

Highlighting Tannins:1 ml of 10% aqueous lead acetate solution was added to 3 ml of the extract. The formation of a blue, black-blue, whitish, or brownish precipitate indicates the presence of tannins. To identify the classes of tannins, 1 ml of extract was added to 2 ml of distilled water and then 1 to 2 drops of 0.1% ferric chloride were added. The appearance of a blue, blue-black or black coloration indicates the presence of gallic tannins, the green or dark green (or greenish brown) coloration indicates the presence of catechetical tannins.

Identification of Quinones: To 1 ml of extract was added 1 ml of sulfuric acid concentrate (H2SO4). The appearance of a red coloration indicates the presence of quinones.

Demonstration of Saponins:5 ml of peel aqueous extract were added into a test tube. The tube was shaken vigorously for 15 seconds and then allowed to stand for 15 - 60 min. A height of persistent foam, greater than 1 cm, indicates the presence of saponins.

Animal Treatment: Ten 8 - 10 weeks old male wistar mice weighing 20 - 35 g were used for the experiments. The animals were obtained from the animal facility of NanguiAbrogoua University. They were kept in the Animal Room of the ENS under standard conditions of temperature (27˚C - 30˚C), with a 12-hour light: 12-hour dark cycle to acclimatize for 1 week prior to beginning of the experiments. Each male was housed individually in wire mesh cage. All animals were allowed unrestricted access to water and feeded with commercial granules and properly housed. All treatment was administered orally through a metal oropharyngeal cannula. Animals were divided into 2 groups (control group and AqP group) of five mice per group. Control group received 1 ml normal saline. AqP group animals received 100 mg/kg of AqP extract. The treatment was carried out for 35 days.

Body weight assessment: The animals were weighed once a week during the 35 days of treatment in order to determine weight variations. The weight gain of the animals in each batch during the treatment period were then established according to the formula:
Collection of Samples: At the thirty-seventh day, animals were scarified by decapitation after ether anesthesia. The testes and epididymis were removed through the opening of the scrotum.
Fresh and dry weight of the testicles: The removed testicles were immediately weighed. The relative weight of the testicles was calculated according to the formula: Relative weight of the organ = (weight of the organ x 100) / weight of the animal. The testicles were then placed in an oven at 100°C to dry for 24 hours. These organs were weighed a second time in order to record the weight after drying.
Semen Parameters Analysis: Spermatozoa were collected according to the method of(23). and (21). After sacrifice, the caudal parts of the epididymis of each mouse is removed by opening the scrotum, then dilacerated in 10 mL of NaCl concentrated at 9‰ previously incubated in a water bath at 36˚C. Sperm motility was assessed by direct examination of the sperm collecting solution under a light microscope (Olympus CX31RBSF, Philippine) at 100X magnification. A fine drop of solution containing the spermatozoa is placed between slide and coverslip (previously maintained at 36˚C). Motile and immobile sperm were quickly counted in 5 random fields and the percentage of motile forms was determined from the formula: % motile sperm = (number of motile sperm / total number of sperm) ×100.

The sperm density was determined using the Malassez cell. A drop of macerate from the epididymis was taken and placed on the Malassez cell then covered with a coverslip. The sperm count was performed under a light microscope (Olympus CX31RBSF, Philippine) (X 400). The number of spermatozoa per mm3 was estimated according to (24). Analysis of sperm morphology was performed using a sperm smear. Briefly, a drop of the previous solution is placed on a slide and spread using a coverslip. The smear is stained with eosin solution. The smear was examined for normal and abnormal sperm (abnormalities of the head and tail) under a light microscope at X400 magnification.

Histopathological Analysis: Testes were fixed in 10% formalin for 48 hours at room temperature. They were then dehydrated by successive passage through alcohol baths of increasing degree (80˚, 90˚ and 100˚) for varying times at room temperature. Thinning of the testes was done in three toluen baths for varying times. Impregnation was carried out in the oven (Memmert, Germany) between 58˚C and 60˚C in 2 successives paraffin baths. Testes were then embedded in paraffin at room temperaturein molds. 5 µm testicular sections were made with a microtome (Leica RM2125RTS; Germany). The sections are mounted on slides and then dewaxed at 58˚Cto 60˚C in an oven (Memmert, Germany) for 30 minutes to be dewaxed.

Statistical Analysis: Statistical analysis was performed using the R 4.02 software and Excel 2016 spreadsheet for the realization of weight evolution curves. For each parameter (Sperm density, motility and morphology; weight gain, testicular fresh and dry weight, seminal vesicle fresh weight, levator muscle fresh weight) Shapiro-Wilk test was using to verify distribution's normality. We used Bartlett test to verify variance homogeneity. After these verifications, we performed an Student test to compare the means of the control and AQ P groups. The level of significance chosen for these analyzes is 5% (P = 0.05). The averages were each presented with its associated standard deviation.

Results:-

Phytochemical components of AqP extract: Phytochemical screening of AqPKigeliaafricana extract (table 1) showed the presence of numerous secondary metabolites in variable abundance. AqP extract is particularly rich in flavonoids, quinones and saponosides. Sterols and polyterpenes, polyphenols, catechic tannins and anthocyanins were also detected. Gallic tannins, alkaloids and anthraquinones were not detected in AqP extract.

Table 1 : Phytochemical screening of Kigeliaafricana fruit peel. (-) negativ reaction, (+) positive reaction, (++)hightreactiv reaction.

Phytochemical compounds	Sterol and polyterpenes	Polyphenols	Flavonoids	Catechic tanins	Gallic tanins	Quinones	Alcaloids	Anthocyans	Anthraquinones	Saponosides
Peel extract	+	+	++	+	-	++	-	+	-	++

Body weight gain: In the control animals, the weight gain is~24% (± 4.18) which is greater than that of the animals treated with the AqP extract (~14.60% ± 4.06) (figure 1). The observed difference is highly significant (P < 0.001)

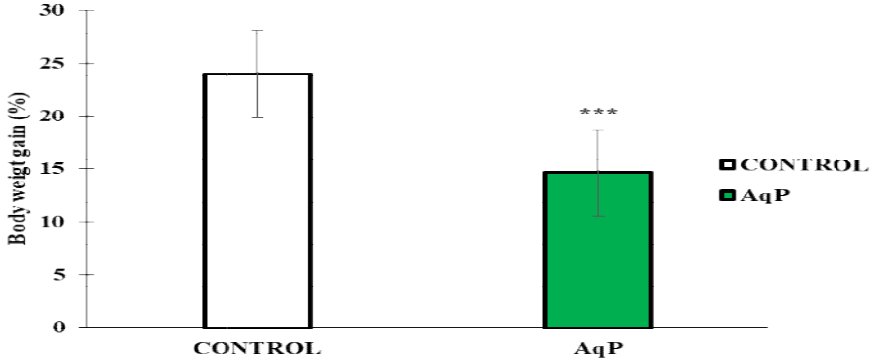

Figure 1 : Body weight gain (%) of control group (white) and AqP group (green) during 35 days. Difference is highly significative at P < 0.001.

Testicular weight: In AqP group, fresh testicular weight (~0.246 ± 0.021) was lower than in control group (~0.311 ± 0.016) with a highly significant difference (P < 0.001). In the case of dry testicular weight, AqP group also showed a lower value (~0,053 ± 0.002) than control group (~0,057 ± 0.001) with a very significant difference (P < 0.01). These data showed that AqP extract decrease testicular weight (figure 2).

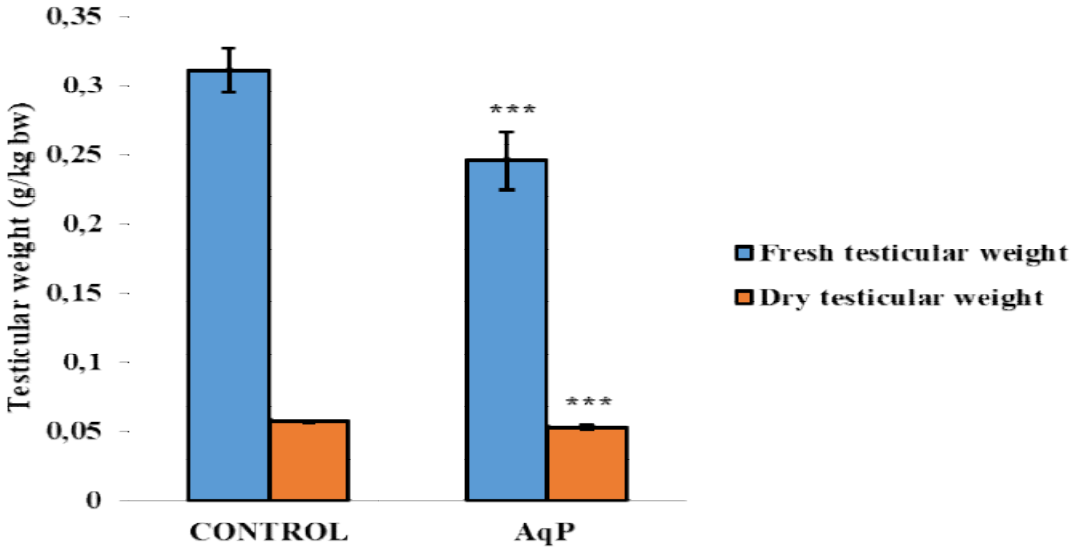

Figure 2 : Fresh (blue) and dried (orange) testicular weight in control group and AqP group. Highly significant difference at P < 0.001.

Analysis of sperm parameters

Peel (P) aqueous extract decreased sperm density: The density of sperm in AqP group (~ 54.25.106 spz / ml ± 7.736) was lower than in control group (~ 57.95.10^6spz / ml ± 7.169). But the difference was not significant (P = 0.468). These data suggested that AqP extract would decrease sperm density.

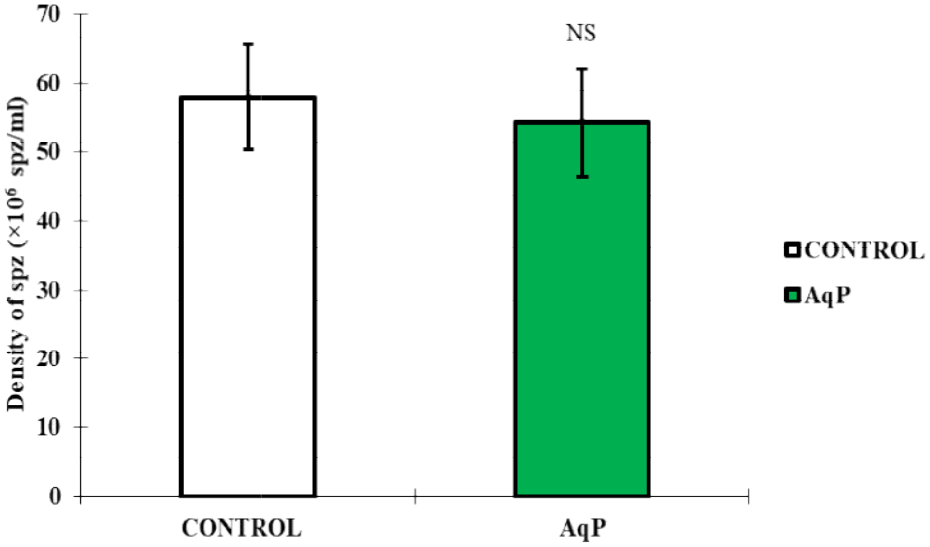

Figure 3 : Sperm density analysis in control group (white) and AqP group (green). (NS) Not significant difference at P = 0.468.

Peel aqueous extract increased sperm mobility: The percentage of mobile sperm is highter in AqP group (~56% ± 5.47) than control (29% ± 2.23) (Figure 4). The difference was highly significant at P < 0.001. These observations showed that AqP extract from of Kigeliafruit improved sperm mobility.

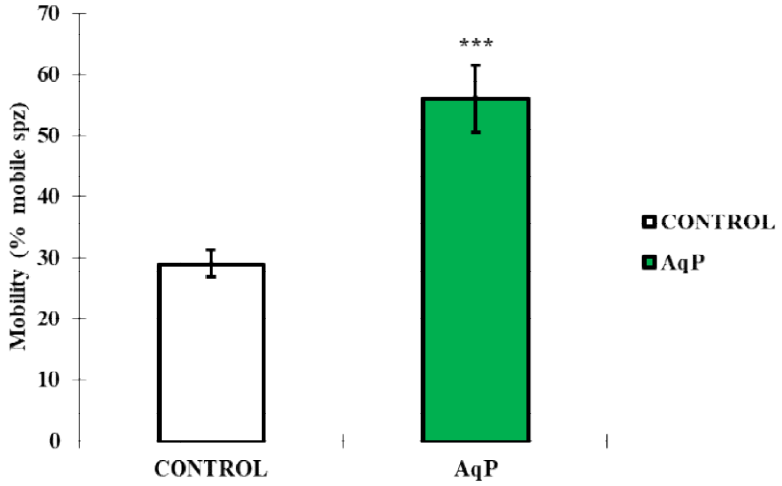

Figure 4 : Sperm mobility in control group (white) and AqP group (green). Highly significant difference at P < 0.001.

Peel aqueous extract improve sperm morphology: The percentage of normal spermatozoa observed in the case of P aqueous extract (~91.9% ± 1.342) was significantly higher than control animals (~85% ± 4.677) (P< 0.05) (figure 5). These results showed that AqP extract of Kigelia fruit improved sperm morphology.

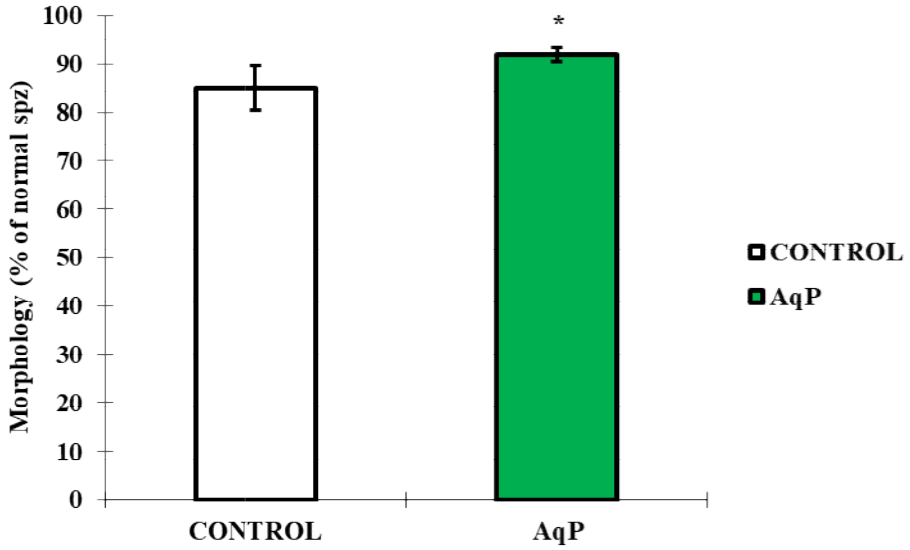

Figure 5 : Sperm morphology in control group (white) and AqP group (green). Difference is significant at P < 0.05.

Histological analysis of testis section of P extract group: The testis of control group and AqP group animals did not show any tissue alteration (figure 6 a and b). In control group (figure 6 a) and AqP group (figure 6 b) testis section's presented several seminiferous tubules of various sizes and shapes homogeneously separated. Leydig cells cluster was observed between tubes in control and AqP groups (6 a and 6 b; arrow head). Tubes with lumen (L) of variable diameters were frequently observed in the two groups. In these tubes, all cells of the germ line representing different stages of spermatogenesis (spermatogonia, spermatocytes I, round spermatids, and spermatozoon) have been identified (figure 6 a' and 6 b'). For control group, numerous immobiles matures sperm has been observed in

tube's lumens (figure 6 a'). Numerous elongated spermatids and young immatures spermatozoon were more frequently observed in the seminiferous epithelium of AqP group (figure 6 b'; arrows) unlike immobiles matures spermatozoon that seemed numerous in the lumen. Some tubes without lumen (*) were also presents. These observations showed that spermatogenesis was normally active and fully complete in most of the seminiferous tubules of control animals and AqP groups. Howether, the progression of spermatogenesis as well as its quality seemed affected in animals of the AqP group.

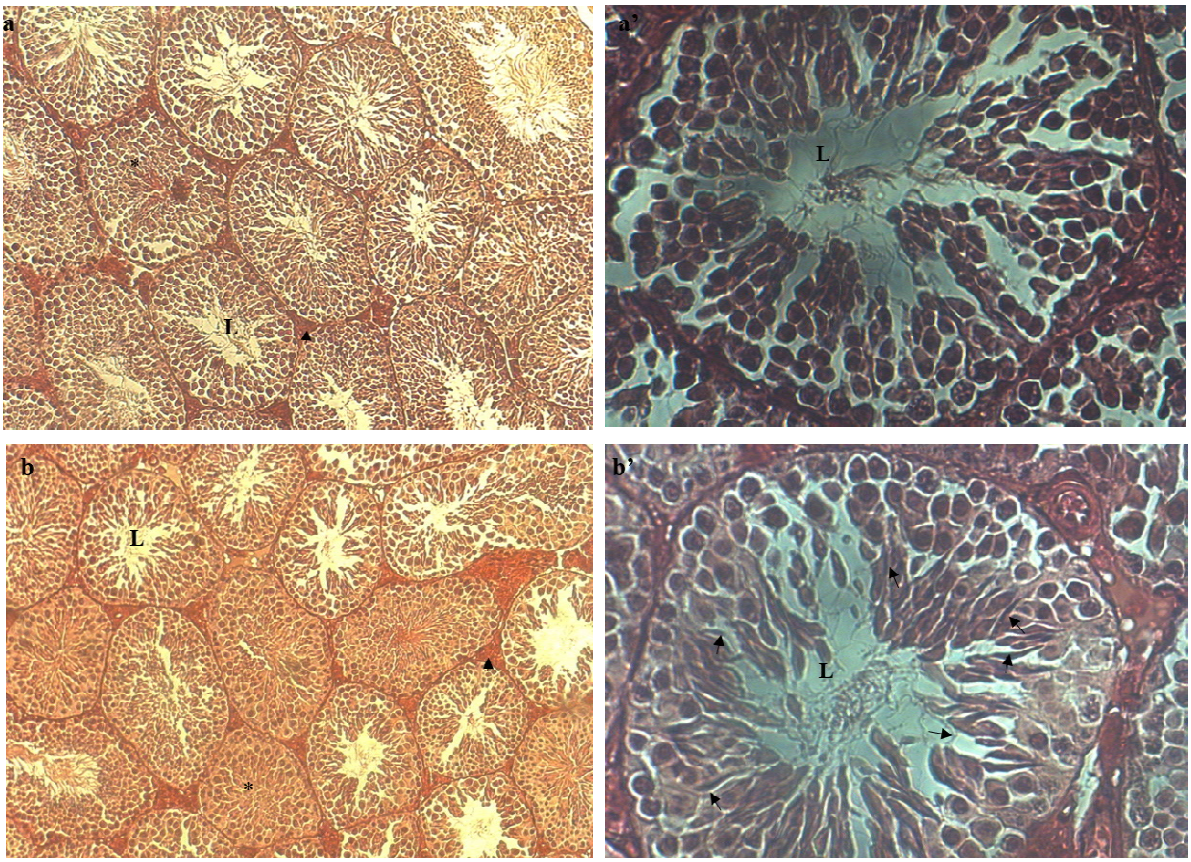

Figure 6 : Histological sections of testis of control group (a and a') and AqP group (b and b'). General observation of seminiferous tubes showing germinal cells in control group (a) AqP group (b) ×100. (L) for lumen of tubes; (*) for tubes without lumen; Arrows show elongated spermatids in seminiferous epithélium and young immatures sperm in lumen of a tube in AqP group (b') ×400. Arrow heads show Leydig cells cluster (arrow) in control group (a) and AqP group (b). Hemalun-eosin coloration

Discussion:-

The objective of this work was to study the effects of kigeliaafricana fruit peel's aqueous extract on sperm parameters and testicular tissue in mice. For this, we first determined the phytochemical composition of the aqueous extract of the fruit. Then, we analyzed the variations in body weight, fresh and dry testicular weight, sperm parameters and testicular tissue of males treated with a concentration of 100 mg/kg of body weight of Kigeliaafricana extract. The choice of this concentration is based on the work of(12, 13, 15, 16) and (21). Very few data describe the phytochemical composition and effects of Kigeliaafricana fruit peel on fertility in males. Thus, this study is to our knowledge, the first to highlight the improvement in the mobility and morphology of spermatozoa by the peel extract of the fruit of Kigeliaafricana.

The study of chemical composition of AqP extract showed the presence of many compounds in variable abundance. Sterol and polyterpenes, Polyphenols, Catechic tannins, and anthocyanin were present. AqP extract was particularly rich in Flavonoids, Quinones and Saponosides. The presence of these compounds would give the fruit peel many biological activities (for review see 19,18). At the qualitative level, we could compare the composition of AqPextract with that of the aqueous extract of the pulp for sterols and polyterpenes, polyphenols, flavonoids,

catechin tannins and quinones (21). A difference was also observed in their abundance. These differences could come from the fact that the screenings were carried out with different parts of the fruit. The presence or abundance of a compound in an extract depends on which plant organ it comes from. We can therefore assume that a difference could also be observed between the parts of the same organ. However, it is important to underline that the screening is based on the observation of the intensity of the reaction after addition of the reagent. The actual amount of each compound is therefore not known.

The AqP extract caused an increase in body weight of males by 14% (± 1.81). However, this increase was lower than that observed in the control animals, 24% (± 1.87) with a highly significant difference ($p < 0.001$). These data show that the fruit peel extract has an anabolic effect. However, this anabolic effect would be regulated and of lower intensity in the treated animals because the mass gain is lower than that of the controls. The anabolic effect could be explained by the presence of compounds such as flavonoids which have an androgen-like effect. They are able to bind to androgen receptors. The pathway regulating the anabolic effect would therefore involve testosterone receptors (25, 26).

The fresh weight of testis of AqP group (~ 0.246 ± 0.021) was lower than that of the control group (~ 0.311 ± 0.016) with a highly significant difference ($P < 0.001$). In the case of the dry weight of the testis, a very significant reduction was also observed in the treated animals of the AqP group (~ 0.053 ± 0.002) compared to the controls (~ 0.057 ± 0.001) ($P < 0.01$). These data show that AqP extract causes a reduction in testicular weight. Steroidogenesis is one of the causes of the increase in the weight of the sexual organs like testis (27). Weight, height and secretory function are tightly regulated by androgens. The increase in these parameters could be considered as a biological indicator of the effectiveness of the plant in stimulating steroidogenesis (28). Thus, reduction in fresh and dry weight of the testis observed in our study suggests that the extract does not stimulate steroidogenesis. In men, the weight of the testis can be considered as an indicator of normal spermatogenesis but also of the quantity of sperm (29, 30). The low testicular weight observed in males is consistent with the idea of an alteration of spermatogenesis.

The analysis of the sperm density confirms this hypothesis of the alteration of spermatogenesis by the extract. Indeed, the animals treated with the peel extract presented a lower sperm density (~ 54.25.106 spz / ml ± 7.736) than control group (~ 57.95.106 spz / ml ± 7.169) with a difference not significant ($P = 0.468$), thus suggesting that the peel extract decreases sperm density and therefore does not stimulate spermatogenesis. Although the AqP extract did not stimulate sperm production to a level at least equivalent to that of controls, it had no deleterious effect on testicular tissue as evidenced by testicular sections. In fact, seminiferous tubules had preserved their integrity and mostly presented a lumen as in the control group, thus showing active and complete spermatogenesis in most of the tubules. However, in AqP group, elongated spermatids as well as young immature spermatozoa were more frequently observed in the seminiferous epithelium than mature spermatozoa in the tube lumen unlike the control group. Based on this accumulation of elongated spermatids and immature spermatozoa, we could hypothesize that AqP would disturb progression of spermatogenesis. This disturbing would be located at the final stages of spermiogenesis. The results of the histological sections are therefore consistent with the analysis of the sperm density and the low testicular weight.

The results relating to weight of testis, sperm density and histological sections are in accordance with an alteration of spermatogenesis following treatment with peel extract. These results are surprising knowing that aqueous extract contains such secondary metabolites similar to those found in ethanolic and aqueous extract of whole fruit, which stimulates spermatogenesis (12, 13, 21). such as sterols, flavonoids, saponins. This raises questions about the mechanisms involving all the different metabolites detected in the fruit peel extract, specifically their necessary quantity, their nature, their place of action and their interactions with other metabolites. We certainly detected the presence of sterols, flavonoids, saponins in the extract, but the distinction of the nature of these different types of each group of metabolites was not possible in this study, unlike the work of (31). In the case of flavonoids for example, some can reduce the expression of androgen receptors, inhibit the activity of the receptor by causing its relocation outside the nuclei of the target cells (32,33) while others are able to bind to androgen receptors and produce an androgen-like effect or inhibit aromatases in order to maintain the endogenous level of testosterone (25, 26, 34). The current results do not identify the precise mechanisms involved. Although the extract does not stimulate steroidogenesis as indicated by the low testicular weight, however, there is no data indicating variation of testosteron endogenous concentration of the treated animals and controls animals allowing comparison. Based on this and our observations, we can therefore suppose that the extract would reduce the endougenous concentration of testosterone or inhibit the function of androgen receptors preventing the binding of testosterone. This could partly explain the reduction in testicular weight and sperm density.

The aqueous peel extract improved sperm quality at a dose of 100 mg/kg body weight. Indeed, the peel increases the percentage of motile spermatozoa, about twice as much (~56% ± 5.47) compared to the control (~29% ± 2.23) with a highly significant difference ($P < 0.001$). The percentage of normal spermatozoa (~91.9% ± 1.342) also increased compared to the control (~85% ± 4.677) with a significant difference ($P < 0.05$). We believe that this improvement in mobility and morphology could be linked to the secondary metabolites present and particularly to flavonoids, quinones and saponins. They would act directly or indirectly during spermiogenesis and the acquisition of mobility in the epididymis. Several hypotheses could be considered. The first hypothesis that would explain the improvement in sperm motility and morphology relates to antioxidant enzymes and non-enzymatic antioxidants improving sperm parameters (35, 36, 37, 38). Indeed, morphology and mobility of spermatozoa are closely related to the balance between the production and activity of free radicals as well as antioxidant (39).

Thus, the level of reactive oxygen species must necessarily be maintained at a low level by antioxidants at the risk of disrupting spermatogenesis and the functioning of spermatozoa (40, 41, 42, 43). An exogenous supply by administration of a plant extract could stimulate the defense against oxidative stress (44, 45, 46). This is particularly the case with the peel extract in which polyphenols (flavonoids, anthocyanins) and quinones whose antioxidant activity is widely known (47,48). Other determining parameters for obtaining motile and normal spermatozoa such as the osmolarity of the seminal fluid, the efflux of fluid caused by osmosis during the differentiation of spermatids into spermatozoa, aquaporins, phosphorylation, calcium, bicarbonate ions (46, 49) could also be influenced by the secondary metabolites contained in the peel of the fruit. The intervention of flavonoids in the functioning of the mitochondria present in the sperm flagellum would also be possible (50). But the identification of the precise mechanisms remains difficult because in our study, only the distinction of the main classes of compounds was possible.

Conclusion:-

The results presented in this work show that in males, the aqueous extract of the peel of the fruit of Kigeliaafricana regulates muscle mass gain and improves the mobility and morphology of spermatozoa. Regarding the quantity of spermatozoa and testis sections, the peel extract does not block spermatogenesis but seems to affect its progression as well as its quality. It nevertheless maintains the integrity of the testicular tissue. The effects of Kigelia fruit peel on sperm parameters are related to the different secondary metabolites detected in the peel. However, questions about the mechanisms involving them still persist.

Acknowledgement:-

We would like to thank the laboratory technicians for their availability and sincerecollaboration in this study. Finally, we would like to thank Dr. Yao Konan, SystematicBotanist Researcher at the National Center for Floristics at Félix Houphouet-BoignyUniversity, for his contribution to the identification of the plant used in this study.

Conflicts of Interest:-

The authors declare no conflicts of interest regarding the publication of thispaper.

References:-

1.Elisabetsky E, Balick M J, Laird SA. Medicinal Resources of the Tropical Forest: Biodiversity and ItsImportance to Human Health, Columbia University Press, New York, NY, USA, 1996.
2.Roodt V.Kigeliaafricana; In The Shell Field Guide to The Common Trees of The Okavanga Delta andMoremi Game Reserve, Gaborone, Botswana: Shell Oil, Botswana. 1992; 4: 176-80.
3. Grace OM, Light ML, Lindsey KL, Mulholland DA, van Staden J, Jager AK, EloJN. Antibacterialactivity and isolation of active compounds from fruit of the traditional African medicinal tree Kigeliaafricana.S. Afr. J. Bota. 2002; 68: 220-22.
4. Picerno, P., Autore, G., Marzocco, S., Meloni, M., Sanogo, R. and Aquino, R.P.Anti-Inflammatory Activity of Verminoside from Kigeliaafricana and Evaluationof Cutaneous Irritation in Cell Cultures and Reconstituted Human Epidermis.J. Nat. Prod.2005 ;68 : 1610-14. https://doi.org/10.1021/np058046z
5. Olubunmi A, Olatunji AG, Adeyemi OS, Scott FO. Antioxidant and antimicrobial activity of cuticularwax from Kigeliaafricana. FABAD J. Pharm. Sci. 2009;34: 187-94.
6. HoughtonPJ,Photiou A, Uddin S, Shah P, Browning M, JacksonSJ, Retsas S. Activity of Kigelia pinnata against Melanoma and Renal CarcinomaCell Lines. Planta Medica. 1994 ;60 : 430-433. https://doi.org/10.1055/s-2006-959525
7. Jackson S, BeckettK. Sausage Tree Kigeliapinnta: An Ethnobotanicaland Scientific Review. Herbal Gram: American Botanical Council. 2012;94 : 48-59.

8.Olalye MT, Rocha JBT. Commonly used tropical medicinal plants exhibt distinct in vitro antioxidant activities against hepatotoxins in rat liver. Exp ToxicolPathol.2007 ; 58(6) : 433-38.
9. OlaleyeMT,Rocha BJ. Acetaminophen-induced liver damage in mice: effects of some medicinal plants on the oxidative defense system. Exp ToxicolPathol.2008 ;59(5) : 319-27.
10.Kela SL, Ogunsusi RA, Ogbogu VC, Nwude N. Screening of some Nigerian plants for molluscicidal activity. Revue d'élevage et de médecinevétérinaire des pays tropicaux. 1989 ;42(2): 195-02
11.Ogbeche KA, Ogunbiyi YO, Duru FIO. Effect of Methanol ExtractofKigeliaafricana on Sperm Motility and Fertility in Rats. Nig. J. Health Biomed Sci. 2002 ; 1 : 113-16.https://doi.org/10.4314/njhbs.v1i2.11467
12. AzuO,&DuruF,Osinubi A, Noronha C,EleshaO,Okanlawon A. Preliminary study on the androgenic effects of Kigelia Africana fruit extract in male Sprague-Dawley rats. Mid. East Fertil.Soci. J.2009; 14: 185-91.
13.Azu OO, Duru FIO, Osinubi AA, Noronha CC, EleshaSO,OkanlawonAO. Preliminary Study on the Antioxidant Effect of KigeliaafricanaFruit Extract (Bignoniacieae) in Male Sprague-Dawley Rats. Afr. J. Biotechnology. 2010 ; 9 : 1374-81. https://doi.org/10.5897/AJB10.933
14.Adeparusi EO, Dada AA and Alale OV. Effect of medicinal plant (Kigeliaafricana) on sperm quality of African catfish, Clariasgariepinus (Burchell, 1822) broodstock. J. Agric. Sci. 2010. 2(1):193 – 199.
15.Azu OO, Duru FIO, Osinubi AA, Oremosu AA, Noronha CC, EleshaSO,Okanlawon, A.O. Histomorphometric Effects of Kigeliaafricana (Bignoniaceae)Fruit Extract on the Testis Following Short-Term Treatment with Cisplatinin Male Sprague–Dawley Rats. Middle East Fertil.Soci. J. 2010;15 : 200-8.https://doi.org/10.1016/j.mefs.2010.07.001
16.Azu OO, Duru FIO, Osinubi AA, Oremosu AA, Norohna CC, OkanlawonAO,Elesha, SO. Long-Term Treatment with Kigeliaafricana Fruit Extract Ameliorates the Testicular Toxicity Following Cisplatin Administration inMale Sprague-Dawley Rats. J. Med. Plants Res. 2011;5 : 388-97
17. Nabatanzi A, Nkadimeng SM, Lall N, Kabasa JD, McGaw LJ.Ethnobotany, Phytochemistry and Pharmacological Activity of Kigeliaafricana(Lam.) Benth. (Bignoniaceae). Plants , 2020 ;9 : Article No. 753.https://doi.org/10.3390/plants9060753
18.HalderS, Sharma A. A Review on Kigelia Africana. World J.Pharma. Res.2017 ;6 : 389-11.
19.Saini AK, Chauhan PK, SinghV, Sharma P. Phytochemical, Antioxidant& in Vitro Antibacterial Activity of Aqueous and Ethanolic Fruit Extracts ofKigeliaafricana, Indian J. Pharma. Bio. Res. 2013;1 : 46-2. https://doi.org/10.30750/ijpbr.1.2.12
20.Fagbohun OF, BabalolaOO, AgboolaFK, Joseph JS, Malindisa S, MsagatiTAM Evaluation of Phytochemicals, Antioxidants, Trace Elements in Kigeliaafricana Fruit Extracts and Chemical Profiling Analysis Using UHPLC-qTOF-MS2Spectrometry. Bio Trace Elt Res. 2020 ;195 : 679-95.
21.Koné MC, Kpan BW, Kandé I, Kouakou RK, Koman RS, KonanY, KouakouK. Effect of Different Parts of Kigeliaafricana Fruit Aqueous Extracts on Sperm Parameters and Testis. Adv Reproduc Sci. 2021; 9(3): 171-88
22.Zirihi GN, KraAM,Guede-Guina F. Evaluation of the AntifungalActivity of Microglossapyrifolia (Lamarck) O. Kunze (Asteraceae) "PYMI" on thein Vitro Growth of Candida albicans. Pharma. Trad. Afr.Med. 2003 ; 17 : 11-8.
23.Ngoula F, Watcho P, Dongmo MC, Kenfack A, KamtchouingP,TchambouеJ. Effects of Pirimiphos-Methyl (an Organophosphate Inesctiside) onthe Fertility of Adult Male Rats. Afr.Health Sci. 2007;7 : 3-9.
24. Sultan C, Priolet G, Benzard Y, Rosa R,Josso F. Hematology Technique.2nd Edition, Flammarion Medicine Science, Paris. 1982https://doi.org/10.1016/j.mefs.2010.07.001
25. D'Arrigo G, Gianquinto E, Rossetti G, Cruciani G, Lorenzetti S,Spyrakis F. Binding of Androgenand Estrogen-Like Flavonoids to Their Cognate (Non)Nuclear Receptors: A Comparison by Computational Prediction. 2021.
26. Xiang Hu, Xusheng Li, Pan Deng, Yulin Zhang, Ruijing Liu, Dongbao Cai, Qingjie Xu, Xinwei Jiang, Jianxia Sun &Weibin Bai. The consequence and mechanismof dietary flavonoids on androgen profiles and disorders amelioration, Critical Reviews in Food Science and Nutrition.2022.63(3):1-24. DOI: 10.1080/10408398.2022.2090893.
27. Price D. & William Ashman H. G. Sex and internal secretions. Williams and Wilkins. Young William C. Baltimore.1961;1 :366-48.
28. Thakur M. & Dixit V. K. Aphrodisiac activity of Dactilorhizahatagirea (D.Don) Soo in Male Albino Rats. Evid. Based complement Med..2007;4(1): 29-31.
29.Sakamoto H., Ogawa Y. & Yoshida H.Relationship between testicular volume and testicular function: comparison of the Prader orchidometric and ultrasonographic measurements in patients with infertility. Asian J.Andro.2008;10(2) :319-24
30. Bahk J. Y., Jung J. H., Jin L. M. & Min S. K. Cut-off value of testes volume inyoung adults and correlation among testes volume, body mass index, hormonal level, and seminal profiles. Uro. 2010;75(6):1318-23

31. Nabatanzi, A., Nkadimeng, S.M., Lall, N., Kabasa, J.D. and McGaw, L.J. Antioxidantand Anti-Inflammatory Activities of Kigeliaafricana (Lam.) Benth. Evidence-Based Complementary and Alternative Medicine , 2020, Article ID: 4352084.
32.Zhu W, Zhang JS, Young CY. Silymarin inhibits function of the androgen receptor by reducing nuclear localization of the receptor in the human prostate cancer cell line LNCaP. Carcinogenesis, 2001;22(9): 1399-403.
33. YangF, songL, WangH, WangJ, Xu z,Xing N. Oncology Reports 2015;33: 2659-2668,
34. Jeong, H.J., Shin, Y.G., Kim, I.H. and Pezzuto, J.M. Inhibition of AromataseActivity by Flavonoids. Archives of Pharmacal Research. 1999;22 : Article 309.https://doi.org/10.1007/BF02976369
35. Gualtieri R, Kalthur G, Barbato V, Longobardi S, Di Rella F, Adiga SK, Talevi R. Sperm Oxidative Stress during In Vitro Manipulation and Its Effects on Sperm Function and Embryo Development. Antioxidants (Basel). 2021;10(7):1025. doi: 10.3390/antiox10071025. PMID: 34202126; PMCID: PMC8300781.
36.Gholami-Ahangaran M, Karimi-Dehkordi M, Akbari Javar A, Haj Salehi M, Ostadpoor M. A systematic review on the effect of Ginger (Zingiber officinale) on improvement of biological and fertility indices of sperm in laboratory animals, poultry and humans. Vet Med Sci. 2021;7(5):1959-1969. doi: 10.1002/vms3.538. Epub 2021 Jun 30. PMID: 34191404; PMCID: PMC8464296.
37.Santiago J, Silva JV, Santos MAS, Fardilha M. Fighting Bisphenol A-Induced Male Infertility: The Power of Antioxidants. Antioxidants (Basel). 2021;10(2):289. doi: 10.3390/antiox10020289. PMID: 33671960; PMCID: PMC7919053.
38.De Luca MN, Colone M, Gambioli R, Stringaro A, Unfer V. Oxidative Stress and Male Fertility: Role of Antioxidants and Inositols. Antioxidants (Basel). 2021;10(8):1283. doi: 10.3390/antiox10081283. PMID: 34439531; PMCID: PMC8389261.
39.Krishnamoorthy G, Venkataraman P, Arunkumar A, Vignesh RC, AruldhasMM,Arunakaran, J. Ameliorative Effect of Vitamins (Alpha-Tocopheroland Ascorbic Acid) on PCB (Aroclor 1254) Induced Oxidative Stress in Rat EpididymalSperm. Reproduc.Toxico. 2007;23 : 239-245.https://doi.org/10.1016/j.reprotox.2006.12.004
40.Lewis B, Aitken RJ. A Redox-Regulated Tyrosine PhosphorylationCascade in Rat Spermatozoa. J.Androl.2001;22 : 611-622.
41.Saleh RA, Agarwal A. Oxidative Stress and Male Infertility: From ResearchBench to Clinical Practice. J.Androl. 2002 ; 23 : 737-752.
42.Agarwal A, Virk G, Ong C,Du Plessis SS. Effect of Oxidative Stresson Male Reproduction. W.J. Men ’sHealth.2014 ;32 : 1-17.
43.O’Flaherty C. Peroxiredoxin 6: The Protector of Male Fertility. Antioxid. 2018;7,Article No. 173. https://doi.org/10.3390/antiox7120173
44.Daunter B, Hill R, Hennessey J, Mackay EV. Seminal Plasma Biochemistry.I. Preliminary Report: A Possible Mechanism for the Liquefaction ofHuman Seminal Plasma and Its Relationship to Spermatozoal Motility. Androl. 1981 ;13 : 131-141. https://doi.org/10.1111/j.1439-0272.1981.tb00019.x
45.Kawakami E, Takemura A, Sakuma M, Takano M, Hirano T, Hori T,Tsutsui T. Superoxide Dismutase and Catalase Activities in the SeminalPlasma of Normospermic and Asthenozoospermic Beagles. J.Vet.MedSci. 2007 ;69 :133-136. https://doi.org/10.1292/jvms.69.133
46.Martin-Hidalgo D, Bragado MJ, Batista AR, Oliveira PF, Alves MG.Antioxidants and Male Fertility: From Molecular Studies to Clinical Evidence.Antioxid. 2019 ;8, Article No. 89. https://doi.org/10.3390/antiox8040089
47.Dias MC, Pinto DCGA, Silva AMS. Plant Flavonoids: Chemical Characteristics and Biological Activity. Molecules. 2021;26(17):5377. doi: 10.3390/molecules26175377. PMID: 34500810; PMCID: PMC8434187.
48.Nowicka B, Trela-Makowej A, Latowski D, Strzalka K, Szymańska R. Antioxidant and Signaling Role of Plastid-Derived Isoprenoid Quinones and Chromanols. Int J Mol Sci. 2021;22(6):2950. doi: 10.3390/ijms22062950. PMID: 33799456; PMCID: PMC7999835.
49.Pereira R, Sa R, Barros A, Sousa M. Major Regulatory MechanismsInvolved in Sperm Motility. As J Androl.2017;19 : 5-14.
50.Kicinska A, Jarmuszkiewicz W. Flavonoids and Mitochondria: Activation of Cytoprotective Pathways? Mol. 2020;25(13):3060. doi: 10.3390/molecules25133060. PMID: 32635481; PMCID: PMC7412508.