

| | | |
|---|---|---|
|  <p>ISSN NO. 2320-5407</p> | <p>Journal Homepage: -www.journalijar.com</p> <p>INTERNATIONAL JOURNAL OF ADVANCED RESEARCH (IJAR)</p> <p>Article DOI:10.21474/IJAR01/7405 DOI URL: http://dx.doi.org/10.21474/IJAR01/7405</p> |  <p>INTERNATIONAL JOURNAL OF ADVANCED RESEARCH (IJAR) ISSN 2320-5407 Journal Homepage: http://www.journalijar.com Journal DOI:10.21474/IJAR01</p> |
|---|---|---|

RESEARCH ARTICLE

AGENESIS OF CORPUS CALLOSUM: A LATE DISCOVERY WITH NEUROPSYCHIATRIC SYMPTOMS.

Youness Mamouni Alaoui, Yassine Otheman, Adil Akanour, Mohamed Kadiri, Jamal Mehssani and Mohamed zakarya Bichra.

Department of Psychiatry, Military Hospital of Instruction Mohammed V, Rabat, Morocco.

Manuscript Info

Manuscript History

Received: 13 May 2018
Final Accepted: 15 June 2018
Published: July 2018

Keywords:-

Agenesis of the corpus callosum, dementia syndrome, neuropsychiatric disorders

Abstract

Agenesis of the Corpus Callosum (ACC) is a cerebral malformation which belongs to the midline diseases; its prevalence is difficult to specify. It is characterized by clinical and etiological heterogeneity. It can be complete or partial, associated or not to other malformations. Thanks to the progress of imagery techniques and genetics, the diagnosis of this malformation is possible early, even in the antenatal period. We report here the case of a patient with an ACC, discovered in an elderly person after the occurrence of late psychiatric disorders.

Copy Right, IJAR. 2018., All rights reserved.

Introduction:-

Corpus callosum is the main inter hemispheric cerebral commissure, and the largest connective pathway in the brain. Its function is related to coordination and complex problem-solving. The agenesis of this brain structure is a well-known congenital cerebral malformation that can be either partial or total, isolated or associated with other brain or extra-brain abnormalities. Its aetiologies are multiple. The diagnosis of agenesis of the corpus callosum (ACC) is essentially based on brain MRI. The clinical signs are variable and may be missing; its discovery is sometimes fortuitous. We report here the case of a patient with an ACC, discovered in an elderly person after the occurrence of late psychiatric disorders.

Clinical case:-

Mr .A.C is a 72 year oldman, married, father of two children, he is the youngest of two siblings, born of a non-consanguineous couple, and he is a retired civil servant. He had an ordinary childhood, he does not have any medical or psychiatric history, and is described by his wife as a sociable and responsible person.

The patient was referred to psychiatric consultation, by his family's physician, for suicidal ideations, anxiety, persecutive delusion, associated with insomnia, and behavioural disorders made of motor instability. These disorders were of progressive installation, and have been aggravated for a month. Given the persistent suicidal risk, the patient was admitted to psychiatric ward, for better diagnostic and therapeutic management, as well as to monitor him closely. The patient was given antipsychotic medication: risperidone (1 mg/day for 3 days then 2mg/day), and anxiolytic medications: lorazepam (1 mg/nightly). The neurological examination was normal, except for mnesic fixation disorders, so the patient had no apraxia, agnosia or language disorder. EEG and karyotype were normal. In parallel, all the other biological and physiological examinations were normal.

Corresponding Author:-YounessMamouniAlaoui.

Address:-Department of Psychiatry, Military Hospital of Instruction Mohammed V, Rabat, Morocco.

Cerebral MRI showed total agenesis of the corpus callosum, dilation of the ventricular junction and occipital horns, discrete cortical atrophy, and bilateral hippocampal atrophy (figure 1,2).

Discussion:-

The corpus callosum is the main inter-hemispheric structure of the brain; it develops between the third and the fifth month of conception, and continues to change even in adulthood. According to the literature, the prevalence of CCA is difficult to specify, especially because of asymptomatic forms. It ranges from 0.3 to 0.7% in the general population [1]. There are early-onset forms whose clinical manifestations evoke a central disease such as hypotonia [2], convulsions, craniofacial dysmorphism, microcephaly or macrocephaly [3].

In other cases, diagnosis is made after epileptic seizures, behavioral disorders (irritability), intellectual deficit, memory disorders; focal neurological signs [4] or a complex malformative set of the nervous system. Anterior pituitary deficiency or recurrent hypothermia may also be linked to this malformation [5].

While isolated forms, are often detected in the context of a family survey or fortuitously during the assessment of an intercurrent illness [6].

The diagnosis of ACC can be made either by antenatal ultrasound [7] or by MRI [8]. MRI usually shows a dilatation of the posterior horns of the lateral ventricles, the absence of septum pellucidum, the ascension of the third ventricle filling the space left by the absence of the septum of the corpus callosum, and a radial disposition of the median furrows [9].

In the case of our patient, the MRI showed in addition: Bilateral hippocampal atrophy that could explain memory disorders, and discrete cortical atrophy, that may be the cause of a dementia syndrome, that could explain the behavioral disorders in this patient.

The etiologies of ACC are multiple; they may be of metabolic, toxic, vascular, infectious or genetic origin.

However, in this case, it is difficult to search for the origin of this malformation, since the patient is old and his parents have died.

The prognosis of ACC is difficult to specify [10], it depends largely on the associated malformations. Nevertheless, it seems that the prognosis of isolated ACC is better than that of ACC associated with other malformations. This could explain the asymptomatic evolution in our patient during all these years, with a good socio-professional insertion.

Conclusion:-

Many organic pathologies are fortuitously discovered during neuropsychiatric disorders. This is the case of our patient, in whom behavioral disorders of recent appearance have led to the diagnosis of a total ACC. This shows the capacity of the brain to compensate for missing structures, by establishing new connections between the two hemispheres, even if the process involved in these neuroplasticity mechanisms is still unknown.

Figures

Figure 1: Sagittal section showing agenesis of the corpus callosum

Figure 2: coronal section showing agenesis of the corpus callosum

Conflicts of interest:-

The authors do not declare any conflict of interest for this work.

Authors' collaboration:-

All authors were actively Involved in the development of this work.

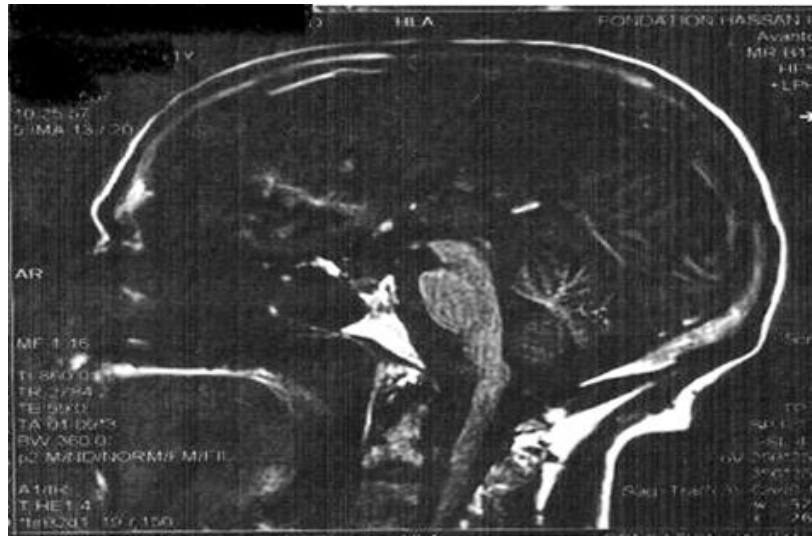


Figure 1:-Sagittal section showing agenesis of the corpus callosum

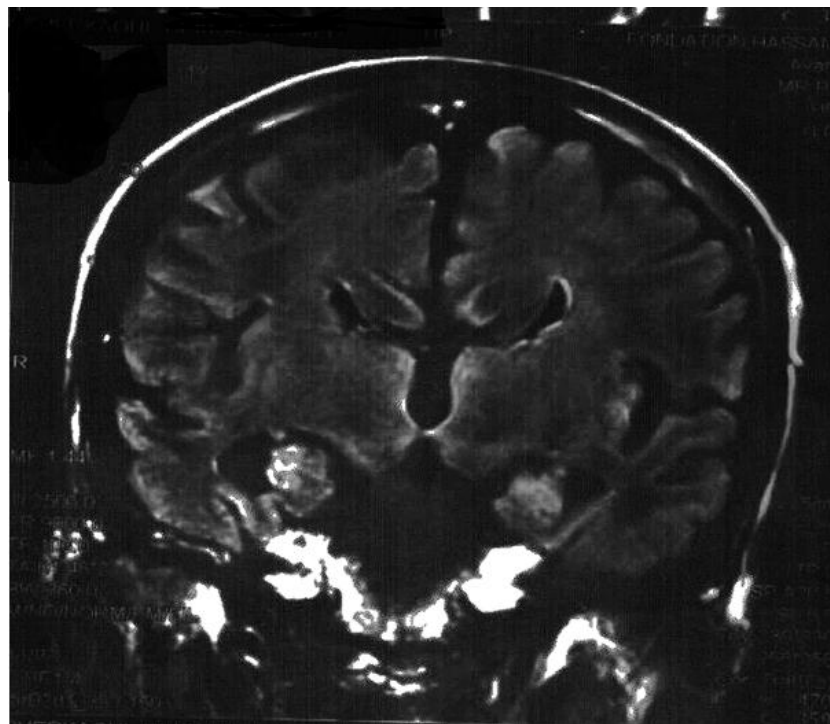


Figure 2:-Coronal Section showing agenesis of the corpus callosum

References:-

1. Chouchane M, Benouachkou V, Debouche, Giroud M, Durand C, Gouyon JB. Les agénésies du corps calleux : aspects étiologiques, cliniques, moyens de diagnostic et pronostic .ArchPediatr 1999 ; 1306-1
2. Couture A, Droullé P, Didier F. Les malformations cérébrales.In : Couture A, Veyrac C, Baud C, éd. Echographie cérébrale du fœtus au nouveau-né. Montpellier : Sauramps ; 1994.p.267-370.
3. D'Ercole C, Girard N, Cravello L, Boubli L, Potier A, Raybaud C, et al. Prenatal diagnosis of fetal corpus callosum agenesis by ultrasonography and magnetic resonance imaging.PrenatDiagn 1998,18:247-53 .
4. Giroud M, Tenenbaum D, Morizot B, Ferlet P, Chevalier Nivelon A, DumasR, et al. Les agénésies du corps calleux. Polymorphisme clinique. Sem Hop 1987 ; 63 :1843-9.
5. Gonzales E, Caeymaex L, Aboura Vial M, Laveaucoupet J, PLabrunep, Tachdjian G . Cocaine et trisomie 8 associées au diagnostic prénatal d'agénésie du corps calleux. J GynecolObstetBiolReprod 2005 ; 34 :803-806.
6. Jezequel Ch, Vuong MH. Agénésie du corps calleux chez l'enfant. Rev Ped 1984; 2: 89-96.
7. Lacey DJ. Agenesis of the corpus callosum : clinical features in 40 children.Am J Dis Child 1985 ; 139 :953-5
8. Lemesle M, Giroud M, Madinier G, Martin D, Baudouin N, Binnert D, et al. Agénésies du corps calleux : les modes de révélation chez l'adulte. Rev Neurol1997 ;153 :256-61.
9. Nizard S, Barthez-Carpentier MA, Gelot A, Hebert C, Abimelech M, OEsperandieu. Les agénésies isolées et familiales du corps calleux sont elles de bon pronostic ? Archiv de Péd 11 2004 ; 429-431.
10. Shapiro WR, Williams GH, Plum F. Spontaneous recurrent hypothermia accompanying agenesis of corpus callosum. Brain 1969; 92 :423-36.