

 <p>ISSN NO. 2320-5407</p>	<p>Journal Homepage: -<a href="http://www.journalijar.com">www.journalijar.com</a></p> <h2 style="text-align: center;">INTERNATIONAL JOURNAL OF ADVANCED RESEARCH (IJAR)</h2> <p style="text-align: center;">Article DOI:10.21474/IJAR01/8075 DOI URL: <a href="http://dx.doi.org/10.21474/IJAR01/8075">http://dx.doi.org/10.21474/IJAR01/8075</a></p>	 <p>INTERNATIONAL JOURNAL OF ADVANCED RESEARCH (IJAR) ISSN 2320-5407 Journal Homepage: <a href="http://www.journalijar.com">http://www.journalijar.com</a> Article DOI:10.21474/IJAR01/8075</p>
---	--	--

### RESEARCH ARTICLE

#### ABSENCE OF MUSCULOCUTANEOUS NERVE - A RARE VARIATION.

Anagha V S<sup>1</sup> and K Jayasree<sup>2</sup>.

1. Senior Resident, Department of Anatomy, Government Medical College, Kozhikode, Kerala, India.
2. Head of Department, Government Medical College, Kozhikode, Kerala, India .

#### Manuscript Info

##### Manuscript History

Received: 11 September 2018

Final Accepted: 13 October 2018

Published: November 2018

##### Keywords:

Musculocutaneous Nerve, Median Nerve

#### Abstract

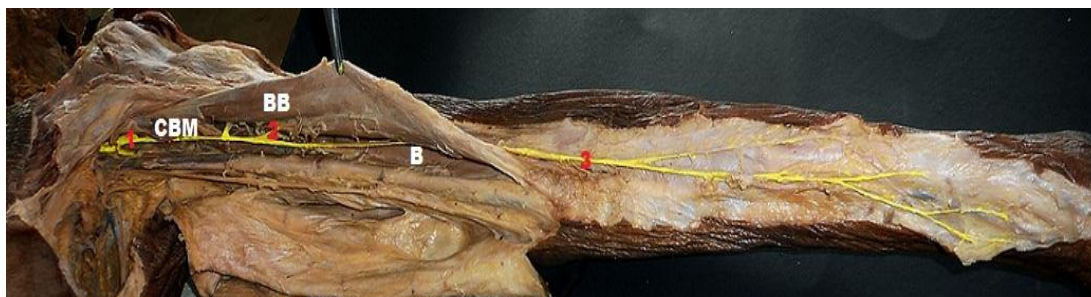
This study was carried out in the Department of Anatomy, Government Medical College, Kozhikode, Kerala in 100 upper limbs of 50 cadavers. The variations in the origin, course and branching pattern of musculocutaneous nerve were observed. Complete absence of musculocutaneous nerve was observed in the left upper limb (1%) of a male cadaver and median nerve was found to replace the musculocutaneous nerve. Knowledge of this kind of variation is of great use for the Anesthetists, Orthopaedicians and Plastic surgeons for diagnosing the condition as well as during reconstructive surgeries.

*Copy Right, IJAR, 2018,. All rights reserved.*

#### Introduction:-

Variation in the brachial plexus and its terminal branches are not uncommon. But complete absence of musculocutaneous nerve is very rare.

The musculocutaneous nerve<sup>1</sup> arises from the lateral cord of brachial plexus (C5, C6, C7), opposite the lower border of pectoralis minor. It pierces the coracobrachialis and descends laterally between the biceps and brachialis to the lateral side of arm. Just below the elbow, it pierces the deep fascia lateral to the tendon of biceps and continues as lateral cutaneous nerve of forearm. It supplies coracobrachialis, both the heads of biceps and medial half of brachialis. Through the branch to brachialis, it also supplies the elbow joint. The nerve also sends a branch to the humerus which enters the shaft with the nutrient artery.



**Fig 1:-**Normal course and branching pattern of musculocutaneous nerve in the left upper limb of a male cadaver

**Corresponding Author:-Anagha V S.**

Address:-Senior Resident, Department of Anatomy, Government Medical College, Kozhikode, Kerala, India.

1. Musculocutaneous nerve
2. Branch to biceps brachii
3. Lateral cutaneous nerve of forearm

CBM- Coracobrachialis muscle, BB- Biceps Brachii, B- Brachialis

The anatomical knowledge of musculocutaneous nerve and its variations is important because many surgical procedures in the upper limb involve mobilization and displacement of muscles of anterior aspect of arm and unawareness of the variations may lead to damages of a major nerve.

### Aim and objectives:-

#### Aim:

The aim of the study is to determine the origin, course and branching pattern of musculocutaneous nerve and its variations.

#### Objectives:

To find out

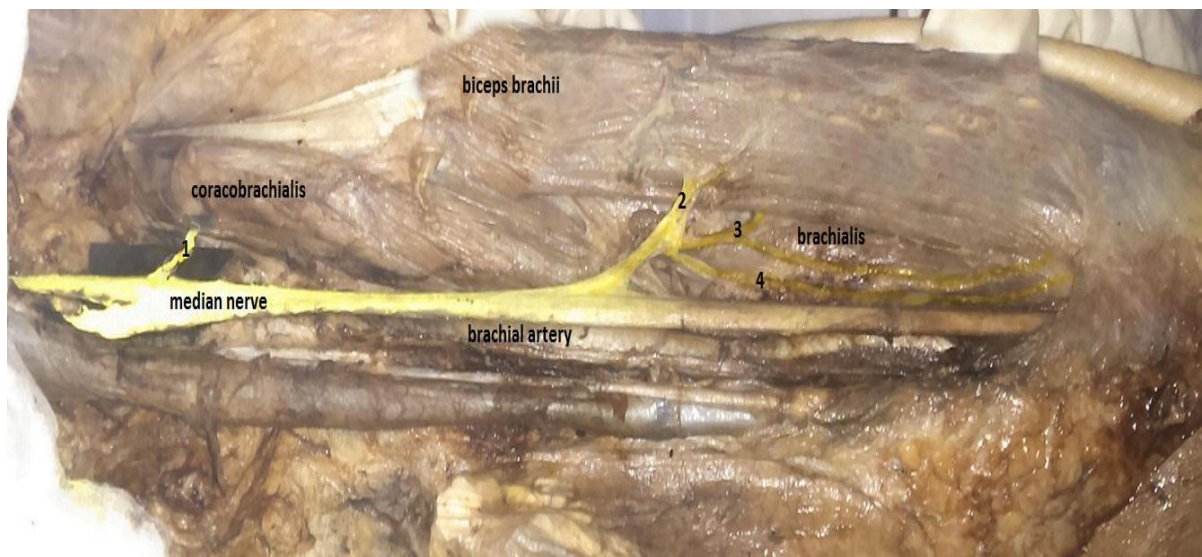
1. Presence or absence of musculocutaneous nerve
2. Origin of musculocutaneous nerve
3. Variation in the course and branching pattern

### Materials AndMethods:-

The study was carried out in the Department of Anatomy, Government Medical College, Kozhikode. Dissections of 100 upper limbs of formalin fixed cadavers were carried out following the guidelines in The Cunningham's Manual of Practical Anatomy<sup>2</sup>.

### Results:-

Among the 100 upper limbs dissected, we observed a complete absence of musculocutaneous nerve in the left upper limb of one male cadaver. It was replaced by the median nerve which supplied coracobrachialis, medial half of brachialis and biceps brachii muscles and gave off the lateral cutaneous nerve of forearm, in addition to its usual pattern of innervation. In the right upper limb of the same cadaver, normal course and branching pattern of musculocutaneous nerve was observed.



**Fig 2:-**Absence of musculocutaneous nerve in the left limb of a male cadaver, replaced by median nerve (Le Minor's<sup>3</sup> Type 5)

1- Branch to coracobrachialis, 2- Branch to biceps brachii, 3- Branch to brachialis, 4- Lateral cutaneous nerve of forearm

### Discussion:-

In the embryo, the forelimb muscles develop by regional expression of five Hox D genes, from the mesenchyme of paraxial mesoderm in the fifth week of the intrauterine life. The growth cones of the motor axons arrive at the base of the limb bud to form the brachial plexus and continue in the limb bud. The guidance of the developing axons is regulated by the expression of chemo attractants and chemo repulsants in highly coordinated site-specific manner. Tropic substances such as brain-derived neurotropic growth factor, c-kit ligand, neutrin-1 and neutrin-2 attract the correct growth cones or support the viability of the growth cones that happen to take the right path. The significant variations in nerve pattern may be the result of altered signaling between the mesenchymal cells and the neuronal growth cones or circulatory factors at the time of fusion of brachial plexus cords<sup>4</sup>.

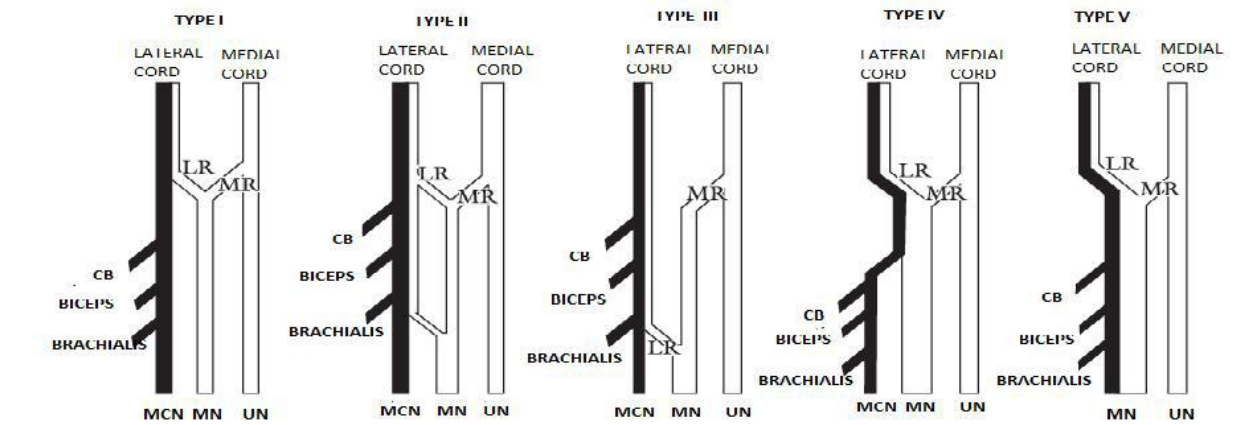
There is little data in the literature on the prevalence of absence of the musculocutaneous nerve. In the present study, absence of the nerve was noted in the left upper limb of a male cadaver. Here, median nerve replaced the musculocutaneous nerve; coracobrachialis, biceps brachii and brachialis were supplied by branches arising from the median nerve. Median nerve also gave the lateral cutaneous nerve of forearm.

The absence of musculocutaneous nerve is described in literature by various authors like Beheiry E E<sup>5</sup> (2004), Joshi S D et al (2008)<sup>6</sup>, Virendra Budhiraja et al<sup>7</sup> (2011), Priti Chaudhary et al<sup>8</sup> (2013), Dr.Naimish R.Bhojak et al<sup>9</sup> (2014) and Lina Leng et al<sup>10</sup> (2016). The findings in the present study (1%) is close to the results obtained by Beheiry EE<sup>5</sup> (1.6%) and Lina Leng et al<sup>10</sup> (3.12%) as shown in the Table 1.

Author	Total No: of Limbs studied	Absence of nerve	Frequency (%)
Beheiry EE	60	1	1.6%
Joshi S.D et al	85	5	5.5%
Virendra Budhiraja et al	116	13	11.2%
Priti Chaudhary et al	60	6	10%
Dr.Naimish R.Bhojak et al	50	2	4%
Lina Leng et al	160	5	3.12%
Present Study	100	1	1%

**Table 1:-**Comparison of frequency of absence of musculocutaneous nerve

Le Minor<sup>3</sup> (1992) classified the variations of the musculocutaneous and median nerves into 5 types.



**Fig 3:-**Schematic representation of Le Minor's classification

LR-Lateral root, MR-Medial root, CB- Coracobrachialis, MN-Median nerve, MCN-Musculocutaneous nerve, UN-Ulnar nerve

**Type I:**

Normal classical pattern. There is no communication between the median nerve and the musculocutaneous nerve.

**Type II:**

The fibers of the lateral root of the median nerve pass through the musculocutaneous nerve and join the median nerve in the middle of the arm.

**Type III:**

The lateral root fibers of the median nerve pass along the musculocutaneous nerve and after some distance leave it to form the lateral root of the median nerve.

**Type IV:**

The musculocutaneous fibers join the lateral root of the median nerve and after some distance, the musculocutaneous nerve arises from the median nerve.

**Type V:**

The musculocutaneous nerve is absent and the entire fibers of the musculocutaneous nerve pass through the lateral root and fibers to the muscles supplied by the musculocutaneous nerve branch out directly from the median nerve.

The findings in our study are similar to Type V of Li Minor's.

The existence of this variation may be attributed to the random factors influencing the mechanism of formation of limb muscles and the peripheral nerves during embryonic life. These observations should be considered in a high median nerve injury which can occur in the axilla or proximal arm. In such cases, patients can present with weakness of flexion and supination at the elbow. There can also be hypoesthesia of lateral surface of the forearm, in addition to the classical signs of median nerve palsy. Knowledge of this kind variation will be of great use for the Anesthetists, Orthopaedicians and Plastic surgeons for diagnosing the condition as well as during reconstructive surgeries.

**Conclusion:-**

The present study was a cadaveric study of musculocutaneous nerve conducted by dissection of 100 upper limbs of 50 adult cadavers in the Department of Anatomy, Government Medical College, Kozhikode, Kerala. The variations in the origin, course and branching pattern of musculocutaneous nerve and its relation with median nerve were studied and documented.

The results of the present study can be summarized as:

1. The presence of musculocutaneous nerve was observed in 99% of limbs and absence was noted in 1%, where the median nerve was found to replace the musculocutaneous nerve.
2. In 99% cases, the musculocutaneous nerve was found to arise from the lateral cord and in one limb the nerve was absent.

**References:-**

1. Susan Standring, Upper Arm In: Gray's Anatomy, The Anatomical Basis Of Clinical Practice. 41st Edition. ELBS and Churchill Livingstone. 1995.
2. Romanes GJ. Cunningham's Manual of Practical Anatomy. Oxford University Press. 15th edition. 1996:151
3. Le Minor JM. A rare variant of the median and musculocutaneous nerves in man. Arch AnatHistolEmbryol. 1992; 73: 33-42
4. Nakatani T, Shigenori T, Mizukami S. Absence of the musculocutaneous nerve with innervation of coracobrachialis, biceps brachii, brachialis and the lateral border of the forearm by branches from the lateral cord of the brachial plexus. J Anat. 1997; 191: 459-460.
5. Beheiry EE. Anatomical variations of the median nerve distribution and communication in the arm. Folia Morphol. 2004 Aug; 63(3):313-8.
6. Joshi S.D. Joshi S.S. & Athavale S.A. Hitch-Hiking Fibres Of Lateral Cord Of Brachial Plexus In Search Of Their Destination, J. Anat. Soc. India. 2008; 57 (1) 26-29.
7. Budhiraja V, Rastogi R, Asthana AK, Sinha P, Krishna A, Trivedi V. Concurrent variations of median and musculocutaneous nerves and their clinical correlation--a cadaveric study. Ital J AnatEmbryol Arch ItalAnat Ed Embriologia. 2011; 116(2):67-72

8. Chaudhary P, Kalsey G, Singla R, Arora K. Communication Between Musculocutaneous and Median Nerve—Different Types and Their Incidence in North Indian Population, Indian Journal of Clinical Practice. 2013; 24(4): 36471.
9. R.Bhojak DN, Patel DJP, Desai DJN, Ram DSH. Anatomical Variation in Musculocutaneous Nerve –A Cadaveric Study -. Natl J Integr Res Med. 2014; 5(1):92–5
10. LinaLeng LL Huaying Liu, Tiantao Wang, Si D. Classifying Musculocutaneous Nerve Variations Depending on the Origin. J NeurolDisord. 2016; 4(4).