

 <p>ISSN NO. 2320-5407</p>	<p>Journal Homepage: -www.journalijar.com</p> <h2>INTERNATIONAL JOURNAL OF ADVANCED RESEARCH (IJAR)</h2> <p>Article DOI:10.21474/IJAR01/9123 DOI URL: http://dx.doi.org/10.21474/IJAR01/9123</p>	 <p>INTERNATIONAL JOURNAL OF ADVANCED RESEARCH (IJAR) ISSN 2320-5407 Journal Homepage: http://www.journalijar.com Journal DOI:10.21474/IJAR01</p>
---	--	---

RESEARCH ARTICLE

UNUSUAL PRESENTATION OF RARE OVARIAN TUMOR: CASE REPORT.

Fatima usmani, Neena Gupta and Uruj jahan.

Manuscript Info

Manuscript History

Received: 24 March 2019
Final Accepted: 26 April 2019
Published: May 2019

Abstract

Acute abdomen with hemoperitoneum in childbearing age group due to obstetrical reasons is common but it's extremely rare for a woman with gynaecological conditions. In women presenting with hemoperitoneum with acute abdomen and no history of trauma with pregnancy ruled out granulosa cell tumor should be kept in the differential diagnosis. Measurement of markers and frozen section should be readily available to diagnose this rare tumor as well as to prevent incomplete resection. We report a rare case of ruptured granulosa tumor of the ovary. She presented with acute abdomen due to hemoperitoneum.

Copy Right, IJAR, 2019,. All rights reserved.

Introduction:-

40 year old, P3L3, presented to emergency ward with pain abdomen with nausea and vomiting. Her menses were normal. General condition was poor, she was pale with clinical hemoglobin of 6 gm%, pulse of 150/minute and blood pressure of 70/50 mm of Hg. On P/A examination, abdomen was distended with guarding, tenderness, rigidity. Her urine pregnancy test (UPT) was negative. Decision for immediate exploratory laparotomy was taken. Intra operative findings revealed 1.5 litres of hemoperitoneum. Right sided ruptured ovarian mass was seen measuring 8x8 cms. Uterus along with both fallopian tubes were normal and her left ovary was normal. Right sided salpingo-oophorectomy was done and the tissue was sent for histopathological examination. Histopathologic examination revealed well differentiated adult type granulosa cell tumor. Patient was planned for relaparotomy after 6 months and hysterectomy with left sided salpingo-oophorectomy and staging was done. She was stage 1c. She was referred to radiotherapy department for chemotherapy.

Discussion:-

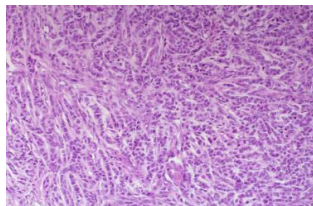
1. Granulosa stromal cell tumors are a type of sex cord stromal cell tumors. These tumors constitute 4.3% of all ovarian neoplasms. These tumors can occur in any age group but they are most common in 50-55 years of age (1).
2. The chances of hemoperitoneum with granulosa cell tumor has been reported in 5 to 20% of cases. It is reported that tumor rupture occurred in 17.6% of patients prior to surgical intervention. However, in diagnosed cases of adult granulosa cell tumor patients' have not presented with acute abdomen (2).
3. Diagnosis is confirmed on laparotomy as in the present case where hemoperitoneum and active bleeding ovarian mass was noticed. Anticipation of these problems and timely actions like frozen sections of the suspicious lesions will help in preventing incomplete surgeries requiring repeat procedures.
4. Management of granulosa tumors depends on the stage of the tumor and age of the patient. Early stage disease in young women requires unilateral salpingo-oophorectomy and surgical staging in an attempt to preserve fertility. In elderly women total abdominal hysterectomy with bilateral salpingo-oophorectomy along with surgical staging is done. The overall survival with stage I and stage II disease is 99%.

5. Patients with large tumor size (≥ 10 -15 cm), stage IC, poorly differentiated tumor, high mitotic index or tumor rupture are said to be high risk and adjuvant chemotherapy should be advised in view of increased risk of relapse. Patients with low risk stage I tumor should be kept on observation. In patients with recurrence or stage III- IV granulosa cell tumors postoperative chemotherapy is recommended but the survival benefit is still not known due to paucity of results and lack of randomized trials, so no treatment has been standardized(3).
6. The lack of specific markers in the identification of granulosa cell tumors has led to development of a panel of antibodies to identify inhibin, calretinin, epithelial membrane antigen, and low molecular weight keratin which is expressed on tumor cells, through immunohistochemistry. Immunohistochemistry not only helps in diagnosis but also is useful in administration of targeted chemotherapy against these tumors.(4)

Conclusion:-

Although rare tumor but should be kept as a differential diagnosis in women of childbearing age presenting as hemoperitoneum where pregnancy is ruled out. Facilities like frozen section should be readily available so as to prevent incomplete resection.

Cells with coffee bean nuclei with folds/grooves seen



References:-

1. Vani BR, Geethamala K, Geetha RL, and Srinivasa MV. Granulosa cell tumor of ovary: A clinicopathological study of four cases with brief review of literature. *J Midlife Health*. 2014; 5(3): 135–138.
2. Taira Y, Hirakawa M, Nagayama C, Ikemiyagi K, Touma T, Tokashiki M. Successful treatment of adult-type granulosa cell tumor of the ovary by palliative radiotherapy. *J Obstet Gynaecol Res*. 2012;38(2):461-5.
3. Segal R, DePetrillo AD, Thomas G: Clinical review of adult granulosa cell tumors of the ovary. *Gynecol Oncol* 1995; 56(3): 338-44.
4. Nofech-Mozes S, Ismiil N, Dubé V, Saad RS, Khalifa MA, Moshkin O, et al. Immunohistochemical characterization of primary and recurrent adult granulosa cell tumors. *Int J Gynecol Pathol*. 2012;31(1):80-90.