

 <p>ISSN NO. 2320-5407</p>	<p>Journal Homepage: -www.journalijar.com</p> <h2 style="text-align: center;">INTERNATIONAL JOURNAL OF ADVANCED RESEARCH (IJAR)</h2> <p style="text-align: center;">Article DOI:10.21474/IJAR01/8892 DOI URL: http://dx.doi.org/10.21474/IJAR01/8892</p>	 <p>INTERNATIONAL JOURNAL OF ADVANCED RESEARCH (IJAR) ISSN 2320-5407 Journal Homepage: http://www.journalijar.com Journal DOI:10.21474/IJAR01</p>
---	--	---

RESEARCH ARTICLE

MAJOR APPROACHES OF ATRAUMATIC SURGERY IN DENTISTRY.

Amália Rossi Dourado¹, Tays de Cássia Lanson¹, Janaína Viriato Silva¹, Fábio Renato Braga Marcato¹, Gabriel Taroco Medina¹, Kauana Caldeira Siqueira¹, Ana Cláudia Ramos¹, Andreia da Silva Borges de Castro¹, Luana Rodrigues de Sá da Silveira¹, Idiberto José Zotarelli Filho^{1,2} and Marcelo Augusto Rudnik Gomes^{1,2}.

1. University Center North Paulista (Unorp) Dental School - São José do Rio Preto – SP, Brazil.
2. Post Graduate and Continuing Education (Unipos), Department of scientific production, Street Ipiranga, 3460, São José do Rio Preto SP, Brazil.

Manuscript Info

Manuscript History

Received: 12 February 2019

Final Accepted: 14 March 2019

Published: April 2019

Key words:-

Surgery. Atraumatic Surgery.
Implantology.

Abstract

Introduction: It is estimated that in dental atraumatic surgery in general, studies of synthesis and meta-analysis and decision analysis that represent nearly 27.0 % of all studies. Most of the selected studies was developed in the USA, Netherlands and the UK. These three countries and 15 journals were responsible for almost 50.0 % of all publications. The other papers were published in other journals and 61 originated from 32 other countries, including Brazil.

Objective: to demonstrate through the literature review the importance of improving the techniques of atraumatic surgeries in dentistry.

Methods: Following the criteria of literary search with the use of the Mesh Terms that were cited in the item below on "Search strategies", a total of 45 papers that were submitted to the eligibility analysis were collated and, after that, 27 studies were selected.

Conclusion: It is concluded that there are several attempts to minimize the effort of the professional, reduce the surgical time and ease the bleeding and inflammatory processes, edema, pain and ecchymosis that can affect patients. Thus, the maximum preservation of the integrity of the soft tissues adjacent to the prosthetic spaces and the preservation of the level of the alveolar bone collar should be sought to achieve minimization of surgical trauma.

Copy Right, IJAR, 2019,. All rights reserved.

Introduction:-

In atraumatic dental surgery, there are several studies with meta-analysis and decision analysis that account for almost 27.0% of all studies [1]. This selection of data was due to the significant increase of the quantitative synthesis methods in the dental literature from the beginning of the 21st century. Most of the selected studies were developed in the USA, the Netherlands and the United Kingdom [2]. These three countries and 15 journals accounted for almost 50.0% of all publications. The other papers were published in 61 other journals and originated in 32 other countries, including Brazil [3].

Corresponding Author:-Amália Rossi Dourado.

Address:-University Center North Paulista (Unorp) Dental School - São José do Rio Preto – SP, Brazil.

In addition, each of these three methods provides a quantitative summary of available evidence and reveals information gaps [2]. In summary, in the meta-analysis the uncertainty is about the conclusions obtained from a set of studies on minimally traumatic surgery. For decision analysis, uncertainty lies in clinical decision making for a patient or a group of similar patients. Therefore, the studies were classified in the following areas: periodontics (n = 80); cariology (n = 52); implantology (n = 40); endodontics (n = 31); orthodontics (n = 32); oral pathology (n = 26); buccomaxillofacial surgery (n = 28); prosthesis (n = 25) and others (n = 24) [1-5].

Dental transplantation appears as an alternative treatment to all social strata, being called as a biological prosthesis [6]. Thus, the transfer of a natural tooth from its alveolus to another site are related to extensive caries, root resorption, periodontal disease, coronoradicular fracture, agenesis to the aplasia of teeth. The technique must be atraumatic for better prognosis of the tooth to be transplanted, since the periodontal ligament should not be manipulated, because it is necessary to repair the periodontal tissues [6].

In addition, with the increasing modernization of implantology, we have the immediate implants as the procedure that is most likely to succeed among the rehabilitating treatments of the oral cavity, using implants osseointegráveis [7]. Immediate implants are those implanted just after the extraction of roots or compromised teeth, using the remaining alveolus to implant the implant, minimizing trauma and optimizing the treatment [7,8].

Among the several advantages that immediate implants provide, there is a good acceptance of the patient, a decrease in the number of surgical interventions, and the limitation of resorption of the residual alveolar bone. Added to this is the possibility of installing a provisional tooth in acrylic or photopolymerizable resin, fixed on the newly installed implant, further reducing bone loss and preserving the gingival contour of the region, returning aesthetics, smile and reintegration Social. Thus, this procedure is called "immediate esthetics" on the immediate implant. However, for results with a good critical level of significance, the implant should have a large part of the surface of its turns anchored in healthy and natural bone [6-9].

In addition, a significant and useful procedure, directly associated with immediate implants, is the technique known as root burial, which allows a proliferation of inserted gingiva (enough to cover a few times total of the alveolus after the implant of the immediate implant, without the need. However, it is not a technique widely used by some specialists, although it is easily executable and can provide great biological and aesthetic benefits [9,10].

Therefore, the present study aimed to demonstrate through the literature review the importance of improving the techniques of atraumatic surgeries in dentistry.

Methods:-

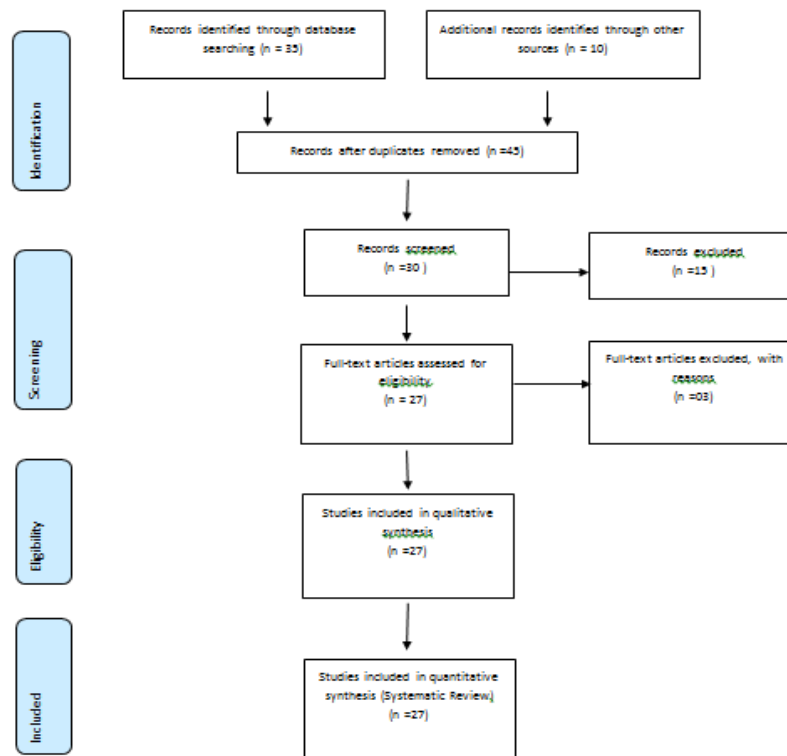
Study design

Following the criteria of literary search with the use of the Mesh Terms that were cited in the item below on "Search strategies", a total of 45 papers that were submitted to the eligibility analysis were collated and, after that, 27 studies were selected.

Search Strategy and Sources of Information

In general, as an example, the search strategy in MEDLINE / Pubmed, Web Of Science, ScienceDirect Journals (Elsevier), Scopus (Elsevier), OneFile (Gale) followed the following steps: - search for mesh terms: Cardiovascular diseases. Exodontia. Dental treatments. Prevention, use of the booleanos "and" between mesh terms and "or" among historical findings.

Flow Chart



Literature review

Exodontia indiscriminately, without the objective of immediate or late rehabilitation of the new prosthetic space, has long ceased to make sense, since the serious biological and social consequences generated by dental losses without adequate rehabilitation are widely known [1]. As a result of the enormous advance and diffusion of the modern implantology and the level of safety of the treatment provided by it, besides the correct techniques of making conventional prostheses relatively safe if planned correctly, the patient can have a suitable rehabilitation with several techniques [1].

If the maintenance of the original tissue contours is respected, the chances of achieving good aesthetic levels and acceptable functional frameworks increase considerably [1,2]. Such care is even more important and critical when the surgical procedure is performed in the anterior regions of the mouth. The preservation of interproximal bone levels is essential for maintaining the vertical level of the interdental papillae, avoiding dark areas and spaces between the natural and artificial teeth, which may impair the aesthetic result that can produce real satisfaction in the patient [2].

Likewise, the preservation of bone and gingival integrity can drastically reduce the volumes of medications administered in the postoperative period and facilitate the creation of adequate profiles and contours for gingival conditioning, even if procedures and techniques of conventional prostheses or immediate implants with immediate esthetics, are used for the rehabilitation of the case [2,3].

Thus, since the most primordial extraction techniques have been created and developed, several attempts have been made to minimize the effort of the professional, shorten the surgical time and ease the bleeding and inflammatory processes, edema, pain, and ecchymosis that can affect patients, in the trans and postoperative periods. Thus, one should seek the maximum preservation of the integrity of the soft tissues adjacent to the prosthetic spaces; preservation of the level of the alveolar bone [4-7].

In addition, atraumatic restorative treatment (ART) was developed by Frencken in Africa in order to control the evolution of caries [8-11]. The main functions of ART are preservation of dental structure with minimal operative

intervention, reduction of endodontic treatment or exodontia, and reduction of discomfort to the patient due to the lack of local anesthesia [12].

Authors compared the psychological behavior of children when using ART in relation to conventional treatment [13]. Heart rates were monitored throughout the procedures and the researchers concluded that manual instruments in atraumatic treatments caused less discomfort and anxiety than conventional rotary instruments. The ART can act as a preparatory treatment for the restorations, as it can eliminate the cariogenic microbiota within 48 h [14-18].

Still, glass ionomer cements (GIC) are widely used in dentistry because of their cariostatic effect, because of the release of fluoride in the superficial layers of the restorations [19,20]. Yet, in addition to the release of fluoride, the GIC are able to incorporate it again from toothpastes. However, the limitations on the use of GIC are related to its physical properties and aesthetic limitations [21]. The GIC present low cohesive resistance and wear, limiting the use for one-face restorations, besides suffering syneresis and imbibition [22].

Discussion:-

Based on the histological concept in which living tissues are formed by cells joined by fine elastic tissue and with nerve fibrils, capillaries, lymphatic and blood vessels [1,2]. The rupture of these cells by surgical trauma leads to the release of enzymes that delay healing. For this reason, surgical trauma should be minimized. The prevention of trauma is done through good planning of the surgery, work together, good lighting, strength control, knowledge of the topographic anatomy, control of movements and gestures, search for a point of support to reduce tremor and decrease in surgery time [3].

The basic rules that govern the doctrine of the atraumatic surgical technique are a tensionless surgeon, minimal and precise movements, dissecting only the indispensable, reducing tissue exposure to a minimum, gentle manipulation, use of correct instruments and techniques, use of embedded compresses in warm physiological solution [23].

As evidence, atraumatic exodontia techniques have several advantages over conventional techniques currently performed, especially with regard to maintaining the integrity of the alveolar bone and inserted gingiva. They consist of controlled techniques, with a high level of predictability [24,25].

In addition to this, atraumatic restorative treatment (ART) provides a glimpse of various minimally traumatic treatment options, depending on factors such as aesthetics, tooth function, patient expectations, cost of restoration and optimization of surgical techniques [26,27]. Thus, several authors have highlighted the advantages of ART, such as greater preservation of dental structure, curative and preventive technique in a single procedure, preservation of internal dentine, reduction of trauma, reduced risk of pain, paucity use of anesthesia, reduction of anxiety of patients, greater acceptance of adults and children, lower cost, speed of execution, possibility of correction of inadequate technique, good clinical performance in one-sided restorations, possibility of execution in social spaces such as schools, daycare centers or home care [10-15].

Conclusion:-

It is concluded that there are several attempts to minimize the effort of the professional, reduce the surgical time and ease the bleeding and inflammatory processes, edema, pain and ecchymosis that can affect patients. Thus, the maximum preservation of the integrity of the soft tissues adjacent to the prosthetic spaces and the preservation of the level of the alveolar bone collar should be sought to achieve minimization of surgical trauma.

Conflict of interests

There is no conflict of interest between authors.

References:-

1. Oh S, Kim S, Lo HS, Choi JY, Kim HJ, Ryu GJ, Kim SY, Choi KK, Kim DS, Jang JH. Virtual Simulation of Autotransplantation Using 3-dimensional Printing Prototyping Model and Computer-assisted Design Program. J Endod. 2018 Dec;44(12):1883-1888.
2. Krug R, Connert T, Soliman S, Syfrig B, Dietrich T, Krastl G. Surgical extrusion with an atraumatic extraction system: A clinical study. J Prosthet Dent. 2018 Jun 28. pii: S0022-3913(18)30116-1.

3. Amorim RE, Leal SC, Frencken JE. Survival of atraumatic restorative treatment (ART) sealants and restorations: a meta-analysis. Clin Oral Invest, 2011.
4. Barreto VC. Avaliação das restaurações atraumáticas em pré-escolares. Dissertação (mestrado)-Universidade Federal do Rio Grande do Sul. Faculdade de odontologia. Porto Alegre, 2007.
5. Brasil. Ministério da saúde / Conselho Nacional de Saúde. Documento base da III Conferência Nacional de Saúde Bucal: acesso e qualidade, superando a exclusão social. Brasília, 2004.
6. Cardoso AC. O Passo-a-Passo da Prótese Sobre Implante. Ed. Santos, 1ª ed, 2005.
7. Carvalho PS. Gerenciando os Riscos e Complicações em Implantodontia. Ed. Santos. São Paulo, 2007.
8. Carvalho LS. Tratamento restaurador atraumático em cavidades atípicas. Revista Gaúcha de Odontologia. Porto Alegre, v.57, n.3, 357-362, 2009.
9. Coatoam GW, Mariotti A. Immediate placement of anatomically shaped dental implants. J Oral Implantol; 26:170-176, 2000.
10. Colares V, Franca C, Amorin FHA. O tratamento restaurador atraumático nas dentições decídua e permanente. Revista Portuguesa de Estomatologia, Medicina Dentária e Cirurgia Maxilofacial. V. 50, n.1, 35-41, 2009.
11. Cooper LF, Rahman A, Moriarty J. Immediate mandibular rehabilitation with endosseous implants: simultaneous extraction, implant placement, and loading. Int J Oral Maxillofac Implants;17:517-525, 2002.
12. Covani V, Crespi R, Cornelini R, Barone A. Immediate implants supporting single-crown restoration: a 4 year prospective study. J Periodontol; 75:982-988, 2004.
13. Foschetti JHM. Tratamento restaurador atraumático associado a medidas preventivas na saúde pública brasileira. Trabalho de conclusão de curso (Especialização) – Universidade Federal de Minas Gerais, 2010.
14. Frencken JE, Holmgren CJ. Tratamento restaurador atraumático para a cárie dentária. São Paulo. Santos Editora, 2001.
15. Gomes AC. Tratamento restaurador atraumático como alternativa de tratamento em bebês portadores de fissura, relato de caso clínico. Revista Odontológica de Araçatuba, v.24, n.2, 52-55, 2003.
16. Groisman M, Frossard WM, Ferreira HM, DE Menezes FLM, Touati B. Single-tooth implants in the maxillary incisor region with immediate provisionalization: 2-year prospective study. Pract Proced Aesthet Dent;15:115-122, 2003.
17. Irinakakis T. Rationale for socket preservation after extraction of a single-rooted tooth when planning for future implant placement. J Can Dent Assoc;72:917-922, 2007.
18. Jahangiri L, Devlin H, Ting K, Nishimura I. Current perspectives in residual ridge remodeling and its clinical implications: a review. J Prosthet Dent; 80:224-37, 1998.
19. Kan JY, Rungcharassaeng K, Lozada J. Immediate placement and provisionalization of maxillary anterior single implants: 1-year prospective study. Int J Oral Maxillofac Implants;18:31-39, 2003.
20. Lazzara RJ. Immediate implant placement into extraction sites: Surgical and restorative advantages. Int J Perio Rest Dent; 9:332-343, 1989.
21. Marcus SE, Drury TF, Brown LJ, Zion GR. Tooth retention and tooth loss in the permanent dentition of adults: United States. J Dent Res 1996; 75:684-695, 1991.
22. Mccall RA, Rosenfeld AL. Influence of residual ridge resorption patterns on implant fixture placement and tooth position. 1. Int J Periodontics Restorative Dent ;11:8-23, 1991.
23. Saunders WB. Osseointegration. Dorland's illustrated medical dictionary, 29th ed. Philadelphia; 1285, 2000.
24. Tischler M, Misch C. Extraction site bone grafting in general dentistry. Review of applications and principles. Dent Today; 23:108-113, 2004.
25. Vescovi P, Campisi G, Fusco V, Mergoni G, Manfredi M, Merigo. Surgery-triggered and non surgery-triggered bisphosphonate-related osteonecrosis of the jaws (BRONJ): a retrospective analysis of 567 cases in an Italian multicenter study. Oral Oncol 47:191-194, 2011.
26. Wagenberg BD, Ginsburg TR. Immediate implant placement on removal of the natural tooth: retrospective analysis of 1,081 implants. Compend Contin Educ Dent; 2001, 22:399-408, 2001.
27. Wheeler SL, Vogel RE, Casellini R. Tissue preservation and maintenance of optimum esthetics: a clinical report. Int J Oral Maxillofac Implants; 2000,15:265-271.