



Journal homepage: <http://www.journalijar.com>

INTERNATIONAL JOURNAL
OF ADVANCED RESEARCH

ISSN NO. 2320-5407

MANAGEMENT & OUTCOME OF HYPOSPADIAS IN GEZIRA NATIONAL CENTER FOR PEDIATRICS SURGERY

**A thesis submitted to
SUDAN MEDICAL SPECIALIZATION BOARD**

In partial fulfillment of the requirements

For the award of the degree of

CLINICAL M.D. IN GENERAL SURGERY

BY

DR ASHRAF M. A. GUMAA, MBBS

Under The Guidance of

Dr Faisal A. Nugud, MBBS, MD Surgery,

Asst. Professor of Pediatrics Surgery

FACULTY OF MEDICINE

UNIVERSITY OF GEZIRA

SUDAN. 2008-2009



INTRODUCTION:

The term hypospadias refers to the urethral meatus, which instead of being located at the tip of the penis is found somewhere along its ventral side. There are different degrees of severity of hypospadias. In the least severe cases the urethral opening is located just below the glans ; in the most severe cases the opening is found at the base of the penis close to the perineum.(1)

Hypospadias is one of the most common congenital malformations in males, and consequently there are a great many articles which discuss its correction by surgery as well as its physical etiology. (2)

In the best of my knowledge' there is hardly any data available in our country about this important issue.

The importance of hypospadias arise not only from it being a common problem ' but also as it affects one of the most personal parts of the male anatomy. So it has its psychological impact as well as its physical & functional impacts. (1)

This anomaly needs a great concern based on scientific statistics for accurate assessment of the problem, and accurate assessment of our management of this problem.

DEFINITION:

Etymologically, the term hypospadias is derived from the Greek word *hupo*, meaning 'under' and, *spaôa* 'fissure' or 'crack'. Hypospadias is an abnormality of anterior urethral and penile development (2). Classically there is an association of three anatomic and developmental anomalies of the penis:

- ❖ 1/ an abnormal ventral opening of the urethral meatus, which may be located anywhere from the ventral aspect of the glans penis to the perineum.
- ❖ 2/ an abnormal ventral curvature of the penis (chordee).
- ❖ 3/ an abnormal distribution of foreskin, with a "hood" present dorsally and deficient foreskin ventrally. (3)

The second and third of these typical characteristics are not present in all cases.

HISTORICAL BACKGROUND:

The earliest medical text describing hypospadias dates back to the second century AD and was the work of Galen [130-199 A.D.], the first to use the term and more particularly emphasised the major significance of chordee. (4)

The next major medical text referring to hypospadias was written by Ambrose Pard [1510-1590] (5). He also described chordee and gave extensive descriptions of hermaphroditic conditions and their overlap with hypospadias.

The third great surgical writer was Pierre Dionis [d.1718] (6), the founder of modern French surgical education; sixteenth and seventeenth century French surgeon, who wrote a major textbook on surgery, including a reference to hypospadias.

Chordee deformity:

After Galen and a brief reference by Oribasus [325-403A.D.], there was almost no reference to chordee for 1,500 years. Surgeons seemed to concentrate their efforts on the position of the orifice. However, the other reference is to the attitude of the Roman Catholic Church to the deformity. A manuscript has been discovered in the University of Rome (7) of an action by a Maltese woman, Mathia, in 1542 for annulment of marriage on account of a deformity (hypospadias) of her husband.

Not only did surgeons largely ignore the technical challenge of chordee for 1,800 years, they were also slow to recognise its causes. However in 1842, Mettauer (8) in the United States was the first to study the chordee, and significantly recognised that skin tethering was the principle cause. He advocated a "succession of subcutaneous incisions. Despite this, the advice was ignored, and indeed, the ignorance was formalised by Etienne Bouisson in 1860 (9), who first emphasised a "central fibrous band" on the corpora as the cause. That misconception continued for more than 100 years, even in Denis Browne's concept. The truth of Mettauer's concept of 1842 was not rediscovered until 1967, when D. R. Smith of the United States (10) restressed the significance of skin and subcutaneous shortening and tethering. This concept was then used in the operative procedures of Allen and Spence in 1968 (11) and Lowell King in 1970 (12). The fact that these are the principal structures of chordee and they are proximal to the orifice was realised by Mettauer 150 years ago! This late recognition of the essential factors of chordee also ignored the pioneer work of Duplay in 1874 (13) and 1880 (14, 15), who stressed complete chordee release before urethroplasty. Lauenstein in 1892 (16), added skin from the pubis to the penis to make up for the deficiency, and of Edmunds in 1913 (17), who moved preputial skin to the shaft. Better known are the procedures of Blair et al. (1933) (18), Blair [1938] (19), and Byers [1955] (20), who extended the use of preputial flaps to make up for shaft deficiency, now a standard technique in many repairs. Other surgeons had tried other means: Beck, in 1917 (21), had passed the glans through a buttonhole of prepuce to get skin to the ventral surface (a procedure developed later by Nesbitt in 1941) (22). Physick and also Pancoast in 1844 (23) used part of the dorsal corpora (another procedure advocated by Nesbitt 100 years later). In 1936 Young (24) popularised the concept of a "congenital short urethra", another erroneous concept, except in rare circumstances.

Urethral reconstruction:

The first "repair" was recorded by Antyl in the first century A.D (25) who recommended amputation beyond the orifice, also advocated by Paul of Aegina [625-690] (26), and this was the only method offered for 1,000 years except for two brief references to skin stretching. Galen stretched the skin over the orifice up to the glans, anchored it with tape, and cut off the excess. The next period, for almost another 1,000 years until the nineteenth century, might be described as the era of tunnelling and cannulation. A tunnel was made by trocar through the penis and the channel kept open by a cannula or bougies until it epithelialised. Abulcasis [936-1013] (27), an Arab physician, used lead bougies, Guy de Chauliac [1363] (28) used a silver cannula, others being.

Lusitanus [1511-1568] (29), a Portuguese, Dionis [1707] (6), who used a lead cannula, Morgagni [1761] (30), Sir Astley Cooper [1815] (31), using a gum elastic catheter as did Dupuytren [1777-1835] (32) and Mettauer in 1842 (8). In 1836 Dieffenbach (33) denuded the edges of the urethral gutter and sutured them over a cannula, but it broke down.

Repairs blossomed from the middle of the nineteenth century and ushered in the modern era. All the current methods derive from innovative surgeons of this period.

Over 300 repairs have been described and all are based upon the use of three types of tissue: (1- penile and preputial skin; (2- scrotal skin; and (3- free grafts.

It will be convenient to take each of these modalities in turn.

1-Penile and preputial skin:

These tissues have been utilised in a number of ways, and at least six modern techniques have evolved: (1- tube in situ, with or without additional flaps; (2- buried skin; (3- pedicle tube grafts; (4- flip-flap grafts from proximal to the orifice; (5- urethral advancement; and (6- meatotomy, hemi-circumcision, meatal advancement and glanuloplasty (MAGPI).

1.1- Tube-in-situ, distal to the orifice:

Anger, in 1874 (34), first used longitudinal flaps on either side of the urethral groove by overlapping them as a double-breasted suit, but did not denude them. Not surprisingly, they broke down. In 1875 John Wood in London (35) also covered the urethral groove with skin by button-holing the prepuce and joining it to peno-scrotal skin. Again, no actual "tube" was constructed.

Simon Duplay, in France in 1874 (13), first actually tubularised the skin, although Thiersch had performed this procedure for epispadias in 1869. Duplay incised the skin on either side of the urethral groove, bringing the edges together as a tube (although not the orifice itself, which was closed later over a catheter). The outer skin was closed edge-to-edge over the tube.

There were many failures, but his first success came after a five-stage repeat. This basic tubularisation of skin distal to the orifice is still used by many surgeons.

In 1880 (14) Duplay described a second procedure that is remarkable in two respects. Firstly, he made the urethral strip much narrower and sutured it over a catheter, but not as a completely secure tube. In other words, it was a "buried strip", the forerunner of the Denis Browne technique 69 years later. Indeed, Duplay specifically commented on the capacity of the tissues to tubularise themselves: "Although the catheter is not actually covered entirely by skin. The next stage was to add extra skin to the area by transference of preputial skin, as an initial phase. In 1892 Lauenstein (16) added skin from the pubis; in 1899 Beck (38) added a peno-scrotal flap over the tube; in 1913 Edmunds (17) moved prepuce before tubularisation; in 1917 Beck (21) button-holed the glans through the prepuce to obtain extra skin; and in 1932 Ombr'odanne (39) did the same procedure and grafted the prepuce onto denuded areas lateral to the tube.

In the D.R.Smith two-stage repair he grafts preputial skin onto the shaft and glans as a first stage, to obtain thick viable skin for tubularisation in the second stage down to the tip, with a second stage of overlapping double-breasted, denuded flaps over the new urethral tube (36, 37). But Duplay, Edmunds, Ombr6danne, and Byars laid the foundation.

1.2-Buried skin:

The concept of a buried strip of skin that would subsequently complete its own tubularisation was popularised by Denis Browne in 1949 (40). Browne always acknowledged the idea to the Australian surgeon, Hamilton Russell, who in 1915 (41), after excising a urethral stricture, found that if the urethral ends were joined as a flat strip of mucosa and buried, the urethra re-formed. Browne was apparently unaware of the second operation of Duplay in 1880.

1.3-Pedicle skin grafts:

In the modern era there has been much enthusiasm for the use of pedicle tubes, generally derived from the prepuce, retaining their principal blood supply on the pedicle and swung ventrally to be anastomosed to the existing urethra.

One-stage repairs have been achieved, commencing with the work of Broadbent, Woolf, and Toksu [1961] (42), Des Prez, Persky, and Kiehn [1961] (43) (who first used the words "island flap"), and developed so expertly by Duckett (44).

In 1838 Liston (45) had closed a fistula from a preputial flap. In 1896 Van Hook (46) used a proximally-based pedicle tube of prepuce(46) ; in 1899 Rochet (47) swung a pedicle from scrotal skin based on blood supply just proximal to the meatus and tunnelled through the glans and penis; in 1900 Hamilton Russell (48) described a "stole" operation, a pedicle tube of penile and preputial skin; in 1901 (49) C. H. Mayo (50) made a distally based pedicle of prepuce; in 1917 Bevan (50) tunnelled a penile pedicle through the glans; in 1929 Rosenstein (51) used a

pedicle graft of bladder mucosa; and in 1940 Davis (52) employed a pedicle from dorsal pedicle skin.

1.4-Flipp-flap tube:

Based proximal to the meatus and swung distally Bouisson had used a proximal peno-scrotal flap swung distally in 1860 (9), but strangely, no one else employed a flip-flap technique until 1932 (Mathieu) (53). It was one of the few procedures not followed up in the nineteenth century. After Mathieu, it was later developed by Ross et al. [1959] (54) and Mustard6 [1965] (55).

1.5-Urethral advancement

Beck, in 1898 (38), was probably the first to mobilise the urethra and draw it distally along a trocar track. But like the flip-flap repair, urethral advancement was a late development, first by the British urologist Badenoch [1950] (56) for by-passing a stricture, and later by McGowan and Waterhouse [1964] (57).

1.6-MAGPI (meatal advancement and glanuloplasty) (58):

In 1874 Duplay (13) deepened the glanular groove and closed it over a catheter, and in 1898 Beck (38) mobilized the urethra for balanitic hypospadias and sutured it distally-procedures not dissimilar to the modern MAGPI repair.

2-Scrotal repairs:

As scrotal repairs are now rarely performed, the discussion will be brief. In 1860 Bouisson (9) utilised a peno-scrotal flap swung distally, but not tubularised. In 1870 Moutet (59) swung a scrotal flap over the urethral groove and covered its new surface with skin from the pubis, which sloughed. In London in 1875 Wood (35), being unaware of Duplay's work, button-holed the glans through the prepuce and then sutured the prepuce to a peno-scrotal flap. In 1891 Landerer (60) denuded long skin strips on either side of the urethral groove both proximal and distal to the meatus, then buried the penis back into the scrotum so that the denuded strips came together; as a second stage, the penis was released from the scrotum. The modern era was popularized by Cecil [1936] (61) at first by a three-stage technique.

3-Free grafts:

Free grafts have been popular in some countries over the last 30 years, but their use also dates from the last century. Nov'o Jossierand, the third of the great French surgeons of the last century (with Duplay and Ombr'odanne), in 1897 (62) utilised an autograft of penile and preputial skin wrapped around a catheter and tunnelled through the penis and glans along a trocar track introduced through a perineal urethrostomy. It strictured, as is the fate of many free grafts.

In 1937 McIndoe (63) designed a hollow trocar to introduce a Thiersch graft of penile and preputial skin around a gum elastic catheter. In 1941 Humby (54) employed a one-stage technique using a full-thickness prepuce graft, later developed by Devine and Horton in 1955 (64).

Other tissues have also been used. Saphenous vein was used by Tanton, Unger, and Becker in 1909 (65) and by Tuffier in 1910 (66), Cantas in 1911 (67), and Marion 1922(68). Fistulae and rejection of grafts resulted. Bladder mucosa was first used by Rosenstein in 1929 (51) as a pedicle graft and as a free graft by Memmelaar in 1947 (69) and Marshall and Spellman in 1955 (70). Schmieden employed ureter (from operation or autopsy) in 1909 (71) with failure; Lexer used appendix in 1911 (72); cadaveric urethra was said to be a success by Bourque in 1952 (73), as Pringle claimed for bullock,s urethra in 1904 (74). Even a dog's aorta was used by Legueu (75), but without success.

Perhaps no surgical concern in history has inspired such widespread and varied opinion with regard to management as has hypospadias. From the earliest recorded description of hypospadias to the present, several hundred surgical approaches and/or variations on a theme have been described. Over 300 different types of repairs have been described in the medical literature. Although most reports have been in the last60 years, most basic techniques were described over a century ago.

Modern anesthetic techniques, fine instrumentation, sutures, dressing materials, and antibiotics have improved clinical outcomes and have, in most cases, allowed surgical treatment with a single-stage repair within the first year of life on an outpatient basis.

CLASSIFICATION:

Many different classification systems with varying utility have been proposed through history (fig. 1), Anatomic classification of hypospadias recognizes the level of the meatus without taking into account curvature. A more recent classification was described. This classification indicates:

- (1- The site of urethral meatus (before and after chordee correction).
- (2- The prepuce (incomplete or complete).
- (3- The glans (cleft, incomplete cleft or flat).
- (4- The width of urethral plate.
- (5- The degree of penile rotation if present.
- (6- The presence of scrotal transposition.

Using the general classification, surgeons are able to conduct multi-centre studies to evaluate different techniques of repair. (76)

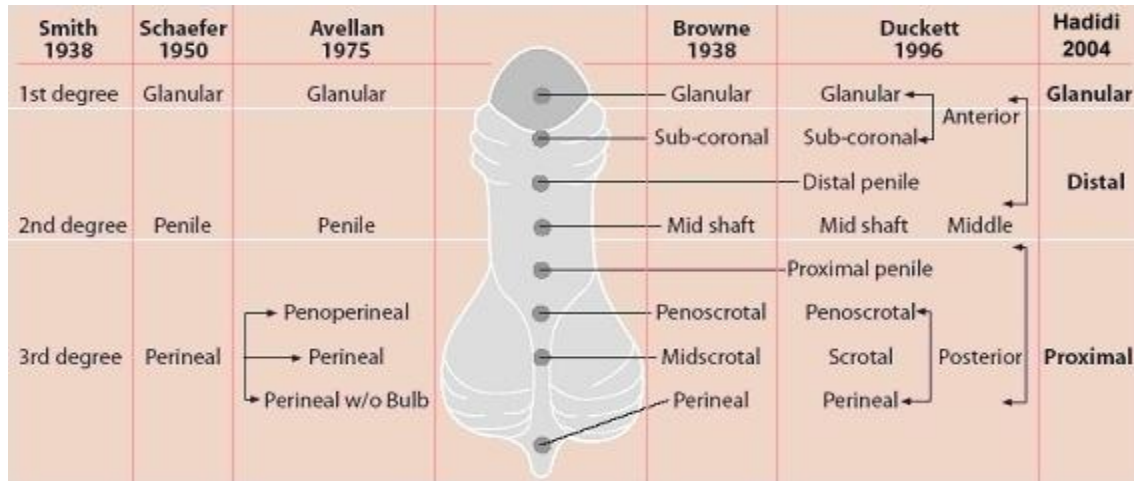


Fig. 1: Different classifications of hypospadias, according to location of meatus (from: Hypospadias Surgery; 2006; by Prof. Ahmed T Hadidi)

PENILE ANATOMY:

The penis is made up of three separate cylinders. The two paired cylinders called corpora cavernosa make up the majority of the bulk and the erectile functioning of the penis. These two cylinders split and anchored to the pelvis bone by a tough membrane. Each of these cylinders is encased in a very tough thick sheath called the tunica albuginea. The third cylinder of the penis is called the corpus spongiosum and it contains the urethra. The tissue around the erectile body is much thinner and actually this cylinder sits in a groove created by the other two cylinders. As this structure approaches the end of the penis it becomes swollen and is known as a glans or the head of the penis. As this layer gets closer to the body it expands to form the bulb. Covering all three of these cylinders is a thick tough membrane called Buck's fascia. Finally a final layer covers this area called Colles fascia or the superficial layer which is continuous with the abdominal wall and makes these whole supporting structures of the penis very tough allowing it to take quite a bit of force and trauma. The skin covering the penis is extremely mobile and expanded. This is necessary to allow an erection to take place; it is controlled by the hormonal system. The head of the penis is covered by a foreskin. This is a double layer of penile skin that is very freely moveable. The body of the penis is anchored to the pubic bone and a thickening of the rectus muscle anchors the penis. (77)

BLOOD SUPPLY:

Two arterial systems contribute to the blood supply of the penis. The deeper system responsible for supplying the erectile tissues arises from the internal Pudendal arteries (a. pudendae internae), or sometimes from an accessory internal artery. Four branches, either

collateral or terminal, should be considered: the artery to the bulb of the penis, the urethral artery, the deep artery of the penis and the dorsal artery of the penis.

Variations are frequently present in the origin, distribution and symmetry of these arteries, but on the whole the blood supply is organized into three planes, inferior or ventral, middle or deep and superior or dorsal. These three planes are complementary: when the blood supply to any one of them is occluded, at whatever level this may be, the blood supply is supplemented by the plane immediately above it. Arteriogram should be interpreted with caution because anatomical variations may at first sight be taken for pathological change.

The superficial system, supplying the tissues around the erectile organs, arises from the lateral inferior pudendal arteries. Three types of supply have been described' according to whether the right and left arteries have a symmetrical distribution or whether the arterial network arises in large part or totally from one side. (78).

INNERVATION OF THE PENIS:

The dorsal nerve of the penis (n. dorsalis penis) is the deepest division of the pudendal nerve ' it accompanies the internal pudendal artery along the ramus of the ischium, it then runs forward along the margin of the inferior ramus of the pubis, between the superior and inferior layers of the fascia of the urogenital diaphragm . piercing the inferior layer gives a branch to corpus cavernosum penis , and pass forward , in accompany with the dorsal artery of the penis, between the layers of the suspensory ligament , on to the dorsum of the penis' and ends on the glans penis . In female this nerve is very small, and supplies the clitoris (n. dorsalis clitoridis). (79)

The nervous system of the penis is involved with both the creation and maintenance of an erection as well as an ejaculation. The most numerous sensory nerves are located on the head, or glans, of the penis. To achieve an erection it takes multiple input from numerous areas of both brain and the spinal cord. The first part of the penile erection is controlled by the brain, known as psychogenic erection. These occurs under any type of mental or erotic stimulation. Penile erection can also be caused by friction of the skin of the penis alone' this is known as reflexogenic erection, which commonly occurs among men who have had damage to the spinal cord and who are unable to get an erection unless physically stimulated. (77)

PREPUTIAL ANATOMY:

At approximately eight weeks of gestation, symmetrical low ridges arise just proximal to sulcus near to the meatus and progress dorsally until they form a fold entirely around the glans, except in the midline on the ventrum where they are blocked by incompletely developed urethra.

This preputial fold rolls over the base of the glans to leave a groove between it, the coronal sulcus and the nascent prepuse (79). Simmultaneously, the glanular lamella, an ingrowth

of epithelium many cells thick, actively proliferates in the groove to form a shelf between the preputial fold and the glans (80, 81).

Since this epithelial tissue generates most actively at the apex (proximal end) of the groove its proliferation carries the ridge of the preputial fold distally. The tissues of the most proximal portion of the epithelial glanular lamella is not as well differentiated as the distally, showing that the prepuce is not formed by fusion' but by being pushed ahead by active proliferation.

The mesenchyme between the layers of prepuce proliferates, thus extending its tip even after it reaches the summit of the glans.

By 4 months the single epithelial layer between the prepuce and the glans begins to split into 2 layers beginning distally and continuing proximally until birth (82).

Thus three processes form the prepuce: 1) initially, the skin of the shaft is folded over the base of the glans at the coronal sulcus to create a groove. 2) a ring of epithelial cells form a shelf and proliferates in the groove to carry the prepuce progressively distally until it reaches the tip of the glans, helped by mesenchymal growth within the prepuce, and 3) beginning distally, the epithelial layer between the prepuce and the glans separates into 2 layers.

DEVELOPMENT OF THE PENIS:

Normal sexual determination and differentiation: a recap.

The differentiation of the gonad (which at the beginning of the process is the same in both sexes) into a testicle or an ovary is a genetic process known as sexual determination (83). The factors responsible for sexual determination are partly chromosomal and partly at the level of the gene (84). At the moment of conception the sex of the embryo is determined by the combination of sexual chromosomes: in males, the chromosomal sex is most often 46 XY, in females 46 XX. In addition, there is a specific gene sequence responsible for testicular development. It appears that the gene SRY, carried by the Y chromosome, is the principal initiator of the cascade of genetic interactions which determine the development of the undifferentiated gonad into a testicle. As for the term gonadic sex, this is used to describe the status of the gonads: whether they comprise testicular tissue, or ovarian tissue.

Following the gonad's determination as a testicle, masculine sexual differentiation is dependent on the production and action of androgens - hormones of gonadic origin (83).

Until the sixth week, whatever the sex of the embryo, the internal genital passages are represented by two pairs of genital canals: the Wolffian and Müllerian ducts. These ducts take one or other direction according to the hormones produced by the gonads (84). In male embryos (46 XY), the internal male phenotype is achieved thanks to the secretion and action of two

androgens. One is the anti-Müllerian hormone (AMH) which permits a regression of the Müllerian ducts. The other is testosterone, which contributes to the maintenance and development of the Wolferian ducts (epididymis, vas deferens, seminal vesicles and ejaculatory ducts).

The constitution of the external male phenotype sex (external genital organs and genito-urinary sinus) needs the conversion of testosterone into a more powerful hormonal derivative - dihydrotestosterone or DHT - which happens with the help of a specific enzyme, type 25-alpha-reductase (83).

To recap, the external genital structures develop in both sexes (46 XY or 46 XX), from the same original tissues. In the state known as undifferentiated (84), these tissues are identical and comprise a pair of labio-scrotal folds, a pair of genito-urinary folds and a genital tubercle.

Normally, in an individual of male genetic sex (46 XY), between the 8th and 14th week the genital outlines change under the influence of DHT which fixes itself on special cell receptors (85). On one side the pads of genital tissue knit together to form the scrotum. On the other, the genital tubercle elongates to form the shaft and glans of the penis. As the penis grows, the genital folds are drawn forward, then knit together under the penis. During this process of knitting together the genito-urinary membrane forms the urethral canal, which, in fusing, forms a tube the whole length of the penis, comprising the penile urethra.

This process continues forward and draws nearer the glans: this is the glanular urethra. The extremity of the glans, containing the most distal part of the urethra, is formed through an invagination of epithelial cells hollowing out the centre of the glans. Finally, the urethra opens at the extremity (or apex) of the glans in a vertically oriented slit. The formation of a complete prepuce (foreskin), with its final cutaneous fold surrounding the glans on its ventro-dorsal part, signals the successful end of this process.

In the absence of androgens and DHT, the external sex organs differentiate in the female way (85). The genital tubercle inclines towards the base to form the clitoris, the genito-urinary folds remain separated to form the small lips (labia minora) of the vulva, and the labio-scrotal folds do not knit together and consequently form the large lips (labia majora).

HYPOSPADIAS EMBRIOGENESIS:

Different manifestations of hypospadias can appear, depending on the moment when, during the embryonic development of the phenotypic masculine sex, the different fusion processes which form the urethra are disrupted (85). According to Frisé, the severity of hypospadias can be seen as a continuum. The earlier the fusion process is interrupted, the hypospadias will be classified as 'severe' or 'complex'. Conversely, 'simple' cases of hypospadias will arise from failures during the terminal phases of urethral development.

The degree of hypospadias depends on the location and the length of the urethral orifice (85). The most severe cases of hypospadias arise when the pads of genital tissue do not fuse at all. The urethra opens in the perineum and the hypospadias is called 'perineal'. In the case where the genital pads fuse only partially, and the urethral orifice opens between the base of the penis and the root of the scrotum, the hypospadias is classified as 'peno-scrotal'.

An incomplete fusion of the genital folds produces an opening of the urethra at a point along the ventral side of the penis, which is 'penile' hypospadias.

Finally, when the epithelial invagination of the glans is defective, the urethral opening is located under the glans, and this is known as 'glanular' hypospadias.

Theories of Hypospadias embryogenesis:

In the male fetus, at the 50 mm stage (approximately 11th week of development) (86), when the interstitial (Leydig) cells of the testis increase in number, size, and function, the urethral folds begin to fuse ventrally in the midline to form the urethra (87). Via a similar process, the proximal portion of the glanular urethra forms shortly thereafter and is thus derived from the urethral plate (endodermal origin). The distal portion of the glanular urethra is formed by lamellar ingrowth of the surface epithelium (ectodermal origin), which grows toward the distal extent of the urethral plate, becoming stratified squamous epithelium at the completion of development. This classic "ectodermal ingrowth theory" for development of the distal glanular urethra has recently been challenged by the "endodermal differentiation theory" (88).

The endodermal differentiation theory described by Kurzrock and colleagues is based on the results of immunohistochemical staining for different cytokeratins in 36 serially sectioned human fetal phallic specimens of gestational ages 5 to 22 weeks. According to these investigators the urethral plate extends to the tip of the phallus and maintains patency and continuity throughout urethral development; therefore, the epithelium of the entire urethra originates from the urogenital sinus (endoderm). Sections of the distal glanular urethra showed no evidence of ectodermal tissue ingrowth. Kurzrock and colleagues [1999] provided further support for the endodermal differentiation theory using tissue recombinant grafting techniques, suggesting that under the correct cellular signaling conditions endodermally derived epithelium (urethral plate) differentiates into the stratified squamous epithelial phenotype present in the fully developed distal glanular urethra. (88)

With regard to preputial development, Hunter (88) noted that at the 40 mm stage preputial tissue did not uniformly surround the phallus in the form of a circle; rather, it was present in an oblique orientation, radiating out on either side of the phallus from the point of the urethral opening, with the urethral opening placed "well back" on the ventral surface of the phallus at this stage of development. According to Hunter, at this early stage of development the preputial tissue appears as a "hood" dorsally and gradually becomes less well marked ventrally

as it approaches the urethral meatus. Complete preputial covering of the glans occurs at approximately the 130 mm stage (20th week) of development. (86)

NEUROVASCULAR ANATOMY:

Using immunohistochemical localization and three-dimensional computer reconstructive techniques, Baskin and colleagues (91) studied neural and vascular anatomic features of 10 normal and 1 hypospadiac fetal penis. They showed that the nerves that innervate the penis originate proximally as two well-defined bundles under the pubic rami superior and slightly lateral to the urethra. This was similar for both the hypospadiac and normal fetal penises compared. As the two crural bodies converge into the corpora cavernosa, the nerves diverge, spreading around the corpora cavernosa to the junction with the urethral spongiosum. Nervous tissue fans out in this manner from the 11 and 1 o'clock positions all along the penis and does not remain confined to two well-defined bundles. The absence of neuronal structures at the 12 o'clock position along the entire shaft of the penis was also noted (91).

On further comparison of normal and hypospadiac fetal penile anatomy with the use of immunostaining techniques, Baskin and colleagues (1998) noted that the most striking difference detected was that of relative vascularity. There was extensive vascularity of the distal urethral spongiosum and glans in the hypospadiac compared with the normal penises examined. Baskin and colleagues proposed implications for hypospadias repair in that incision of these sites (i.e., distal urethral spongiosum and glans), which are rich in large endothelial-lined sinuses, results in release of epithelial growth factors that encourage tissue repair without significant scar or stricture formation.

ASSOCIATED ANOMALIES:

Hypospadias appears most often in an isolated manner (84). However, it is known that other genital malformations or anomalies, some more serious than others, sometimes accompany this condition.

Genetic Associations:

Aarskog (92) was one of the first to perform cytogenetic analyses in patients with hypospadias. He found a normal karyotype in all cases of glanular hypospadias and noted that abnormal karyotypes tended to occur among patients with the most severe degrees of hypospadias, especially among those with associated cryptorchidism. Yamaguchi and colleagues (93) studied 110 consecutive patients who had cryptorchidism and/or hypospadias. Seven (6.4%) of these patients were found to have chromosomal anomalies. The incidence of chromosomal anomalies in patients with cryptorchidism only was 4.8% (4/83), in patients with hypospadias only it was 5.6% (1/18), and in concomitant cases the incidence was 22.2% (2/9).

Cryptorchidism and Inguinal Hernia:

Associated abnormalities include cryptorchidism (8% to 9%) and inguinal hernia and/or hydrocele (9% to 16%) (22, 23, 24). These overall rates for males with hypospadias increase significantly in those with more proximal defects. The concomitant occurrence of hypospadias and cryptorchidism even in the setting of nonambiguous genitalia should alert the urologist to evaluate for the possible presence of an intersex state.

Syndromes:

According to the Smith's text *Recognizable Patterns of Human Malformation*, there are approximately 49 recognized syndromes in which hypospadias is either a "frequent" (15) or an "occasional" (34) associated finding (97). Of these 49 syndromes in which hypospadias is an associated finding, 38 (78%) also have associated micropenis, cryptorchidism, and/or a scrotal abnormality. This would seem to further support an endocrinopathic etiology for hypospadias.

Intersex States.

Based on his experiments in the rabbit fetus, Jost regarded all hypospadias as a form of male pseudohermaphroditism (98). A high index of suspicion for an intersex state should accompany presumed males with any degree of hypospadias and cryptorchidism (99,100,101,102). In 1976, Rajfer and Walsh reported the incidence of intersexuality in children with cryptorchidism, hypospadias, and otherwise nonambiguous genitalia to be 27%. (99)

In a detailed evaluation of hypospadias level and exact status of concomitant cryptorchidism, Kaefer and colleagues [1999] evaluated 79 presumed males presenting with one or both undescended testes and hypospadias. Intersex conditions were identified with almost equal frequency in the 44 cases (30%) of unilateral and 35 (32%) of bilateral cryptorchidism. In the group with unilateral cryptorchid testis, patients with a nonpalpable testis were at least threefold more likely to have an intersex condition than those with a palpable undescended testis (50% versus 15%). In the bilateral cryptorchid group, patients with one or more nonpalpable testes were also almost three times as likely to have an intersex condition compared with those who had bilateral palpable undescended gonads (47% versus 16%). Meatal position was graded as anterior in 33% of cases, middle in 25%, and posterior in 41%, with the more posterior location conferring a significantly greater likelihood of intersexuality (anterior, 2 of 26 cases; middle, 1 of 20; posterior, 21 of 33) (103).

More rarely, the penis may be combined with the scrotum ; or the position of the scrotum may change place with the root of the penis (peno-scrotal transposition).

Hypospadias is most severe when accompanied by these genital anomalies. (104)

ETIOLOGICAL HYPOTHESIS OF HYPOSPADIAS:

In simple terms, hypospadias is thought to be caused by incomplete closure of tissue on the undersurface of the penis, known as the urethral folds, which form the urethra (105) and more recent reviews (106,107) suggest a multifactorial etiology of hypospadias, which may include one or more of the following: an environmental or other endocrine disruptor; a native endocrinologic, enzymatic, or local tissue abnormality; and a manifestation of arrested development.

(1) Hereditary factors:

The existence of a hereditary causal factor for hypospadias has been demonstrated by certain studies which show the presence of several affected people in the same family. In one relatively old study (108), the authors concluded that if the father of a family has hypospadias, the probability that one of his sons will carry it is increased to around 8 percent, and the likelihood that one of his brothers will also be affected reaches 12 percent. Moreover, the risk for the next generation increases to around 26 percent if two members of the same family are carriers of hypospadias (e.g., when the father and one of the sons are affected).

According to a more recent study concerning the heredity of hypospadias (109), almost 7 percent of the families interviewed - in which a child presented one or other form of hypospadias at birth - reported knowing of the existence of another affected family member.

(2) Genetic factors:

The pathogenesis of hypospadias equally comprises factors of a genetic order. Earlier molecular analyses have revealed that there might be a mutations of the gene responsible for the enzyme activity of 5-alpha-reductase, leading to disturbance of the production of dihydrotestosterone which is necessary for development of the male genito-urinary tract (110).

Recent genetic studies carried out on humans and animals (111), have shown that alterations affecting certain genes - such as gene HOXA13 - are susceptible to change the response of the receptor to androgens (located at the level of the genital tubercule) and to lead to the phenotypic expression of hypospadias.

(3) Endocrinal factors:

More specifically, the defects of the hypospadias anomaly may result from 1) abnormal androgen production by the fetal testis, 2) limited androgen sensitivity in the target tissues of the developing external genitalia, and/or 3) premature cessation of androgenic stimulation secondary to premature involution of Leydig cells of the fetal testis. (112)

Other possible etiologic factors include insufficient synthesis of testosterone or dihydrotestosterone or both (presumably from defective or deficient 5 α -reductase enzyme activity) and/or defects in androgen receptor quality or quantity or both. Several entities in the

spectrum of androgen resistance (androgen insensitivity syndromes) have been elucidated at the clinical and molecular level. (113)

Nowadays, it is widely accepted that androgens play a crucial role in the development of the male external genital organs. More precisely, recent anatomical studies support the hypothesis that androgens are essential for the formation of the ventral portion of the human urethra. This type of research supports even more strongly the possibility that hypospadias can appear following deficiencies during the biosynthesis of 5α -reductase or via a defect in the androgen receptors. (114)

It is notable also that other hormone deficiencies, such as an excessive production of the anti-Müllerian hormone (AMH) may equally play a role in the etiology of hypospadias by interfering with the biosynthesis of testosterone. (115)

Several endocrinopathic/enzymatic factors have been identified in humans and in animal models of hypospadias. It has been observed that genotypic male infants born with a severe deficiency of 3β -hydroxysteroid dehydrogenase enzyme (a microsomal enzyme essential in biosynthesis of almost every biologically active steroid hormone) have incomplete masculine development and hypospadias. (116)

A 5-fold increased risk of hypospadias appears to exist in males born through in vitro fertilization (IVF) when compared with a control group. This may reflect maternal exposure to progesterone, which is commonly administered in IVF protocols. Progesterone is a substrate for 5-alpha reductase and acts as a competitive inhibitor of the T-to-DHT conversion. (117)

4) Environmental factors: In recent years a debate has begun in the scientific community about the negative impact of environmental factors on male reproduction in humans (118). This debate has mostly centered on the hypothesis that certain substances of exogenous origin, known as endocrine disruptors, could be responsible for the appearance of disorders of sexual differentiation (119). More precisely, disturbances in masculine sexual differentiation may be induced by two categories of products: the xenoestrogens and the anti-androgens (120). Endocrine disruptors will affect in particular the normal development of the urethra, but will equally influence the physiology of testicular descent and spermatogenesis in the male. (121)

The list of products incriminated as endocrine disruptors is a long one comprises diverse synthetic products such as insecticides, pesticides, fungicides, industrial chemical products, substances used in the pharmaceutical industry, detergents and materials used in the fabrication of plastics. Certain natural substances of vegetable origin but having similar properties to hormones naturally produced in the body (animal and human), known as phyto-estrogens, have also been classified as potential endocrine disruptors. (122)

The hypothesis of an "arrest of development, (123,124) would seem the most plausible explanation for hypospadias although it does not identify a possible specific cause of the arrested

development, it would account for the concomitant occurrence of all three typical characteristics of hypospadias—penile curvature, hypospadiac meatus, and deficient foreskin. Complete straightening of the phallus does not occur until approximately the same time as the completion of urethral closure and just before completion of preputial formation. In addition, the dorsal "hood" of the prepuce described in the early stages of development is an exact description of the observed appearance of the preputial defect typically associated with hypospadias (125). This "hood" appearance is present at a time during development when the meatus is still hypospadiac in location. Slight variations in timing of the developmental arrest may account for hypospadias variants such as the megameatus intact prepuse (MIP).

Current knowledge notwithstanding, the absence of an exact causal agent for hypospadias in humans continues to pose a problem (126). Even today, the etiology of the majority of observed cases remains, unexplained.

PENILE CURVATURE (CHORDEE):

According to E.D.Smith (127), Galen [130–199AD] was the first to use the term "hypospadias" and the first to emphasize the major significance of penile curvature. Although there were references to penile curvature in the 1500s (Ambrose Paré) and in the 1700s (Pierre Dionis), there was apparently no understanding of its cause until the attempt by Mettauer in 1842. Mettauer (123) described a "skin tethering" etiology for penile curvature. This concept was ignored for more than 100 years until championed by Smith in 1955. He believed that the major cause of curvature was skin and that correction of curvature depended on freeing attachments of the ventral skin and corpora cavernosa distal to the urethral meatus (128).

Creevy, in 1958, acknowledged Smith's thoughts regarding the significance of skin and proposed his own hypothesis regarding the etiology of penile curvature, implicating the tissue now commonly referred to as the urethral plate by stating that the "urethra distal to the urinary meatus appears as a modified strip of mucosa covering a band of dense fibrous tissue composed of abortive corpus spongiosum". (129)

More recently, study of penile development via examination of fetal specimens has led to the understanding that penile curvature is a part of the early stages of normal penile development (130,132) and therefore the condition would be observed in the newborn carried to term. These observations support the "arrest of development" hypothesis for etiology of hypospadias as proposed by Mettauer [1842] and Van Hook [1896]. (131)

Currently, three major theories are proposed for the cause of penile curvature: (1- abnormal development of the urethral plate; (2- abnormal, fibrotic mesenchymal tissue at the urethral meatus; and (3- corporal disproportion or differential growth of normal dorsal corpora cavernosal tissue and abnormal corporal tissue ventrally. (132,133,134)

DIAGNOSIS:**HISTORY:**

Detailed family history should be obtained. Previous members of family with hypospadias should be recorded .fourteen per cent of male siblings of an index child have hypospadias. If two members of the family have hypospadias, then the risk is 21% in subsequent male children. Maternal ingestion of hormone medications during pregnancy should be ascertained. (135)

PHYSICAL EXAMINATION:

Although the diagnosis of hypospadias has been made using prenatal fetal ultrasonography, the diagnosis is generally made upon examination of the newborn infant.

A dorsal hood of foreskin and glanular groove are evident, but upon closer inspection, the prepuce is incomplete ventrally and the urethral meatus is noted in a proximally ectopic position. Rarely, the foreskin may be complete, and the hypospadias is revealed at the time of circumcision. If hypospadias is encountered during neonatal circumcision, after the dorsal slit has been performed, the procedure should be halted, and the patient should be referred for urologic evaluation.

Chordee may be readily apparent or only discernible during erection. Proximal hypospadias is commonly associated with a bifid scrotum and penoscrotal transposition, in which the rugated scrotal skin begins lateral to the penis, instead of its normal posterior origin. (2)

It must be kept in mind that apparent simple, isolated hypospadias may be the only visible indication of a significant underlying abnormality. (98)

RADIOLOGICAL EVALUATION:

In general, the literature does not support routine imaging of the urinary tract with either ultrasonography (136,137), or intravenous urography (136,138) for evaluation of children with isolated hypospadias, particularly when the hypospadiac meatus is middle or anterior in location. Retrograde injection of radiographic contrast material into the presumed urethral meatus (genitogram) is an essential component of the intersex evaluation when such an evaluation is deemed appropriate. Preoperative evaluation is more extensive in patients with posterior hypospadias includes voiding cystourethrography (VCUG) in those with a scrotal or perineal defect to evaluate the frequent presence and extent of a prostatic utricle. (139)

PREVALENCE:

In the specialist field of pediatric urology, it is reported that hypospadias is a common congenital malformation.

In a comprehensive review, Sorensen in 1831 reported a prevalence for hypospadias in 1 in 300 and also reported the same figure for live male births in Denmark. (140)

In 1896, Van Hook reported a figure for hypospadias prevalence of 1 in 300 live births, and in a postmortem series of 12,280 children (124),

Campbell in 1947 reported a prevalence of 1 in 1100 boys. (141)

Sweet and colleagues [1974] reported their 30-year experience and reviewed the epidemiology of hypospadias. During the period 1940 to 1970, inclusive, 113 cases of hypospadias were noted in 13,776 live male births (1 of every 122), 87% of defects were coronal or glanular. In their review of the literature from five different countries, Sweden had the lowest reported prevalence, 1 in 1250 live male births. (94)

In 1997, two independent and well-established surveillance systems in the United States, the Metropolitan Atlanta Congenital Defects Program (MACDP) and the nationwide Birth Defects Monitoring Program (BDMP), reported near-doubling of hypospadias rates in the most recent compared with the immediately preceding decades (142). As measured by the BDMP, hypospadias rates increased from 2.02 per 1000 male births in 1970 to 3.97 per 1000 in 1993. In other words, approximately 1 in every 250 live male births was a boy with hypospadias. The rate of severe hypospadias increased threefold to fivefold, from 0.11 per 1000 male births in 1968 to between 0.27 and 0.55 per 1000 male births per year from 1990 to 1993, as recorded by the MACDP (142). The rising trend may simply reflect more frequent or earlier diagnosis of mild forms of hypospadias over time or an increasing tendency to report to registries of congenital anomalies.

What explanations does the scientific community give regarding these rises? The concept of endocrinal disruption, as discussed above, has been increasingly accepted and proposed as a way of accounting for the increased incidence of hypospadias observed in more industrialized nations. (143, 144, 14)

However, a number of authors agree that new epidemiological research of a multi-disciplinary nature must be carried out, in order to clarify the part played by chemical substances disrupting endocrine function in the reported increased frequency of hypospadias. (119,120,121,126)

Familial aspects include the finding of hypospadias in approximately 6% to 8% of fathers of affected boys and 14% of male siblings of the index case of hypospadias. (96,106,146)

Roberts and Lloyd [1973] noted an 8.5-fold higher rate of hypospadias in one of monozygotic male twins, compared with singleton live male births (147). They suggested that this strong association of monozygotic twinning and hypospadias may be the result of an inability of a single placenta and reduced hCG levels to meet the requirements of two developing male fetuses. In an evaluation of monozygotic male twins discordant for hypospadias, Fredell and colleagues found that 16 boys with hypospadias from 18 such pairs, had a statistically significant lower birth weight than their unaffected twin. (109)

MORTALITY & MORBIDITY:

The treatment for hypospadias is surgical repair. (148,149) Hypospadias is generally repaired for functional and cosmetic reasons. The more proximally ectopic the position of the urethral meatus is, the more likely the urinary stream is to be deflected downward, which may require urinating in a sitting position. Any element of chordee can exacerbate this abnormality (150,151). Fertility may be affected. The abnormal deflection of ejaculate may preclude effective insemination, and significant chordee can preclude vaginal insertion of the penis or be associated with inherently painful erections. Although the most minor forms of hypospadias are physiologically insignificant, they too may require repair based on the potential psychological stress of having a genital anomaly. (152)

MANAGEMENT:

PERIOPERATIVE CONSIDERATIONS:

Hormonal Manipulation

There is considerable controversy surrounding the use of hormonal stimulation or supplementation for the purpose of penile enlargement before hypospadias repair. Topics of debate include whether to administer any adjunctive gonadotropins or hormones and, if so, which agent, route, dose, dosing schedule, and timing of treatment is to be employed.

Androgen Stimulation (hCG)

Koff and Jayanthi [1999] recently presented evidence that supports the use of hCG before repair of proximal hypospadias. An increase in penile size and length was noted in 12 boys aged 8 to 14 months who received a 5-week course of hCG preoperatively. The significant increase in penile length occurred primarily proximal to the urethral meatus, advancing the meatus distally anywhere from 6 to 19 mm. Observations included decreased hypospadias and chordee severity in all patients, increased vascularity and thickness of proximal corpus spongiosum, and allowance for more simple repairs in 3 of the 12 boys receiving hCG preoperatively. (153)

Shima and colleagues [1986] noted impaired gonadotropin and testosterone response to luteinizing hormone-releasing hormone and hCG stimulation in prepubertal boys with hypospadias. These authors did not discuss the penile or meatal response to stimulation. (154)

Androgen Supplementation or Replacement

Various preparations, including testosterone ointment, applied to the glans penis for 2 weeks before surgery, have been used to stimulate penile growth (155). Citing variable absorption and inconsistent results with the use of topical testosterone, Gearhart and Jeffs [1987] administered testosterone enanthate intramuscularly (2 mg/kg body weight), 5 and 2 weeks before reconstructive penile surgery. They noted a 50% increase in penile size and an increase in available skin and local vascularity in all patients. A near-doubling (from 3 to 5 cm) of the mean transverse length of the inner prepuce was also noted in some (156). In addition, they reported minimal side effects and return of plasma testosterone levels to within the normal range for age within 6 months after therapy. Others have employed variations in the total dose and schedule of testosterone enanthate administration, using 25 mg intramuscularly once weekly for a total of either two (157) or three injections. (158)

Monfort and Lucas (1982) used a 4-week period of local penile stimulation with daily application of dihydrotestosterone (DHT) cream before repair of hypospadias or epispadias (159). They reported a mean increase in penile circumference and length by 50% of pretreatment measurements, without any lasting side effects or gonadotropin level perturbation, and without any effects in the pubertal or postpubertal period.

Timing of Hormonal Manipulation

Hormonal manipulation at any age is not without risk. Caution must be exercised with regard to neonatal administration of hCG, in that evidence obtained from an experimental rat micropenis model supports delaying hormonal therapy until the pubertal period McMahan et al, (160). However, in their study of boys with congenital hypogonadotropic hypogonadism and micropenis, Bin-Abbas and colleagues [1999] concluded that one or two short courses of testosterone therapy in infancy and childhood (puberty) augmented adult penile size into the normal range (161). These results refute the theoretical concern and experimental evidence that testosterone treatment in infancy or childhood impairs penile growth in adolescence and compromises adult penile length. The conclusion that prepubertal exogenous testosterone administration does not adversely affect ultimate penile growth has been supported by the study of men with true precocious puberty or congenital adrenal hyperplasia (162) and by the study of growth and androgen receptor status of testosterone-stimulated human fetal penile tissue in vitro. (163)

HYPOSPADIAS SURGERY:

OPTIMAL TIME FOR SURGERY:

Initially, surgical reconstructions for hypospadias were practiced during later childhood, or even postponed to early adolescence (164). It was only around the second half of the 19th century that certain North American surgeons proposed that the operations be carried out before children entered primary school, to permit them to urinate standing up in the boys' toilets (165). The idea became accepted practice at the end of the 1970s [166]. At that time, according to the American Academy of Pediatrics (AAP), technical considerations remained of prime importance. (167)

At the beginning of the 1980s, two publications appeared concerning the technical possibilities of starting to operate on very young children (168,169). As technical changes reduced the possible age of surgery, an awareness began to develop about the psychological implications of surgery at such a young age (170). And at the end of the decade, Lepore and Kesler [1979] described a specific pattern of negative behavior in a group of children who had just been operated upon. They alerted the medical community to the danger to the children's psychological health caused by genital surgery around the age of three years. (171)

According to a review of the literature at that time, Schultz et al. [1983] suggested - with regard to emotional and cognitive development and the emergence of self-image and sexual identity - that surgical interventions should be practiced during the first year of the child's life. They also stated that it should be arranged so that parent-child separation during hospitalization was minimized and that parental accompaniment should be encouraged, with the aim of reassuring parents and allowing them to express their anxieties, worries or feelings of guilt, emotions which are often present. (172)

In a recent article from the American Academy of Pediatrics (AAP) 1996, it has become technically possible (e.g., using optical magnifiers, micro-instruments, delicate materials and sutures, and with progress in anesthesia) to operate on almost all forms of hypospadias in very young children while minimizing not only the time spent in hospital and the amount of separation from parents (173), but also the number of operations required (e.g., by using single stage procedures). Recent studies showed that the ideal time for hypospadias correction is between 3 and 15 months as the penis grows less than 1 cm during the first 3 - 4 years (Fig. 2). (148)

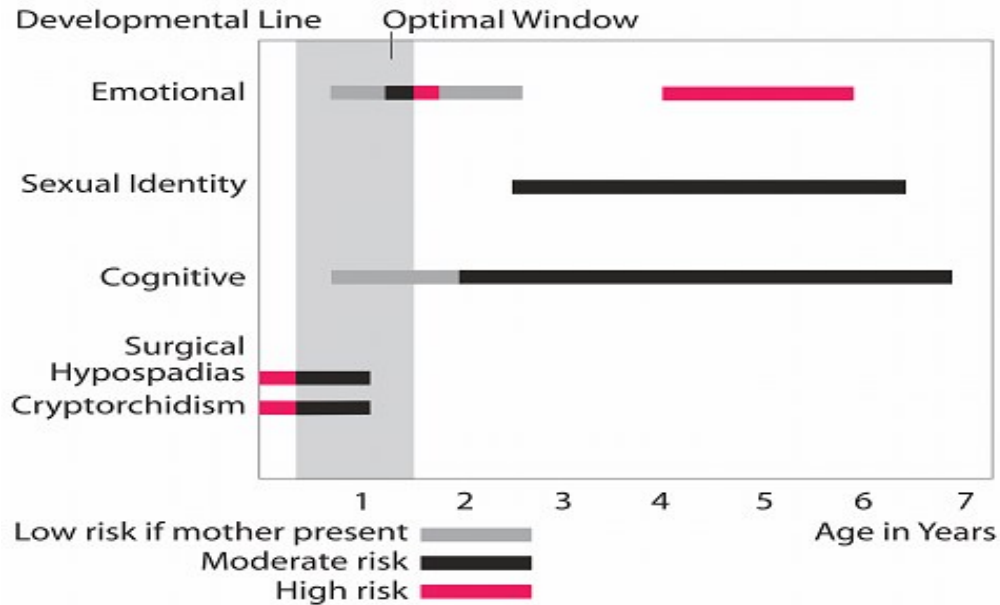


Fig. 2:

Evaluation of risk for hypospadias repair from birth to age 7 years. The optimal window is from 3 to 15 months of age. (From: Hypospadias Surgery; 2006; by Prof. Ahmed T Hadidi).

Current practice, in North America, is to carry out this type of surgical intervention between the ages of 6 and 18 months (AAP, 2000). However, there is still no true consensus on this question internationally. In France, for example, some surgeons prefer to wait until the child is one or two years old (174). Overall, however, the tendency is to operate increasingly early, with as few operations as possible and in as limited a time period as possible, with the aim of diminishing the psychological impact of both the hypospadias and the experience of surgery. (118,152,174)

Anesthesia:

General: General anesthesia, typically with endotracheal intubation, has been the mainstay of anesthetic technique for hypospadias repair. General anesthesia provides uninterrupted performance of the repair without concern for patient movement or sensation of pain. Adjunctive analgesia in the form of long-acting injectable agents, delivered via a caudal route or as a penile block, has proved safe and efficacious.

Local and Regional: A popular agent for adjunctive analgesia is bupivacaine hydrochloride (0.25%), administered as a caudal or penile block. A statistically significant improvement in postoperative pain control was noted for those patients who received a penile block both at the beginning and at completion of hypospadias repair, compared with the other groups. (175)

Antibiotics:

In general, perioperative antibiotics are not indicated for routine outpatient hypospadias repair. However, one intravenous dose of a broad-spectrum antibiotic may be indicated for those in whom the urethra is catheterized intraoperatively. Administration of a prophylactic antibiotic during use and for several days beyond removal of an indwelling urethral catheter has been described. (176)

Hemostasis:

Based on the hypothesis that some complications (e.g., urethrocutaneous fistula, repair breakdown) are in part a result of ischemic tissue necrosis, use of electrocautery should be limited during hypospadias repair, if it is used at all (177). The current of monopolar cautery is dispersed to the remote grounding site, usually along the vessels, and in this way may irreparably damage tissue microvasculature (178). Others employing electrocautery prefer the bipolar variant and the use of fine-point neurologic forceps (176). Others favor injection of a vasoconstrictive agent (epinephrine diluted 1:200,000 with lidocaine [Xylocaine]) deep to proposed glanular incisions, as well as intermittent use of a tourniquet at the base of the penis during urethroplasty. Other options for effective temporary hemostasis without permanent tissue devitalization include intermittent compression with gauze soaked in iced saline or epinephrine solution or both.

Optical Magnification:

Wacksman [1987] reported that a new microscope (mouth-controlled operating room microscope) compared favorably to loupe magnification and allowed use of small sutures with great accuracy (179). Shapiro [1989] compared the results of hypospadias repair using 3.5× magnification (loupes) and using the Zeiss reconstruction microscope (180). There was no significant difference in outcome, and Shapiro's prediction that the microscope would be used more often in the repair of hypospadias in the future does not appear to have come to fruition.

Sutures and Suture Technique:

Stay sutures are used whenever possible to limit tissue handling. Typically, a subcuticular technique is employed during longitudinal closure of the neourethra when performing a tubularization technique. Perhaps the most important aspect of closure of the neourethra is the exact placement of each suture such that the edge of the epithelial surface is inverted and the raw surfaces of the subepithelial tissue are approximated. Healing then provides a "watertight" anastomotic suture line that, at least theoretically, decreases the risk of urethrocutaneous fistula formation. However, Hakim and coworkers (1996) reported that the technique, either subcuticular or full thickness, did not affect results provided the suture used was of polyglactin composition (181). In contrast, Ulman and colleagues documented a statistically significant lower fistula rate (4.9% versus 16.6%) for subcuticular compared with full-thickness technique (182). DiSandro and Palmer [1996] reported a fourfold increase in urethral stricture rate after

hypospadias repair with polydioxanone suture compared with chromic or polyglycolic acid suture. (183)

Neourethral Intubation:

Another source of controversy in hypospadias repair is the use or omission of postoperative urethral catheterization. In a multicenter report combining the experience of four institutions, excellent results were obtained in 96.7% of 336 patients repaired with the Mathieu technique as modified by Rabinowitz [1987](181). Complications occurred in 11 patients and consisted of urethrocutaneous fistula in 9, meatal retraction in 1, and meatal stenosis in 1.

Results were not affected by urethral catheterization status. In a prospective, randomized study, McCormack and colleagues [1993] found no difference in outcome when comparing 19 boys with urinary diversion and indwelling urethral catheter versus 16 boys without, all of whom underwent Mathieu hypospadias repair. (184)

Others report rates of urethrocutaneous fistula formation and meatal stenosis twofold greater in patients with a urethral catheter compared with those diverted suprapubically after hypospadias repair. (185)

Based on these results and those for the more extensively studied Mathieu repair, there does not appear to be an advantage to or necessity for use of a urethral catheter after some hypospadias repairs. This may be true for some of the more recently described techniques as well. (186)

Dressing:

An ideal penile dressing should be nonadherent, slightly absorbent and compressive, and yet somewhat elastic and soft to allow for slight swelling. In order to achieve these goals, several different dressing techniques have been described (187). In 1982, De Sy and Oosterlinck described a soft, pliable foam dressing, the "silicone foam elastomer,"[1880], this dressing appears to be well tolerated and is easily removed in 4 to 6 days. Also it has been used in conjunction with a pantaloons spica cast for postoperative immobilization after free graft hypospadias repair (189). Although the urethrocutaneous fistula rate was similar to previous experience, this method of postoperative care significantly reduced the hospitalization time and cost.

In two prospective randomized trials, it was shown that there is little or no advantage to the application of a dressing to the operated hypospadias, patients were randomly assigned to receive either transparent film dressing, elastic wrap dressing, or no dressing. Antibiotic ointment was used to coat the penis in those receiving "no dressing." The method of

postoperative care (dressing versus no dressing) did not affect surgical success rate or wound healing. (190,191)

In general, a regimen of no dressing appears to result in increased patient comfort and decreased burden for the caregiver.

Postoperative Penile Erection and Bladder Spasm:

Stock and Kaplan [1995] reported use of ketoconazole as a reliable method for preventing postoperative penile erections after penile surgery. Ketoconazole reduces adrenal and testicular androgen production through the inhibition of 17, 20-desmolase, thereby preventing the conversion of cholesterol to testosterone. Hepatotoxicity is a recognized side effect of ketoconazole. (192)

Amyl nitrite has also been used to prevent penile erections (Horton and Horton, 1988). Judicious use of anticholinergic medication has been described for postoperative bladder spasm in stented patients. (193)

GENERAL PRINCIPLES OF HYPOSPADIAS REPAIR:

Regardless of the technique employed for repair of hypospadias and its associated defects, attention to penile curvature and its correction (orthoplasty), urethroplasty, meatoplasty and glanuloplasty, and finally skin coverage, are universal concerns.

Orthoplasty:

-Assessment of Penile Curvature:

Intraoperative assessment of penile curvature by either artificial or pharmacologic methods is a critical step in hypospadias repair and is typically performed after degloving of the penile shaft skin. A subjective impression or an objective (protractor) measurement of the observed curvature helps guide management. (194)

- Artificial Erection: Gittes and McLaughlin were the first to describe artificial erection as an aid to the evaluation of penile curvature. An Injection of normal saline with a "butterfly" needle into the corpora directly is performed by insertion of the needle through the lateral aspect of one or the other corpora cavernosa. Alternatively, the needle may be passed through the glans in order to decrease or eliminate the possibility of hematoma formation beneath Buck's fascia. (195)

- Pharmacologic Erection: Intracorporal injection of the arterial vasodilator prostaglandin E1 (PGE1) has been used for pharmacologic induction of erection during hypospadias repair (196). It allows for a more accurate and continued assessment of penile curvature before, during, and after its correction.

-Management of Penile Curvature with or without Hypospadias:

The site for orthoplasty and the specific technique employed are dictated by the direction and severity of curvature, by penile size, or both. Except where indicated in the technique description, orthoplasty techniques may be performed on any surface of the penis.

- Skin Release and Transfer: Penile skin may be the sole source or only a contributor to penile curvature (36) or torsion (197). In 1968, Allen and Spence observed this association with distal hypospadias, when on making a circumcising incision proximal to a coronal hypospadiac meatus they noted that freeing of penile shaft skin from the underlying urethra permitted penile straightening. As part of the repair, preputial skin was transposed ventrally.
- Plicating and Heineke-Mikulicz Techniques: Nesbit [1965] described removing "vertical elliptical segments" of tunica albuginea (transversely oriented) from the disproportionately longer, convex aspect of the penis in order to correct curvature (198). Another method for correcting the disparity in tunica albuginea length consists of lengthening the shorter concave surface by using the Heineke-Mikulicz principle (199). Several transverse incisions in the tunica are closed longitudinally to achieve lengthening of the concave aspect of the penis (200). Multiple parallel plicating sutures placed opposite the site of maximal curvature is a more recently reported technique that has become the preferred method for the treatment of penile curvature by the reporting authors. (201)
- Corporal Rotation: Corporal rotation, achieved via a ventral, midline longitudinal incision alone, was described by Koff and Eakins [1984] for correction of ventral penile curvature in a hypospadiac patient. Medial rotation and suture fixation of the dorsal aspect of both corpora cavernosa has been described for management of severe curvature. The corporal rotation technique allows one-stage reconstruction while achieving or maintaining maximal penile length. (202)
- Dermal Graft: The dermal graft has been used extensively for repair of significant penile curvature. It is ideal for the short phallus with severe penile curvature, for which the Nesbit wedge or tunica albuginea plications may be inadequate. The dermal graft is harvested from a nonhair-bearing donor site, typically in the groin. in an elliptical shape at a length slightly longer than the ventral defect to be created by transverse linear corporotomy injected with saline below the dermis to ease dissection . The graft is then defatted and placed in saline. A transverse incision is made at the site of maximal

curvature (concavity) and the dermal graft is anastomosed to the edges of the corporal defect with a running simple suture of 6-0 polyglactin. (203)

- Tunica Vaginalis Graft: Use of a tunica vaginalis free graft as a ventral corporal patch orthoplasty technique was reported as the first stage (orthoplasty) of a two-stage repair of severe hypospadias. (204)
- Total Penile Disassembly: A radical approach of penile disassembly and corporoplasty was described to correct curvature without the need for placement of an interposition corporal graft, thus minimizing the work of straightening the penis and lengthening the urethra in those patients with associated hypospadias. (200)

Urethroplasty:

-Neourethral Formation: Techniques for urethroplasty typically use immediately adjacent tissue, local tissue flaps, free grafts of genital or extragenital tissue, or some combination of these.

- Immediately Adjacent Tissue: The neourethra may be formed via reconfiguration of tissue immediately juxtaposed to the hypospadiac meatus and/or along the path of proposed urethroplasty. This may be the least risky and least technically challenging of all forms of urethroplasty. An example would be simple tubularization of the urethral plate
- Local Tissue Flaps: The term flap implies that the tissue used is excised and transferred with its vasculature preserved or surgically reestablished at the recipient site. Tissue flaps may be classified by their vascularity. A random flap does not have a defined cutaneous vascular territory. The term axial flap implies the presence of specific, defined vasculature in the base of the flap. The term island flap implies maintenance of vascular and division of cutaneous continuity. (205)
- Local or Extragenital Free Grafts : The term graft implies that tissue has been excised from one location and transferred to a graft host bed, where a new blood supply develops by a process called "take" . As with all free grafts, a well-vascularized recipient site is crucial for optimal graft survival. The initial phase of take, called imbibition, relies on diffusion of nutrient material from the adjacent graft host bed into the graft and requires approximately 48 hours. This is followed by the second phase of take, inosculation, which is the formation of new and permanent vascularization of the graft and also requires approximately 48 hours. (205)

-Neourethral Coverage (Second Layer): Second-layer coverage of the neourethra with the use of various vascularized flaps has significantly decreased urethrocutaneous fistula as a complication of hypospadias repair. (36)

- Subcutaneous (Dartos) Flap: the dorsal prepuce is unfolded and the underlying dartos layer is sharply dissected to the base of the penis and then incised longitudinally in the midline. (206)
- Tunica Vaginalis: Tunica vaginalis tissue may be used as an alternative for second-layer coverage of the neourethra, the inferolateral border of the neourethral mesentery may be advanced over the edges of the neourethra as a buttress. The testis to be used as the donor of tunica vaginalis is delivered into the operative field and isolated from its scrotal attachments. The tunica vaginalis is incised, and an appropriate width of flap is isolated from the testis and widely mobilized on its own vascular pedicle. (Tunica vaginalis is harvested similarly for corporal patch graft orthoplasty.) The tunica vaginalis flap is then secured over the neourethra by placement of simple interrupted sutures, and the testicle is replaced in the scrotum. (207,208)
- Corpus Spongiosum: Paraurethral (spongiosal) tissue approximation in the midline as a second cover of the initial suture line was initially described by van Horn and Kass [1995] as an adjunct to distal hypospadias repair (209). Similarly, Yerkes and colleagues [2000] described mobilizing distal spongiosum lateral to the open urethra along with the urethral plate away from the corpora cavernosa, subsequently wrapping it around various types of urethroplasty for distal hypospadias in order to prevent fistula formation. (210)

-Meatoplasty and Glanuloplasty: These two components of hypospadias repair are discussed together because successful completion of one is intim dependent on the other. In 1977, Devine and Horton described the "V-flap" glanuloplasty as an adjunct to tubularized skin graft urethroplasty. This technique involves extensive dissection of the glans penis with development of a midline, anteriorly based flap of glans epithelium. Underlying subepithelial tissue is removed from the glans flap, and the flap is fixed to the tunica of the corpora cavernosa, consistently fashioning a widely patent, complication-free meatus. (211)

Others have incorporated a glanular "W-shaped" flap meatoplasty with urethroplasty. (212)

Penile Shaft Skin Coverage: Various techniques have been employed for the purpose of completing hypospadias with adequate skin coverage of the penis. These techniques have included ventral transfer of preputial skin either with a buttonhole through the skin for through passage of the glans penis (22,39) or a midline longitudinal split of the prepuce or dorsal penile skin followed by lateral transfer of the skin on either side of the penis for ventral coverage. (55,213,214)

DIFFERENT TISSUES USED FOR CORRECTION OF HYPOSPADIAS:

To correct hypospadias and achieve a terminal meatus, one may use one of the following basic principles or tissues:

- 1) Mobilisation of the urethra.
- 2) Skin distal to the meatus.
- 3) Skin proximal to the meatus.
- 4) Preputial skin.
- 5) combined prepuce and skin proximal the meatus.
- 6) Scrotal skin.
- 7) Dorsal penile skin.
- 8) Different grafts.

CHOISE OF OPERATIVE TECHNIQUE:

More than three hundred operations have been described for the treatment of hypospadias. Surgeons have proceeded through Browne repairs and scrotal flaps, to Duplay tubes, to free skin grafts, to island flaps and onlays, to bladder and buccal mucosal repairs, to a host of single-stage innovations, to different concepts of chordee correction and with all manner of bladder drainage systems. However, hypospadias repairs can be grouped into five or six major principles, depending on the tissues used. (76)

For glanular hypospadias with mobile meatus, Prof. Hadidi prefers to perform the Inverted Y Meato-Glanuloplasty technique. For hypospadias without chordee, he prefers to use the Tubularised Plate technique (inverted Y Thiersch) or Y-V glanuloplasty modified Mathieu approach. The author has adopted the lateral-based flap for proximal hypospadias with deep Chordee. Two-stage repair may be preferred in patients with perineal hypospadias to avoid the use of hair-bearing areas of skin.

DESCRIPTION OF COMMONLY PRACTICED PROCEDURES:

The inverted Y Meato-Glanuloplasty:

This technique is suitable for a limited number of hypospadias patients. It is ideal for patients with glanular hypospadias characterised with mobile meatus. If the meatus is not mobile

or can not be brought to the tip of the penis, the technique is contra-indicated. An inverted Y incision is outlined on the glans. The two diverging limbs are incised along the upper edge of the meatus. The longitudinal limb extends in the midline to the tip of the glans. A space is created for the new urethra. The inverted Y is sutured as an inverted V preserving the dog ears. The glans is freely mobilised to wrap around the urethra. Urinary diversion and dressing is applied for 24 hours only. (76)

The Tubularised Plate (YTP) Technique (inverted Y modified Thiersch Technique)

This technique is suitable for hypospadias patients without deep chordee. Whether the hypospadias is distal or proximal as long as the patient has no or only superficial cutaneous chordee. It is a modification of the standard Thiersch technique in order to have a slit like meatus at the tip of the glans. It avoids the major drawbacks of tubularised incised plated technique like stenosis or recurrent fistula. The inverted Y allows to bring the urethral plate deep into the glans. In order to reduce the incidence of fistula, a second layer is mandatory. For distal or glanular hypospadias, the second protective layer is taken from the preputial fascia. For proximal hypospadias without deep chordee, Prof. Hadidi prefers to use fascia from the scrotum with or without tunica vaginalis fascia. (215)

The Y-V modified Mathieu procedure:

The meatal-based flap technique of Mathieu is the most popular technique for distal hypospadias repair and has withstood the test of time. However, the major drawback of the original Mathieu technique is the final appearance of the meatus (a smiling meatus that is not very terminal). The Y-V glanuloplasty helps to employ the Mathieu operation in all forms of distal hypospadias and gives a terminal, slit like meatus. This will include about 70 to 80 % of patients with hypospadias. The only contraindication is the presence of severe chordee distal to the hypospadiac meatus.

Steps of Y-V glanuloplasty modified Mathieu technique:

a) Y Incision; b) The three flaps elevated and coring to make a space for the neo-urethra; c) Y sutured as V with preservation of dog-ears; d) The dog-ears opened; e) U shaped flap; f) urethroplasty; g) A small dog-ear is excised near the meatus; h) A small V is excised from the neourethra; i, j) Meatoplasty and glanuloplasty. (216)

A Y-shaped incision is outlined on the glans with the centre of the Y where the tip of the neo-meatus will be located. Each limb of the Y is 0.5 cm long. The Y-shaped incision is made deep and the three flaps are elevated and a core of soft tissue is excised from the bed of each flap to create a space for the neo-urethra. The Y-shaped gap is sutured as a V making sure to keep the dog-ears at the upper ends of V suture lines. These dog-ears will enlarge the circumference of the tip of glanular wings 1 cm at least.

A U-shaped incision is made slightly longer than the distance between the meatus and the designed tip of the neo-meatus. The longitudinal incisions should diverge away from the hypospadiac meatus to allow for adequate blood supply to the flap. The U-shaped incision will open wide the dog- ears.

A continuous subcuticular running Vicryl® 6-0 on a cutting needle is used for neo-urethra reconstruction. The subcuticular suture is continued until the tip of the glans, then goes back with the same stitch in a running stitch approximating the flap fascia to the depth of the glans and the shaft of the penis (double breasting). Thus, one will have one knot only for the whole two layers.

A small V is excised from the apex of the parameatal flap and the meatus is reconstructed. The glanular wings are approximated using transverse mattress interrupted sutures.

The preputial skin is left intact. The prepuce may be reconstructed if parents desire after 6 months when everything has healed well or circumcision performed. Usually, it is not recommended to perform circumcision during urethroplasty, in case complications occur and the preputial skin becomes important. (216)

Lateral Based (LB) Flap:

The lateral based flap may be used in all types of proximal hypospadias. This flap with double blood supply, combines the advantages of meatal-based flap, and preputial pedicle flap techniques into one procedure without the need for an intervening anastomosis. It also allows for extensive excision of ventral chordee and the urethral plate (if necessary) without damaging the flap.

Operative steps

A deep Y-shaped incision is made on the glans. The centre of the Y is where the tip of the neo-meatus will be located. The upper two short limbs of the Y are 0.5 cm long. The long vertical limb Y extends down the whole length of the glans penis to the coronary sulcus. The resultant three flaps are elevated and a core of soft tissue is excised to create a space for the neo-urethra.

Meticulous excision of any chordee or fibrous bands is carried out. This fibrous tissue is particularly heavy in the midline but may extend well laterally. The meatus is assessed and a cut back is made to widen the meatus.

A rectangular skin strip is outlined extending proximally from the urethral meatus staying in the midline in the scrotum to avoid potentially hair bearing skin. The skin strip is extended

distally and laterally by curving towards the prepuce. This allows for formation of a very long tube that can reach the tip of the glans wherever the original position of hypospadias meatus is.

The skin incision is carried completely around the meatus leaving a small cuff of skin. The meatus is freed proximally. The adjacent penile skin is elevated (rather than the flap). The flap with its pedicle is mobilised through the dorsum of the penis and down to the root of the penis to avoid penile rotation.

The skin strip and proximal cuff are tubularised around a Nelaton catheter size 10 Fr inside the urethra. The author prefers to use Vicryl 6/0 on a cutting needle. Suturing is carried out from distal to proximal in a subcuticular continuous manner. Several reinforcing interrupted stitches are usually taken to form water tight tube.

The neomeatus is then constructed by suturing the terminal end of the neourethra to the central V of the glans. A final slit like meatus is obtained by excising a small V from the tip of the neo-urethra. Then, the glanular wings are wrapped around the neourethra and approximated in the midline. When completed a near normal wide meatus is created at the tip of a conical shaped glans. The long anastomotic contact between the neo-meatus and glans created by the Y glanuloplasty is important to create a wide meatus and avoid post operative meatal stenosis. The vascular areolar subcutaneous tissue layer is then used to provide a complete covering for the neourethra. The skin is closed in the midline using 6/0 Vicryl in a continuous transverse mattress. This helps to simulate the normal ventral median skin raphae. A percutaneous suprapubic cystocath is inserted into the bladder for 10 - 14 days. A compression dressing is applied for 6 hours for haemostasis. (217)

Transverse Preputial Island Flap:

A deep Y-shaped incision is made on the glans as in the Lateral based (LB) flap technique. Meticulous excision of any chordee or fibrous bands is carried out. This fibrous tissue is particularly heavy in the midline but may extend well laterally. The meatus is assessed and a cut back is made to widen the meatus. A sub coronal incision is made around the glans. The incision continues laterally until it reaches the gap where the fibrous chordee was excised.

The penile and preputial skin is dissected free off the shaft from distal to proximal close to the Buck's fascia preserving the arteries that constitute the pedicle to the preputial flap.

A 1.5 cm wide rectangular flap is prepared. The length must suffice the gap between the meatus and the tip of the glans. Extra length can be obtained by going down into the penile skin in a horseshoe fashion on either side. The flap is tubularised around a 10 Fr catheter and sutured into the meatus beginning with the suture line underneath the pedicle utilizing interrupted 7-0 polyglactin suture. Then, the pedicle is separated from the outer preputial skin in a plane just below the intrinsic blood supply of the outer prepuce down to the root of the penis.

The upper small median flap resulting from the Y incision is sutured to the upper dorsal end of the tube. A V is excised from the tip to obtain a slit like meatus. The mobilized glans wings are rotated medially around the neo-urethra. Three transverse mattress sutures maintain firm approximation of the glanular wings in the midline. The mobilized glans wings are rotated medially and three transverse mattress sutures maintain firm approximation of the glanular wings in the midline. De-epithelialisation of skin to protect the neourethra. (218)

MAGPI (Meatal Advancement and Glanuloplasty Incorporated) :

This technique may be used in glanular hypospadias with mobile urethral meatus that can be pushed to the tip of the glans. If the meatus is not mobile enough, the results are less satisfactory.

Meatal advancement: The dorsal lip distal to the meatus is cut longitudinally to avoid urine deflecting downwards. In the classic MAGPI, the incision is closed transversely (Heineke Mickulicz technique). Thus the dorsal meatal edge is advanced distally. Recently, some surgeons leave it without closure as a modification of the TIP-Technique.

The glanuloplasty is accomplished by elevating the ventral edge of the meatus forwards and rotating the flattened glanular wings upwards and ventrally in a conical manner. It is important to reapproximate glans tissue in a two layers fashion with a deep closure of glans mesenchyme and a superficial layer of glans epithelium. There have been several modifications of this technique. (219)

Onlay Island Flap:

The Onlay Island Flap is ideal for patients with proximal hypospadias without deep Chordee. According to the author experience, most patients with proximal hypospadias have deep chordee that necessitates excision. However, recently, many surgeons prefer to perform dorsal placcation if the chordee is less than 30o after skin degloving and preserve the urethral plate.

Operative steps

The tip of the neo-meatus is identified. This point is where the flat ventral surface of the glans begins to curve around the meatus. A midline vertical incision is made in the glans until the width of the glanular groove is adequate for the meatus. The vertical incision is left open without closure for secondary epithelialisation.

A subcoronal incision is made around the glans. The incision continues on either side of the urethral plate at the junction with the normal ventral skin, then up on either side of the glanular groove to the apex of the glansplasty.

The skin is degloved from distal to proximal close to the Buck's fascia preserving the arteries that constitute the pedicle to the preputial flap. The pedicle is then separated from the outer preputial skin in a plane just below the intrinsic blood supply of the outer prepuce. The elevation of the glans wings will permit them to be rotated around the urethroplasty.

A 1-cm wide onlay flap is prepared from the inner prepuce. The onlay flap is sutured into place beginning with the suture line underneath the pedicle utilizing running 7-0 polyglactin suture. The glans should be drawn together setting up the first stitch of the glansplasty ventrally at its apex.

The mobilized glans wings are rotated medially around the neo-urethra. Three transverse mattress sutures maintain firm approximation of the glanular wings in the midline. (220)

Denis Browne Technique:

In the first stage, a circumferential incision is made proximal to the coronal sulcus, and the penile shaft is degloved. Failure to create a straight phallus is one of the avoidable complications. Penile straightening and full removal of chordee must be confirmed by means of the artificial erection test. If the penis remains bent despite resection of all chordee, an alternative approach may be needed, such as insertion of a dermal or tunica vaginalis graft into the shaft, or dorsal plication.

When it has been ascertained that the penis is straight, the glans is prepared. The glans is either divided deeply in the midline to the tip or, if the mucosal groove is deep, this is preserved and incisions are made just lateral to the groove in each side. The dorsal foreskin is unfolded carefully and divided in the midline. The most distal portion of the foreskin is rotated into the glanular cleft and sutured to the mucosa of the glans with interrupted sutures. A midline closure is performed, and the midline sutures catch a small portion of Buck's fascia. This eliminates dead space and helps to create a groove in preparation to the second stage. The bladder is drained with a Foley catheter for approximately 5-7 days.

The second stage is completed at about 4-5 years of age. At that time perineal urethrostomy is performed and peripheral incision is made around a midline strip of skin on the ventral shaft of the penis, extending from the urethral meatus to the inferior portion of the glans. A small triangle of the glans is denuded on each side of the midline. By combining wide undermining and dorsal relaxing incisions, lateral skin flaps can then be approximated over the midline longitudinal strip of skin, which remains attached to the ventral surface of the penis. No catheter is placed over the buried skin on the penis. The perineal catheter is usually removed on the 10th postoperative day, thus allowing the perineal fistula to heal spontaneously. (221)

Two Stage repair:

Small group of patients with severe proximal hypospadias, chordee, and a small phallus as well as patients with recurrent hypospadias and fibrous unhealthy skin may benefit from a two-stage procedure.

In the first stage, a circumferential incision is made proximal to the coronal sulcus, the chordee is excised, and the penile shaft is de-golged. Penile straightening and removal of all chordee tissue must be confirmed by the use of the artificial erection test.

The glans is divided deeply in the midline to the tip. The dorsal foreskin is unfolded carefully and divided in the midline. A midline closure is performed, and the midline sutures catch a small portion of Buck's fascia. The bladder is drained with an 8 French Silastic Foley catheter for approximately 5 to 7 days.

If there is inadequate genital skin available, buccal mucosa or rarely bladder mucosa may be used. The buccal mucosa is harvested from the inner surface of the cheek or the inner surface of the upper or lower lip. The parotid duct is identified opposite the upper molars, and cannulated with 3-0 nylon. The graft is outlined and the submucosa infiltrated with 1% lignocaine containing 1:2000 epinephrine. The graft is incised and the mucosa is dissected away by sharp dissection.

The second stage of the procedure is carried out 6 to 12 months later. The previously transferred skin or mucosa is used to reconstruct the glans and urethra. A 16-mm diameter strip is measured, extending to the tip of the glans. The strip is tubularized with a running subcuticular stitch of 6-0 Vicryl® all the way to the tip of the glans. Tension is reduced by generous mobilization and undermining of adjacent tissues. A protective intermediate layer (either tunica vaginalis or dartos) helps to reduce post-operative complications.

The lateral skin edges are mobilized, and the remaining tissue is closed over the repair in at least two layers. A strip of skin (3 - 5 mm wide) is de-epithelialised on one side to provide a raw surface of deep dermis. This is achieved by cutting 2 or 3 fine longitudinal strips with a pair of small curved-on-scissors. The medial edge of the shaved flap is brought across the buried urethroplasty and sutured to fascial tissue beneath the other flap (double breasting). (222)

COMPLICATIONS:

Complications of hypospadias repair include bleeding/hematoma, meatal stenosis, urethrocutaneous fistula, urethral stricture, urethral diverticulum, wound infection, impaired healing, and breakdown of the repair. (193,223,224)

When reoperation is indicated, appropriate timing is crucial. However, more serious complications involving either partial or complete breakdown of the hypospadias repair may require a major reconstructive effort. At times, this involves the task of performing a complete repair in the face of less than optimal tissues and conditions. In general, unless immediate re-exploration is indicated for bleeding, infection or débridement, reoperation for complications should not be performed less than 6 months after previous repair.

- Bleeding and Hematoma :

Bleeding has been noted as the most common complication of hypospadias repair. This may require addition of a compressive dressing due to persistent oozing. At other times, significant postoperative bleeding may require immediate exploration to identify and treat the source. Hematoma may form as a result of persistent bleeding; if large in size, it may require wound exploration and hematoma evacuation. Consequences of hematoma formation range from simple temporary cosmetic issues to wound or repair breakdown (225). Patients with excessive bleeding and/or hematoma formation, particularly those requiring reoperation, should undergo evaluation for bleeding diathesis/dyscrasias. (193)

- Infection :

Infection is an uncommon complication of hypospadias repair. When infection is suspected, culture, incision and drainage, and débridement, when indicated, are incorporated with appropriate empirical and definitive antibiotic therapy. Severe infection may lead to breakdown of the entire repair.

- Meatal Stenosis :

The complication of meatal stenosis is perhaps most commonly caused by technical issues at the time of repair, such as fashioning of the urethral meatus with too narrow a lumen or performance of glanuloplasty too tightly. Urethral (meatal) dilation or meatotomy may be sufficient for the mildest forms of meatal stenosis. However, a more complex distal urethral stricture also involving the meatus may require a more extensive flap procedure. (226)

- Urethrocutaneous Fistula :

The suspicion of a urethrocutaneous fistula is often reported by a parent or caregiver. This can be confirmed on physical examination with or without voiding, or with retrograde injection of dye such as methylene blue, either alone or with glycerin (193,223). Fistula may result from, or be associated with, distal stricture or meatal stenosis. Other risk factors include failure to invert all epithelial edges at urethroplasty, devitalization of tissue, and failure to add appropriate second-layer urethroplasty coverage.

Second-layer coverage of the neourethra has been shown to significantly reduce the fistula rate as reported by several authors. (36,223,227,228) Repair of urethrocutaneous fistula is optimized by the same principle (52,223,229,230). At times, larger or multiple fistulas may require incision of the intact skin bridges and delayed repeat hypospadias repair.

- Urethral Stricture :

Urethral stricture other than meatal stenosis may be a complication of proximal hypospadias repair. The proximal anastomotic site of a tubularized repair such as the TPIF appears to be particularly at risk. This type of stricture may be successfully treated with less invasive means, such as endoscopic cold knife urethrotomy (Scherz et al, 1988). However, a more extensive stricture may warrant patch with free graft or, preferably, pedicled flap urethroplasty; either of these two techniques achieves greater success when used as an onlay rather than a tubularized segment. In a thorough review of anterior urethral stricture repair techniques. (231)

Others have discussed the usefulness of mucosal grafts for treatment of urethral stricture disease (232). In 1989, Schreiter described a two-stage mesh-graft urethroplasty using split-thickness skin, for application in the absence of available pedicled flap tissue or an appropriate graft bed (231). The mesh-graft technique would be useful in those instances when all other options have failed.

- Urethral Diverticula :

Although infrequent, urethral diverticulum formation may occur after hypospadias repair. Similar to urethrocutaneous fistula, urethral diverticulum may be associated with distal stricture or meatal stenosis. Zaontz and colleagues described repair of this entity with circumferential skin incision, penile shaft skin degloving, diverticular excision and urethral closure, followed by "pants over vest" subcutaneous tissue coverage of the repair, with excellent results (234). For more extensive lesions, Aigen and colleagues described repair similar to that for megalourethra. (235)

- Recurrent Penile Curvature :

Late-onset, recurrent curvature has been described by several authors as a complication of orthoplasty performed alone or in conjunction with hypospadias repair. Farkas reported that a second operation (and sometimes more) was required in approximately 50% of cases of hypospadias and initial severe curvature (236). In a more contemporary report, late-onset curvature in patients with hypospadias thought to be caused equally by extensive fibrosis of the reconstructed urethra, corporeal disproportion, or both. (237)

- **Repair Breakdown :**

Repair breakdown may occur secondary to devascularization of local tissues or flaps used in urethroplasty or other components of hypospadias repair. Breakdown may also result from urethroplasty and/or approximation of the glans (glanuloplasty) under tension, or from devitalized tissue resulting from excessive use of electrocautery, unidentified vascular pedicle injury during repair, or hematoma formation (225). Regardless of the cause, repair breakdown may require débridement of devascularized, necrotic tissue before repair. (193)

- **Hypospadias Cripples :**

The term "hypospadias cripple" used to describe the patient who has undergone multiple, unsuccessful hypospadias repair attempts, with significant resultant penile deformity. These patients represent perhaps the most perplexing of hypospadias repair complications in that they require extensive repair amidst scarred and devitalized tissue. (238)

LONG-TERM FOLLOW-UP:

Gender Identity Issues:

Sandberg and colleagues studied gender-role behavior of middle childhood boys (175 boys aged 6 to 10 years of age) with hypospadias parents completed standardized questionnaires regarding their son's behavior. Both questionnaires, the Child Behavior and Attitude Questionnaire and the Child Game Participation Questionnaire, may help to differentiate between gender-typical boys and boys with gender-identity disorders. Hypospadias subjects did not show consistent differences from a community control group, and the severity of hypospadias was unrelated to gender-role behavior. (239)

Eberle and colleagues reported "satisfactory" results in two thirds of the 42 patients who were available for long-term follow-up after childhood posterior hypospadias repair. However, there were 13 patients who at follow-up still presented with complex sexual ambiguity. In six of these patients, androgen receptor defects were detected by means of biochemical as well as molecular-biologic investigations. These authors emphasized the importance of androgen metabolism for male sexual development and underlined the necessity of careful evaluation in children with posterior hypospadias. (240)

Patient Satisfaction:

Cosmesis:

Mureau and colleagues studied children and adolescents and men with previous hypospadias repair. Although many of the children and adolescents (39%) desired functional

and/or cosmetic penile improvement, they were reluctant to seek advice for these and other issues; therefore, such patients should be monitored through adolescence. Similarly, adult hypospadias patients reported a more negative genital appraisal than comparison subjects, and 37% desired functional or cosmetic penile improvement. (241,242)

Psychosexual Issues:

Mureau and colleagues studied psychosexual adjustment of children and adolescents. In relation to "comparison" subjects, 116 boys aged 9 to 18 years had a more negative genital appraisal and anticipated more ridicule by a partner because of penile appearance than comparison subjects, but sexual adjustment did not differ. The surgical procedures, the number of operations, and the age at final surgery did not significantly affect outcome. (241)

Mureau and colleague also evaluated psychosexual adjustment, sexual functioning, and genital appraisal in adult hypospadias patients 18 years of age or older. A total of 73 hypospadias patients and 50 comparison subjects received a semistructured interview. More hypospadias patients (32.8%) than comparison subjects (12.8%) had been inhibited in seeking sexual contacts. The severity of hypospadias negatively affected genital appraisal. Patient age at final operation positively correlated with sociosexual development. (242,243)

The majority of hypospadias patients experienced a normal adult sex life but were reluctant to seek advice for problems. This subject has been reviewed by others. (244)

Functional Issues:

Uroflow:

Several authors have evaluated uroflowmetry parameters in normal boys (245,246) and in boys after hypospadias repair (247,248,249,250). At some centers, this noninvasive study is part of a postoperative evaluation routine and has been of value in identifying asymptomatic urethral stricture in some patients (247,248). Uroflowmetry data obtained after TPIF repair and after stricture and/or fistula repair reviewed and concluded that the neourethra was functionally equivalent to a normal urethra in most boys.

Sexual Function and Fertility

Several authors have reported relatively normal adult sexual function and fertility after hypospadias repair (241,244,250,251,252). Selection bias may influence these results, because those with a less than optimal outcome or outlook may not wish to divulge such information and therefore may not be represented in these reports.

CHAPTER TWO

JUSTIFICATION, OBJECTIVES & METHODOLOGY

JUSTIFICATIONS:

Hypospadias is getting in the rise both in the international statistics and locally as we observed during our clinical practice. This anomaly has a different presentations, different surgical options and a wide spectrum of complications.

This study is expected to add more to the current status of this perplexing anomaly in Gezira.

GENERAL OBJECTIVES:

The main objective of the study is to determine and describe the epidemiology, the anatomy and the surgical modalities of hypospadias.

SPECIFIC OBJECTIVES:

1. To describe the demographic characteristics of the hypospadiac patients treated in GNCPS.
2. To describe the penile anatomy in the study group.
3. To define treatment options.
4. To identify the complication risk in the different procedures done in GNCPS.
5. To evaluate the out

PATIENTS AND METHODS

STUDY DESIGN:

This is a hospital-based retrospective descriptive study conducted through Jun 2008 to Jun 2009. The study will investigate the age of the patient on presentation, the type or classification of hypospadias, the procedure done and the complications on the base of the data available for that period.

STUDY AREA:

Gezira National Center of Pediatric Surgery (GNCPS) is a reputable center that was established in 1982. The center recruits patients from almost all over Sudan with a capacity of 60 beds. Two pediatric surgeons and two general surgeons run the service in the center, in addition to three to four running registrars, six medical officers and fourteen sisters.

A neurosurgeon is now doing the pediatric neurosurgical work load. There is a 24 hours casualty reception service, three theater days, one general pediatric surgery referred clinic, spina bifida clinic, anorectal malformation clinic and currently a hypospadias clinic was started because of increasing number of patients.

STUDY POPULATION:

The population of this study are all patients of hypospadias presented to GNCPS.

INCLUSION CRITERIA:

All patients admitted in GNCPS and underwent surgical procedure are included.

EXCLUSION CRITERIA:

No exclusion criteria

DATA COLLECTION:

A special questionnaire was designed for the purpose of data collection. Informations obtained include personal data; age of the patient on presentation, Consanguineous marriage, if there was any family history of similar condition and what was the relationship. The data also include a clinical assessment of the penile shaft size, any associated congenital anomaly, site of the urethral meatus, prepuce and glans condition, chordee assessment, urethral plate width, was there a penile torsion or scrotal transposition and what was the investigations done.

The data questionnaire also include the type of the surgical procedure done, and if there was any complications; what was it and what was the management and the outcome.

By the end of the study period a total of 75 patients data were obtained.

METHODS OF DATA ANALYSIS:

The obtained raw data then was edited and coded. A frame of analysis was developed. Then using the software programme 'Statistic Package for Social Sciences' (SPSS) variables were

selected and the following statistic values were obtained; descriptive statistic; simple frequencies and cross-tabulation.

ETHICAL CONSIDERATIONS:

The medical profession is guided by a code of ethics that evolved over years. Ethical issues were considered in this study. No incentives were given to respondents to show informations. The study was designed not to incur harm to participants such as discomfort, anxiety or invasion of privacy.

It was difficult to obtain the consent of all patients, but a written consent was obtained from the hospital authority. All the participants (research team) in the study gave an oral consent to be included.

CHAPTER THREE

RESULTS & ANALYSIS

1. DEMOGRAPHIC DATA

Total number of patients included in this study was 75. On presentation 28% (n= 21) were neonates, 17.3% (n= 13) were infants, 16% (n= 12) were toddlers and 38.7% (n= 29) were ageing 4-7 years. (Table 1).

Consanguineous marriage was positive in 21.3% (n= 16) of theme. (Table 1)

And a family history of hypospadias recorded in 10.6% (n= 8); all were brothers. (Table 1).

2. CLINICAL FINDINGS

In our clinical assessment to determine the degree of hypospadias severity we found that 94.7% (n= 71) of the patients were have adequate penile shaft' while the remaining 33.3% (n= 25) were have a relatively small ones. (Table 2).

Regarding the site of the urethral meatus "before carrying out urethroplasty" it was distal penile in 46.7% (n= 35), proximal penile in 33.3% (n= 25), glanular in 17.3% (n=13) of the study group, in addition to 2 cases (2.7%) with MIP. (table2, figure3).

Associated congenital anomalies were 32% (n= 24): 16 case (66.7%) of them were with UDT, 4 cases (16.7%) with microphallus, 3 cases (12.5%) with inguinal hernia and 1 case (4.2%) with PUJ obstruction. (table3, figure9)

Regarding the prepuce was incomplete in 80% (n= 60) and complete in the remaining 20% (n= 15) of the group studied. (table2)

The glans configuration was flat in 32 (42.7%), incompletely cleft in 25 (33/3%) and cleft in the remaining 18 (24%) of the patients. (Table 2, figure4)

Fifty patients (66.7%) have no chordee while the other 25 (33.3%) were have: 21(84%) of them with superficial and 4 (16%) with deep chordee. (Table 2, figure5).

Urethral plate width found to be equal to or more than 1cm in 25% (n= 39) of the patients and less in the other 48% (n= 36). (Table 2).

There were 11cases (14.7%) with penile torsion (figure11), and 4 cases (5.3%) were with scrotal transposition. (Table 2).

3. INVESTIGATIONS

Investigations were done for evaluation necessity for 36 patients (48%) were as the following:

ABDOMINAL U/S was done for 17 patients (47.2%) of them.

Buccal smear was done for 16 (44.4%) of them.

And chromosomal analysis was done for 3 (4%) patients of this group

(table4, figure 6).

4. OPERATIVE PROCEDURES

Types of surgical repairs were done according to the severity of hypospadias and surgeon experience found to be as the following:

TIP were done for 26 case (34.7%), Two stages repair for 25(33.3%), MAGPI for 13(17.3%) and MATHIEU were done for 11(14.7%). (Table 5, figure 7).

5. COMPLICATIONS

Thirty seven (49.3%) of the patients were accounted to develop a post operative complication:

15 of them (40.5%) developed urethrocutaneous fistula, 16 patients (43.2%) of them developed meatal stenosis, 4 patients (10.8%) of them developed recurrent curvature, and 2 patients (5.5%) of them developed post operative bleeding/haematoma. (Table 6, figure 8).

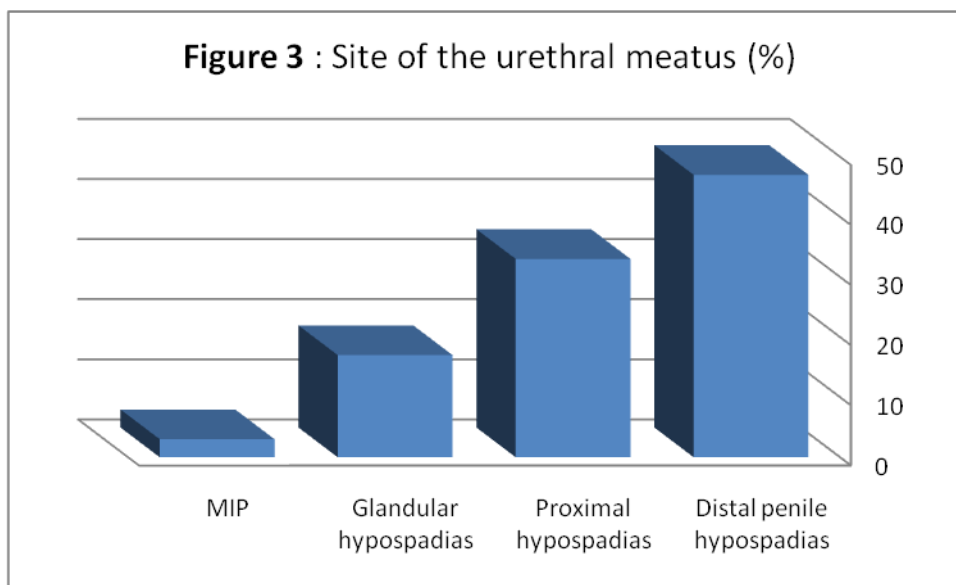
Cross-tabulation with the surgical procedure revealed that of the total 25 patients underwent two stages repair 12 (48%) of them were developed urethrocutaneous fistula and 4 (16%) of them were developed recurrent curvature. (Table 7)

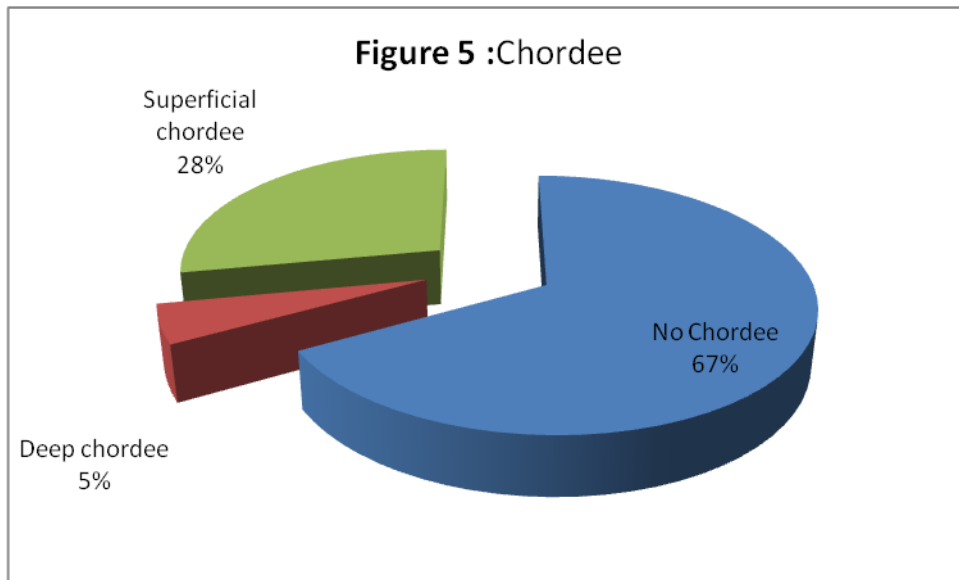
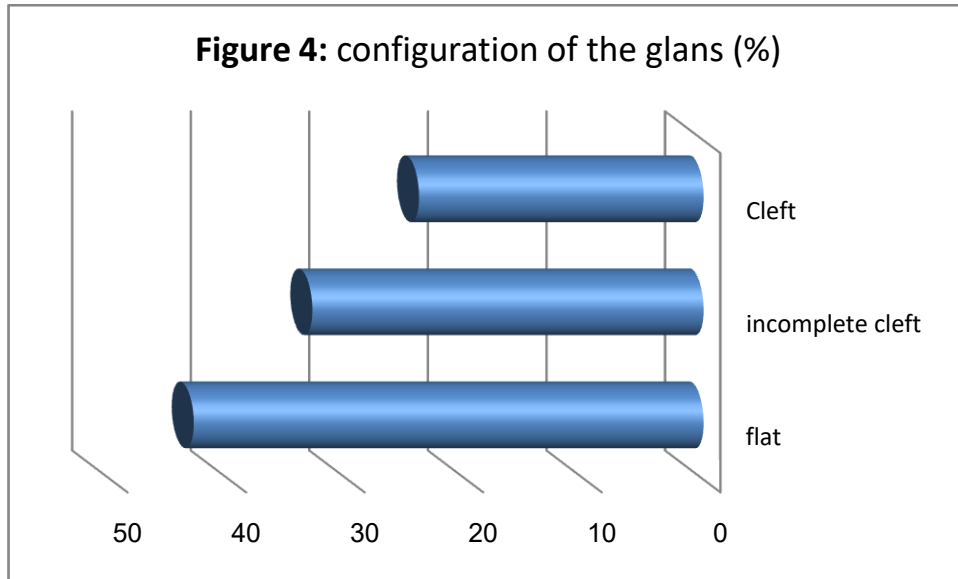
Of total 11 patients of MATHIEU repair; 7 of them (63.6%) were developed meatal stenosis. (Table 7)

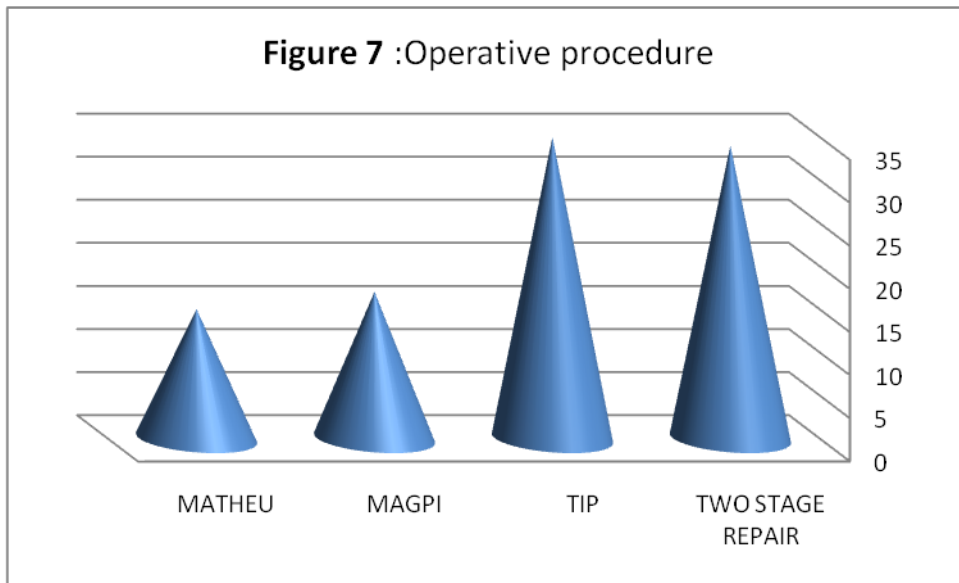
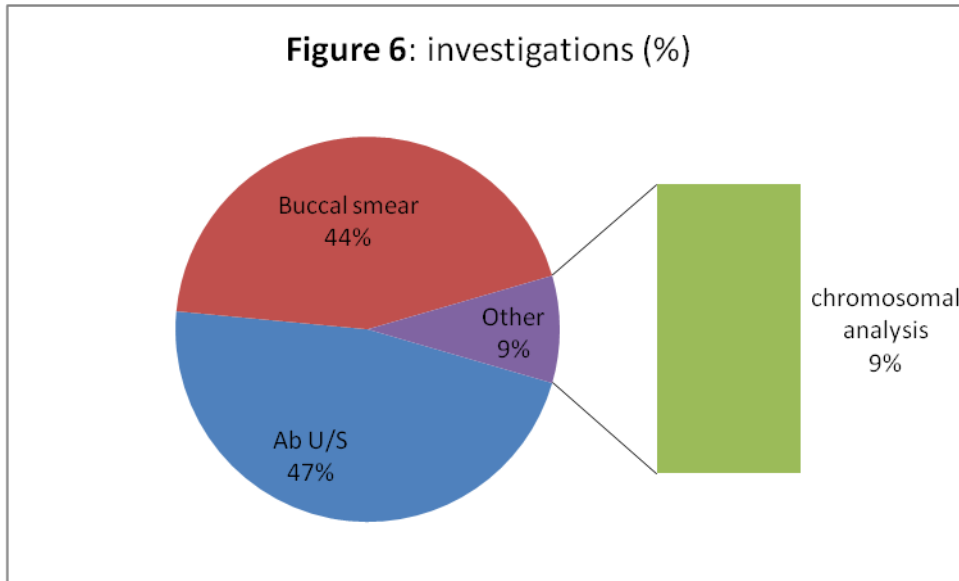
Regarding the 26 patients of TIP; 5 of them (19.2%) developed meatal stenosis, 3 (11.5%) of them developed urethrocutaneous fistula and 2 of them (7.7%) of them developed post operative bleeding. (table7).

6. MANAGEMENT OF COMPLICATIONS

Of the total 38 patients who developed postoperative complication; 36 (94.7%) of them were treated surgically and 2 patients (5.3%) were treated conservatively. (Table 8)







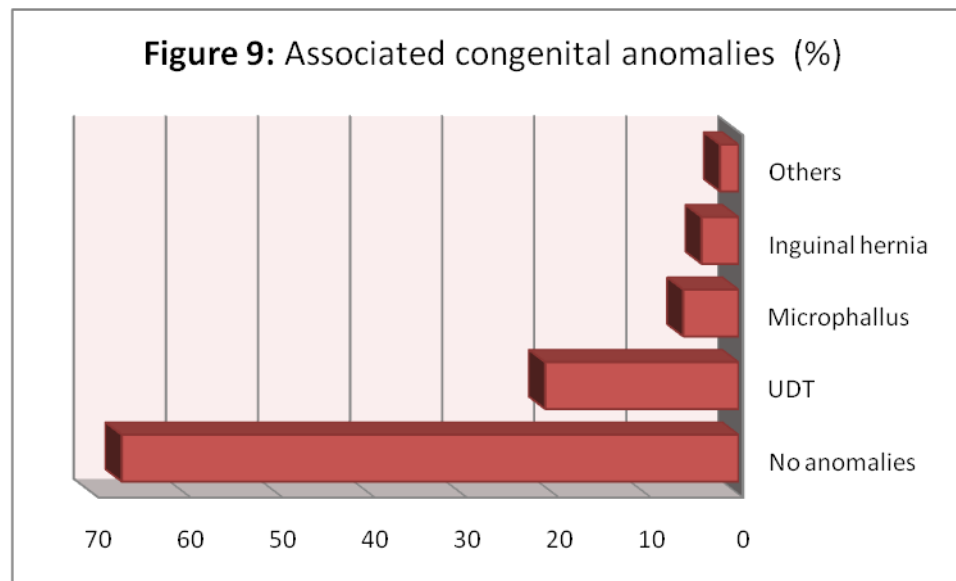
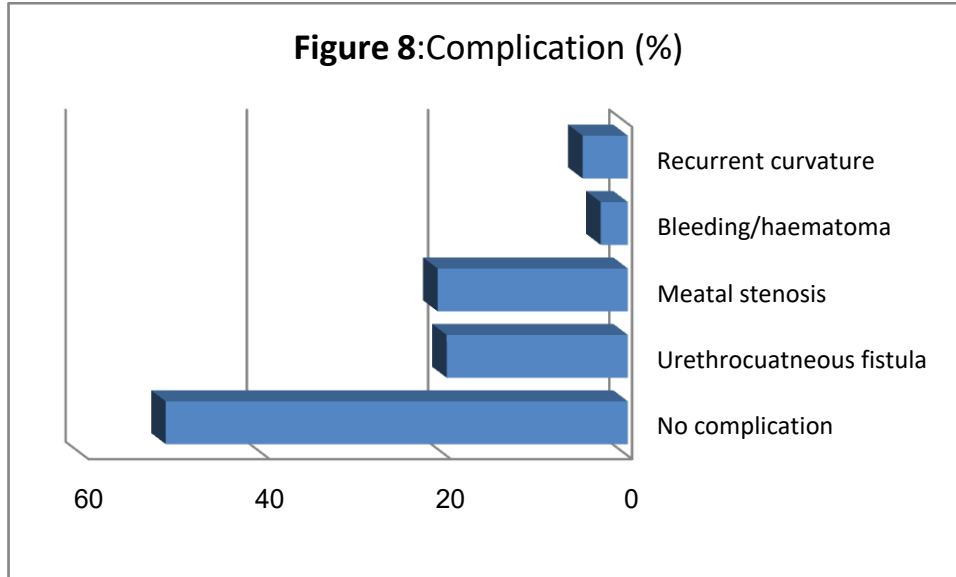


Table 1: patients demographic data.

	No. OF PATIENTS	PERCENT %
Age on presentation:		
-Neonate	21	28
-Infant	13	17.3
-Toddler	12	16
- 4-7 years	29	38.7
- 8-10 years	0	0
Consanguious marriage:		
-Yes	16	21.3
-No	59	78.7
Family history:		
-Yes	8	10.7
-No	67	89.3

Relationship (if +ve F.H):		
-Father	0	0
-Brother	8	100
- 1 st degree	0	0
- 2 nd degree	0	0

Table 2: Clinical findings.

CLINICAL FINDINGS	No. OF PATIENTS	PERCENT %
Penile shaft size:		
- Small	4	5.3
- Adequate	71	94.7
Site of the urethral meatus:		
- glanular	13	17.3
- distal penile	35	46.7
- proximal penile	25	33.3
- MIP		

	2	2.7
Prepuce:		
- Complete	15	20
- Incomplete	60	80
Glans configuration:		
- cleft	18	24
- incompletely cleft	25	33.3
- flat	32	42.7
Chordee:		
- no chordee	50	66.7
- superficial chordee	21	28
- deep chordee	4	5.3
Urethral plate width:		
- < 1 cm	36	48
- > 1cm	39	52
Penile torsion:		
- present	11	14.7
- not present	64	85.3
Penoscrotal transposition:		

- present	4	5.3
- not present	71	94.7

Table 3: Associated congenital anomalies.

ANOMALY	NO. OF PATIENTS	PERCENT %
UDT	16	66.7
Inguinal hernia	3	12.5
Microphallus	4	16.6
PUJ Obstruction	1	4.2
Total	24	100

Table 4: Investigations.

INVESTIGATION	NO. OF PATIENTS	PERCENT %
ABD U/S	17	22.7
BUCCAL SMEAR	16	21.3
CHROMOS. ANALYSIS	3	4
NON	39	52
TOTAL	75	100

Table 5: Operative procedures.

OPERATIVE PROCEDURE	NO. OF PATIENTS	PERCENT %
TIP	26	34.7
TWO STAGE REPAIR	25	33.3
MAGPI	13	17.3
MATHIEU	11	14.7
TOTAL	75	100

Table 6: complications.

Complications	No of patients	% of total patients	% of comp. parients
Urethrocutaneous fistula	15	20	40.5
Meatal stenosis	16	21.3	43.2
Bleeding/haematoma	2	2.7	5.5
Recurrent curvature	4	5.3	10.8
No complication	38	50.7	-
Total	75	100	100

Table 7: Cross-tabulation of complications with the type of operation.

Operation	complications					Total
	no	bleeding/haematoma	meatal stenosis	Urethrocutaneous fistula	Recurrent curvature	
MAGPI	9	0	4	0	0	13
TIP	16	2	5	3	0	26
MATHIEU	4	0	7	0	0	11
2 STAGES REPAIR	9	0	0	12	4	25
Total	38	2	16	15	4	75

Table 8: Management of complications.

TYPE OF MANAGEMENT	NO. OF PATIENTS	PERCENT %
OPERATIVE	36	94.7
CONSERVATIVE	2	5.3
TOTAL	38	100

CHAPTER FOUR

DISCUSSION

The gender of all 75 child enrolled in these study was male. No report of female hypospadias was made of this rare anomaly in which the female urethra opens on the anterior wall of the vagina. (253)

As shown in (table1) 38.7% children were first seen around the age 4-7years. This late presentation can be attributed to the old believe among people in the middle Sudan that anomalies are a Devine event and need not be amended.

In hypospadias where the foreskin is deficient ventrally, it is doomed among people in rural Gezira to "an eagle circumcision" and that such youngsters should be blessed.

It is also observed that those who presented on the early neonatal period (28%) were either cases of severe hypospadias or the parents were educated. (Table 1)

Consanguious marriage was observed in (21.3%) of parents (table 1) which can account for this high sib recurrence rate recorded in this study (10.6%). (Table 1)

Penile shaft size is an important prerequisite for surgery, in this study 4 boys were found to have a relatively small shaft correspond to the normal values for this age (table 2). Again this was observed more frequently among children with severe hypospadias.

Figure three shows that the location of the meatus before orthoplasty, the figures are consistent with those quoted from the literature. (Table 2)

A cryptorchid testis was the most frequently encountered associated anomaly in hypospadiac boys (n=14) of the studied group (table 3, figure9). Both cryptorchidism and hypospadias represent a fetal endocrinopathy involve the testosterone biosynthetic pathway. (Table 3)

In reflecting the findings of our clinical examination on the study group (keeping the order from severe to mild in reviewing) we found that:

On respecting to the penile foreskin (prepuce); it was found to be deficient ventrally (dorsally hooded) in 60 child (80%) and complete in the remaining 15(20%) of them. (Table 2)

Regarding the glans penis configuration; it was found to be flat in 32 case(42.7%), incompletely cleft in 25 case (33.3%) and cleft in the remaining 18 case (24%).(table 2, figure4)

Both above findings were keeping with the literature on their relation to the severity of the hypospadias.

The degree of the chordee is also related proportionally to the severity of hypospadias" the more the proximal hypospadias, the most the severe the chordee" (2) .this is relevant with our findings of 4 cases (5.3%) with deep chordee, 21 (28%) with superficial chordee and 50 (66.7%) with no chordee. (table2, figure 5)

An operative finding (urethral plate width) which predict the type of neourethral formation (250) found to be equal to or more than 1Cm in 39(52%) of the patients, and less in the remaining 36(48%). (table2)

On our study : 11 cases (14.7%) were reported for having a penile torsion, and 4 cases (5.3%) for having a penoscrotal transposition in which the rugated scrotal skin begin lateral to the penis instead of its normal posterior position(253), and both findings are consistent with the more severe proximal hypospadias type. (table2)

In general, the literature does not support routine imaging of the urinary tract with either ultrasonography (136,137), or intravenous urography (136,138) for evaluation of children with isolated hypospadias, particularly when the hypospadiac meatus is middle or anterior in location.

Regarding the investigations were done for evaluation of the patient's condition (apart from that done routinely for fitness assessment) our findings were as follows:

- ❖ Abd U/S was done for 17 patient (22.7%), most of them to locate the testis in cases of impalpable UDT.
- ❖ Buccal smear was done for 16 patients (21.3%) to determine the gender in cases of ambiguous genitalia.

- ❖ Chromosomal analysis was done for 3 patients (4%) for the same purpose. (table4, figure 6)

There is a more than 300 different procedure described in the literature for the hypospadias repair, but the principles are the same. (76)

Concerning choice of the repair procedure type which largely depends on the type of hypospadias and the surgeon's experience and preference' our study revealed the following:

- ❖ TIP procedure "which is more suitable for repair of the hypospadias without chordee (215)" done for 26 patients (34.7%). (table5, figure7)
- ❖ Twenty five patient (33.3%) of the studied group underwent a two stage repair. Group of patients with severe proximal hypospadias, chordee, and a small phallus as well as patients with recurrent hypospadias may benefit from this procedure. (222)
- ❖ For the group of patients with glanular hypospadias and mobile urethra MAGPI is the procedure of choice (219) which was done for 13(17.3%) of our study group.
- ❖ The meatal-based flap technique of Mathieu is the most popular technique for distal hypospadias repair, the only contraindication is the presence of severe chordee distal to the hypospadiac meatus. (216)

In our study 11 patients (14.7%) underwent this procedure. (table5)

Complications after any surgical procedures are possible and these are higher in hypospadias surgery as compared to other reconstructive operations. The reported incidence of complications range from 6 to 30%, varying with the severity of the hypospadias. (254)

Hypospadias repair requires delicate handling of loose and fragile tissue susceptible to edema and infection. Complications depend on the type of hypospadias, surgical technique, size of the penis, age of the child, and experience of the operating surgeon. (254)

Bleeding has been noted as the most common complication of hypospadias repair. This may require addition of a compressive dressing due to persistent oozing. At other times, significant postoperative bleeding may require immediate exploration to identify and treat the source. Hematoma may form as a result of persistent bleeding; if large in size, it may require wound exploration and hematoma evacuation (225). Patients with excessive bleeding and/or hematoma formation, particularly those requiring reoperation, should undergo evaluation for bleeding diathesis/dyscrasias. (193)

A significant hematoma is a potentially dangerous complication which may result in failure of the surgical procedure. Exact incidence of hematoma is not reported in the literature, with only a few cases mentioned in individual articles. (254)

In our study; two cases were reported for having post operative bleeding, both were treated conservatively with successful. (Figure 8 , table 6)

Urethrocutaneous fistula is the commonest reported complication and is often reported by the parent. This can be confirmed on physical examination with or without voiding, or with retrograde injection of dye such as methylene blue. (193)

Incidence of fistula varies from 0 to 23%. Incidence of fistula is less in urethral plate preservation procedures like TIP and onlay flap as compared to inner prepuccial flap and tube urethroplasty. (254)

Fistula may result from, or be associated with, distal stricture or meatal stenosis. Other risk factors include failure to invert all epithelial edges at urethroplasty, devitalization of tissue, and failure to add appropriate second-layer urethroplasty coverage.(223) Also it was found to be significantly higher in the group of patients where neourethra was constructed using 6/0 polyglactine (Vicryl) in a single layer, full-thickness, uninterrupted fashion (16.6%) compared to group of patients in which 7/0 polydioxanone (PDS) was used in the urethral anastomosis performed in a subcuticular, uninterrupted fashion (4.9%).

On our study the reported incidence of the urethrocutaneous fistula was found to be 20% (15 patients) which consistent with the international incidence reported in the literature. (table6, figure 8)

The complication of meatal stenosis is perhaps most commonly caused by technical issues at the time of repair, such as fashioning of the urethral meatus with too narrow a lumen or performance of glanuloplasty too tightly. Urethral (meatal) dilation or meatotomy may be sufficient for the mildest forms of meatal stenosis. However, a more complex distal urethral stricture also involving the meatus may require a more extensive flap procedure. (226)

On our study the incidence was comparatively high, or actually was the highest complication reported in this study 16 patient (21.3%). (table6, figure 8)

Recurrent penile curvature is one of the late-onset complication which has been described by several authors as a complication of orthoplasty performed alone or in conjunction with hypospadias repair. (254)

Farkas reported that a second operation (and sometimes more) was required in approximately 50% of cases of hypospadias and initial severe curvature. (236)

In a more contemporary report, late-onset curvature in patients with hypospadias thought to be caused equally by extensive fibrosis of the reconstructed urethra, corporeal disproportion, or both. (237)

On our study 4 patients (5.3%) developed recurrent curvature. (table6, figure 8)

Of the total 75 patient studied ,incidence of complications recorded in 38 (49.3%) of the patients which reflects a relatively high rate, although the literature does not project any acceptable limit of acute complications but Bhat review an acceptable limit of complications of (<5% in distal hypospadias and <10% in proximal hypospadias).

Two patients treated conservatively, while the other 36 underwent surgical intervention later on for correction of the complication with generally satisfactory results (table 8). In general unless immediate exploration is indicated for bleeding, infection or debridement, reoperation for complication should not be done before 6 months of initial surgery. (254)

Finally, cross tabulation between the operative complications and the type of procedure done to the patient to draw their relationship which found to be as follows:

- ❖ Of total 25 patients underwent two stage repair, 12 of them developed urethrocutaneous fistula and 4 developed recurrent curvature. (table7)

This reflects a high incidence rate of complications in this procedure which usually carried on to repair the cases with severe hypospadias.

- ❖ Twelve patients underwent Mathieu's repair; 7 of them developed meatal stenosis.
- ❖ TIP procedure was the most commonly done (for 26 patients) with a relatively low incidence of complications: 5 meatal stenosis, 3 urethrocutaneous fistula and 2 post operative bleeding. This procedure usually done to repair a mild form of hypospadias. (table7)

These findings are consistent with the literature in the association of a high incidence of complications among the repair of the most severe types of hypospadias.

Conclusions:

- ❖ The high family history can be attributed to Consanguineous marriage.
- ❖ Late presentation is associated with mild forms of hypospadias.
- ❖ Distal penile hypospadias is the commonest type seen in the study group.
- ❖ TIP is the common procedure done.
- ❖ Urethrocutaneous fistula and meatal stenosis are the common complications.

Recommendations:

Hypospadias group is suggested under the umbrella of the Sudan Association of Pediatrics Surgery which can help in:

- ❖ A) Organization sessions on the topic.
- ❖ B) Inviting distinguished guests from abroad for weak Slops.
- ❖ C) Promoting research in the field of hypospadias.

REFERENCES:

- [1] Dominique Salm, Louvain-La-Neuve, 2003, Physical and Psychological Effects Of Hypospadias
- [2] John M Gatti. 2007. Hypospadias.
- [3] Mustarde JC: One-stage correction of distal hypospadias: And other people's fistulae. Br J Plast Surg 1965; 18:413–422.
- [4] Galen (c. 130-201 A.D.) In: Opera Omnia vol. 10. C. G. Ktihn, Leipzig, p 1001
- [5] Johnson T (1634) The works of that famous chirurgion AmbrosePar~, translated out of Latine and compared with the French by Th.Johnson. T. H. Cotes and R. Young, London. Reprinted by Milford, Boston, 1968
- [6] Dionis P (d. 1718) In: K Haeger. The illustrated history of surgery. Harold Starke, London, pp 132, 134
- [7] Cassar P (1974) A medico-legal report of the 16th century from Malta. Med Hist 18(4): 354-359
- [8] Mettauer JP (1842) Practical observations on those malformations of the male urethra and penis, termed hypospadias and epispadias Am J Med Sci 4:43
- [9] Bouisson E (1860) Remarques sur quelques vari6t6s de l'hypospadiaset sur traitement chirurgical qui leur convient. C R AcadSci (Paris) 51:552
- [10] Smith DR (1967) Repair of hypospadias in the pre-school child. A report of 150 cases. J Urol 97:723-730
- [11] Allen TD, Spence HM (1968) The surgical treatment of coronal hypospadias mad related problems. J Urol 100:504-508
- [[12] King LR (1970) Hypospadias - a one stage repair without skin graft based on a new principle: chordee is sometimes produced by skin alone. J Urol 103:660-662

- [13] Duplay S (1874) De l'hypospadias pgrineo-scrotal et son traitement chimrgical. Arch Gen Med 133: 513, 657
- [14] Duplay S (1880) Sur le traitement chimrgical de l'hypospadias et de l'epispadias. Arch Gen Med 145:257
- [15] Duplay S (1880) Sur le traitement chirurgical de l'@ispadias. Bull Soc Chir Paris 6:169
- [16] Lauenstein C (1892) Zur Plastik der Hypospadiie. Arch Klin Chir 43:203
- [17] Edmunds A (1913) An operation for hypospadias. Lancet I: 447
- [18] Blair VP, Brown JB, Hamm WG (1933) The correction of scrotal hypospadias and of epispadias. Surg Gynecol Obstet 57:646
- [19] Blair VP, Byars LT (1938) Hypospadias and epispadias. J Urol 40:814
- [20] Byars LT (1955) A technique for consistently satisfactory repair of hypospadias. Surg Gynecol Obstet 100:184-190
- [21] Beck C (1917) Hypospadias and its treatment. Surg Gynecot Obstet 24:511
- [22] Nesbit RM (1941) Plastic procedure for the correction of hypospadias. J Urol 45:696
- [23] Pancoast (1844) In: Murphy LJT (1972) The history of urology. Charles C. Thomas, Springfield, p 456
- [24] Young HH (1936) Stricture of the prostatico-membranous urethra; newer methods in the management of difficult lesions. Ann Surg 104:267
- [25] Antyl (1st century A.D.) In: Hauben DJ (1984) The history of hypospadias. Acta Chir Plast 26(4): 196-199
- [26] Aegineta P (1844) The seven books of Paulus Aeginata. Sydenham Society, London
- [27] Abulcasis (936-1013) In: Hauben DJ (1984) The history of hypospadias. Acta Chir Plast 26(4): 196
- [28] de Chauliac G (1363) In: Hauben DJ (1984) The history of hypospadias. Acta Chir Plast 26(4): 196
- [29] Lusitanus (1511-1568) In: Hauben DJ (1984) The history of hypospadias. Acta Chir Plast 26(4): 196
- [30] Morgagni JB (1761) In: Murphy LJT (1972) The history of urology. Charles C. Thomas, Springfield, p 453

- [31] Cooper A (1815) In: Hauben DJ (1984) The history of hypospadias. Acta Chit Plast 26(4): 197
- [32] Dupuytren G (1830) In: Murphy LJT (1972) The history of urology. Charles C. Thomas, Springfield, p 454
- [33] Dieffenbach JF (1837) Guérison des fentes congénitales de la verge, de l'hypospadias. Gaz Hebd Med 5:156
- [34] Anger (1874) In: Murphy LJT (1972) The history of urology. Charles C. Thomas, Springfield, p 454
- [35] Wood J (1875) A new operation for the cure of hypospadias. Med Times Gaz I: 114, 242
- [36] Smith ED (1973) A de-epithelised overlap flap technique in the repair of hypospadias. Br J Plast Surg 26: 106-114
- [37] Smith ED (1990) Hypospadias. In: Ashcraft KW (ed) Paediatric urology. Saunders, Philadelphia, pp 353-395
- [38] Beck C (1898) A new operation for balanic hypospadias. NY Med J 67:147
- [39] Ombrédanne L (1923) Précis clinique et opératoire de chirurgie infantile. Masson, Paris
- [40] Browne D (1949) An operation for hypospadias. Proc Roy Soc Med 41:466-468
- [41] Russell RH (1915) The treatment of urethral stricture by excision. Br J Surg 2:375
- [42] Broadbent TR, Woolf RM, Toksu E (1961) Hypospadias – one stage repair. Plast Reconstr Surg 27: 154-159
- [43] Des Prez JD, Persky L, Kiehn CL (1961) One stage repair of hypospadias by island flap technique. Plast Reconstr Surg 28: 405-411
- [44] Duckett JW (1980) Transverse preputial island flap technique for repair of severe hypospadias. Urol Clin North Am 7:423
- [45] Liston R (1840) Practical surgery, 2nd edn. Churchill, London. Quoted in Murphy LJT (1972). The history of urology. C. C. Thomas, Springfield, p 461
- [46] Van Hook W (1896) A new operation for hypospadias. Ann Surg 23:378
- [47] Rochet V (1899) Nouveau procédé pour refaire le canal pénién dans l'hypospadias. Gaz Hebd Med Chit 4:673
- [48] Russell RH (1900) Operation for severe hypospadias. Br Med J ii: 1432
- [49] Mayo CH (1901) Hypospadias. JAMA 36:1157

- [50] Bevan AD (1917) A new operation for hypospadias. JAMA 68: 1032
- [51] Rosenstein P (1929) Ersatz der fehlenden Harnröhre bei der Hypospadias penoscrotalis durch Blasenschleimhaut. Z Urol 23: 627
- [52] Davis DM (1940) The pedicle tube graft in the surgical treatment of hypospadias in the male. Surg Gynecol Obstet 71:790
- [53] Mathieu (1932) Traitement en un temps de l'hypospadias balanique et juxtabalanique. J Chir 39:481
- [54] Ross JE Farmer AW, Lindsey WK (1959) Hypospadias - a review of 230 cases. Plast Reconstr Surg 24:357
- [55] Mustard JC (1965) One stage correction of distal hypospadias and other people's fistulae. Br J Plast Surg 18:413-422
- [56] Badenoch AW (1950) A pull-through operation for impassable traumatic stricture of the urethra. Br J Urol 22:404
- [57] McGowan AJ Jr, Waterhouse K (1964) Mobilisation of the anterior urethra. Bull NY Acad Med 40:776-782
- [58] Duckett JW (1981) MAGPI (meatoplasty and glanuloplasty). Urol Clin North Am 8(3): 573-579
- [59] Moutet (1870) In: Murphy LJT (1972) The history of urology. Charles C. Thomas, Springfield, p 454
- [60] Landerer A (1891) Operation der Hypospadias aus dem Scrotum. Deutsch Z Chir 32:591
- [61] Cecil AB (1936) Congenital malformations of the penis. In: Cabot H (ed) Modern urology, 3rd edn. Lea & Febiger, Philadelphia, p 120
- [62] Nov-Josserand G (1897) Traitement de l'hypospadias: nouvelle méthode. Lyon Méd 85:198
- [63] McIndoe AH (1937) An operation for cure of adult hypospadias. Br Med J I: 385
- [64] Devine CJ, Hortou CE (1961) A one stage hypospadias repair. J Urol 85:166-172
- [65] Tanton P (1909) La transplantation veineuse par l'autoplastie de l'urètre. Presse Méd 17:65
- [66] Tuffier T (1910) A propos des greffes uréthroplastiques. Bull Soc Chir 36:589
- [67] Cantas M (1911) Contribution à l'étude du traitement de l'hypospadias. Sur un nouveau procédé d'autoplastie. Lyon Chir 5:250

- [68] Marion G (1922) Réparation de l'hypospadias balanique. J Urol Med Chit 14:473
- [69] Memmelaar J (1947) Use of bladder mucosa in a one stage repair of hypospadias. J Urol 58:68-73
- [70] Marshall VF, Spellman RM (1955) Construction of urethra in hypospadias using vesical mucosal grafts. J Urol 73:335-342
- [71] Schmieden V (1909) Eine neue Methode zur Operation der Männlichen Hypospadié. Arch Klin Chir 90:748
- [72] Lexer E (1929) Zur Operation der Hypospadié. Zentralbl Chir 56: 414
- [73] Bourque JP (1952) New surgical procedure for cure of scrotal hypospadias - grafting of a male human urethra taken from a fresh cadaver. J Urol 67:698
- [74] Pringle JH (1904) Repair of the urethra by transplantation of the urethra of animals. Ann Surg 40:387
- [75] Legueu In: Murphy LJT (1972) The history of urology. Charles C. Thomas, Springfield, p 460
- [76] Hypospadias Surgery; 2006; by Prof. Ahmed T Hadidi
- [77] Christopher Steidle 'MD.WebMD Medical Reference 'from (The impotence Sourcebook) 1998.
- [78] S.Juskiewenski' Ph. Vaysse' J.Moscovici' S.Hammoudi and E.Bouuissou. Arterial blood supply to the penis' Surgical and Radiological Anatomy. 2005 Jul: 101-107.
- [79] Henry Gray (1825-1861). Anatomy of the Human Body. 1918. Page 968.
- [80] Glenister 'T.W.: The origin and fate of the urethral plate in man. J. Anat. ' 88:413 ' 1954.
- [81] Glenister ' W.W.: A consideration of the processes involved in the development of the prepuce in man. Brit. J. Urol. ' 28: 243 ' 1956.
- [82] Deibert ' G.A.: The separation of the prepuce in the human penis. Anat. Rec. '57:387 ' 1933.
- [83]Hughes, I.A. (2001). Minireview: sex differentiation. Endocrinology, 142, 8, 3281-3287
- [84] Encha-Razavi, F., & Escudier, E. (2000). Embryologie humaine. De la molécule à la clinique (2ème ed.). Paris: Masson.
- [85] Larsen, W.J. (1996). Embryologie humaine. De Boek Université. (Le développement du système uro-génital, pp. 235-279).

- [86] Stephens FD, Smith ED, Hutson JM: Embryogenesis of hypospadias. In Stephens FD (ed): Congenital Anomalies of the Urinary and Genital Tracts. Oxford, UK: Isis Medical Media Ltd, 1996, pp 80–90.
- [87] Glenister JW: The origin and fate of the urethral plate in man. *J Anat* 1954; 288:413–418.
- [89] Kurzrock EA, Baskin LS, Cunha GR: Ontogeny of the male urethra: Theory of endodermal differentiation. *Differentiation* 1999; 64:115–122.
- [90] Hunter RH: Notes on the development of the prepuce. *J Anat* 1935; 70:68–75.
- [91] Baskin LS, Erol A, Li YW, et al: Anatomical studies of hypospadias. *J Urol* 1998; 160:1108–1115; discussion, 1137.
- [92] Aarskog D: Clinical and cytogenetic studies in hypospadias. *Acta Paediatr Scand Suppl* 1970; 203:1–61.
- [93] Yamaguchi T, Kitada S, Osada Y: Chromosomal anomalies in cryptorchidism and hypospadias. *Urol Int* 1991; 47:60–63.
- [94] Sweet RA, Schrott HG, Kurland R, et al: Study of the incidence of hypospadias in Rochester, Minnesota, 1940–1970, and a case-control comparison of possible etiologic factors. *Mayo Clin Proc* 1974; 49:52–58
- [95] Khuri FJ, Hardy BE, Churchill BM: Urologic anomalies associated with hypospadias. *Urol Clin North Am* 1981; 8:565–571.
- [96] Sorber M, Feitz WF, de Vries JD: Short- and mid-term outcome of different types of one-stage hypospadias corrections. *Eur Urol* 1997; 32:475–479.
- [97] Jones KL: *Smith's Recognizable Patterns of Human Malformation*, 5th ed, vol 1. Philadelphia, WB Saunders, 1997.
- [98] Aarskog D: Intersex conditions masquerading as simple hypospadias. *Birth Defects Original Article Series* 1971; 7:122–130.
- [99] Rajfer J, Walsh PC: The incidence of intersexuality in patients with hypospadias and cryptorchidism. *J Urol* 1976; 116:769–770.
- [100] Borer JG, Nitti VW, Glassberg KI: Mixed gonadal dysgenesis and dysgenetic male pseudohermaphroditism. *J Urol* 1995; 153:1267–1273.
- [101] Albers N, Ulrichs C, Gluer S, et al: Etiologic classification of severe hypospadias: Implications for prognosis and management [see comments]. *J Pediatr* 1997; 131:386-392.
- [102] Smith EP, Wacksman J: Evaluation of severe hypospadias. (Editorial; comment.) *J Pediatr* 1997; 131:344–346.

- [103] Kaefer M, Diamond DA, Hendren WH, et al: The incidence of intersexuality in children with cryptorchidism and hypospadias: Stratification based on gonadal palpability and meatal position. *J Urol* 1999; 162:1003–1006;
- [104] Eberle, J., Überreiter, S., Radmayr, C., Janetschek, G., Marberger, H., & Bartsch, G. (1993). Posterior hypospadias: long-term followup after reconstructive surgery in the male direction. *Journal of Urology*, 150, 1474-1477.
- [105] Winslow BH, Devine CJ Jr: Principles in repair of hypospadias. *Semin Pediatr Surg* 1996; 5: 41–48.
- [106] Sweet RA, Schrott HG, Kurland R, et al: Study of the incidence of hypospadias in Rochester, Minnesota, 1940–1970, and a case-control comparison of possible etiologic factors. *Mayo Clin Proc* 1974; 49:52–58.
- [107] Baskin LS: Hypospadias and urethral development. *J Urol* 2000; 163:951–956.
- [108] De Sy, W.A. (1996a).Quelle technique pour quel hypospadias? *Annales d’Urologie*, 30, 160-166.
- [109] Fredell, L., Kockum, I., Hansson, E., Holmner, S., Lundquist, L., Läckgren, G., Pedersen, J., Stenberg, A., Westbacke, G., & Nordenskjöld, A. (2002).Heredity of hypospadias and the significance of low birth weight.*Journal of Urology*,167: 1423-1427.
- [110] Silver, R.I., & Russel, D.W. (1999). 5-alpha-reductase type 2 mutations are present in some boys with isolated hypospadias. *Journal of Urology*, 162, 1142-1145.
- [111] Morgan, E .A., Nguyen, S.B., Scott, V., & Adler, H.S. (2003). Loss of Bmp7 and Fgf8 in Hoxa13-mutant mice causes hypospadias. *Development*, 130, 3095-3109.
- [112] Devine CJ Jr, Horton CE: Hypospadias repair. *J Urol* 1977; 118: 188–193.
- [113] Griffin JE, Wilson JD: Syndromes of androgen resistance. *Hosp Pract (Off Ed)* 1987; 22:159–164.
- [114] Hughes, I.A. (2001). Minireview: sex differentiation. *Endocrinology*, 142, 8, 3281-3287.
- [115] Hughes, I.A. (2001). Minireview: sex differentiation. *Endocrinology*, 142, 8, 3281-3287.
- [116] Goldman AS, Bongiovanni AM: Induced genital anomalies. *Ann N Y Acad Sci* 1967; 142:755–767.
- [117] Macnab AJ, Zouves C: Hypospadias after assisted reproduction incorporating in vitro fertilization and gamete intrafallopian transfer. *Fertil Steril* 1991; 56:918–922.118d’un hypospadias moyen et sévère. *Annales d’Urologie*, 30, 187-191.

- [118] Weber, R.F.A., Pierik, F.H., Dohle, G.R., & Burdof, A. (2002). Environmental influences on male reproduction. *British Journal of Urology International*, 89, 143-148.
- [119] Toppari, J. (2002). Environmental endocrine disruptors and disorders of sexual differentiation. *Seminars in Reproductive Medicine*, 20, 305, 312.
- [120] Sultan, C., Balaguer, P., Terouanne, B., Goerget, V., Paris, F., Jeandel, C., Lumbroso, S., & Nicolas, J. (2001). Environmental xenoestrogens, antiandrogens, and disorders of male sexual differentiation. *Molecular and Cellular endocrinology*, 178, 99-105.
- [121] Rittler, M., & Castilla, E.E. (2002). Endocrine disruptors and congenital anomalies. *Cadernos de Saúde Pública*, 18, 421-428.
- [122] Santti, R., Makela, S., Strauss, L., Korkman, J., & Kostian, M.L. (1998). Phytoestrogens: potential endocrine disruptors in males. *Toxicology and Industrial Health*, 14, 223-237.
- [123] Mettauer JP: Practical observations in those malformations of the male urethra and penis, termed hypospadias and epispadias, with an anomalous case. *Am J Med Sci* 1842; 4:43–58.
- [124] Van Hook W: A new operation for hypospadias. *Ann Surg* 1896; 23:378–393
- [125] Hunter RH: Notes on the development of the prepuce. *J Anat* 1935; 70:68–75.
- [126] Baskin, L.S., Himes, K., & Colborn, T. (2001). Hypospadias and endocrine disruption: is there a connection? *Environmental Health Perspectives*, 109, 1175-1182.
- [127] Smith ED: The history of hypospadias. *Pediatr Surg Int* 1997; 12:81–85.
- [128] Smith DR: Hypospadias: Its anatomic and therapeutic considerations. *J Int Coll Surg* 1955; 24.
- [129] Creevy CD: The correction of hypospadias: A review. *Urol Surv* 1958; 8:2–47.
- [130] Glenister JW: The origin and fate of the urethral plate in man. *J Anat* 1954; 288:413–418.
- [131] Van Hook W: A new operation for hypospadias. *Ann Surg* 1896; 23:378–393.
- [132] Kaplan GW, Lamm DL: Embryogenesis of chordee. *J Urol* 1975; 114:769– 772.
- [133] Bellinger MF: Embryology of the male external genitalia. *Urol Clin North Am* 1981; 8:375–382.
- [134] Duckett JW, Devine CJ Jr, Mitchell ME, et al: Controversies in hypospadias surgery. *Dial Pediatr Urol* 1996; 19:8.

- [135] Ahmed T.Hadidi.Amir F.Azmy (2004). Hypospadias surgery..
- [136] Cerasaro TS, Brock WA, Kaplan GW: Upper urinary tract anomalies associated with congenital hypospadias: Is screening necessary? J Urol 1986; 135:537–538.
- [137] Davenport M, MacKinnon AE: The value of ultrasound screening of the upper urinary tract in hypospadias. Br J Urol 1988; 62:595–596.
- [138] McArdle F, Lebowitz R: Uncomplicated hypospadias and anomalies of upper urinary tract: Need for screening? Urology 1975; 5:712–716.
- [139] Retik AB: Proximal hypospadias. In Marshall FF (ed): Textbook of Operative Urology. Philadelphia, WB Saunders, 1996, pp 977–984.
- [140] .Sorensen HR: Hypospadias with special reference to aetiology. Copenhagen, Ejnar Munksgaard, 1953.
- [141] Campbell MF: Hypospadias: When to operate. Am J Surg 1947; 74:795– 796.
- [142] Paulozzi LJ, Erickson JD, Jackson RJ: Hypospadias trends in two US surveillance systems. Pediatrics 1997; 100:831–834.
- [143] Dolk, H. (1998). Rise in prevalence of hypospadias. Lancet, 351, 770.
- [144] Harrison, P.T.C., Holmes, P., & Humprey, C.D.N. (1997). Reproductive health in humans and wildlife: are adverse trends associated with environmental chemical exposure? The Science of the Total Environment, 205, 97-106.
- [145] Wakefield, J. (2001). Bad news for boys. Linking hypospadias and endocrine disruptors. Environmental Health Perspectives, 109, A 542.
- [146] Bauer SB, Bull MJ, Retik AB: Hypospadias: A familial study. J Urol 1979; 121:474–477.
- [147] Roberts CJ, Lloyd S: Observations on the epidemiology of simple hypospadias. Br Med J 1973; 1:768–770.
- [148] Bukowski, P., & Zeman, P.A. (2001). Hypospadias: of concern but correctable. Contemporary Pediatrics, 2, 89.
- [149] De Sy, W.A. (1996b). Le lambeau préputial transversal pédiculé pour lacorrection
- [150] Zaontz, M.R., & Packer, M.G. (1997). Abnormalities of the external genitalia. Pediatric Clinics of North America, 44, 1267-1297.
- [151] Sheldon, C.A., & Duckett, J.W. (1987). Hypospadias. Pediatric Clinics of North America, 34, 1259-1271.

- [152] Baskin, L.S. (2000). Hypospadias. Anatomy, embryology, and reconstructive techniques. *Brazilian Journal of Urology*, 26, 621-629.
- [153] Koff SA, Jayanthi VR: Preoperative treatment with human chorionic gonadotropin in infancy decreases the severity of proximal hypospadias and chordee [see comments]. *J Urol* 1999; 162:1435–1439.
- [154] Shima H, Ikoma F, Yabumoto H, et al: Gonadotropin and testosterone response in prepubertal boys with hypospadias. *J Urol* 1986; 135:539–542.
- [155] Perovic S, Vukadinovic V: Onlay island flap urethroplasty for severe hypospadias: A variant of the technique. *J Urol* 1994; 151:711–714.
- [156] Gearhart JP, Jeffs RD: The use of parenteral testosterone therapy in genital reconstructive surgery. *J Urol* 1987; 138:1077–1078.
- [157] Belman AB: Hypospadias update. *Urology* 1997; 49:166–172.
- [158] Stock JA, Scherz HC, Kaplan GW: Distal hypospadias. *Urol Clin North Am* 1995; 22:131–138.
- [159] Monfort G, Lucas C: Dihydrotestosterone penile stimulation in hypospadias surgery. *Eur Urol* 1982; 8:201–203.
- [160] McMahon DR, Kramer SA, Husmann DA: Micropenis: Does early treatment with testosterone do more harm than good? *J Urol* 1995; 154:825–829.
- [161] Bin-Abbas B, Conte FA, Grumbach MM, et al: Congenital hypogonadotropic hypogonadism and micropenis: Effect of testosterone treatment on adult penile size: why sex reversal is not indicated. *J Pediatr* 1999; 134:579–583.
- [162] Sutherland RS, Kogan BA, Baskin LS, et al: The effect of prepubertal androgen exposure on adult penile length. *J Urol* 1996; 156:783–787; discussion, 787.
- [163] Baskin LS, Sutherland RS, DiSandro MJ, et al: The effect of testosterone on androgen receptors and human penile growth. *J Urol* 1997; 158:1113–1118.
- [164] Elbakry, A. (2001). Management of urethrocutaneous fistula after hypospadias repair: 10 years' experience. *British Journal of Urology International*, 88, 590-595.
- [165] Coleman, J.W. (1981). The bladder mucosal graft technique for hypospadias repair. *Journal of Urology*, 125, 708-710.
- [166] Hodgson, N.B. (1981). Hypospadias. *Journal of Urology*, 125, 711.

- [167] American Academy of Pediatrics (1975). The timing of elective surgery on the genitalia of male children with particular reference to undescended testicles and hypospadias. *Pediatrics*, 56, 479-483.
- [168] Belman, B.A., & Kass, E.J. (1982). Hypospadias repair in children less than 1 year old. *Journal of Urology*, 128, 1273-1274.
- [169] Manley, C.B., & Epstein, E.S. (1981). Early hypospadias repair. *Journal of Urology*, 125, 698-700.
- [170] Roberston, M., & Walker, D. (1975). Psychological factors in hypospadias repair. *Journal of Urology*, 113, 698, 700.
- [171] Lepore, A.G., & Kesler, R.W. (1979). Behavior of children undergoing hypospadias repair. *Journal of Urology*, 128, 68-70.
- [172] Schultz, J.R., Klykylo, W.M., & Wacksman, J. (1983). Timing of elective hypospadias repair in children. *Pediatrics*, 7, 342-351.
- [173] American Academy of Pediatrics (1996). Timing of elective surgery on the genitalia of male children with particular reference to the risks, benefits, and psychological effects of surgery and anesthesia. *Pediatrics*, 97, 590-594.
- [174] Paparel, P., Mure, P.Y., Margarian, M., Feyaerts, A., & Mouriquand, P. (2001). Approche actuelle de l'hypospade chez l'enfant. *Progrès en Urologie*, 11, 741-751.
- [175] Chhibber AK, Perkins FM, Rabinowitz R, et al: Penile block timing for postoperative analgesia of hypospadias repair in children. *J Urol* 1997; 158:1156–1159.
- [176] Winslow BH, Devine CJ Jr: Principles in repair of hypospadias. *Semin Pediatr Surg* 1996; 5:41–48.
- [177] Zaontz MR: Nuances of hypospadias. *Probl Urol* 1990; 4:705–721.
- [178] Jordan GH: Techniques of tissue handling and transfer. *J Urol* 1999; 162:1213–1217.
- [179] Wacksman J: Repair of hypospadias using new mouth-controlled microscope. *Urology* 1987; 29:276–278.
- [180] Shapiro SR: Hypospadias repair: Optical magnification versus Zeiss reconstruction microscope. *Urology* 1989; 33:43–46.
- [181] Hakim S, Merguerian PA, Rabinowitz R, et al: Outcome analysis of the modified Mathieu hypospadias repair: Comparison of stented and unstented repairs. *J Urol* 1996; 156:836–838.
- [182] Ulman I, Erikci V, Avanoğlu A, et al: The effect of suturing technique and material on complication rate following hypospadias repair. *Eur J Pediatr Surg* 1997; 7:156–157.

- [183] DiSandro M, Palmer JM: Stricture incidence related to suture material in hypospadias surgery. *J Pediatr Surg* 1996; 31:881–884.
- [184] McCormack M, Homsy Y, Laberge Y: "No stent, no diversion": Mathieu hypospadias repair. *Can J Surg* 1993; 36:152–154.
- [185] Demirbilek S, Atayurt HF: One-stage hypospadias repair with stent or suprapubic diversion: Which is better? *J Pediatr Surg* 1997; 32:1711–1712.
- [186] Steckler RE, Zaontz MR: Stent-free Thiersch-Duplay hypospadias repair with the Snodgrass modification. *J Urol* 1997; 158:1178–1180.
- [187] Cromie WJ, Bellinger MF: Hypospadias dressings and diversions. *Urol Clin North Am* 1981; 8:545–558.
- [188] De Sy WA, Oosterlinck W: Silicone foam elastomer: A significant improvement in postoperative penile dressing. *J Urol* 1982; 128:39–40.
- [189] De Sy WA, Oosterlinck W: Silicone foam elastomer: A significant improvement in postoperative penile dressing. *J Urol* 1982; 128:39–40.
- [190] McLorie GA, Joyner BD, Bagli DJ, et al: A prospective randomized clinical trial to evaluate methods of postoperative care in hypospadias. *Pediatrics* 1999; 104(suppl): 813A.
- [191] Van Savage JG, Palanca LG, and Slaughenhaupt BL: A prospective randomized trial of dressings versus no dressings for hypospadias repair. *J Urol* 2000; 164:981–983.
- [192] Stock JA, Kaplan GW: Ketoconazole for prevention of postoperative penile erection. *Urology* 1995; 45:308–309.
- [193] 222. Horton CE Jr, Horton CE: Complications of hypospadias surgery. *Clin Plast Surg* 1988; 15:371–379.
- [194] Bologna RA, Noah TA, Nasrallah PF, et al: Chordee: Varied opinions and treatments as documented in a survey of the American Academy of Pediatrics, Section of Urology. *Urology* 1999; 53:608–612.
- [195] Gittes RF, McLaughlin AP: Injection technique to induce penile erection. *Urology* 1974; 4:473–474.
- [196] Perovic S, Djordjevic M, Djakovic N: Natural erection induced by prostaglandin-E1 in the diagnosis and treatment of congenital penile anomalies. *Br J Urol* 1997; 79:43–46.
- [197] Culp OS: Struggles and triumphs with hypospadias and associated anomalies: Review of 400 cases. *J Urol* 1966; 96:339–351.
- [198] Nesbit RM: Plastic procedure for correction of hypospadias. *J Urol* 1941; 45:699–702.

- [199] Udall DA: Correction of 3 types of congenital curvatures of the penis, including the first reported case of dorsal curvature. *J Urol* 1980; 124:50–52.
- [200] Perovic SV, Djordjevic ML, and Djakovic NG: A new approach to the treatment of penile curvature. *J Urol* 1998; 160:1123–1127.
- [201] Baskin LS, Lue TF: The correction of congenital penile curvature in young men. *Br J Urol* 1998; 81:895–899.
- [202] Koff SA, Eakins M: The treatment of penile chordee using corporeal rotation. *J Urol* 1984; 131:931–932.
- [203] Devine CJ Jr, Horton CE: Use of dermal graft to correct chordee. *J Urol* 1975; 113:56–58.
- [204] Perlmutter AD, Montgomery BT, Steinhardt GF: Tunica vaginalis free graft for the correction of chordee. *J Urol* 1985; 134:311–313.
- [205] Jordan GH: Penile reconstruction, phallic construction, and urethral reconstruction. *Urol Clin North Am* 1999a; 26:1–13, vii.
- [206] Retik AB, Mandell J, Bauer SB, et al: Meatal based hypospadias repair with the use of a dorsal subcutaneous flap to prevent urethrocutaneous fistula. *J Urol* 1994; 152: 1229–1231.
- [207] Kirkali Z: Tunica vaginalis: An aid in hypospadias surgery. *Br J Urol* 1990; 65:530–532.
- [208] Snow BW: Use of tunica vaginalis to prevent fistulas in hypospadias surgery. *J Urol* 1986; 136:861–863.
- [209] Kass EJ: Dorsal corporeal rotation: An alternative technique for the management of severe chordee. *J Urol* 1993; 150:635–636.
- [210] Yerkes EB, Adams MC, Miller DA, et al: Y-to-I wrap: Use of the distal spongiosum for hypospadias repair. *J Urol* 2000; 163:1536–1538; discussion, 1538–1539.
- [211] Devine CJ Jr, Horton CE: Hypospadias repair. *J Urol* 1977; 118:188–193.
- [212] Sensöz ö, Celebioglu S, Baran CN, et al: A new technique for distal hypospadias repair: Advancement of a distally deepithelialized urethrocutaneous flap. *Plast Reconstr Surg* 1997; 99:93–98; discussion, 99.
- [213] Byars LT: Functional restoration of hypospadias deformities: With a report of 60 completed cases. *Surg Gynecol Obstet* 1951; 92:149–154.
- [214] Thiersch C: Ueber die entstehungsweise und operative behandlung der epispadie. *Arch Heilkunde* 1869; 10:20–35.

- [215] Borer JG, Bauer SB, Peters CA, et al: Tubularized incised plate urethroplasty, expanded use in primary and repeat surgery for hypospadias. *J Urol*.2001; 165:581. [216] Hypospadias Surgery, Art and Science. Heidelberg, Springer Verlag, 2004).
- [217] Broadbent TR, Woolf RM, Toksu E: Hypospadias: one stage repair. *Plast Reconst Surg*.1961; 27:154.
- [218] Dukett JW Jr:Transverse Preputial Island flap technique for repair of severe hypospadias.*Urol Clin North Am*.1980;7:423-430.
- [219] Arap S;Mitre AL;de goes GM:Modified meatal advancement and glanuloplasty pair of distal hypospadias. *J Urol*.1984; 131:1140-1141.
- [220] Baskin LS;Dukett JW;Ueoka K,et al :changing concepts of hypospadias curvature lead to more onlay island flap procediures.*J Urol*.1994;151:191196.
- [221] Brown D: An operation for hypospadias.*Proc R Soc Med*.1949; 41:466-468.
- [222] Braka A: Hypospadias repair:the two-stage alternative.*Br J Urol*.1995a;76[Suppl]: 31-41.
- [223] Duckett JW, Kaplan GW, Woodard JR, et al: Panel: Complications of hypospadias repair. *Urol Clin North Am* 1980; 7:443–454.
- [224] Retik AB, Keating M, Mandell J: Complications of hypospadias repair. *Urol Clin North Am* 1988; 15:223–236.
- [225] Elbakry A, Shamaa M, Al-Atrash G: An axially vascularized meatal-based flap for the repair of hypospadias [see comments]. *Br J Urol* 1998; 82:698–703.
- [226] De Sy WA: Aesthetic repair of meatal stricture. *J Urol* 1984; 132:678–679.
- [227] Belman AB: De-epithelialized skin flap coverage in hypospadias repair. *J Urol* 1988; 140:1273–1276.
- [228] Churchill BM, van Savage JG, Khoury AE, et al: The dartos flap as an adjunct in preventing urethrocutaneous fistulas in repeat hypospadias surgery. *J Urol* 1996; 156:2047–2049.
- [229] Cecil AB: Repair of hypospadias and urethral fistula. *J Urol* 1946; 56:237–242.
- [230] Goldstein HR, Hensle TW: Simplified closure of hypospadias fistulas. *Urology* 1981; 18:504–505.
- [231] Schreiter F, Noll F: Mesh graft urethroplasty using split thickness skin graft or foreskin. *J Urol* 1989; 142:1223–1226.
- [232] Ahmed S, Gough DC: Buccal mucosal graft for secondary hypospadias repair and urethral replacement. *Br J Urol* 1997; 80:328–330.

- [233] Baskin LS, Duckett JW: Mucosal grafts in hypospadias and stricture management. AUA Update Series 1994; 13:270–275.
- [234] Zaontz MR, Kaplan WE, Maizels M: Surgical correction of anterior urethral diverticula after hypospadias repair in children. Urology 1989; 33:40–42.
- [235] Aigen AB, Khawand N, Skoog SJ, et al: Acquired megalourethra: An uncommon complication of the transverse preputial island flap urethroplasty. J Urol 1987; 137:712–713.
- [236] Farkas LG: Hypospadias: Some causes of recurrence of ventral curvature of the penis following the straightening procedure. Br J Plast Surg 1967; 20:199–203.
- [237] Vandersteen DR, Husmann DA: Late onset recurrent penile chordee after successful correction at hypospadias repair. J Urol 1998; 160:1131–1133; discussion, 1137.
- [238] Horton CE, Devine CJ Jr: A one-stage repair for hypospadias cripples. Plast Reconstr Surg 1970; 45:425–430.
- [239] Sandberg DE, Meyer-Bahlburg HF, Yager TJ, et al: Gender development in boys born with hypospadias. Psychoneuroendocrinology 1995; 20:693–709.
- [240] Eberle J, Uberreiter S, Radmayr C, et al: Posterior hypospadias: Long-term followup after reconstructive surgery in the male direction. J Urol 1993; 150:1474–1477.
- [241] Mureau MA, Slijper FM, Nijman RJ, et al: Psychosexual adjustment of children and adolescents after different types of hypospadias surgery: A norm-related study. J Urol 1995a; 154:1902–1907.
- [242] Mureau MA, Slijper FM, van der Meulen JC, et al: Psychosexual adjustment of men who underwent hypospadias repair: A norm-related study. J Urol 1995b; 154:1351–1355.
- [243] Mureau MA, Slijper FM, Slob AK, et al: Psychosocial functioning of children, adolescents, and adults following hypospadias surgery: A comparative study. J Pediatr Psychol 1997; 22:371–387.
- [244] Bracka A: Sexuality after hypospadias repair. BJU Int 1999; 83(suppl. 3):29–33.
- [245] Gutierrez Segura C: Urine flow in childhood: a study of flow chart parameters based on 1,361 uroflowmetry tests. J Urol 1997; 157:1426–1428
- [246] Szabo L, Fegyverneki S: Maximum and average urine flow rates in normal children: The Miskolc nomograms. Br J Urol 1995; 76:16–20.
- [247] Garibay JT, Reid C, and Gonzalez R: Functional evaluation of the results of hypospadias surgery with uroflowmetry. J Urol 1995; 154:835–836.

- [248] Jayanthi VR, McLorie GA, Khoury AE, et al: Functional characteristics of the reconstructed neourethra after island flap urethroplasty [see comments]. *J Urol* 1995; 153:1657–1659
- [249] Malyon AD, Boorman JG, Bowley N: Urinary flow rates in hypospadias. *Br J Plast Surg* 1997; 50:530–535.
- [250] Svensson J, Berg R: Micturition studies and sexual function in operated hypospadiacs. *Br J Urol* 1983; 55:422–426.
- [251] Berg R, Svensson J, Astrom G: Social and sexual adjustment of men operated for hypospadias during childhood: A controlled study. *J Urol* 1981; 125:313–317.
- [252] Woodhouse CR: The sexual and reproductive consequences of congenital genitourinary anomalies. *J Urol* 1994; 152:645–651.
- [253] Mustard6 JC, plastic surgery in infancy & childhood, hypospadias, Edenburg, 2nd edition: Churchling Livingstone 1979:445.
- [254] Bhat A, Mandal AK. Acute postoperative complications of hypospadias repair. *Indian J Urol* [serial online] 2008 [cited 2009 Jul 6]; 24:241-8.

Hypospadias in Sudanese:**Management & complications in GNCPS**

Date...../...../.....

No.....

Personal data

1- Age: A) neonate B) infant C) toddler D) 4 —7 y E) 8 — 10 y

1- Contagious marriage: A) yes B) no

3- F.H. of similar condition: A) yes B) no

If yes: 3b- A) father B) brother C) 1st degree D) 2nd degree

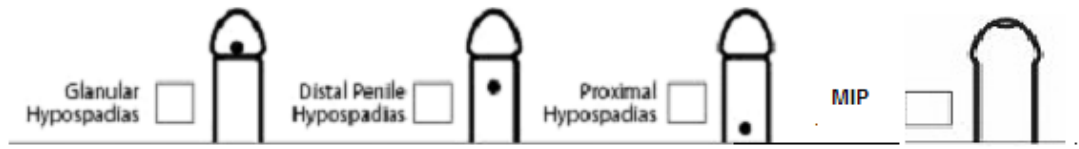
Clinical findings

4- Penile shaft size: A) small B) adequate

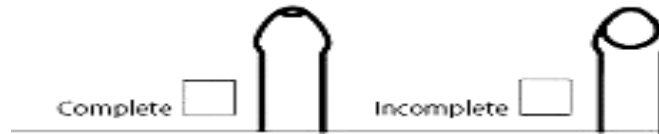5- Associated anomalies:

A) U.D.T. B) Micro phallus C) Inguinal hernia

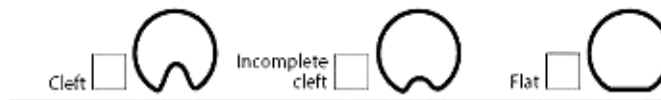6- Site of urethral meatus (before chordee correction):



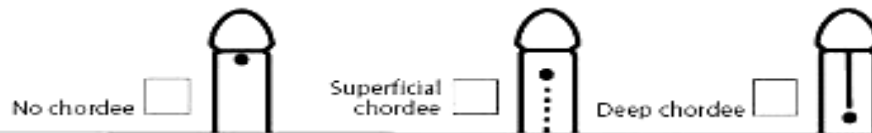7- Prepuce:



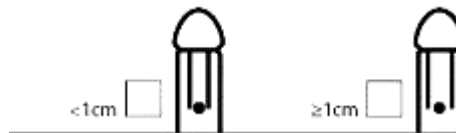
8- Glans:



9- Chordee:



10- Urethral plate width:



11- Penile torsion:



12- Scrotal transposition



13- Investigations: A) USS abd. B) Buccal smear C) Chromosomal analysis

14-Operative procedure:

A) MAGPI

B) TYP

C) V-Y

- D) LBF E) TIP F) Onlay flap G) Docket
- H) Mathieu I) Denis Brown J) two stages repair K) others
- 15-Complications:** A) bleeding/hematoma B) meatal stenosis C) U.C fistula
- D) Urethral diverticulum E) infection F) Recurrent Curvature
- G) Repair breakdown H) Hyposp. cripples I) others

16-Management of complications:

A) CONSERVATIVE

B) OPERATIVE:

1. Type of procedure.....
2. Time.....
3. Outcome.....



A photo showing an anterior view of the GNCPS building