



Journal Homepage: - www.journalijar.com

INTERNATIONAL JOURNAL OF ADVANCED RESEARCH (IJAR)

Article DOI: 10.21474/IJAR01/11023

DOI URL: <http://dx.doi.org/10.21474/IJAR01/11023>



RESEARCH ARTICLE

OPEN REPAIR OF MASSIVE ROTATOR CUFF MUSCLE TEARS

Dr. Mustafa Elsagair^{1,2}, Dr. Wisamabuzaid^{1,2}, Dr. Allawafa^{1,3} and Dr. Ahmed Al Kabti^{1,2}

1. Aljazeera Orthopedic Hospital.
2. Misurata Medical Centre.
3. Misurata Cancer Centre.

Manuscript Info

Manuscript History

Received: 18 March 2020

Final Accepted: 20 April 2020

Published: May 2020

Abstract

Background open approach has been considered for years the good standard for rotator cuff repairs. Nevertheless, the rate of tendon-to-bone healing, and that of cuff re-tear, still remains unclear. At a mean follow-up of 31 months, twenty three open repairs of massive rotator cuff tears yielded good and excellent clinical results despite a re-tear rate of 41%. Patients with a re-tear had improvement over the preoperative state, but those with a structurally intact repair had a substantially better result. The purposes of this study were to determine the clinical and structural long-term results after open repair of massive rotator cuff tears in patients who had been examined with the same, standardized methodology at follow up evaluation and to identify additional problems and the functional outcome and rate of re-tears after open repair of large and massive tears of RCT.

Methods: Between 2015 and 2018, 25 shoulders (25 patients) with a mean age of 53 years (range, 35-71) and a large or massive cuff tear were repaired with an open procedure. At a minimum of 31 months postoperatively (23 patients) underwent functional evaluation and US investigation of cuff integrity. Inclusion criteria at the time of surgery; 25 patients, 10 men and 15 women, attended a follow-up clinic at a mean of 31 months (14 to 48). Two patients were lost to follow up and were not included in the analysis. Exclusion criteria: previous operation, fracture or infection on the affected shoulder, or moderate to severe glenohumeral osteoarthritis. The indication for surgery was in all cases a painful shoulder with ongoing functional impairment after an unsuccessful period of physical therapy of at least 3 months. At a mean follow-up interval of 31 months, twenty-three of the patients returned for a review and were examined clinically, radiographically, and evaluated through using of UCLA Shoulder Score (the University of California at Los Angeles Shoulder Score). and with ultrasound imaging with use of a methodology identical to that used at 31 months.

Results: eighteen of the twenty-three patients remained very satisfied or satisfied with the result. The mean subjective shoulder value was 78%. The mean UCLA score improved from 12.2 before operation to 29.8 postoperative. The re-tear rate was 41% but not affect the significant improvement of the patient post operative, infection

rate was just in one case superficial wound infection), two patient with moderate satisfaction and two patient unimproved post operative)(

Discussion: Our results suggest that large and massive rotator cuff tears treated with open technique using with (5-mm metal bone anchors-G4 Superanchors(DePuyMitek, Raynham, MA) with double-loaded No. 2 Ethibond sutures) have a very satisfactory clinical outcome, despite a significant re-tear rate.

Conclusion: open repair of massive RCTs may result in a good clinical outcome and significant improvement and return to daily activity in a number of patients despite a high rate of recurrent or residual tears.

Copy Right, IJAR, 2020,. All rights reserved.

..... **Introduction:-**

Rotator cuff tears are one of the most common causes of shoulder pain and disability in the upper extremity. With old and young population, treatment of full-thickness rotator cuff tears has become a common problem in facing orthopedic .

Rotator cuff pathology is a common problem in old age. The incidence of rotator cuff tear increases increases with age is multifactorial and it has been mainly attributed to chronic attritional changes from impingement in old age

Rotator cuff injury can occur in younger patients due to trauma .

The patients with rotator cuff tear may have mild shoulder pain with slight loss of function or may even be asymptomatic

In some patients the symptoms can be severe progressive shoulder pain, and frequently associated with night pain and severe disability in elevating the arm . This is especially true in case of severe rotator cuff tear

Operative management of rotator cuff tear is usually required in patients with symptoms refractory to a conservative rehabilitation program

Large tears are frequently associated with pain, weakness and persistent functional disability and are incompatible with heavy manual work in middle-aged patients. Most massive rotator cuff tears show an unfavorable outcome after conservative management .

Partial repair, simple decompression and debridement, and conservative management also may be considered in non massive RCTs. Massive RCTs have been traditionally associated with a poor prognosis, but surgical treatment may actually provide high rates of achievement The goal of rotator cuff repair is to reduce pain and improve function with increased shoulder strength and range of motion (ROM). Optimal repair of the rotator cuff includes achievement of high fixation strength, minimal gap formation and maintenance of mechanical stability under cyclic loading, and proper healing of tendon to bone

Massive rotator cuff tears, defined as tears with detachment of at least two complete tendons, have an unfavorable treatment history, and repair is technically difficult and associated with a distinctly higher retear rate than that associated with the repair of smaller tears and also the overall outcome of massive tears is less satisfactory massive rotator cuff tears (RCTs) have the widest diameter (≥ 50 mm) and involve two or three tendons [1]. Complete repair of a massive RCT, although technically challenging, may be accomplished by open or arthroscopic procedures.

the purposes of this study were to determine the clinical and structural long-term results after open repair of massive rotator cuff tears in patients who had been examined with the same, standardized methodology at a mid-term follow up evaluation and to identify additional problems and the functional outcome and rate of re-tears after open repair of large and massive tears of RCT

Materials and Methods:-

Prospectively 25 patients with a large or massive tear of the rotator cuff who had surgical repair between January 2015 and December 2019.

Inclusion criteria were the presence of a large or massive tear, identified by imaging and confirmed intra-operatively, which was repaired using open approach.

Exclusion Criteria:

previous operation, fracture or infection on the affected shoulder, or moderate to severe glenohumeral osteoarthritis. The indication for surgery was in all cases a painful shoulder with ongoing functional impairment after an unsuccessful period of physical therapy of at least 3 months

25 patients, 10 men and 15 women, attended a follow-up clinic at a mean of 31 months(14 to 48). Two patients were lost to follow up and were not included in the analysis.

The mean age of the patients at surgery was 53 years(35 to 71), and in 17 of 23 patients (75%) the dominant arm was affected. two patient had previously undergone a subacromial decompression for impingement symptoms without evidence of a tear of the rotator cuff at the time of surgery. The mean time between the onset of symptoms and surgery was 6 months. In nine patients (40%) the onset of symptoms was acute, six after a fall, one following a 'jerking movement' of the arm, and one associated with a dislocation of the shoulder. In nine patients (36%) the onset of symptoms was gradual, and five (24%) identified an acute event that worsened their existing symptoms.

The indication for surgery was a symptomatic tear of the rotator cuff, confirmed by either ultrasound or MRI, following acute injury or with persistent symptoms after three months of non-operative treatment, which included physiotherapy, subacromial injections and anti inflammatory medication.

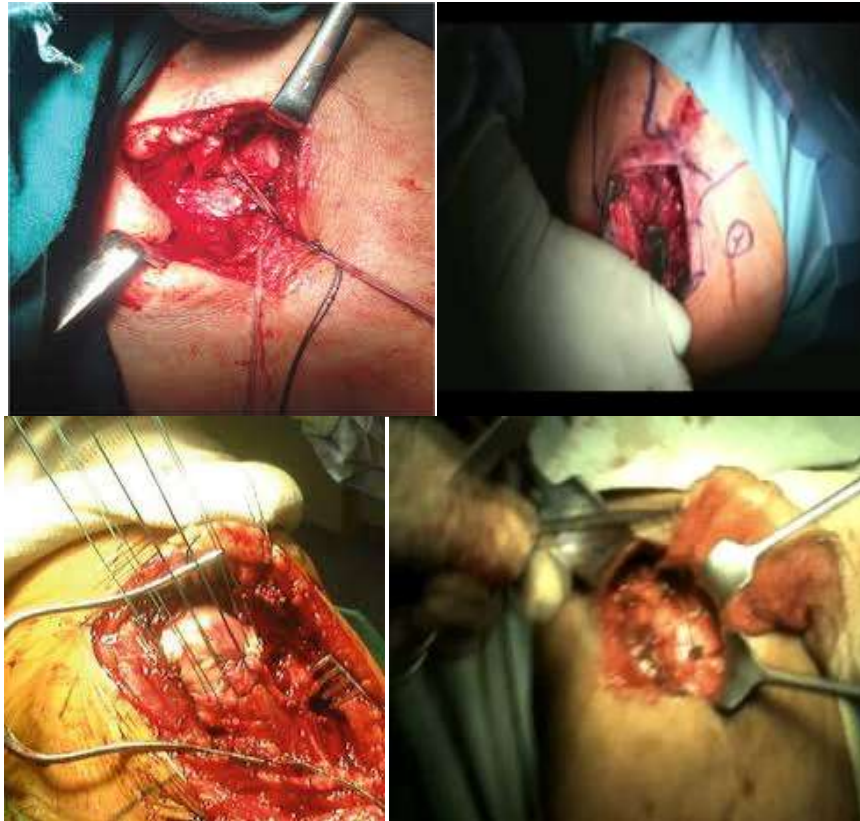
All procedures were performed by a consultant orthopaedic surgeon (Dr Mustafa elsagair , DrRacheeddarbounk , DrMarwan abowedneen) with assistant (Dr A alkabti and Dr W abuzaid)under general anesthesia and patient in supine position with a sandbag under scapula which allows extension of shoulder to expose posterior cuff and given interscalane block, the upper extremity is draped free which allows movements of shoulder to bring different parts of cuff in view intraoperatively. Manipulation of shoulder was done in patients with preoperative shoulder stiffness. A 4-5 cm incision is taken on anterolateral edge of acromion and extended distally to carry dissection between raphe between anterior and middle part of deltoid. The deltoid is detached with cautery from anterior edge of acromion bring cuff in view

Acromioplasty was done either with a sharp osteotome (antero inferior part of acromion was osteotomized and the bone piece is peeled off from cuff) or with the help of high speed burr

The torn tendon was tagged by traction sutures after removing the hypertrophic bursal tissue , around the split site to improve visualization,. The tear was mobilized and reattached to the bone with 2-4 (mean 2.5) 5-mm metal bone anchors-G4 Superanchors (DePuyMitek, Raynham, MA) with double-loaded No. 2 Ethibond sutures (Ethicon, Somerville, New Jersey).

For large massive tears, the anterior and posterior edges are sutured to each other and the remaining edge is attached as described above.

Skin sutured with 3-0 nonabsorbable (ethilon) suture. Arm sling pouch was given,Although in all cases the coracoacromial ligament was released, neither distal clavicle resection was performed, biceps tenotomy done in one case .



Intraoperative massive RCT Repair:

Postoperatively, all shoulders were protected in a broad arm sling for 6 weeks, while light pendulum exercises were commenced as soon as pain allowed. Passive range of motion exercises including forward flexion and external rotation were initiated under the guidance of a physical therapist 2 weeks later. Active-assisted shoulder motion was permitted after the 6th postoperative week and hydrotherapy was encouraged at the same time. Return to high demand daily activities was allowed 6 months postoperatively.

Out of the 25 patients with a large or massive tear, 23 patients with large tear were available for clinical and US evaluation at a minimum of 14 months postoperatively and constitute our study population. Functional assessment was performed at 6, 12, and 18 months postoperatively and on final follow-up, using UCLA scores for objective evaluation. Patient satisfaction was also recorded.

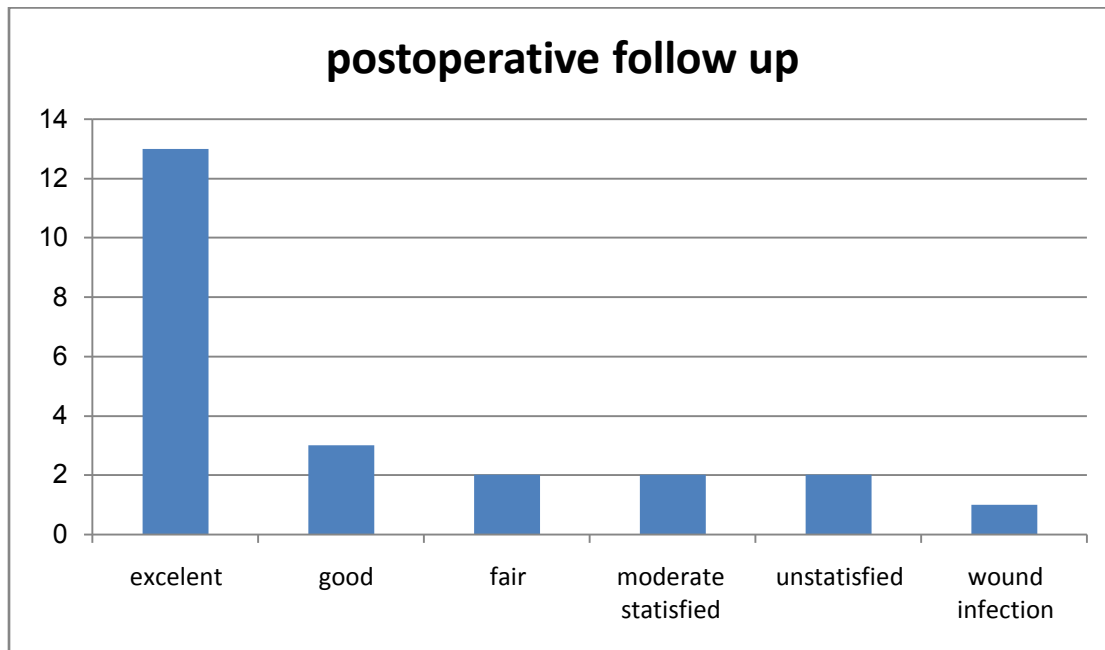
In all patients, a musculoskeletal US was performed at least 14 months years postoperatively by the same examiner (drwisam), using a high-resolution linear-array transducer with variable high frequency (8-13 MHz) (Philips).

The sonographic evaluation of the rotator cuff was performed according to a standard protocol.¹³ Rotator cuff tendons, including subscapularis, supraspinatus, and infraspinatus, as well as the long head of biceps, were examined in transverse and longitudinal planes with additional coronal views of the supraspinatus when necessary. Dynamic scan was employed in all cases.

The ultrasound criteria for the diagnosis of full-thickness rotator cuff tears were: 1) nonvisualization of the supraspinatus tendon due to retraction under the acromioclavicular joint; 2) detachment of the supraspinatus from the greater tuberosity with medial dislocation, or loss of normal supraspinatus substance with widening of the gap between the supraspinatus and biceps tendon and exposure of a bare area of bone and cartilage; 3) a hypoechoic or anechoic cleft extending through the entire substance of the cuff; and 4) coexistence of fluid in the subacromial-subdeltoid bursa and/or the presence of fluid in the sheath of the long head of biceps tendon.^{2, 20} The size of the tear was measured in millimeters directly on freeze-frame images with the use of the cursor software function.

Results:-

At final follow-up 31 months postoperatively (range, 14-48), there was a significant improvement in the overall UCLA score from 12.2 to 29.8. According to the UCLA score, the result was rated as excellent in 56% (13 shoulders), good in 13% (3 shoulders), and fair in 8% (2 shoulders). The patients stated that they were very satisfied with the outcome and they would undergo the procedure again. Two patients (2 shoulders) stated they were moderately satisfied. Two patients unsatisfied post operatively, One patient developed a superficial wound infection that was successfully treated with surgical debridement and antibiotics.

**UCLA Score post operative (tab 1):**

All patients	
Postoperative UCLA score 32–35	13
Postoperative UCLA score 29-31	3
Postoperative UCLA score 28	2
Postoperative UCLA score 0–27	5
Complete repair	16
Partial repair	7

Rotator cuff repair integrity was assessed in all 23 cases at an average of 31 months postoperatively (range, 14-48) with ultrasonographic evaluation. Thirteen repairs were intact and watertight, while recurrent defects were detected in the remaining 10 cases (43%). Recurrent tears were categorized as “small” if the defect was at least 1-2 mm smaller than the preoperative dimension and “large” if it was >2 mm larger than the initial one). In 10 shoulders (56%), the recurrent tear was “small” 7 cases <3 cm, and 2 cases >3 cm and <5 cm] and only in 1 cases (8%) the defect was “large” [>5 cm].

Postoperative u/s defect (Tab 2):

	Number of cases	percentage
Mostly no defect	13	% 56

Small defect 1-2 cm	7	% 30
Intermediate defect 3-5 cm	2	% 8
Large defect 6 cm	1	% 4

The, recurrence of a “small” tear did not clearly affect the clinical outcome, and this is emphasized by the fact that both clinical scores in this patient subgroup were directly comparable to the scores of patients with an intact cuff. On the other hand, a “large” postoperative re-tear was recorded in 1 case and found to be related to the preoperative tear size (massive in the case). Moreover, it led to a fair functional outcome that was significantly worse than that of the subgroup of patients with an intact cuff.

We use UCLA Shoulder Score (the University of California at Los Angeles Shoulder Score). The questionnaire is a combined objective and subjective survey that requires completion by both the doctor and patient. It has five subscales made up of: active forward elevation and strength (physician reported), pain, satisfaction, and function (patient reported). A maximum score of 35 is possible with higher scores indicating better outcomes.

Section 1: Pain

Section 2: function

Present always and unbearable; strong medication frequently	Unable to use limb
Present always but bearable' strong medication occasionally	Only light activities possible
None or little at rest' present during light activities; salicylates used frequently	Able to do light housework or most activities of daily living
Present during heavy or particular activities only; salicylates used occasionally	Most housework, shopping, and driving possible; able to do hair and to dress and undress, including fastening bra
Occasional and slight	Slight restriction only; able to work above shoulder level
None	Normal activities

Section 3: Active forward flexionSection 4-Strength of forward flexion (manual muscle testing)

°150	Grade 5 (normal)
°150-°120	Grade 4 (good)
°120-°90	Grade 3 (fair)
°90-°45	Grade 2 (poor)
°45-°30	Grade 1 (muscle concentration)
°30>	Grade 0 (nothing)

Section 5: Satisfaction of patient

Satisfied and better	Not satisfied and worse
----------------------	-------------------------

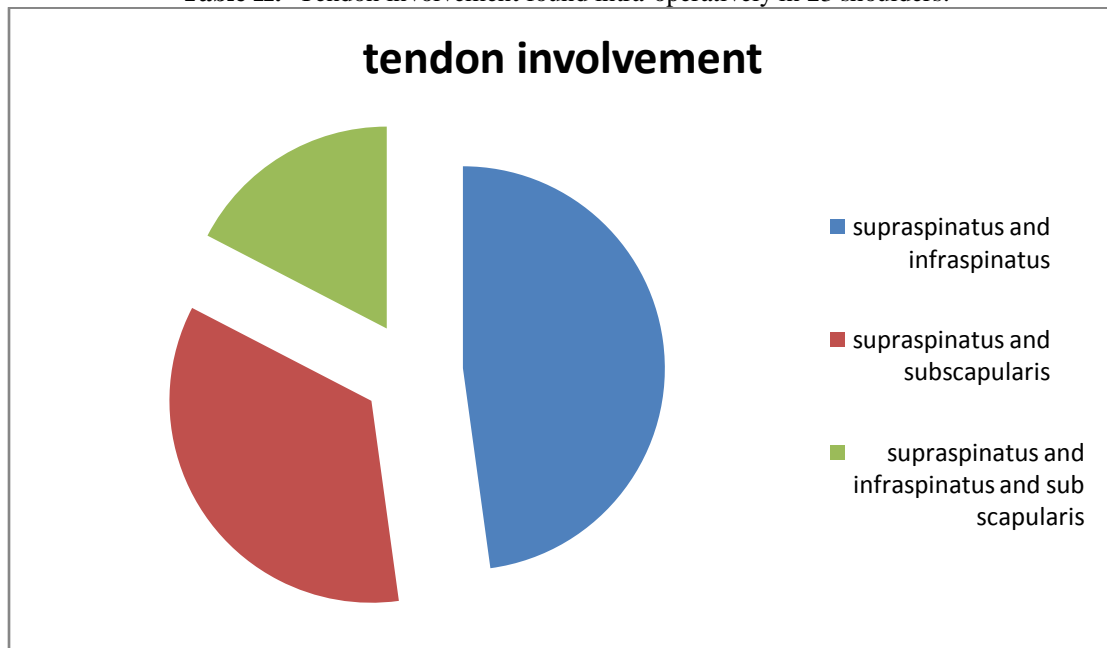
Our mean result according to UCLA Shoulder Score

No. of patients	Pre operative	Post operative
Pain (mean)	2	4
Function	2	5

Active forward flexion	1	5
Strength of forward flexion (manual muscle testing)	2	4
Satisfaction of patient	2	4

Despite the high re-tear rate, objective functional evaluation with UCLA scoring systems presents very satisfactory long-term clinical results of RC repair with open rotator cuff repair. Our results reveal that the presence of a re-tear does not necessarily mean surgical failure or poor outcome. Even if a “large” 4 re-tear occurs, the postoperative functional condition of the shoulder remained improved. However, a structurally intact cuff or even a “small” re-tear were related with a superior clinical outcome.

Table II:- Tendon involvement found intra-operatively in 23 shoulders.



Tendon involvement Number (tab 4):

	Tendon involvement Number	(%)
Supraspinatus and infraspinatus	11	% 47
Supraspinatus and subscapularis	8	% 34
Supraspinatus, infraspinatus and subscapularis	4	% 17

Discussion:-

The best treatment for large and massive tears of the rotator cuff remains controversial. It is widely acknowledged that surgical repair of such tears significantly reduces pain and improves shoulder function, but the size of the tear and the poor quality of the tissues often make successful repair difficult.

The potential advantages of arthroscopic methods over open repair are reduced deltoid morbidity, faster rehabilitation, and the ability to assess and treat intra-articular pathologies. However, the all-arthroscopic approach is technically difficult and has a steep learning curve.

Baysal et al prospectively reviewed 84 patients with tears of all sizes, including 17 with large and massive tears, who underwent mini-open repair, and reported a statistically significant improvement in shoulder scores and range of movement. They found no difference in outcome between different tear sizes at one year, but noticed a trend towards improved outcome in smaller tears

Liem et al observed a rate of re-tear of 36.8% in isolated supraspinatus tears diagnosed by MRI; Verma et al observed re-tears in 50% in tears > 3 cm using ultrasound. The rates of retear after open repair vary greatly, from 10%³⁷ to 86%.³⁸ Higher rates for large and massive tears have been found after arthroscopic repairs, ranging from 31%⁷ to 94%,⁶ and the 17% in our study compares favourably with these results

Cofield et al, in a prospective long-term study of open repair of chronic tears found size to be the most important determinant of outcome, and similar results were reported by Kim et al.

Others found no difference in outcome between tears of different sizes.^{12,28,33} Verma et al identified the integrity of repair as an important predictor of outcome, with significant deficits in function in patients with a re-tear. We observed no difference in shoulder scores either pre- or postoperatively between patients with large or massive tears.

Our study corroborates the findings of Castagna et al, Jost et al, and, more recently, of Hanusch et al,¹⁷ and confirms that a re-tear does not necessarily mean surgical failure, since the postoperative clinical scores recorded were significantly improved, even if a tear re-occurred, provided the re-tear was smaller in size than the initial one.

Our long-term results with a clinical improvement after repair of massive tears regardless of tendon integrity are consistent with the results of Gerber and Zumstein who also showed a significant clinical improvement after open repair of 27 massive tears at the 3- and 10-year follow-up despite a retear rate of 37% and 57%, respectively. These authors found a slight improvement of clinical scores at the 10-year follow-up compared to the 3-year follow-up, despite an increasing retear rate. At both follow-ups, the authors found no reversibility of fatty muscle infiltration and muscle atrophy. We could confirm these findings and found a mild progression of both parameters in postoperative intact cuffs, but a significant progression in return cuffs.

Mellado et al showed that open repair of massive cuff tears in 28 patients resulted in significant clinical improvement and patient satisfaction despite a retear rate of 86%. Correlation of postoperative clinical and MRI results showed that a retear of 3.4 cm or less in the coronal plane and a postoperative fatty infiltration of the infraspinatus less than or equal to 2 were positive predictors for a good clinical outcome.

Conclusion:-

Open repair of massive RCTs may result in a good clinical outcome and significant improvement and return to daily activity in a number of patients despite a high rate of recurrent or residual tears.

Reference:-

1. Fuchs B, Gilbert M, Hodler J, Gerber Ch. (2006) Clinical and structural results of open repair of an isolated one-tendon tear of the rotator cuff. *J Bone Joint Surg Am.* 2006;88:309–316.
2. Gerber Ch, Meyer D, Frey E, von Rechenberg B, Hoppeler H, Frigg R, Jost B, Zumstein M. (2009) Reversion of structural muscle changes caused by chronic rotator cuff tears using continuous musculoskeletal traction: An experimental study in sheep. *J Shoulder Elbow Surg.* 2009;18:163–171.
3. Harvie P, Ostlere SJ, Teh J, et al. (2004) Genetic influences in the aetiology of tears of the rotator cuff: sibling risk of a full-thickness tear. *J Bone Joint Surg [Br]* 2004;86-B: 696-700.
4. Matthias A. Zumstein, Bernhard Jost, Julia Hempel, Juerg Hodler and Christian Gerber (2012), Massive Tears of the Rotator Cuff The Clinical and Structural Long-Term Results of Open Repair of RTC
5. Gerber C, Fuchs B, Hodler J. (2000) The results of repair of massive tears of the rotator cuff. *J Bone Joint Surg Am.* 2000;82:505-15
6. Klepps S, Bishop J, Lin J, Cahlon O, Strauss A, Hayes P, Flatow EL. (2004) Prospective evaluation of the effect of rotator cuff integrity on the outcome of open rotator cuff repairs. *Am J Sports Med.* 2004;32:1716-22.
7. Birgit C Hanusch, Lorna Goodchild (2009) Large and massive tears of the rotator cuff: Functional outcome and integrity of the repair after a mini-open procedure

8. AchilleasBoutsiadis, MDa, Anastasia Fotiadou,(2012) Functional outcome and structural integrity following mini-open repair of large and massive rotator cuff tears:
9. Christoph Bartl,1,2 Pannos Kouloumentas,2,3 Konstantin Holzapfel,4 Stefan Eichhorn(2008) Long-term outcome and structural integrity following open repair of massive rotator cuff tears
10. Jost B, Zumstein MA, Pfirrmann CW, Gerber C. (2006) Long-term outcome after structural failure of rotator cuff repairs. J Bone Joint Surg Am. 2006;88:472–79.
11. Zingg PO, Jost B, Sukthankar A, Buhler M, Pfirrmann CW, Gerber C.(2007) Clinical and structural outcomes of nonoperative management of massive rotator cuff tears. J Bone Joint Surg Am. 2007;89:1928–34
12. Zanetti M, Jost B, Hodler J, Gerber C.(2000) MR imaging after rotator cuff repair: fullthickness defects and bursitis-like subacromial abnormalities in asymptomatic subjects. Skeletal Radiol. 2000;29:314-9.
13. Bishop J, Klepps S, Lo IK, Bird J, Gladstone JN, Flatow EL. (2006)Cuff integrity after arthroscopic versus open rotator cuff repair: a prospective study. J Shoulder Elbow Surg. 2006;15:290–299.
14. Boileau P, Brassart N, Watkinson DJ, Carles M, Hatzidakis AM, Krishnan SG (2005). Arthroscopic repair of full-thickness tears of the supraspinatus: does the tendon really heal? J Bone Joint Surg Am. 2005;87:1229–1240.
15. Bedi A, Dines J, Warren RF, Dines DM.(2010) Massive tears of the rotator cuff. J Bone Joint Surg Am. 2010;92:1894–908.
16. Jennifer A Coghlan Rachelle Buchbinder Sally Green(2008) Surgery for rotator cuff disease Cochrane Systematic Review - Intervention Version published: 23 January 2008
17. Ticker JB, Warner JJ. Single-tendon tears of the rotator cuff.(1997)Evaluation and treatment of subscapularis tears and principles of treatment of supraspinatus tears. OrthopClin North Am. 1997;28:99-116.
18. Warner JJP, Allen AA, Gerber C.(1994)Diagnosis and management of subscapularis tendon tears. Tech Orthop. 1994;9:116-22.
19. Wirth MA, Rockwood CA Jr.(1997)Operative treatment of irreparable rupture of thesubscapularis. J Bone Joint Surg Am. 1997;79:722-31.