



Journal Homepage: -www.journalijar.com

INTERNATIONAL JOURNAL OF ADVANCED RESEARCH (IJAR)

Article DOI:10.21474/IJAR01/11043

DOI URL: <http://dx.doi.org/10.21474/IJAR01/11043>



RESEARCH ARTICLE

VASCULAR INJURIES OF THE UPPER LIMB IN A URBAN TRAUMA CENTER: A RETROSPECTIVE ANALYSIS

Shabnam Fathima A.¹, Prathap Kumar S.² and Sritharan N.³

1. Institute of Vascular Surgery, Madras Medical College, Chennai, India.
2. Assistant Professor, Institute of Vascular Surgery, Madras Medical College, Chennai, India.
3. Professor, Institute of Vascular Surgery, Madras Medical College, Chennai, India.

Manuscript Info

Manuscript History

Received: 22 March 2020

Final Accepted: 25 April 2020

Published: May 2020

Key words:-

Vascular Injuries, Brachial, Radial, Ulnar, Arterial Injury

Abstract

Vascular injuries of the upper limb are commonly encountered in our tertiary care center. It ranges from simple accidental cut injury to a major crush injury with severe contaminated soft tissue, bony and nerve injury. In our study we have retrospectively analyzed the case records of those who had vascular injuries, distal to the deltopectoral groove, managed with vascular repair as an emergency procedure. We studied the pattern of injury, demographics, associated injuries and patency of vascular repair done. Iatrogenic injuries were excluded. 14.6% of injuries involved the pediatric age group. About 82 patients were included in the study. Majority (87%) were males. Mean age was 59.5 years. Mean duration from injury to vascular repair was 5 hours. Blunt injuries were predominant (63.4%). Brachial artery was commonly involved. Interposition repair with autologous reversed great saphenous vein was frequently used procedure. 51.2% of injuries had associated bony injury and 41.2% had nerve injuries. The patency rate of vascular repair was highest in brachial artery repair group, followed by forearm vessels repair group. The limb salvage rate was 97.6%.

Copy Right, IJAR, 2020,. All rights reserved.

Introduction:-

Extremity traumatic injuries are a threat to both life and functionality of patients across the world. Vascular injuries of the extremity constitute 30-50 % of the vascular injuries¹. They can be caused both by blunt and penetrating injury. Vascular injuries of the upper limb are common in our tertiary care referral center. They range from simple cut injury to a major limb threatening crush injury.

Vascular injuries of the extremity usually occur in young productive age group commonly involving the male population. In this article, we analyze the vascular injuries of the upper limb distal to the deltopectoral groove, which includes the third part of axillary artery, brachial, radial and ulnar artery, managed by emergency open surgery for vascular repair.

Materials and Methods:-

The study was done in The Institute of vascular surgery, Madras Medical College, Chennai over a period of 3 years from 1st July 2016 to 30th May 2019. The case records of the patients with upper extremity vascular trauma were

Corresponding Author:- Shabnam Fathima A

Address:- Institute of Vascular Surgery, Madras Medical College, Chennai, India.

analyzed retrospectively and demographic data, associated injuries and pattern of injuries were collected. Only those who were managed with emergency vascular repair distal to deltopectoral groove were included in the study. Patients whose vessels were ligated, underwent primary amputation, had non salvageable limbs and were managed conservatively were excluded from the study. Patients with single forearm vessel injuries involving the radial or ulnar underwent vascular repair if they underwent an open surgical procedure for tendon or nerve repair or bony fixation, otherwise they were managed conservatively or vessel was ligated and hence were excluded from the study. Patients with non-flow limiting intimal defects and flaps, small pseudoaneurysms and arteriovenous fistula diagnosed by duplex, presenting as non critical viable limbs with triphasic doppler signals were treated non operatively².

All patients with upper extremity trauma without pulses with salvageable limb were taken up for revascularisation with hand doppler assessment and without ct angiogram³. Associated nerve injuries were diagnosed by preoperative physical examination and intraoperative assessment. Mangled extremity severity scoring was not used. In all patients vascular injury was first repaired, followed by bony stabilisation by the orthopaedic when indicated followed by nerve and tendon repair by the plastic repair with skin cover finally.

Reversed Great saphenous vein was used as conduit in all interposition repair cases. Extra anatomical bypass repair was done in severely contaminated wound. In patients' with penetrating injury involving less than two third of vessel circumference, vein patchplasty was done. When the injured vessel segment is within two branches and could be resected and primary anastomosis could be done without tension, then it was undertaken. Embolectomy was used only in paediatric patients with humerus fracture without pulses. Fasciotomy was used only when presentation was at least 6 hours post injury, combined vein injury and forearm develops severe edema post revascularisation in brachial artery injuries.

In the post operative period, therapeutic heparinisation was done and patient discharged on antiplatelet aspirin 75mg once daily for a month. The patient was followed up and the patency of the graft assessed by palpable pulse or triphasic flow in the graft.

Results:-

During the period of 3 years, around 82 patients were treated for upper extremity vascular trauma. Among those injured, the young productive male dominated. 87% were males and 13% were females (fig 1). The median age of presentation was 59.5 years with the youngest being 3 years and eldest being 75 years of age.

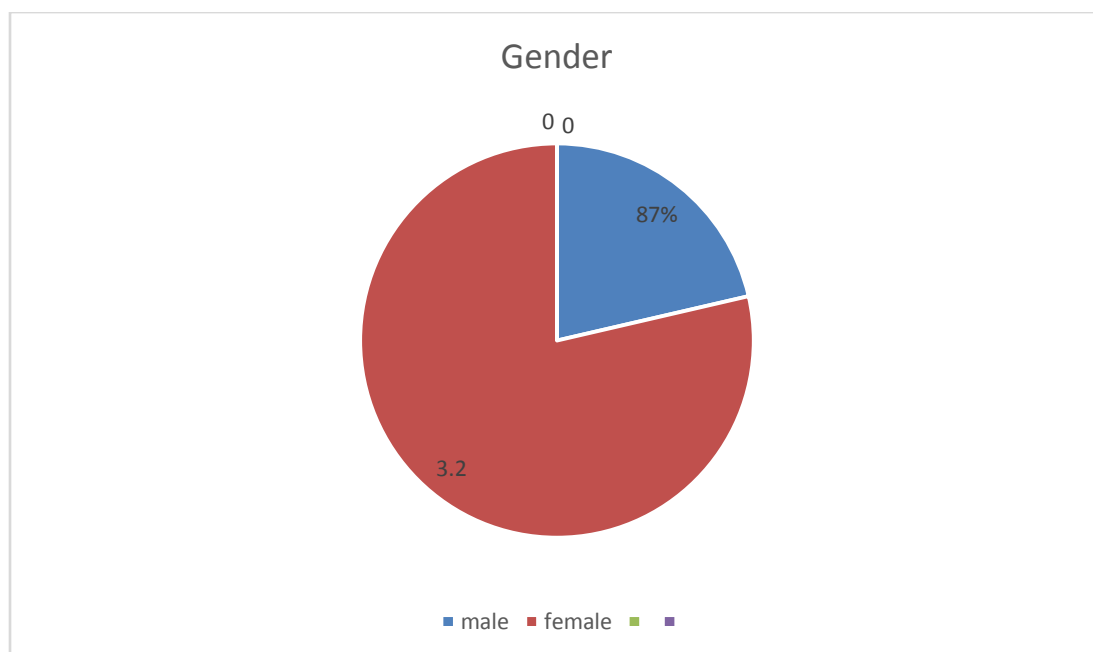


Figure 1:-

14. 6% involved pediatric population. 35% of those injured were between 20-30 years age group (Table 1). Earliest presentation was within 1 hour and maximum delayed presentation was 2 days later in a patient. Median time since presentation was 12 hours. Majority presented 6 hours after the injury. There was no significant association between delayed presentation and limb salvage or vascular repair patency.

Table 1:-

Age	No of patients
1-10	9
11-20	9
21-30	29
31-40	15
41-50	15
51-60	3
61-70	1
71-80	1

Blunt injury occurred in 63.4% (n=52) patients and penetrating injury occurred in 36.6% (n=30) patients. Road traffic accidents were predominant cause of vascular injury involving 45.10% (n=37 patients), next followed by occupational injury in 36.5% (n=30), with assault, self-inflicted injury, monkey bite injury and bullgore injury causing the rest of vascular trauma.

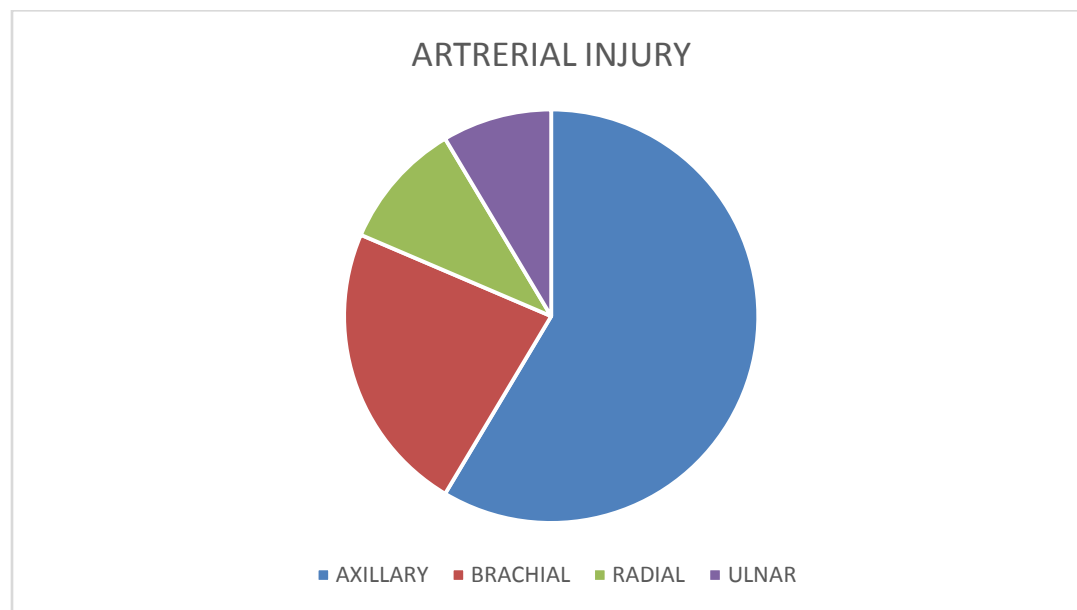


Figure 2:-

50 % (n=41) involved forearm radial and ulnar vessels injury with radial artery involved in 26% and ulnar involved in 24% of all the vessel injured. 46.3% (n=38) involved brachial artery. 4 % (n=3) involved axillary artery injury. Forearm single vessels injury were 28.1% and injuries involving both radial and ulnar involved 21.9% of the patients. Associated nerve injuries were involved in 41.2% (n=34) patients. Median nerve was the predominantly injured nerve (n=20) and ulnar nerve injured in (n=18). Brachial plexuses injury was involved in 3 cases. 51.2% were associated with the bony injury namely Humerus shaft fracture, supracondylar fracture, both bone fracture forearm. 8.3% n=7 involved vein injuries also. 30.4% n=25 involved contusion injury, 20.7% n=17 incomplete transection and 46.3% n=25 complete transection injury.

In 86.5% (n=71) patients interposition vein graft was used. Among them the majority involved the brachial artery. In all these cases, reversed great saphenous vein graft was used. In 10.9% (n=9) patients primary end to end anastomosis was done. In severe contaminated wounds extra anatomical bypass with interposition vein graft was done in 12% (n=10).

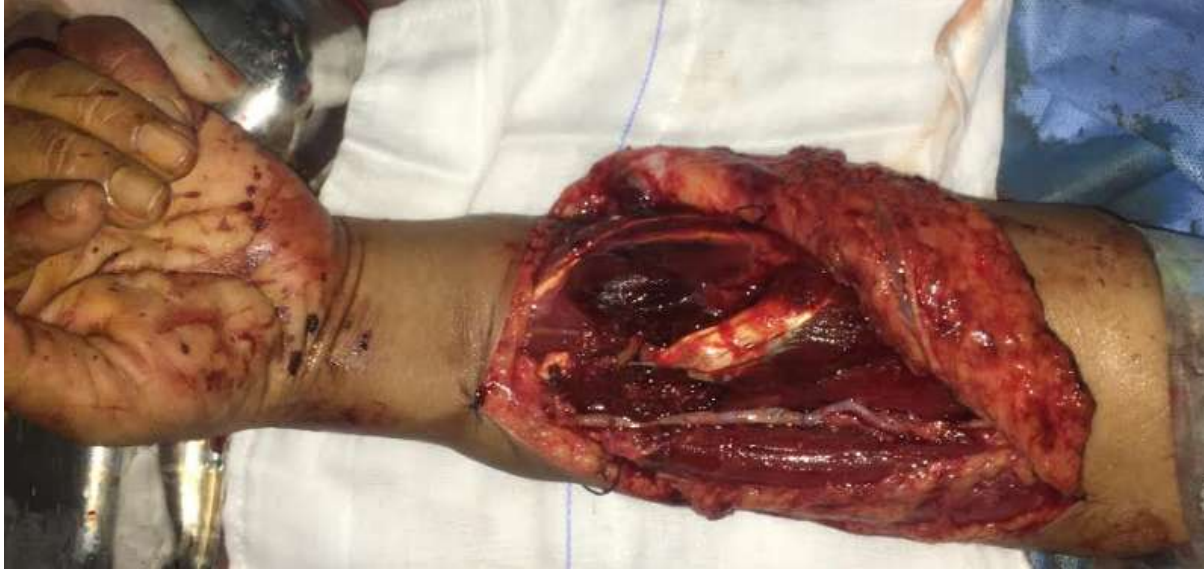

Figure 2:-

In the pediatric age group supracondylar fracture associated vessel injury comprised of 58.8% (n=7). In a single pediatric patient with supracondylar fracture without pulses with monophasic radial and ulnar flow patterns on hand Doppler study, on surgical exploration, patient didn't have any contusion in the vessel adjacent to bony trauma, hence embolectomy of brachial vessel was done and patient had pulses returned. The child was kept under therapeutic heparin dosage till discharge and continued low dose aspirin for a month after discharge. The vein patch was used in single pediatric patient with humerus fracture and brachial artery incomplete transection injury with a small rent. Intraluminal shunts were not used in any patient. All tendon injuries were repaired primarily.

Primary wound suturing was done in 89.02% (n=73). Split skin grafting for cover was done as secondary procedure in 3.65% (n=3). Flap cover as primary method for skin cover was done in 7.31% (n=6).

Concomitant venous injury repair was undertaken in 6% (n=5). Blow out of the anastomosis occurred in 9% (n=8). Anamolous high bifurcation of brachial artery was found in one patient.

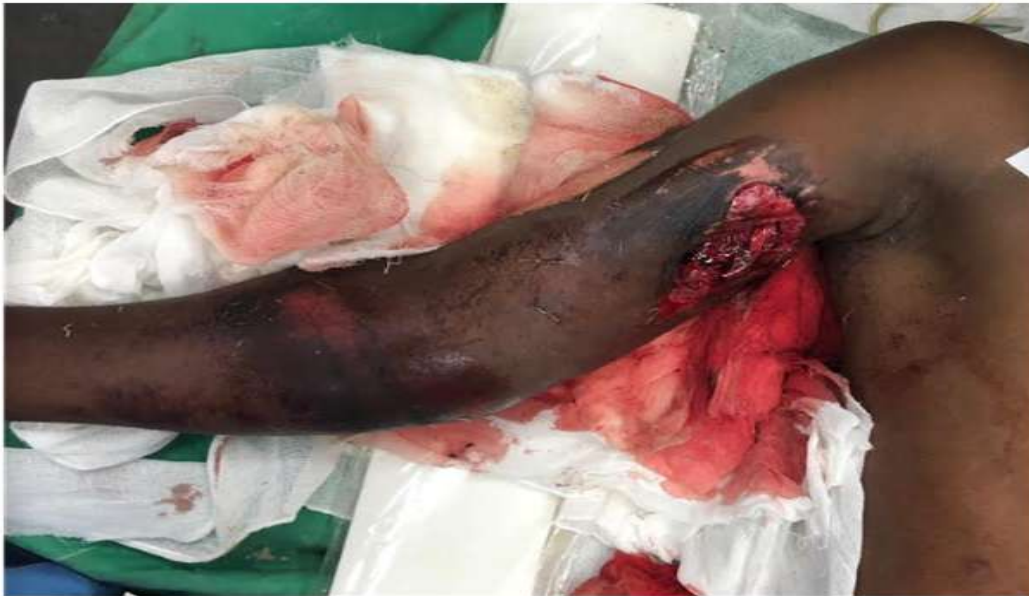

Figure 3:-

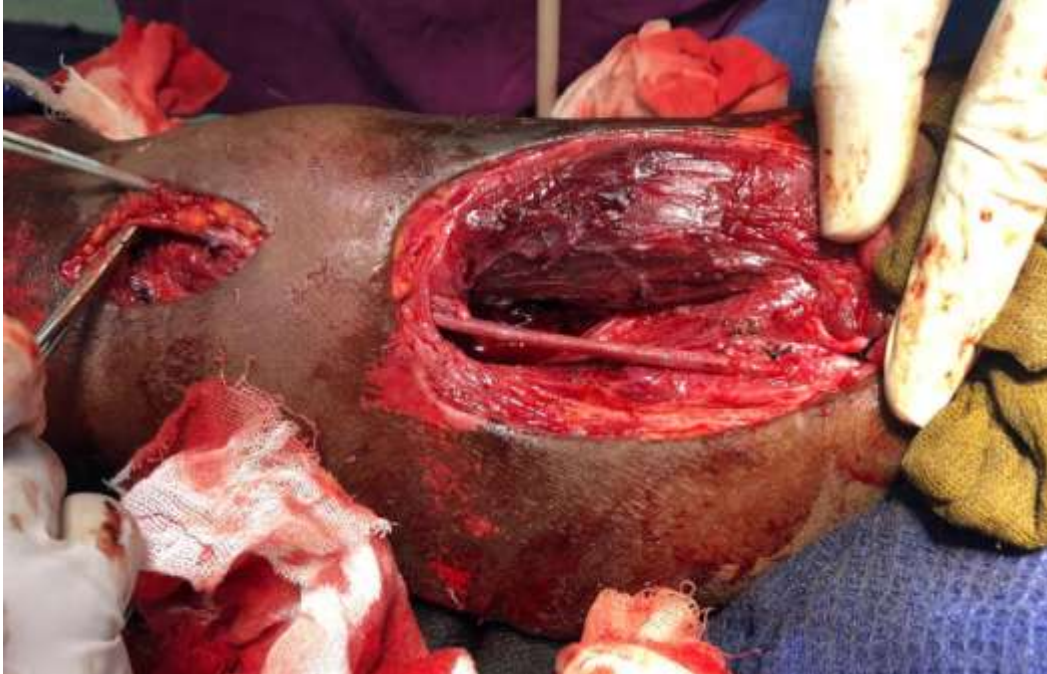

Figure 4:-

Patency at discharge was highest for the brachial artery being 84% and lowest for axillary artery being 33%. The low patency rate for axillary artery could be attributed to major contaminated crush injury of the extremity with multiple other injury sustained by the patients. The radial artery had a patency of 83% and ulnar artery had patency of 72%. In two vessel injury, the patency of atleast single vessel was 66%. The limb salvage rate was 97.6% as two patients required amputation, one due to wound infection and sepsis in an axillary artery injury patient and another brachial artery injury patient with severe crush injury of the fingers, required finger disarticulation.

Discussion:-

Trauma of the extremity carries a high rate of morbidity and mortality. Although vascular injuries account only 1-2 % of the injured patients it accounts for a greater share of morbidity, mortality and resource utilization than those without vascular injuries.⁴ Vascular injury of the upper extremity carry a better prognosis than the lower extremity, especially the injury distal to profunda brachii artery.⁵ It can be attributed to rich collateral network of blood vessels of the upper limb.

Most studies report a higher association of penetrating injury as a causation of injury but contrary to them our study showed a higher association of blunt trauma with vascular trauma. This could be attributed to the urban patient population catered to by our institution, with majority being road traffic associated trauma. Blunt trauma carry a worser prognosis than penetrating trauma due concomitant other injuries and high energy associated with the injury.⁶

In our study, 86% were males, in support to previous studies, which showed vascular injuries were more commonly occurred in males than female. It causes a major economic loss as it involves the young productive male population.⁷

In all cases vascular injuries were diagnosed by physical examination and hand held Doppler assessment. Arteriography was not required in any case for diagnosis, those it has been advocated for diagnosis in penetrating vascular trauma patients.⁸ Also, Shanmugham et al have reported 100% limb salvage without angiography in our center for upper extremity vascular trauma management.

The vascular repair in circumstances of single forearm vessel injury was undertaken only when patient was taken up for open surgery for nerve or tendon repair or bony fixation. Otherwise ligation of radial or ulnar nerve repair in non ischemic hand is considered safe and cost effective.⁹ The overall patency rate for all repaired forearm vessels was

66%. The collateral arteries were the reason for the low patency rate. The remaining intact forearm artery demonstrated a consistent increase in flow velocity. No patient had symptoms of hand claudication inspite of thrombosis or ligation of a single forearm vessel.

Adequate proximal and distal exposure of vessel is essential for vascular control and repair. Most cases required an excision of the injured segment with either interposition bypass graft with reversed saphenous vein graft repair or end to end anastomosis without suture line tension. In our study most brachial artery repair was done by interposition graft repair in contrast to previous reports.¹⁰ In our study concomitant nerve injury was reported in 41.2 % in comparison to other studies where it was around 46%.¹¹ The nerve repair was done as primary repair except a few cases after limb revascularisation. The fasciotomy was done as recommended by previous studies when limb ischemia time is more than 6 hours, associated vein injuries and patient develops or presents with tense edematous compartment on revascularisation. Most of the wound were closed by primary suturing except a select few where split skin graft and flap was used for cover.

The limitation in our study is that it is retrospective study. Mangled extremity severity scoring is not used in assessment. There is no outcome assessment of limb functionality of the patients, especially those with nerve injuries.

Conclusion:-

Brachial artery was commonly involved in the injury in our centre. The patency rate for vascular repair was highest in brachial artery. Most of the repair was done with reversed saphenous vein graft. In axillary artery repair, the patency rate was lower, possibly due to severe contamination and multiple other injuries sustained.

References:-

1. Hunt CA, Kingsley JR. Vascular injuries of the upper extremity. Southern medical journal. 2000 May;93(5):466-8.
2. Dennis JW, Frykberg ER, Veldenz HC, Huffman S, Menawat SS. Validation of nonoperative management of occult vascular injuries and accuracy of physical examination alone in penetrating extremity trauma: 5-to 10-year follow-up. Journal of Trauma and Acute Care Surgery. 1998 Feb 1;44(2):243-53.
3. Shanmugam V, Velu RB, Subramaniyan SR, Hussain SA, Sekar N. Management of upper limb arterial injury without angiography—Chennai experience. Injury. 2004 Jan 1;35(1):61-4.
4. Halvorson JJ, Anz A, Langfitt M, Deonanan JK, Scott A, Teasdall RD, Carroll EA. Vascular injury associated with extremity trauma: initial diagnosis and management. JAAOS-Journal of the American Academy of Orthopaedic Surgeons. 2011 Aug 1;19(8):495-504.
5. Schlickewei W, Kuner EH, Mullaji AB, Gotze B. Upper and lower limb fractures with concomitant arterial injury. The Journal of bone and joint surgery. British volume. 1992 Mar;74(2):181-8.
6. Creagh TA, Broe PJ, Grace PA, Bouchier-Hayes DJ. Blunt trauma-induced upper extremity vascular injuries. Journal of the Royal College of Surgeons of Edinburgh. 1991 Jun;36(3):158-60.
7. Franz RW, Goodwin RB, Hartman JF, Wright ML. Management of upper extremity arterial injuries at an urban level I trauma center. Annals of vascular surgery. 2009 Jan 1;23(1):8-16.
8. Lynch K, Johansen K. Can Doppler pressure measurement replace "exclusion" arteriography in the diagnosis of occult extremity arterial trauma. Annals of surgery. 1991 Dec;214(6):737.
9. Aftabuddin M, Islam N, Jafar MA, Haque E, Alimuzzaman M. Management of isolated radial or ulnar arteries at the forearm. Journal of Trauma and Acute Care Surgery. 1995 Jan 1;38(1):149-51.
10. Ergunes K, Yilik L, Ozsoyler I, Kestelli M, Ozbek C, Gurbuz A. Traumatic brachial artery injuries. Texas Heart Institute Journal. 2006;33(1):31.
11. Shaw AD, Milne AA, Christie J, Jenkins AM, Murie JA, Ruckley CV. Vascular trauma of the upper limb and associated nerve injuries. Injury. 1995 Oct 1;26(8):515-8.