



Journal Homepage: -[www.journalijar.com](http://www.journalijar.com)

## INTERNATIONAL JOURNAL OF ADVANCED RESEARCH (IJAR)

Article DOI:10.21474/IJAR01/11320  
DOI URL: <http://dx.doi.org/10.21474/IJAR01/11320>



### RESEARCH ARTICLE

#### RETRIEVAL OF FRACTURED NI-TI ROTARY INSTRUMENT USING ULTRASONICS AND INSTRUMENT RETRIEVAL SYSTEM UNDER DENTAL OPERATING MICROSCOPE

Dr. Kamal Bagda, Dr. Radhika Kubavat, Dr. Kruti Kachoriya, Dr. Kiran Vachhani, Dr. Kailash Attur and  
Dr. Zarna Patel

#### Manuscript Info

##### Manuscript History

Received: 10 May 2020  
Final Accepted: 15 June 2020  
Published: July 2020

##### Key words:-

Dental Operating Microscope,  
Instrument Retrieval, Instrument  
Retrieval System (IRS), Instrument  
Separation, Ultrasonics

#### Abstract

During routine endodontic therapy, a clinician may encounter many procedural errors and obstacles which may alter the course of treatment; one such error is instrument separation. A separated instrument prevents complete cleaning and shaping of the root canal and this might potentially influence the course of the treatment. Hence, every attempt must be made to retrieve the broken instrument. There are various instrument retrieval kits and chair side techniques available for this purpose. The present case report describes the successful retrieval of separated nickel-titanium rotary instrument with the help of ultrasonics and instrument retrieval system (IRS) under dental operating microscope.

Copy Right, IJAR, 2020,. All rights reserved.

#### Introduction:-

The introduction of nickel- titanium (Ni- Ti) alloy by Walia in 1988 revolutionized the way root canals were instrumented. Despite its wide acceptance, these files tend to fracture without warning. The separation rates of stainless steel instruments have been reported to range between 0.25% and 6% compared to that of Ni- Ti rotary instruments, which are between 1.3% and 10.0%.[1,2]

Intracanal separation of endodontic instruments may hinder cleaning and shaping procedures within the root canal system, with a potential impact on the outcome of treatment. Broken instruments usually prevent access to the apex and the prognosis of teeth with broken instruments in the canals may be lower than for normal ones. The prognosis of these cases mainly depends on the preoperative condition of the periapical tissues. Hence, every attempt must be made to retrieve the broken instrument.[2,3] There are various specialized instrument retrieval kits such as the Masserann Kit, IRS Kit, and Canal Finder system. Some of the authors have used chairside techniques such as wire- and- loop method, file braiding technique, hypodermic needle, and glue technique for retrieving broken instruments.[1]

The present case report describes about the successful retrieval of separated Ni- Ti rotary instrument with the help of ultrasonics and instrument retrieval system (IRS) under a dental operating microscope (DOM).

#### Case Report:

A 44-year-old female patient reported to the department of conservative dentistry and endodontics with the chief complain of incomplete root canal treatment in upper right front tooth. Patient gave history of root canal treatment at a local dentist, initiated 4 weeks prior. Patient was asymptomatic. Medical history was noncontributory. Clinical examination revealed dislodged temporary restoration in relation to maxillary right canine. The tooth was nontender

on percussion and palpation. Periodontal probing depths were normal. Tooth was nonvital. Intraoral periapical radiograph (IOPA) revealed separated instrument fragment, extending approximately from 2 mm below the canal orifice, to the apex around 15 mm. [Fig. 1]. The case was diagnosed as a previously initiated root canal treatment with asymptomatic apical periodontitis in relation to 13.

Since the efforts of bypassing the fragment went futile an attempt to retrieve it was made with ethylenediaminetetraacetic acid and H-file technique that proved unsuccessful. Hence, retrieval was planned using ultrasonic tips and instrument removal system (IRS).

After the administration of local anaesthesia (2% lignocaine hydrochloride with adrenaline 1:80,000) under rubber dam isolation, the access cavity was modified and the lingual shoulder was removed using Gates Glidden (GG) drill- 3,- 2,- 1(Dentsply,Ballaigues,Switzerland) to ensure a straight line access to the coronal end of the fragment. When viewed under the dental operating microscope (Labomed, Operating microscope) at  $\times 3.5$  magnification, the coronal part of the separated instrument was visible and the fragment was oriented toward the buccal aspect of the canal and was threaded into the dentin. The dentin surrounding the fractured fragment was troughed using ultrasonically activated ET25 tip mounted on handpiece (ACTEON, Satelec) at a power setting 3 under coolant [Fig.2]. Troughing was initially performed on the palatal aspect to free the coronal end of the fragment.

Ultrasonic vibrations (direct and indirect) failed to deliver the instrument out of the canal as it was tightly engaged to the adjacent dentin near the apex. Hence, additional troughing was performed on the buccal aspect of the canal to free the instrument from dentin. This caused the partial loosening of the fractured instrument from the dentin [Fig.3].

IRS system was then employed for retrieval. Microtube of the IRS system was inserted into the canal with the long part of its beveled end oriented to the wall to “scoop up” the head of the separated instrument and guide it into the microtube. Success in guiding the head of the separated instrument into the microtube was achieved after few attempts. Same color-coded screw wedge was then inserted and slid internally through the microtube’s length until it contacted the separated instrument. The separated instrument was engaged by gently turning the screw wedge handle counterclockwise. A few degrees of rotation served to tighten, wedge and often displace the head of the separated instrument through the microtube window. The separated instrument was removed by rotating the microtube and screw wedge assembly out of the canal in counterclockwise . The microtube and the screw wedge were taken out of the canal along with the separated instrument [Fig 4 and 5].

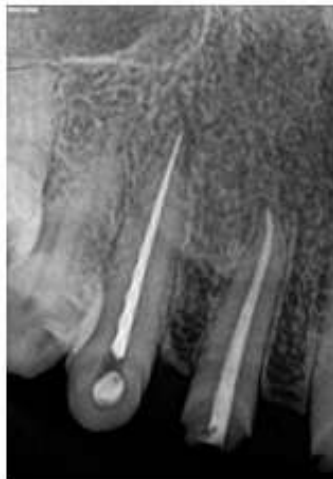

Figure 1: Pre-operative radiograph



Figure 2: ET25 ultrasonic tips (ACTEON)

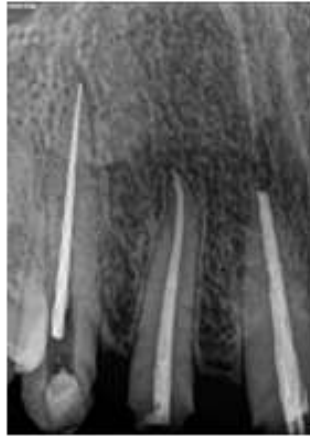

Figure 3: After ultrasonic troughing



Figure 4: IRS kit

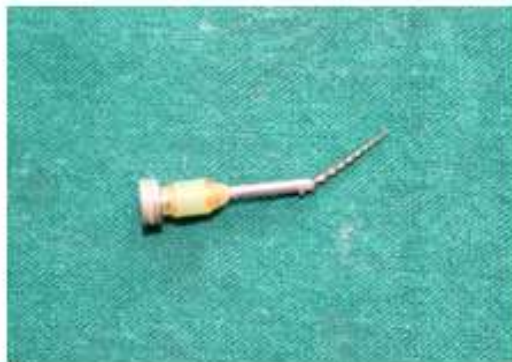

Figure 5: Separated file retrieved with IRS

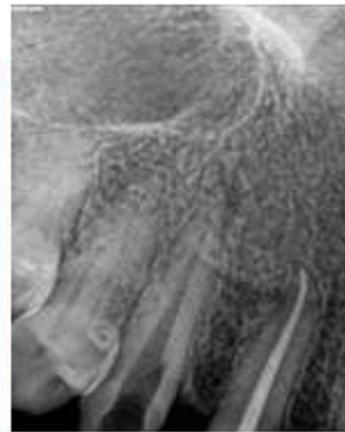


Figure 6: After removal of the separated file

Radiographs were taken to make sure that finally the canal was cleared of obstruction [Fig 6]. When viewed under the dental operating microscope (Labomed, Operating microscope) at  $\times 3.5$  magnification, the canal was cleared from the separated file [Fig 7]. The fractured fragment was measured and was approx. 15 mm [Fig 8]. Working length radiograph was then taken and the canals were prepared and irrigated with 2.5% sodium hypochlorite during instrumentation. The final irrigation was performed using 17% EDTA and 2.5% sodium hypochlorite. The canal was dried with absorbent paper points and obturated with cold lateral compaction technique. The access cavity was restored with resin composite Filtek Z250 (3M Dental Products, St Paul, MN, USA) [Fig 9,10]. The patient was asymptomatic during the 4- week follow- up period.

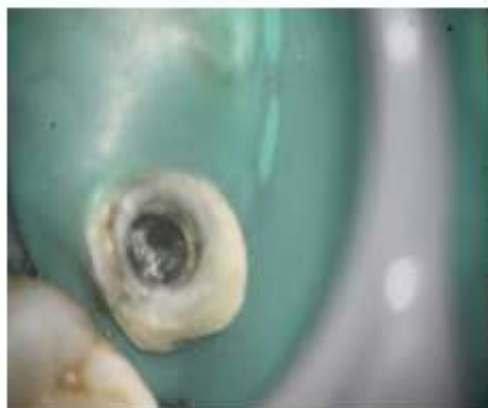

Figure 7: Clinical view after file retrieval under DOM



Figure 8: Fractured fragment

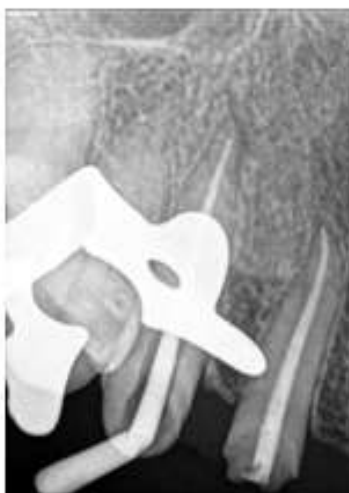

Figure 9: Master cone radiograph

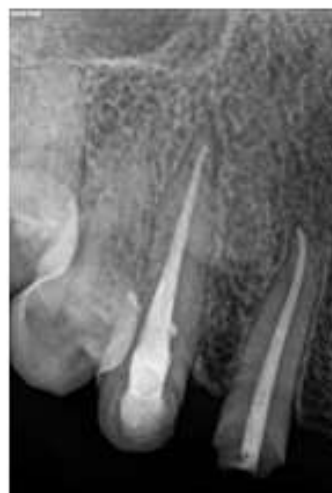

Figure 10: Post operative radiograph

### Discussion:-

A Ni- Ti rotary file may fracture inside the root canal due to cyclic or torsional fatigue. A variety of strategies such as heat treatment, ion implantation, electropolishing, twisting of files, altering the metallurgy, and newer design features are being employed during the manufacturing process to improve the fracture resistance.(10) Various factors have been associated with the fracture of Ni- Ti rotary instruments: operator experience, rotational speed, canal curvature, instrument design and technique, torque, manufacturing process, and absence of glide path. Restricted access, improper angulation of the file during usage, canal anatomy, and over usage of files could also contribute to file separation.(1,4)

The most ideal management of separated instruments is to prevent the occurrence in the first place. Adhering to proven concepts, integrating best strategies and utilizing safe techniques during the root canal preparation procedures will virtually eliminate the broken instrument procedural accident.(5) Prevention may also be greatly facilitated by thinking of negotiating and shaping instruments as disposable items. Simply discarding all instruments after the completion of each endodontic case will reduce breakage, lost clinical time and upsets. However, on

occasion an instrument will break and in spite of the best existing technologies and techniques the broken file segment may not be able to be bypassed or retrieved.

Intracanal instrument separation can be effectively managed by either bypassing it or retrieving. However, retrieval was attempted in the present case. Several methods and techniques have been advocated over the years for the removal of separated solid objects such as silver points and fragments of endodontic instruments. If the coronal aspect of the fragment to be removed is accessible, it has the ability to be withdrawn from the canal by a variety of instrument systems.<sup>(6)</sup> Examples of such systems include Masseran kit, Endodontic Kit, the Cancellier IRS, the Ruddle IRS, Canal Finder, Endo rescue, and Mini forceps. Recently, Terauchi developed a new file retrieval kit that claims to remove minimal dentin.<sup>(4,9)</sup>

Few authors suggest the use of specialized ultrasonic tips under DOM to overcome the problem of excessive removal of dentin. The ultrasonic tip is activated at lower power settings in order to prevent tip breakage and severing of the fractured instrument. Water supply is reduced to enhance visibility into the canal. The activated file should be of a tip size that enables trephination of dentin around the fragment. However, files that are too small should not be used because they are themselves prone to separation. The ultrasonic tip is placed between the exposed end of the file and canal wall and it is vibrated around the obstruction in a counterclockwise direction that applies an unscrewing force to the file as it is being vibrated. This technique will help in removing instruments that have a clockwise cutting action. If the file has a counterclockwise cutting action, then a clockwise rotation will be needed. With this trephining action and the vibration being transmitted to the separated fragment, the latter often begins to loosen and floats out of the root canal. Furthermore, if one is not cautious and excessive pressure is applied, the vibrations may push the fragment further apically, or cause the ultrasonic tip to fracture leading to a more complicated scenario. Also, to prevent separation of the ultrasonic tip, it is important to avoid unnecessary stress by only activating it when in contact with root tissue.<sup>(2,8)</sup>

Operating under high power magnification enables precise use of ultrasonic, avoiding unnecessary dentin removal thereby increasing the success rate by 67%–95%.<sup>(11)</sup>

The IRS system provides a procedural breakthrough for the removal of intracanal obstructions such as silver points, carrier-based obturators or broken file segments. The IRS system is indicated when ultrasonic efforts prove to be unsuccessful to remove broken instruments that are lodged in the straightaway portions of the root or partially around the canal curvature. One of the most important factors to be considered prior to instrument retrieval by this system is to obtain a straight line access to the coronal end of the separated instrument by the use of modified gates glidden drills, #1 and #2 sectioned at their maximum cross-sectional to obtain a flat end. The objective here is to create a straight line access to the coronal aspect of the separated fragment. However, this leads to removal of a considerable amount of radicular dentin and can cause iatrogenic damage like perforation. Close inspection of pre-operative radiographs and knowledge of root anatomy is imperative before attempting the removal procedure in any tooth to ascertain the relative amount of surrounding dentin and the risk of perforation. File removal generally results in ledge formation and therefore a possible stress concentration point. When the file is located in the middle or apical third of the root, removal procedure significantly reduces the root strength.<sup>(3,7)</sup>

It would be wiser to prevent separation of instruments from occurring as attempting its retrieval is time-consuming, involves potential complications, and increases the anxiety level of the patient. Treatment option and long-term prognosis of treatment subsequent to file fracture is influenced by many factors: canal preparation stage, level of microbial contamination and intracanal location of separated file. Presence of separated instrument in the canal hinders accessibility to the apical terminus, impedes thorough cleaning and shaping procedure and thus may compromise with the outcome of endodontic treatment and reduce the chances of successful treatment.

Hence, attempt to retrieve the separated instrument is considered as a more favourable option. However, one should keep in mind that the removal of separated instrument should not weaken the existing radicular tooth structure further risk of perforation and postoperative fracture, thereby reducing the long-term prognostic value of the tooth.<sup>(12)</sup>

### **Conclusion:-**

There exist no standardized procedure for successful and guaranteed removal of separated instrument from the canal. This case report attempt to address and report conventional techniques must be tried before but if they prove

to be unsuccessful alternative devices should be used for the removal of broken endodontic instruments. Finally, improved visualization combined with a conservative approach, balanced with favorable prognosis is the treatment option of choice.

The Ni- Ti rotary file was successfully retrieved in the maxillary right canine using ultrasonic tips and instrument retrieval system(IRS) under the dental operating microscope.

**References:-**

1. Natanasabapathy V, Sundar S, Koteeswaran V. Retrieval of fractured Ni-Ti rotary instrument using ultrasonics and file braiding technique under surgical operating microscope. *Endodontology* 2017;29:65-8.
2. Sokhi R, Sumanthini MV, Shenoy V .Retrieval of Separated Instrument using Ultrasonics in a Permanent Mandibular Second Molar: A Case Report . *Journal of Contemporary Dentistry*, January-April 2014;4(1):41-45
3. Kunhappan S, Kunhappan N, Patil S, Agrawal P. Retrieval of separated instrument with instrument removal system *Journal of the International Clinical Dental Research Organization*, Jan-Dec 2012;4(1)
4. Roda RS, Gentleman BH. Nonsurgical retreatment. In: Cohen S, Burns RC, editors. *Pathways of the Pulp*. 9th ed. St. Louis: CV Mosby; 2006. p. 982-90.
5. Ruddle CJ. Cleaning and shaping root canal systems. In: Cohen S, Burns RC, editors. *Pathways of the Pulp*. 8th ed. St. Louis, Mo: Mosby; 2001. p. 231-91.
6. Nagai O, Tani N, Kayaba Y, Kodama S, Osada T. Ultrasonic removal of broken instruments in root canals. *IntEndod J* 1986;19:298-304.
7. Ruddle CJ. Nonsurgical endodontic retreatment. In: Cohen S, Burns RC, editors. *Pathways of the Pulp*. 8th ed. St Louis, Mo: Mosby; 2001. p. 875-929.
8. Madarati AA, Hunter MJ, Dummer PM. Management of Intracanal Separated Instruments *J Endod* 2013;39:569-81.
9. Bruce L. Chenail, Paul E. Teplitsky, Orthograde Ultrasonic Retrieval of Root Canal obstruction. *J Endod* 1986;13:186-90.
10. Gutmann J L, Gao Y. Alterations in the inherent metallic and surface properties of nickel-titanium root canal instruments to enhance performance, durability and safety: A focused review. *IntEndod J* 2012;45:113-28.
11. Fu M, Zhang Z, Hou B. Removal of broken files from root canals by using ultrasonic techniques combined with dental microscope: A retrospective analysis of treatment outcome. *J Endod* 2011;37:619-22.
12. Shahabinejad H, Ghassemmi A. Success of ultrasonic technique in removing fractured rotary nickel-titanium endodontic instruments from root canals and its effect on the required force for root fracture. *J Endod* 2013;39(6):824-828.
13. Ingle JI, Bakland LK. *Ingles Endodontics*. 6th ed. BC Becker Inc. 2008; 821.