



Journal Homepage: -www.journalijar.com

INTERNATIONAL JOURNAL OF ADVANCED RESEARCH (IJAR)

Article DOI:10.21474/IJAR01/11576

DOI URL: <http://dx.doi.org/10.21474/IJAR01/11576>



RESEARCH ARTICLE

PROSTHETIC REHABILITATION OF EDENTULOUS HEMI MANDIBULECTOMY PATIENT USING AN UNCONVENTIONAL DENTURE

Shari S.R¹, Harshakumar K.², Kavitha Janardanan³ and Litty Francis³

1. Student, Department of Prosthodontics, Government Dental College, Kerala University Of Health Sciences, Trivandrum, 695011, Kerala, India.
2. Professor, Department of Prosthodontics, Government Dental College, Kerala University Of Health Sciences, Trivandrum, 695011, Kerala, India.
3. Assistant Professor, Department of Prosthodontics, Government Dental College, Kerala University Of Health Sciences, Trivandrum, 695011, Kerala, India.

Manuscript Info

Manuscript History

Received: 25 June 2020

Final Accepted: 30 July 2020

Published: August 2020

Key words:-

Hemi Mandibulectomy, Complete Denture, Neutral Zone, Mandibular Deviation

Abstract

The restoration of normal function and aesthetics is often challenging for patients with hemi mandibulectomy due to mandibular rotation, deviation, and unstable occlusion. The successful rehabilitation of a patient with hemi mandibulectomy depends upon the extend of surgical defect, degree of tongue impaired, presence of remaining natural teeth, treatment plan, type of prosthesis, patient co-operation, and duration for initiation of treatment. Prosthodontic treatment along with an exercise program helps to reduce mandibular deviation and thereby improves efficiency of masticatory function. This case report describes the series of steps followed for the rehabilitation of a hemi mandibulectomy defect patient who have an edentulous remaining mandible, using a un conventional denture.

Copy Right, IJAR, 2020,. All rights reserved.

Introduction:-

The mandible along with muscles of mastication and tongue plays an important role in various functions like speech, mastication, swallowing and respiration. Odontogenic tumours of epithelial origin commonly seen in the posterior mandible are often treated with surgical excision. The surgical resection causes loss of mandibular continuity which results in deviation of remaining mandibular segments towards the resected side and rotation of the mandible inferiorly due to muscle pull and gravity.¹ Apart from the deviation of mandible to the resected side, other dysfunctions observed are difficulty in mastication, swallowing, speech, and even respiration.²

A hemi mandibulectomy classification for edentulous patients was provided by Cantor and Curtis.² Retraining the muscles for repeated occlusal approximation is the primary aim in rehabilitation.³ Multiple methods are proposed for the rectification of mandibular deviation based on the nature of the mandibular defects.^{5,6} One such method is intermaxillary fixation. Prosthetic rehabilitation with conventional prostheses such as mandibular based guidance restorations, and palatal based guidance restorations or implant-supported prostheses is also a commonly used treatment method. Initiating the guidance therapy in an earlier stage itself, is more successful for the patient's definitive occlusal relationship.⁴

Retraining mandibular movements are comparatively more difficult for the edentulous patients than the dentulous patients. There are several unfavourable physical limitations when rehabilitating completely edentulous patients with

Corresponding Author:- Dr. Shari S.R

Address:- Postgraduate Student, Department of Prosthodontics, Government Dental College, Medical College Junction, Ulloor, Trivandrum, PIN Code: 695011.

resected mandible and many times may never achieve proper maxillomandibular relationships for optimum mastication and appearance.⁵ This case report describes the rehabilitation of completely edentulous mandibular patients with resected mandible.

Case Report:

A 70-year-old male patient, suffering from Squamous cell carcinoma underwent Hemi Mandibulectomy and was referred to the Department of Prosthodontics, Government Dental College, Trivandrum for rehabilitation. The patient history revealed that he was a Tobacco chewer for more than 30 years. The chief complaint of the patient was difficulty in speech and inability to grind food. He was diagnosed with squamous cell carcinoma of the right buccal mucosa and posterior alveolus two years ago. He underwent extensive resection of the right side of the mandible starting from the midline involving entire body, ramus, coronoid process, and condyle along with radical neck dissection. There were no augmentation of bone and soft tissues in the resected region. Pectoralis major Myocutaneous flap was used for reconstruction. Right side of the tongue was also resected.

It was observed that the patient had a unilateral discontinuity from the midline of the mandible on right side which can be classified as a Type III resection as per the Cantor and Curtis classification. Intra oral examination shows partially edentulous maxilla and completely edentulous left mandibular segment. The treatment plan was formulated after taking into consideration the two main challenges namely, the absence of mandibular ridge affecting retention and the stability of the prosthesis, deviation of mandible to the right-side causing difficulty in speech and mastication. Maxillary acrylic removable partial denture with hollow acrylic ramp and mandibular customized cast metal complete denture was selected to overcome both these issues which resulted in the successful rehabilitation of the patient.

Treatment procedure:

Primary impression was made using irreversible hydrocolloid impression material (DPI) with perforated metal stock trays, complete and partial trays for maxillary and mandibular arch respectively. (Fig.1). Maxillary and mandibular cast was made with Type III dental stone (GYPROCK) (Fig. 2). Custom tray was fabricated using autopolymerising acrylic resin on mandibular primary cast (Fig.3). Border moulding of the mandibular tray was performed using low fusing modelling compound stick (DPI)(Fig.4). Poly vinyl siloxane (3M ESPE) was used for making mandibular secondary impression. Mandibular master cast was poured in Die stone. A cast metal framework for the mandibular prosthesis was fabricated on the master cast. It was tried in the mouth for extension and fit prior to jaw relation. (Fig.5)

Tentative jaw relation was recorded using a record block consisting of autopolymerising resin base and wax occlusion rims. Jaw relation was recorded and casts mounted on articulator. Wax on the lower record base removed and one vertical acrylic pillar and wire bended in zig -zag way was attached to record neutral zone (Fig.6). Then place the record base in mouth and ensure—that vertical pillars and wire loops did not interfere with muscle movements during function. Admix compound (3:7 Impression compound: Greenstick compound) were placed on record base to perform pursuing, smiling, whistling, speaking (Sis, SO, pronouncing vowels), swallowing which aided in moulding the neutral zone (Fig7,8). A Putty index was adapted around the recorded neutral zone of the mandibular arch, to serve as a guide during setting of teeth and wax up of denture. (Fig.9).

The acrylic denture base was replaced with the metal framework. Teeth arranged according to the neutral zone recorded and then try-in was done (Fig.10). Maxillary and mandibular definitive prosthesis were made, finished and polished. To train the patient to achieve an unassisted ideal occlusal contact, a twin bite was recorded on the palatal surface of maxillary denture in wax at the comfortable mandibular position of the patient (Fig.11). Relining of the mandibular denture was done with polyvinylsiloxane impression material (Fig.12). Wax bite was then converted into a hollow acrylic ramp using soap to reduce the weight of the maxillary acrylic partial denture (Fig.13A, 13B,13C,13D,). The definitive prosthesis was finished, polished, and inserted into patient mouth successfully (Fig14a,14b). Simple exercises were suggested to the patient such as repeated opening and closing of the mandible. This helped the patient learn to manipulate the lower denture into proper position. Initially the use of the denture was difficult for the patient, but this was improved with constant use. Within 2 weeks, the patient expressed satisfaction in mastication and phonetics.

Discussion:-

Successful functional rehabilitation of edentulous hemimandibulectomy patients is more difficult than that of a patient with natural teeth.⁶ According to Sharry⁷, the difficulties encountered during the treatment procedures are:

1. Limited coverage and retention.
2. Grossly impaired relation of the mandible to the maxilla.
3. Limited movement of the mandible.

Following the operation, there is loss of facial structures, sensory and motor innervation problems along with the reduced denture base area creates a difficulty in complete denture fabrication.⁸ The surgical area became unsuitable to be covered by an appliance or to receive loading, due to the uneven scarring of tissues, lack of support from bones and mobility of the area into various degrees. Appliances which extend into the surgical region may tend to be displaced towards the untreated side and compression of the tissue on the lingual side occurs. This results in continued soreness and eventually the patient will not use the appliance continuously.⁹

As a result of the surgery, the remaining portion of the mandible is pulled medially by the internal and external pterygoid muscles. It is difficult to get an accurate maxillo-mandibular relation in this deviated position of mandible. Therefore a satisfactory occlusion is difficult to achieve.¹⁰ Different types of treatment modalities are present for the hemimandibulectomy patients:

1. Twin occlusion
2. Guiding flange
3. Palatal ramp
4. Facial reconstructive surgery and osseointegrated implant.

Twin occlusion provides two rows of teeth on the unressected side of maxillary denture. It will provide a wider occlusal table.^{9,11} The inner row of teeth help in restoring the function whereas outer row help in supporting the cheeks and enhancing esthetics.

Mandibular guide flange helps to reduce the deviation of the mandible, preventing supraeruption of maxillary teeth and improve the efficiency of mastication. The flange of guiding flange prosthesis was localised to premolars and first molars. The lingual flange extension is deep into lingual sulcus which helps in increasing the stability of dentures. Support for the Guiding flange is from the natural teeth and residual alveolar ridge. Multiple retentive clasp helps to improve the retention of the prosthesis.¹² For this prosthesis to fabricate teeth should be present on non resected side of both maxillary and mandibular arch for the effective guidance.¹³

Osseointegrated dental implants are considered to be the ultimate solution for replacing the missing teeth for reconstructed mandibulectomy patients.¹²

Sloped Palatal ramp is fabricated on the palatal aspect of the maxillary partial denture such that occlusal surface of the lower teeth glides freely over the buccal slope of ramp, so that minimizing the amount of deviation during mandibular closure.¹⁴

The patient presented with edentulous mandibular arch Type III resected mandible (right side), severe deviation of the mandible to the right and complete obliteration of vestibule on resected side. The case was unique and challenging with factors like reduced salivary output, angular path of mandibular closure, loss of tongue bulk, sensation and mobility, absence of reconstruction of bone in the resected side and loss of vestibule. All these factors can affect the success of the treatment.¹⁵ As a result of the resection and lack of reconstruction, support and stability for the prosthesis was compromised. These difficulties combined with the absence of teeth, strikes out the option of using high force generating guide planes.¹⁰ Hence, guiding flange is not suitable for this patient. Even twin occlusion can not be advised because of the severely restricted lateral movement of the mandible. Unfortunately sloped palatal ramp also generate greater force on mandibular arch which will dislodge the mandibular denture. Due to excessive lateral deviation, sloped palatal ramp or twin occlusion table incorporated in the maxillary acrylic partial denture has a chance to destabilize the mandibular denture during functional contact. Neutral zone record helps to position the teeth in denture such that it prevents the encroachment into the zone of activity of buccal and lingual musculature during function. So this can improve the stability and retention of the denture. Eccentric tooth contact can be avoided by providing shallow cuspal angulation for the posterior teeth.¹⁶

So, initially a tooth indented customised hollow palatal ramp was fabricated, to establish a stable and comfortable masticatory table for the patient. The mouth exercise regimen advised along with this, will help in faster shift of the mandible to the normal side.¹⁰ Slowly, occlusal table can be shifted to the left by adding acrylic resin to the buccal aspect of ramp in accordance with the shift of the mandible. Later on, when the leftward movement of the mandible is sufficient enough, a denture with Twin Occlusion can be provided to the patient.

Conclusion:-

Edentulous patients with partially resected mandible are difficult to treat than with a natural dentition. In this clinical scenario, the dentist should strictly follow the fundamental principals of denture constructions. The customized ramp with indentation of the teeth act as a training device which helps in returning the mandible to a most suitably functioning position. Through determination and constant practice patients will be able to gain excellent control over mandibular movements. After a short period of accommodation, patients could have satisfying mastication and speech.

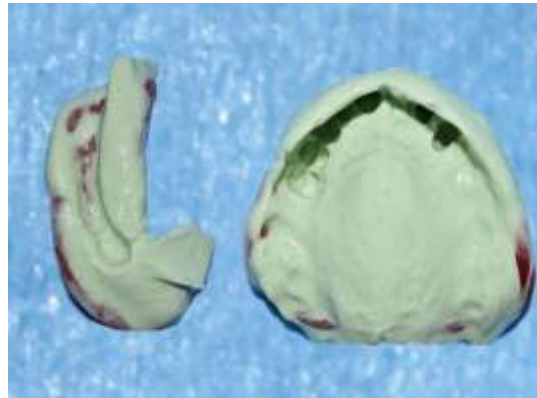


Fig. 1:- Primary impression.

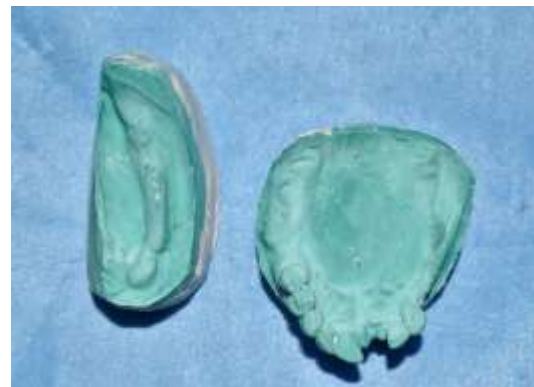

Fig. 2:- Diagnostic cast.

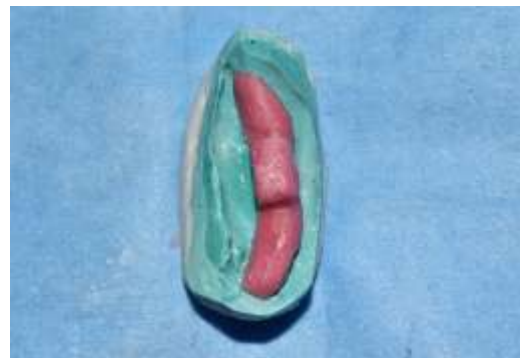

Fig. 3:- Special tray for segmented mandibular arch.

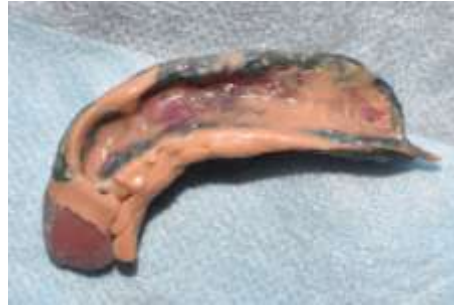

Fig. 4:- Final impression.



Fig. 5:- Metal frame work on master cast.

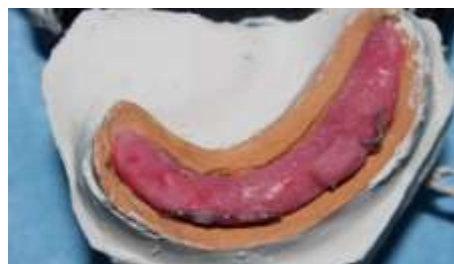

Fig.6:- Modified mandibular denture base.

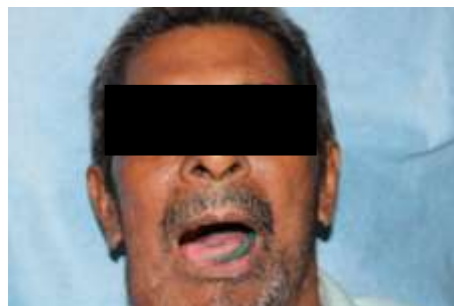

Fig. 7:- Recording neutral zone using admix.



Fig. 8:- Neutral zone record mounted on an articulator.

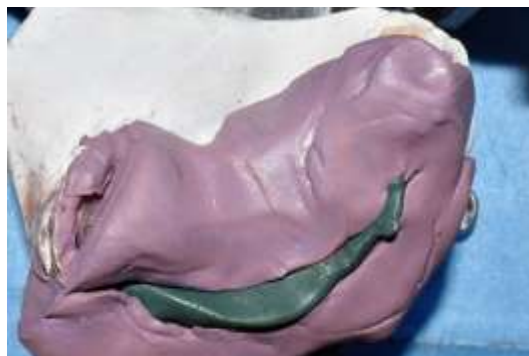

Fig. 9:- Silicone putty index.

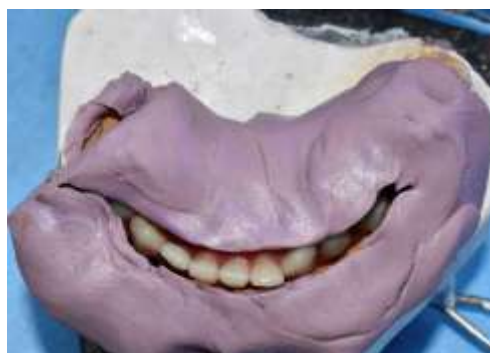

Fig. 10:- Teeth were arranged with in the neutral zone.

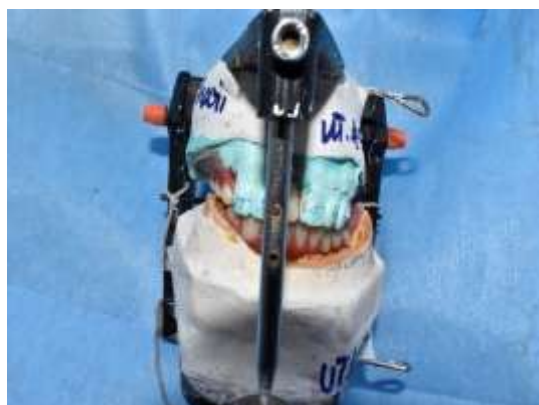

Fig. 11:- After complete teeth arrangement.

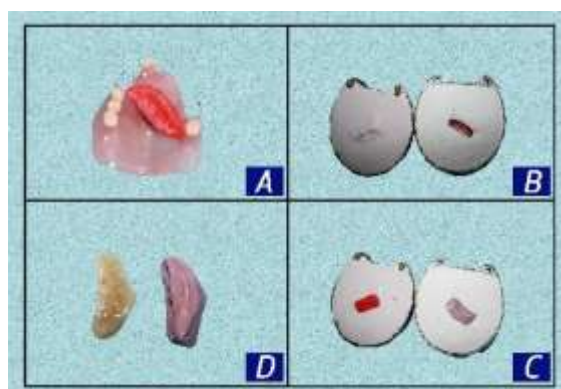


Fig 12 A, B, C, D:- Fabrication of a hollow acrylic ramp using soap.

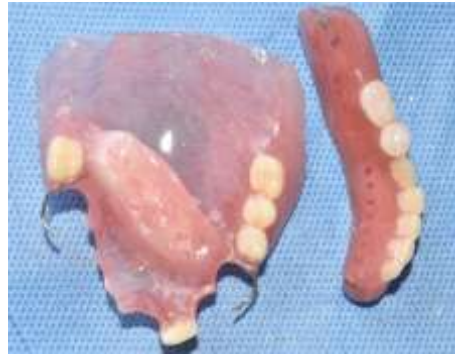

Fig. 13 A:- Final prosthesis.

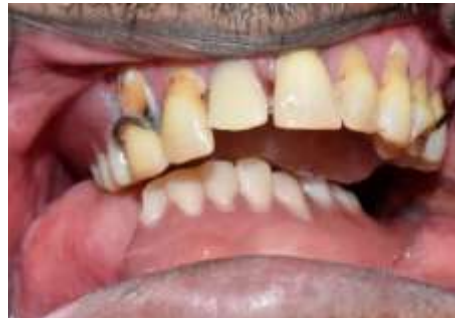

Fig. 13 B:- Intraoral view of final prosthesis.

References:-

1. Chahar PK, Sarkar A. Rehabilitation of Hemi-Mandibulectomy Patient with Twin Occlusion Prosthesis. IJCMSR. 2019 Jan;4(1):24–6.
2. Buemer. J, Curtis. T, Firtell. D. Buemer. J, Curtis.T,Firtell. D.Maxillofacial rehabilitation.St.Louis:Mosby:1979.p 90-169.
3. Nair S, Aparna IN. Prosthetic rehabilitation of hemimandibulectomy defect with removable partial denture prosthesis using an attachment-retained guiding flange. Contemp Clin Dent. 2018;9(1):120–2.
4. Ashlesha Subhash Marathe, Prasad Shankarrao, Kshirsagar. A systematic approach in rehabilitation of hemimandibulectomy: A case report. J Indian Prosthodont Soc. 2016 Jun;16(2):208–12.
5. Jain L, Aeran H, Sharma N. Prosthetic management of hemimandibulectomy patient. International Journal of Oral Health Dentistry. 2017;3(3):195–8.
6. Prakash V. Prosthetic rehabilitation of edentulous mandibulectomy patient: A clinical report. Indian Journal of Dental Research. 2008 Jul 1;19(3):257–60.
7. Sharry JJ. Extension of partial denture treatment. Dent Clin North America. 1962 Nov;8:21–35.
8. Desjardins RP, Laney WR. Prosthetic Rehabilitation After Cancer Resection in the Head and Neck. Surgical Clinics of North America. 1977 Aug;57(4):809–22.
9. Rosenthal L.E. The Edentulous Patient with Jaw Defects. D Clin North America. 1964 Nov;11:773–9.
10. Swoope CC. Prosthetic management of resected edentulous mandibles. The Journal of Prosthetic Dentistry. 1969 Feb;21(2):197–202.
11. Schaaf NG. Oral reconstruction for edentulous patients after partial mandibulectomies. The Journal of Prosthetic Dentistry. 1976 Sep;36(3):292–7.
12. Patil PG, Patil SP. Guide flange prosthesis for early management of reconstructed hemimandibulectomy: a case report. J Adv Prosthodont. 2011;3(3):172–6.
13. Moore DJ, Mitchell DL. Rehabilitating dentulous hemimandibulectomy patients. The Journal of Prosthetic Dentistry. 1976 Feb;35(2):202–6.
14. Sujitha K, Bharathi M, Narayana SL, Naidu MA, Nagaveni D. Prosthodontic Management of Acquired Mandibular Defect by Functionally Moulded Palatal Ramp Prosthesis - A Clinical Report. IJOHMR. 2016;3(1):94–7.
15. Taylor. Clinical Maxillofacial Prosthetics ;2000 Quintessence Publishing Co, Inc P 171-188.
16. Desjardins R. Occlusal considerations for the partial mandibulectomy patient. JPD. 1979;41(3):308–15.