



Journal Homepage: -www.journalijar.com

INTERNATIONAL JOURNAL OF ADVANCED RESEARCH (IJAR)

Article DOI:10.21474/IJAR01/11619

DOI URL: <http://dx.doi.org/10.21474/IJAR01/11619>



RESEARCH ARTICLE

HISTOLOGICAL ASSESSMENT OF ALBINO RATS PERIODONTAL LIGAMENT IN DIFFERENT AGES COMPARING ITS WIDTH WITH HUMAN IN CORRESPONDING AGES

Esraa Ezzeldin Mohamed¹, Medhat A. El-Zainy² and Marwa M. Abdelhameed³

1. Egyptian Russian University Faculty of Dentistry Oral Biology Department.
2. Ain Shams University Faculty of Dentistry Oral Biology Department.
3. Ain Shams University Faculty of Dentistry Oral Biology Department.

Manuscript Info

Manuscript History

Received: 30 June 2020

Final Accepted: 31 July 2020

Published: August 2020

Key words:-

Aging, Periodontal Ligament, PDL Width, Rat Age

Abstract

Introduction: The periodontal ligament is a complicated connection tissue system connecting the alveolar bone to root surface, like any other tissue periodontal ligament undergoes changes by age either in its fibers, ground substance, cells or blood vessels.

Aim of the work: This work aimed to assess the histological changes of periodontal ligament in different ages of albino rats and correlating these changes with corresponding human ages.

Material and Methods: 30 rats were divided evenly into 2 groups (15 rats each). Group 1: 6 months old group and Group 2: 24 months old group rats. Rats were terminated by I.V. overdose of sodium thiopental, the mandibles of the rats were excised to allow for laboratory processing for H&E stain, Masson's trichrome stain and Periodic acid -Schiff (PAS) with subsequent examination, 30 periapical films from two categories of persons aged between 16-18 years and 68-72 years old.

Results: Histologically, group 2 showed significant reduction in immature fibers, cells and ground substance. Statistically, regarding morphometric analysis of periodontal ligament width in periapical human films, there were no significant difference in width between oblique and apical regions in both rats and human. Both experimental rats and human showed increased PDL width by age

Conclusion: There is gradual reduction in fibers and cellularity of periodontal ligament by aging. However, periodontal ligament width mostly increased by age in rats and in examined periapical films in human.

Copy Right, IJAR, 2020,. All rights reserved.

Introduction:-

The periodontal ligament is a fibrous connective tissue that is highly innervated and vascularized (Katchburian and Arana, 2004). Periodontal ligament connects the root of teeth with the alveolar bone. The periodontal ligament has two main functions: 1- transmission and absorption of mechanical stresses, as it is responsible for shock absorption and proprioceptive sensorial perception aiming to comfort dental arch during chewing. 2- provide vascular supply and nutrients to cementum, alveolar bone and periodontal ligament itself (Nanci and Bosshardt, 2006).

Corresponding Author:- Esraa Ezzeldin Mohamed

Address:- Egyptian Russian University Faculty of Dentistry Oral Biology Department.

The orientation of fiber bundles is classified according to their location into gingival and principal, the principal fiber groups are alveolar crest, horizontal, oblique and interradicular. The gingival groups are the ligament fibers in the gingival lamina propria and they are: transseptal, dentogingival, alveogingival and circumferential. Their function is to resist tooth separation and gingival displacement (Bellows et al., 1981).

The extension of principal fibers of periodontal ligament into tooth cementum and bone is called Sharpey's fibers (Katchburian and Arana, 2004).

Fibroblasts constitutes about 50-60 % of total periodontal ligament cellularity. Periodontal ligament fibroblasts are heterogenous because they consist of multiple subpopulations. Periodontal ligament cells are suitable to respond to mechanical stresses (Kantarci et al., 2016).

Other cells in periodontal ligament are cementoblasts and osteoblasts which are formative cells that are showing synthetic activity and are originated from ectomesenchymal cells. There are also epithelial rests of Malassez in the form of islands, strands or network derived from remnants of epithelial root sheath of Hertwig (Berkovitz et al., 2002). The periodontal ligament further contains defense cells such as macrophage, mast cells and plasma cells (Kantarci et al., 2016).

The Periodontal ligament also contains ground substances, All the components of the PDL ground substance secreted by fibroblasts. Its composition varies according to the developmental state of the tissue and location (Berkovitz et al., 2002).

Periodontal ligament is a type of tendons, tendon aging is associated with disorganization and diminished collagen content, which alters the biomechanical response of tendon tissue (Reeves et al., 2006). The functional characteristics of periodontal tissue cells have been altered by the aging process (Abiko et al., 1998)

The width of the periodontal ligament in human molars ranges from 0.15–0.38 mm, with the thinnest part around the middle third of the root. The corresponding values for mouse molar periodontal ligament are 0.1–0.13 mm. It has been reported that the periodontal ligament thickness decreases with age (Barczyk.M. et al., 2013).

Numerous methods have been investigated in several studies to correlate the ages of small mammals with that of a human, i.e. using the weight of the eye lens (Hardy et al., 1983) growth of molar teeth (Pankakoski .E., 1980) counting of endosteal layers in the tibia (Broughton et al., 2002) musculoskeletal growth along with the closure and thickening of the epiphyses (Kahana et al., 2003) , but all of the techniques are relative methods and do not exactly define the absolute age; thus, researchers generally employ more than one method at a time to have a proper idea about the age of the experimental animal.

Recently, Sengupta 2012 supposed that one week of rat age is corresponding to almost one month of human age.

Rare studies highlighted the age changes of periodontal ligament components in details in rats and correlated this with human approximate age.

Material and Method:-

Sample collection:

Animal Model:

Thirty adult, male Wistar albino rats (*rattus albus*) weighing 150-200 grams were collected from the animal house of Ain Shams University to be used in this study.

Animal Housing and Living Conditions:

The rats were caged in stainless steel cages with 5 rats per cage at the Medical Research Center (MRC) – Animal House Unit, Ain Shams University. Under supervision of a specialized veterinarian, the rats were given access to a regular diet of bread and tap water ad libitum. The proper ventilation and nutrition conditions that ensure good and clean working environment were followed. The protocol was reviewed and accepted by the Research Ethics committee of the Faculty of Dentistry, Ain Shams University.

Animal Grouping:

The rats were divided evenly into 2 groups of 15 rats each.

The animals were grouped in the following manner:

Group 1: 6 months old group equivalent to almost 18 years in human.

Group 2: 24 months old group equivalent to almost 72 years in human.

These based on what have been reported by **Sengupta. P. at 2012** who stated that, one human year almost equals two rat weeks (13.8 rat days) while correlating their entire life span.

II- Sacrifaction:

1. Rats were terminated by I/V administration of anesthetic overdose of sodium thiopental 80 mg/kg.
2. The mandibles of the rats were excised to allow for laboratory processing and examination by H&E stain, Masson's trichrome stain and Periodic acid –Schiff (PAS).
3. Carcasses and wastes of the used animals were hygienically disposed of by incineration.

Staining:

a- Haematoxylin and Eosin (H&E) stains: Specimens were transferred to ethylene diamine tetra acetic acid (EDTA), then washed under running water, dehydrated by ascending concentrations, transferred to xylol to clear the alcohol, then infiltrated by paraffin wax and embedded in paraffin wax blocks, Sections were transferred in descending concentrations of alcohol and mounted on glass slides for staining with Hematoxylin and Eosin (H&E) stain and examination by light microscope.

b- Masson Trichrome (MT): Masson's trichrome staining was used to examine collagen fibers as an indicator of age changes occurring in periodontal tissue.

c-Periodic Acid Schiff (PAS): Periodic acid Schiff was used to examine ground substances changes occur during aging of periodontal ligaments., clearing in xylol and mounting in Canada balsam was performed).

Thirty Periapical films of mandibular molar region from persons of equivalent human ages were obtained to correlate widths age changes. The films were classified as follows:

Young group: periapical films from individuals aged between (16-18 yrs.).

Old group: periapical films from individuals aged between (68- 72 yrs.).

Measurement of periodontal ligament width:

Width of periodontal ligament in rats samples was measured by histomorphometry at faculty of dentistry Ain shams university using image J software.

Width of periodontal ligament of human was measured by x-rays periapical films using digital sensor.

Width in both human and rat samples was analyzed in two histological thickness of root middle and apical.

Six readings from each region were recorded and the average mean value is calculated.

Statistical Analysis:

Recorded data were analyzed using the statistical package for social sciences, version 20.0 (SPSS Inc., Chicago, Illinois, USA). Quantitative data were expressed as mean \pm standard deviation (SD). Qualitative data were expressed as frequency and percentage.

Histological results:**Hematoxylin & Eosin Staining:****First Group Gp-1 (Young group 6 mth rats):**

Examination of the (H&E) stained sections of the periodontal ligaments surrounding the lower first molar of rats of the first group revealed collagen fiber bundles of the periodontal ligament (PDL) which were dense and rich in fibers with little ground substance in between them. The bundles showed a regular arrangement, taking their characteristic wavy course as they traveled from cementum to bone (**Fig 1a**). All of the collagen fiber groups showed their regular course and orientation. (**Fig 1b**)

Parts of the collagen fiber bundles were found inserted into the cementum and bone and are known as Sharpey's fibers.

Fibroblasts were found arranged along the axes of the collagen fiber bundles. They were elongated and tapering with thin cytoplasmic extensions. The nuclei of the fibroblasts were oval in shape and ran parallel to each other.

Zuckermandle and Hirschfeld canal is seen perforating the bone carrying vessels (**Fig 1c**).

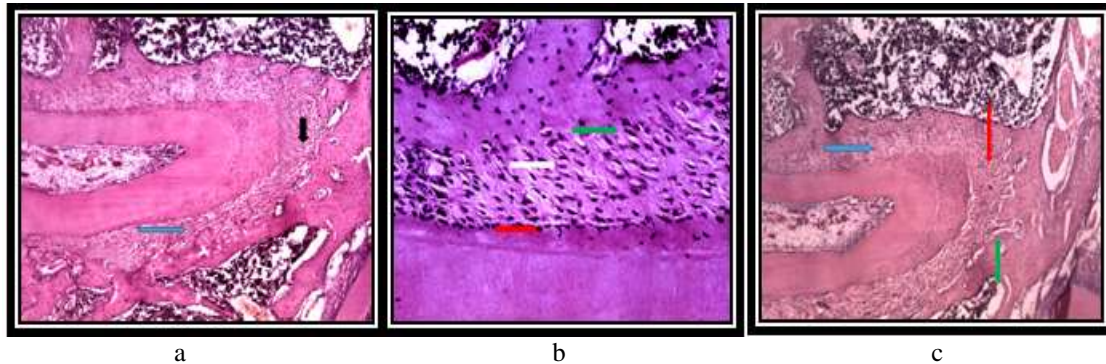


Fig. 1:- a: Photomicrograph of the periodontal ligament of the first group showing oblique (blue arrow) and apical fibers (black arrow) featuring almost normal cellularity, orientation of fibers and normal attachment of periodontal ligament fibers to bone and cementum. b: Higher magnification (x 400) showing oblique fibers featuring dense collagen bundles (white arrow) with normal orientation and attachment to bone (green arrow) and cementum (red arrow). c: oblique fibers (blue arrow) and apical fibers (red arrow) featuring normal cellularity and bone surface is perforated by zuckermandle and Hirschfeld canals (green arrow). (H and E, x200).

Second Group GP-2 (Old group 24 mth rats):

Examination of the (H&E) stained sections of periodontal ligament surrounding the lower first molar of the rats belonging to the old group revealed collagen fiber bundles of PDL whose collagen component was not abundant. The bundles showed obviously thin, deficient fibers with wide spaces in between them. Arrangement of the bundles was distorted, leading to loss of their normal wavy course from bone to cementum, Sharpey's fibers inserting into the cementum and bone were severed in many areas where they should be attached (**Fig 2a & b**).

Observation of the principal collagen fiber groups of the PDL showed irregular arrangement and severing of collagen fiber bundles with large spaces of periodontal dissociation. The apical group of PDL also showed thin fiber bundles arranged in many different directions (**Fig 2c**).

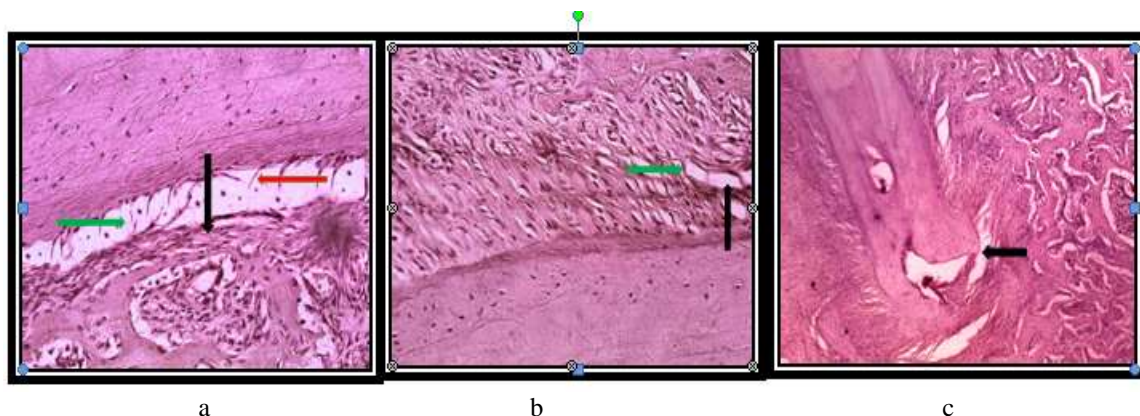


Fig. 2:- a: The periodontal ligament of the old group showing thin deficient oblique fibers (red arrow) distorted arrangement with areas of periodontal ligament (green arrow), lack of parallelism between nuclei of fibroblasts and severing of Sharpey's fibers insertion (black arrow) (H and E, x 400). b: oblique fibers showing thin deficient fiber bundles of the periodontal ligaments (green arrow) in a distorted arrangement with areas of periodontal dissociation (black arrow) (H and E, x 400). c: apical and oblique fibers featuring distorted arrangement of with areas of periodontal dissociation (black arrow). (H and E, x 200).

B. Collagen Fiber maturity assessment by Masson's Trichrome Staining:**First Group:**

Examination of the Masson trichrome (MT) stained sections of the periodontal ligaments oblique and apical groups surrounding rat lower first molar from the first group, revealed predominance of blue color in apical and oblique regions (**Fig 3a & b**)

Second group:

Examination of (MT) stained sections of the periodontal ligaments surrounding the lower first molar of rats of the second group revealed predominance of red color in oblique and apical regions (**Fig 3c & d**)

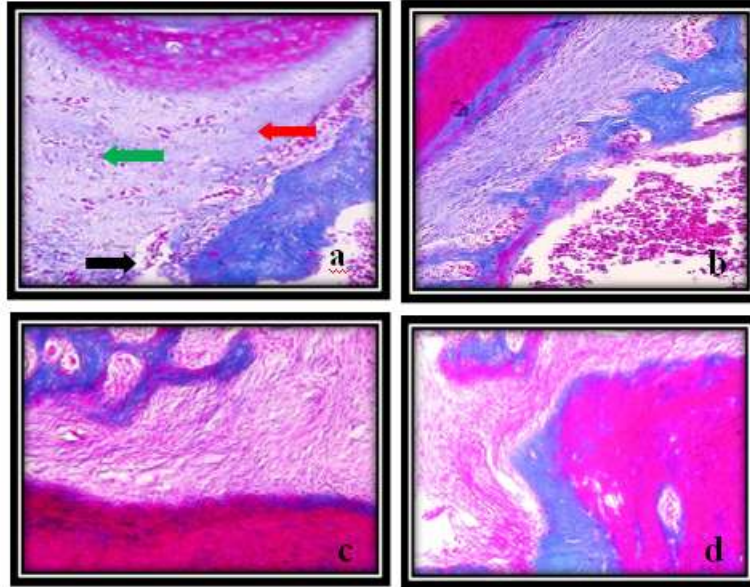


Fig. 3:- Photomicrographs of the periodontal ligament fibers of the first group showing apical (**a**) and oblique fibers (**b**) featuring predominant blue (Red arrow) and red (green arrow) mature collagen fibers in regular orientation with interstitial tissue containing blood vessels (Black arrow). The periodontal ligament fibers of the old group showing oblique (**c**) and apical fibers (**d**) featuring predominance of red color (**MT, x 200**).

Ground substances assessment by Periodic Acid Schiff Staining (PAS):**First Group:**

Examination of the (PAS) stained sections of the periodontal ligaments surrounding the lower first molar of rats of the first group revealed predominance of intense purple magenta color in oblique and apical groups (**Fig. 4a & b**).

Second group:

Examination of the Periodic Acid Schiff (PAS) stained sections of the periodontal ligaments surrounding the lower first molar of rats of the third group revealed pale color at place of fibers (**Fig. 4c & d**).

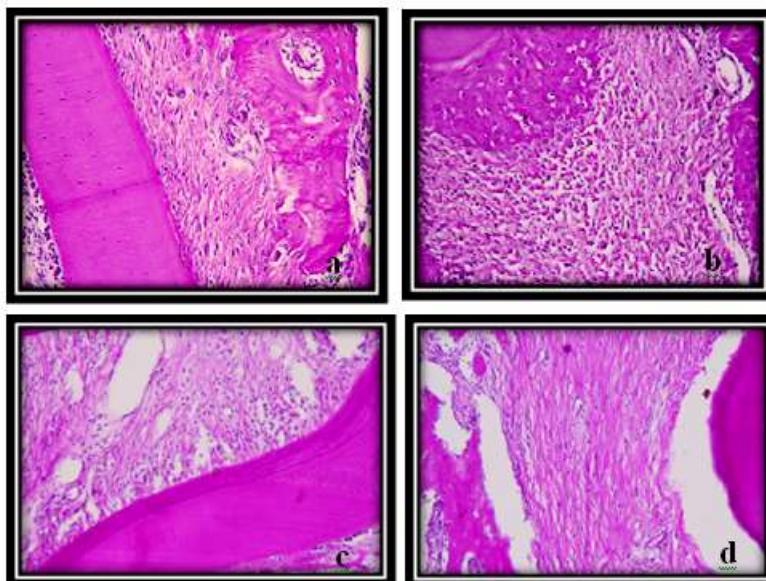


Fig. 4:- Photomicrographs of the periodontal ligament of the first group showing oblique (a) and apical (b) fibers featuring predominance of the purple magenta color. The second group showing oblique (c) and apical (d) fibers featuring pale purple color (PAS, x 200).

Measurement of width of periodontal ligament in human by X - rays:

First group (16- 18 yrs old persons):

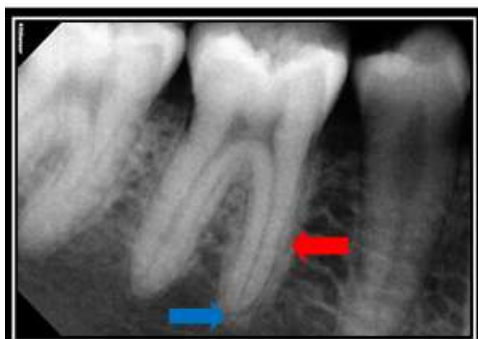

Fig. 5:- A radiographic picture showing width of oblique (red arrow) and apical (blue arrow) periodontal ligament at molar region of young group.

2-Second group (68-72 yrs old persons):

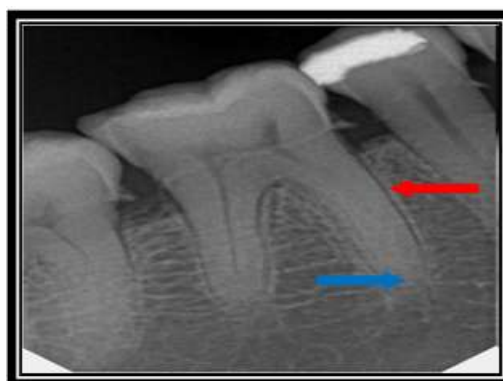


Fig. 6:- A radiographic picture showing width of oblique (red arrow) and apical (blue arrow) periodontal ligament at molar region of the old group.

Statistical Results:-

Histomorphometry statistical analysis for the measurement of periodontal ligament width in periapical films of human and H and E sections of rats. The statistical results revealed that at young age group of rats' average width was from 25400 to 120660.3 pixels and at old age group was from 42862.495 to 228649.45 pixels.

While human width of periodontal ligament (measured from smaller scale) at young age group was ranging from 589.7562 to 3035.829 pixels which is equivalent to 0.002 – 0.011 mm, and at old age group was from 1258.5347 to 2855.5602 pixels which is equivalent to 0.004 – 0.010 mm at apical fibers.

By statistical tests we found that there were significant differences between groups, in rats p-value <0.05 and in human (*p-value <0.05 S).

The results were demonstrated as follows:

Table (1):- Comparison between width level of age according to their rats regarding middle and apical regions.

Rats	Young age	Old age	F	p-value
Oblique				
Mean±SD	50768.31±20572.67	110840.65±46847.48ab	9.590	<0.001**
Range	20637.50-87442.4	28574.996-200081.6		
Apical				
Mean±SD	59932.88±26322.01	123568.65±65118.30ab	5.770	0.008*
Range	25400-120660.3	42862.495-228649.45		

F-One Way Analysis of Variance

*p-value <0.05 S; **p-value <0.001 HS

Post HOC: a: Significant difference with young age; b: Significant difference with middle age

This table showed statistically significant difference between groups according to PDL width in rats regarding middle and apical regions.

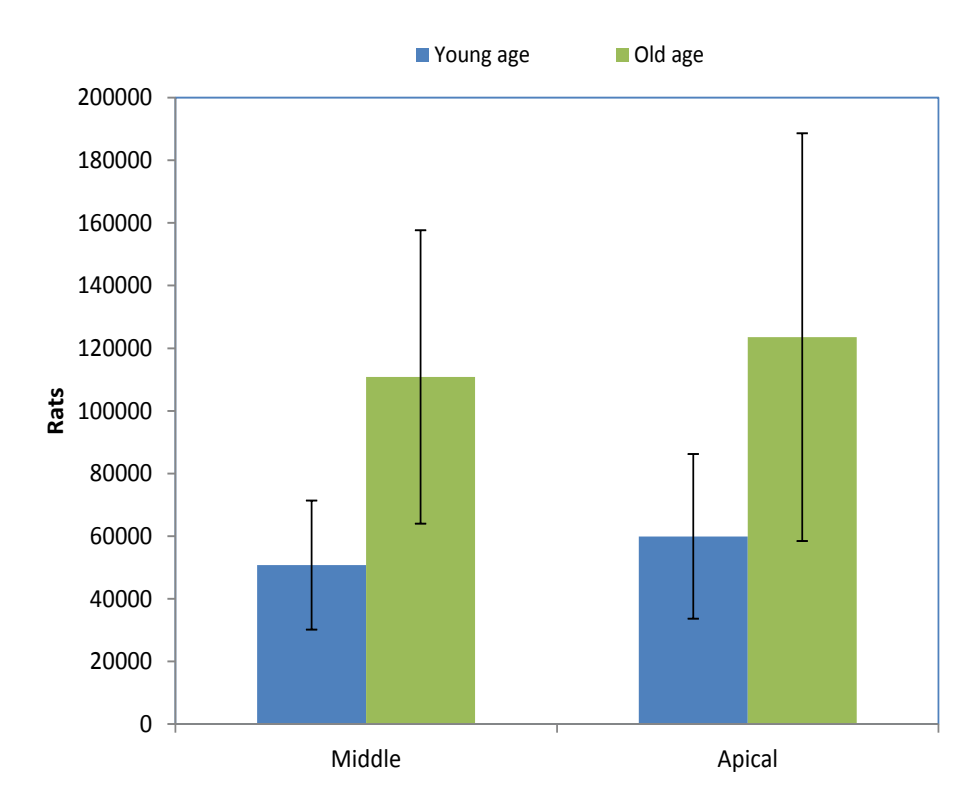


Fig. 7:- Bar chart showing PDL width levels between different rat groups in middle apical root regions.

Table 2:- Comparison between human age groups regarding middle and apical.

Human	Young age	Middle age	Old age	F	p-value
Oblique					
Mean±SD	1787.97±729.96	698.35±308.07a	2031.78±714.30b	5.202	0.028*
Range	734.9243-2531.18	379.5006-1119.981	1330.5894-2711.9788		
Apical					
Mean±SD	1965.13±1042.55	672.01±211.56a	1915.14±835.48b	3.508	0.035*
Range	589.7562-3035.829	427.7431-796.6603	1258.5347-2855.5602		

F-One Way Analysis of Variance

p-value >0.05 NS; *p-value <0.05 S

Post HOC: a: Significant difference with young age; b: Significant difference with middle age

This table showed statistically significant difference between groups according to their human regarding middle and apical.

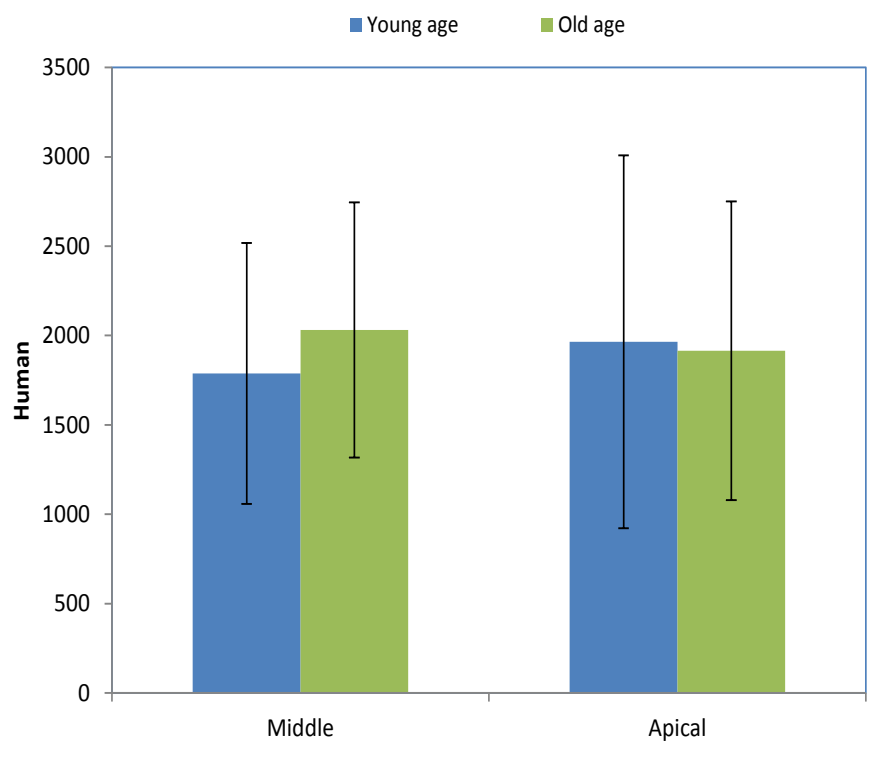


Fig. 8:- Bar chart showing pdl width levels between different human groups in middle and apical root regions.

Discussion:-

Periodontal ligament is a fibrous connective tissue which is mainly composed of collagen fibers type 1, it also contains cells which are mainly fibroblasts, the ligament fibroblasts play a key role in tooth eruption (Weinreb et al., 1997). Therefore, the periodontal ligament is an important connective tissue as it has many functions, it has an eruptive, sensory (Avery, 1999), supportive function (Matsuo et al., 2002) and it share in homeostasis (Wesselink and Beertsen, 1994). Lan Haung et al., 2016 reported that the periodontal ligament is considered as tissues that form at the sites of stress concentration and typically attach mineralized tissues to one another, the calcified portion become enlarged and the fibrous component become smaller with age.

Albino rats were chosen for this study because they are considered relevant models for experimental periodontal research (Struillou et al., 2010), owing to the similarity in the structure of their dentogingival area and nature of the junctional epithelial attachment (Yamasaki et al 1979). The structure and organization of rat periodontal tissue and

anatomy in the molar region is also similar to that of humans, with the exception of their sulcular epithelium, which is keratinized rather than non-keratinized as in humans (Teixeira et al., 2017).

Alveodental ligament groups are mostly occupied by oblique and apical fibers, so they were chosen for examination.

For ethical concerns we could not measure the width of human periodontal ligament histologically, so we rely on periapical x ray films on lower molar region from persons of corresponding rat ages.

Our hematoxylin and eosin staining of the periodontal ligament of the first group which represent young aged rats showed normal cellularity, parallelism between nuclei, dense collagen fibers. We noted that The Periodontal Ligament attachment via Sharpey's fibers, which insert into cementum and alveolar bone. These was ensured by Masson trichrome stain which evaluate collagen synthesis and degeneration, as it stains new collagen blue, while cytoplasm, red blood cells and fibers red (Brainman- Wiksman et al., 2007).

Masson trichrome results of the first group showed predominance of the blue colour and this is an evidence that the collagen formation is more than degeneration and that fibroblasts are continuously forming collagen. These results agreed with Gihan.H et al , 2018 when they conducted a study on adult albino rats to know hazards of soft modern food on the periodontal ligament , they found that histological assessment of specimens from 12 weeks old rats fed on hard diet showed normal architecture of the periodontal ligament at this age , Histological staining by masson trichrome stains revealed proper arrangement of mild to moderate staining of fine and coarse collagen fibers besides active fibroblasts with rounded dark nuclei (Suvic A and Effendy A , 2012 and Guzman A et al ,2009).

Periodic Acid Schiff stain was used to assess the amount of ground substances at different ages, it stained ground substances by purple magenta color.

In our Periodic Acid Schiff results We observed that at young age, intense PAS reaction, this result revealed normal fibroblasts count and function.

Komatsu et al, 2007 stated that "the fibrous architecture of periodontal ligament reflects a biological adaptation to mechanical stimuli". The aggregation and organization of collagen are influenced by duration and frequency of these stimuli onto the connective tissue. At young age, there were a high proportion of type III collagen. this predominance may be related to the fact that this type of collagen is the first to be synthesized considered as young collagen. Later this collagen is replaced by mature collagen.

The periodontal ligament of the second group showed changes with age, periodontal ligament showed marked decrease in fibroblasts count and function as collagen fibers also decreased and the periodontal ligament exhibited uneven and irregular Sharpey's fibers insertion, which is in accordance with Svensson et al who reported that in aged mice there are reduction in collagen content and thinning in fibers.

We also noticed a decline in cellularity as age advances. These results agreed with Lopez Otin et al, 2010 who reported that reduced cellularity is due to decrease in quantity of adult stem cells which are essential for maintenance of tissue homeostasis and regeneration. Consequently, the quantitative and qualitative decline in stem cell function during life known as stem cell exhaustion has been proposed as one the divers of aging. Svensson et al., 2017 conducted a study to show effect of aging on tendons and it had been observed that there are Changes in cell function with age are also supported by in vitro studies on primary tendon cell cultures.

Cell proliferation has been reported to decrease with old age both in injured human supraspinatus, as well as rat and mouse Achilles tendon. The studies in rat and mouse also observed an age-related reduction of cell migration speed in vitro (Svensson et al., 2017). Therefore, decreased cellularity in periodontal ligament of the third group is due to decrease in cell proliferation and stem cells quantity and quality.

There were detachment of fibers from cementum surface and bone surface and also there were spaces between fibers , these findings were coincident with Jacqueline et al., 2013 when they conducted a study to see effect of ascorbic acid on aged rats , They found that there were high proportion of type III collagen in old aged rats and they suggested that this may be due to reduction of ascorbic acid which is a vitamin essential for maintenance of type I

collagen and its absence probably leads to reduction in fibers proportion, this was supported by the fact that elders have reduced level of ascorbic acid and consequently proline residues are not hydroxylated, therefore alpha chains of tropocollagen are incapable to form stable helix and these helices cannot form fibrils, affecting structure of periodontal ligament (Azulay et al 2003).

Masson trichrome staining of the second group periodontal ligaments revealed an obvious diminution in blue colour intensity and predominance of the red one, this is an evidence that there was marked reduction in collagen by age, these results agreed with Rabia, 2017. They found that aged skin featured sparse, fragmented and disorganized collagen (Demaria et al, 2015 and Zoubolis and Boschnakow, 2001).

Periodic Acid Schiff staining of second group revealed obvious decrease in intensity of purple magenta color, as a result of reduction of fibroblasts amount and function with subsequent decline in ground substance production.

Our study demonstrated that there were significant differences between groups when we measured periodontal ligament width.

Statistical analysis results revealed that in rats width of periodontal ligament increased by age, this results disagreed with Katchburian and Arana, 2004 as they found that thickness of periodontal ligament at various regions of root decrease by age. There was no significant difference in width of periodontal ligament between middle and apical parts of root. However, our results agreed with Narita et al. 2012, as they undertaken a study on rats to see age related adaptation of bone –periodontal ligament tooth complex, he found that there was increase in cementum deposition and in measured radial width in rats from 14 to 500 days, this increase was due to increase in function and load on teeth. Also an overall periodontal ligament space demonstrated a gradual decrease after 1.5 months and an increase around 10 and 12 months. These results can be explained as follow, there is an evidence supporting loss of functional efficiency in joints with age due to innate decrease in metabolic rate of cells within mineralized and soft tissues, as well as the soft- hard and hard- hard tissues interfaces (Barros et al, 2002). Age changes were related to changes in periodontal ligament mechanical properties, turnover rate, periodontal ligament width and density.

Osmar et al at 2012, stated that ‘periodontal ligament thickness is directly proportional with root dimensions and root size’. Our results were coincident with their results, as we noticed increase in periodontal ligament width with age. This may be due to the over load on teeth roots which results in cementum deposition leading to increase in root dimension.

In human the width of periodontal ligament increased at old age group. At middle part of the root old age group showed wider periodontal ligament thickness than young age group, at apical part of root there were no difference between young and old age there were approximately equal.

Further studies seem to be required to compare between the aging behavior in different animal species or to follow up the aging criteria of specific constituents of periodontal ligament.

Conclusions:-

1. Periodontal ligament is a dense fibrous tissue supporting teeth and physiologically undergoes structural and functional age changes.
2. Well organized mature evenly distributed fiber bundles, normal cellularity with parallelism of cells between fibers and strongly attachment of Sharpey's fibers to both bone surface and root surface were the criteria of young aged periodontal ligament.
3. Disorganized thin irregular fiber bundles, decreased cellularity and severely attached Sharpey's fibers to both bone surface and root surface were the criteria of old aged periodontal ligament.
4. Periodontal ligament width was increased by age in rats and human, while there was no significant difference between oblique and apical fibers regarding width dimension.

References:-

1. Avery, J.C.D. : Essentials of Oral Histology and Embryology: A Clinical Approach (2nd edn). Mosby, London, 1990.

2. Barczyk , M. , Malgorzata , B. Anne , I. and Donald , G. : Role of integrins in the periodontal ligament : organizers and facilitators . periodontal 2000;63(1):29-47 , 2013.
3. Barros, E., Rodrigues, c., Rodrigues, N., Oliveira, R. and Barros, T. :Aging of the elastic and collagen fibers in the human cervical interspinous ligaments . Spine J.;2:57-62, 2002.
4. Bellows , CG. , Meicher , AH. and Aubin , J. : Contraction and organization of collagen gels by cells cultured from periodontal ligament , gingiva and bone suggest functional difference between cell types . j cell sci : aug ;50:299-314, 1981.
5. Berkovitz, B.K.B., Holland, G.R. and Moxham,B.j.: Oral Anatomy, Embryology and Histology. 4th edition, 2002.
6. Biondo-Simoes-Mde, L., Westphal, V.L., Paula, J.B, Borsato, K.S and Noronho L. : Collagen synthesis after the implantation of polypropylene nets in the abdominal wall of young and old rats. Acta Cir Bras 20: 300-304, 2005.
7. Brainman-Wiksman, L. , Solomonik, I. , Spira, R. and Tennenbaum, T. : Novel insights into wound healing sequence of events . toxicol pathol ; 35:767-779 , 2007
8. Broughton, J.M. , Rampton, D. and Holanda, K. : A test of an osteologically based age determination technique in the Double crested Cormorant **Phalacrocorax auritus**. Ibis. ;144:143–6 , 2002.
9. Demaria, M. , Desprez, P.Y. , Campisi, J. and Velarde, M.C. : Cell autonomous and non-autonomous effects of senescent cells in the skin. J. Investig. Dermatol. ;135, 1722–1726 , 2015.
10. Gihan, S., Reda, S. and Dalia, H.: Hazards of soft modern food on the periodontium of adult albino rats. DOI:10.4103:P178-185, 2018.
11. Guzmán, M. , Silva, H. , Méndez, G. , Martín, P. , Cerda, C. and Cohenca N.: The effect of Emdogain and 24% EDTA root conditioning on periodontal healing of replanted dog's teeth. Dent Traumatol; 25:43–50, 2009.
12. Hardy, A.R. , Quy, R.J. and Huson, L.W. : Estimation of age in the Norway rat (**Rattus norvegicus**) from the weight of the eyelens. J Appl Eco. ;20:97–102, 1983.
Kahana, T. , Birkby, W.H. , Goldin, L. and Hiss, J. : Estimation of age in adolescents: The basilar synchondrosis. J Forensic Sci. ;48:1–5, 2003.
13. Jacqueline, N.Z. , Nathalia, M.L. , Aline, R.T. and Ivan, D.S. : Histological evaluation of the periodontal ligament from aged wister rats supplemented with ascorbic acid Vitamin C. An Bras Dermatol 78: 265-274, 2013.
14. Kantarci , A. , Konermann , A. , Vandyke , T. and Jager , A. : GABA b receptors as modulating target for inflammatory responses of the periodontal ligament . cell mol neurobiol : aug 37(6):1067-1076 , 2016.
15. Katchburian , E. and Arana , V. : Tooth enamel : frontiers in mineral chemistry and biochemistry integrative cell biology and genetics , 2004.
16. Komatsu , K. , Tatsaya , S. and Akemi , S. : Analysis of contribution of collagen fiber component in viscoelastic behaviour of periodontal ligament using enzyme probe . jornal of biomechanics;2700-2706 , 2007.
17. Lan, H. , Benjamin, S. , Xing, Y. and Jill, A. : From restoration to regeneration:periodontal aging and opportunities for therapeutic interventio. Periodontal 2000 72(1) : 19-29, 2016
18. Lopez , M. , Pedro , J. , Ivan , G. , Veronica , R. and clara , B. : human induced pluripotent stem cells develop teratome more efficiently and faster than human embryonic stem cells regardless the site of injection . stem cells28(9), 1568-1570 , 2010.
19. Matsuo, M. and Takahashi, K. :Scanning electron microscopic observation of microvasculature in periodontium. Microscopy Research and Technique. ; 56: 3-14, 2002.
20. Nanci , A. and Bosshardt , D. : structure of periodontal tissues in health and disease ; periodontal 2000 L40-11-28, 2006.
21. Narita, L., Jonathen, M., Sabra, I., Stuart,A., Mark, I. and Sunita, P. : Age related adaptation of bone – periodontal ligament – tooth complex :Rattus – Norivegicus as a model system. doi:10.1371/j ;7(4), 2012.
22. Osmar, A., Pedro, M., Carlos, A. and Marcos, R.: Importance of periodontal ligament thickness. Doi:10.1590/S;27(1):76-9, 2013.
23. Pankakoski, E. : An improved method for age determination in the muskrat, Ondatra zibethica (L.) Ann Zool Fennici.;17:113–21, 1980.
24. Rabia , D. : the periodontal ligament development , an atomy and function . vola6 , 2017.
25. Reeves, N.D. , Narici, M.V. and Maganaris, C.N. : Myotendinous plasticity to ageing and resistance exercise in humans. Exp Physiol.;91:483-498. 2006.
26. Sengupta, P. A Scientific Review of Age Determination for a Laboratory Rat: How old is it in comparison with Human age? Biomed Int.;2:81–9, 2012.

27. Suvik, A. and Effendy, A. : The use of modified masson'strichrome staining in collagen evaluation in wound healing study. MJVR ; 3:39–47, 2012.
28. Svensson, R. Heinemeier, K. , Couppe, C. , Kjaer, M. and Magnusson, P. : Effect of aging and exercise on the tendon I. jappl physiol . 00328, 2017.
29. Teixeira, A. , Jordânia, M. , Luzia H. , Antônia, T. , Nayara, A. , Angela, M. , Francisca, R. , Iracema, M. , Igor, I. , Karuza, M. , Paula, G. , Jose, J. , Gerardo, C. , Vicente, D. , Helliada, V. , and Mirna, M. : Stemodia Maritima Extract Decreases Inflammation, Oxidative Stress, and Alveolar Bone Loss in an Experimental Periodontitis Rat Model." Frontiers in Physiology 8: n. pag:00988, 2017.
30. Weinreb, M. , Gal, D. , Weinreb, M.M. and Pitaru, S. : Changes in the shape and orientation of periodontal ligament fibroblasts in the continuously erupting rat incisor following removal of the occlusal load. Journal of Dental Research.; 76: 1660-1666, 1997.
31. Wesselink, P.R. and Beertsen, W. : Ankylosis of the mouse molar after systemic administration of 1-hydroxyethylidene-1,1bisphosphonate (HEBP). Journal of Clinical Periodontology.; 21: 465-471, 1994.