



Journal Homepage: - www.journalijar.com

INTERNATIONAL JOURNAL OF ADVANCED RESEARCH (IJAR)

Article DOI: 10.21474/IJAR01/10880

DOI URL: <http://dx.doi.org/10.21474/IJAR01/10880>



RESEARCH ARTICLE

RESULTS OF ADJUVANT PACLITAXEL AND CARBOPLATIN AFTER CONCURRENT CHEMO RADIATION (CCRT) IN LOCALLY ADVANCED CERVICAL CANCER (LACC)

Dr. B.K. Shewalkar¹, Dr. Punita Pant², Dr. Jitendra Patel², Dr. Roopa B.³ and Dr. H. Khadilkar²

1. Professor & Head, Department of Radiotherapy and Oncology, Government Medical College and Cancer Hospital Aurangabad, Maharashtra.
2. Associate Professor, Department of Radiotherapy and Oncology, Department of P.S.M, Government Medical College and Cancer Hospital Aurangabad, Maharashtra.
3. Resident, Department of Radiotherapy and Oncology, Government Medical College and Cancer Hospital Aurangabad, Maharashtra.

Manuscript Info

Manuscript History

Received: 18 February 2020

Final Accepted: 20 March 2020

Published: April 2020

Key words:-

Chemoradiation, Chemotherapy, Cervical Carcinoma, Paclitaxel, Carboplatin

Abstract

Background: Concurrent chemo radiation (CCRT) is the standard treatment for locally advanced cervical cancer (LACC) FIGO stage IIB-IVA. However, failure rate after treatment is still as high as 30% to 40% of which local and distant failures are 17% and 18% respectively and the 5-year survival is still poor. Aim of incorporating adjuvant chemotherapy (ACT) is to target the residual disease in the pelvis and to treat occult disease outside the pelvis.

Objective: This study aims to evaluate the feasibility and benefit of adjuvant chemotherapy (ACT) after CCRT in such patients to the improve treatment outcome.

Material and Methods: From July 2017-June 2018, eighty patients of LACC were prospectively evaluated. All patients received radiation upto 50Gy with Cisplatin 40 mg/ m² followed by intra-cavitary radiotherapy- 3fractions of 7 Gy each (28 Gy equivalent). Adjuvant chemotherapy with Paclitaxel (175 mg/m²) +Carboplatin (AUC 5) was planned for all patients to a median of four cycles (range 3–6 cycles).

Results: Eighty evaluable patients were enrolled for adjuvant chemotherapy. Disease-free survival after a median follow-up of 14 months (range 8-20) was 83.75% showing a significantly long term tumor control. The adjuvant chemotherapy was well tolerated. Hematologic and neurologic toxicities were most common side effects in our study however, they were manageable.

Conclusion: Incorporating adjuvant chemotherapy with Paclitaxel and Carboplatin after concomitant chemoradiation is effective, safe and may be a very promising treatment protocol for advanced cervical cancer.

Copy Right, IJAR, 2020,. All rights reserved.

Introduction:-

Cervical cancer is one of most common cancer in developing countries and the third leading cause of cancer death among females in less developing nations. There were an estimated 96,922 new cases and around 60,078 deaths

Corresponding Author:- Dr. Punita Pant

Address:- Associate Professor, Department of Radiotherapy and Oncology, Government Medical College and Cancer Hospital Aurangabad, Maharashtra.

each year in Indian women ^[1]. Nearly 90% of cervical cancer deaths occur in developing parts of the world as patient's presents in advanced stages due to suboptimal screening, lack of awareness and appropriate healthcare infrastructure ^[2].

Concurrent chemoradiation therapy (CCRT) is the standard of treatment for patients with locally advanced cervical cancer International Federation of Gynaecology and Obstetrics (FIGO) stage IIB to IVA, but majority of such patients do not survive five years post treatment ^[3-7].

Improving survival by giving adjuvant chemotherapy (ACT) is a modality to target residual lesion in the pelvis and also helps to eradicate occult disease to prevent metastasis. Other treatment modifications, chemotherapeutic drugs, targeted agents or consolidation chemotherapy are under study. A Phase III study has demonstrated that adding bevacizumab in patients with persistent, recurrent or metastatic cervical carcinoma increases progression-free survival (PFS) and overall survival (OS) ^[8].

In a Phase III study, Duenas-González A et al reported increased progression-free survival (PFS) with the use of adjuvant gemcitabine and cisplatin after concurrent chemoradiation with the same drugs as compared to use of cisplatin alone with radiation in patients with stage IIB to IVA carcinoma cervix. The use of adjuvant or consolidation chemotherapy have also explored in many trials – some of which showed an increased response rate, while the other did not report this advantage ^[9-12]. However, inconsistency in study design, chemotherapeutic interventions and result of survival benefit has been seen among various trials of ACT for LACC.

Paclitaxel has also shown to exert activity in advanced cervical cancer, alone and in combination with platinum analogues ^[13-16]. The combination of carboplatin and paclitaxel after radiotherapy has shown to be feasible in non-small cell lung cancer or head and neck cancer ^[17-19]. In these studies, local toxicity such as mucositis, oesophagitis and pneumonitis was increased, but this seldom resulted in treatment delay, while chemotherapy was hardly delayed for myelo-toxicity. Carboplatin has a number of advantages over cisplatin as it is less nephro- or neurotoxicity and has fewer gastrointestinal side-effects, albeit at the cost of more bone marrow depression ^[20-21].

We aimed to determine the role of adjuvant paclitaxel and carboplatin combination after concurrent chemoradiation in locally advanced cervical cancer patients. Because this regimen can be given in an outpatient setting; a feasibility study was hence performed.

Material and Methods:-

From July 2017-June 2018 this study was done to compare the feasibility and benefits of using CCRT plus ACT in patients of diagnosed cervical cancer FIGO stage IIB-IVA, with median follow up-14 (range 8-20) months.

Eligibility criteria:

Inclusion criteria:

Women with FIGO stage IIB-IVA cervical carcinoma, histological proven squamous cell carcinoma or adenocarcinoma who met the following criteria were eligible: no prior chemotherapy or pelvic radiotherapy, no concurrent other anti-tumour or investigational therapy; ECOG performance status ≤ 2 ; age > 30 and < 75 years; life expectancy ≥ 6 months; adequate bone marrow (leukocyte count $\geq 3.0 \times 10^9/L$ or platelet count $\geq 100 \times 10^9/L$); adequate hepatic and renal functions defined as bilirubin $\leq 1.5 \times$ and serum glutamic-oxaloacetic transaminase/serum glutamic-pyruvic transaminase $\leq 1.5 \times$ of the upper normal value; and creatinine clearance ≥ 40 mg/dL were recruited. Consent to participate were taken.

Exclusion criteria:

Patients with enlarged para-aortic lymph nodes on CT or MRI, cardiac failure, renal impairment/failure, peripheral or central neuropathy, uncontrolled diabetes mellitus or HIV/HBsAg/HCV infection, pregnancy or lactation.

Study design and treatment:

All patients received RT to whole pelvis 50Gy/25 fractions, one fraction per day, five days per week by a 6-15 MV photon beam with 3DCRT technique. Cisplatin 40 mg/ m² was administered weekly simultaneously with radiation. HDR- Intracavitary brachytherapy (ICBT) was given one week after completing external radiotherapy - 3 fractions of 7 Gy each (28 Gy equivalent) to reference point A (2 cm. superior and 2 cm lateral to the cervical os) on weekly basis. Overall treatment time (OTT) ranged from 55 to 65 days.

Four weeks after completion of brachytherapy response evaluation was done by abdominal and pelvic imaging (CECT /MRI) and gynaecological examination. Complete response (CR) was determined after gynecologic examination and defined as complete radiologic disappearance of the cervical lesion/s and no visible tumor. Partial response (PR) was determined by CT/MRI and gynecologic examination and defined as a decrease in tumor diameter of >50%. Stable disease (SD) was defined as <50% response to chemoradiation.

Adjuvant chemotherapy was administered to all the patients who had curative response as well as to patients who did not achieve complete response after CCRT to a median of four cycles (range 3–6 cycles). Each chemotherapy cycle consisted of Paclitaxel 175 mg/m² i.v.in 500 mL 0.9% NaCl glass bottle with codan set over 3hrs and Carboplatin AUC-5 according to Calvert formula (carboplatin dose = [creatinine clearance + 25] x AUC) i.v.in 500 mL 5% glucose over 60 min both on the same day every 3weekly. To avoid hypersensitivity reactions dexamethasone 16 mg, graniset 3 mg and ranitidine 50 mg were administered i.v.to all patients prior to initiation of Paclitaxel infusion. Patients went off study in, unacceptable toxicity or withdrawal of consent. The disease control and DFS were calculated using the Kaplan–Meier method.

Observation and Results:-

A total of 80 patients were treated and analyzed. The clinical characteristics of all patients are listed in Table- 1. The majority of patients had ECOG-1 status (81.2%), squamous cell carcinoma (96.25%), and tumour stage of IIIb (65%).

The complete response and partial response rates were 69/80 (86.25%) and 8/80 (10%), respectively while stable disease was found in 3 patients. Two patients developed local recurrence and distant metastases were observed in one patient (Table-2).

Disease free survival at the median follow up of 14 months was 83.75%.

One patient died from the disease (Table-3).

Table 1:- Patient characteristics.

	Number of patients
Total	80
Age, median (range) in years	50 (30– 75)
ECOG performance score	
0	5
1	65
2	10
Tumour histology	
squamous carcinoma	77
adenocarcinoma	03
Tumour stage	
IIb	21
IIIb	52
IVa	07

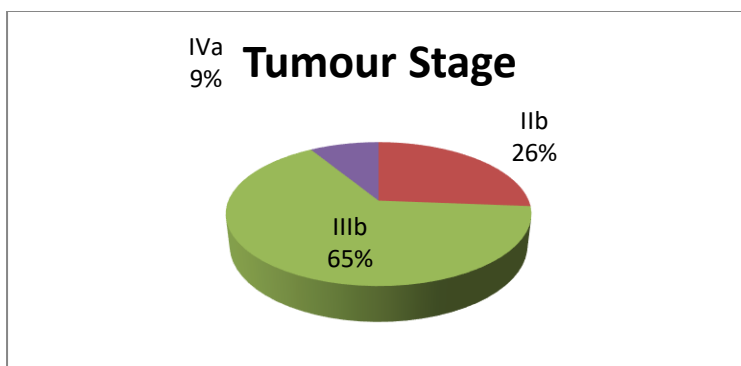


Table 2:- Response to treatment.

Response	After CT-RT	After Adjuvant CT
Complete response	66	69
Partial response	14	08
Stable disease	00	03
No response	00	00

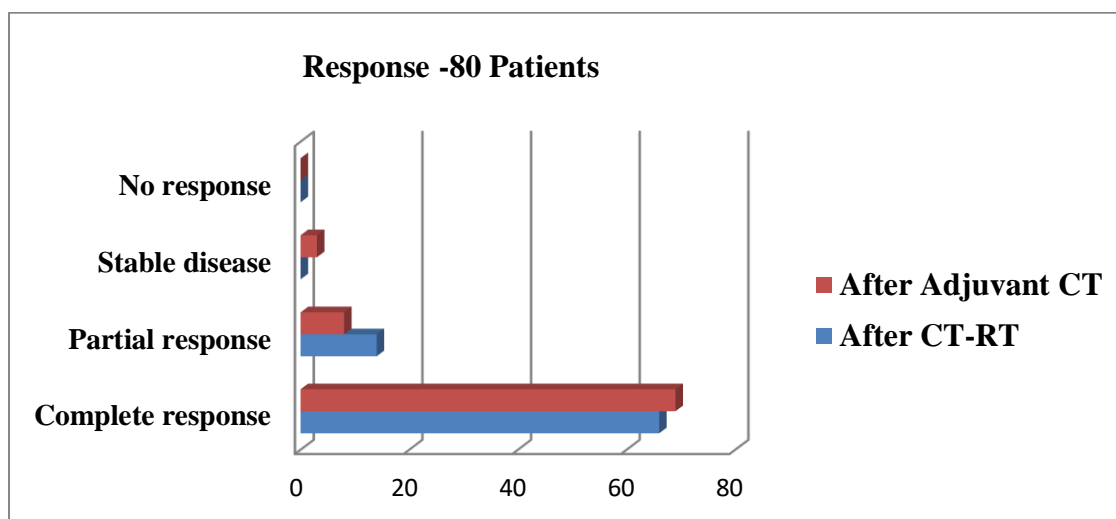


Table 3:- Follow up – Results.

	No of patients
Local recurrence	02
Distant metastasis	01
Disease free survival	83.75%

Treatment related toxicity was evaluated as shown in Table- 4.

The most troublesome side effects were hematologic and neurologic toxicities

Table 4:- Adverse reactions/toxicity.

	Grade				
	0	I	II	III	IV
Anemia	75	2	3	0	0
Neutropenia	64	13	3	0	0
Febrile Neutropenia	76	-	-	4	0
Thrombocytopenia	72	4	4	0	0
Hypersensitivity reaction	65	7	5	3	0
Fatigue	35	18	20	7	0
Anorexia/Nausea	30	34	12	4	0
Vomiting	41	25	14	0	0
Diarrhoea	66	8	6		0
Neurotoxicity	58	6	10	6	0

Table 5:- Statistical Analysis

Overall Comparisons:			
	Chi-Square	df	P value Sig.
Log Rank (Mantel-Cox)	42.882	1	.000
Breslow (Generalized Wilcoxon)	30.811	1	.000
Tarone-Ware	38.123	1	.000

Means and Medians for Survival Time								
RESPONSE	Mean ^a				Median			
	Estimate	Std. Error	95% Confidence Interval		Estimate	Std. Error	95% Confidence Interval	
			Lower Bound	Upper Bound			Lower Bound	Upper Bound
CR	19.574	.295	18.995	20.153
NCR	13.909	.803	12.335	15.483	15.000	.739	13.552	16.448
Overall	17.969	.467	17.054	18.884

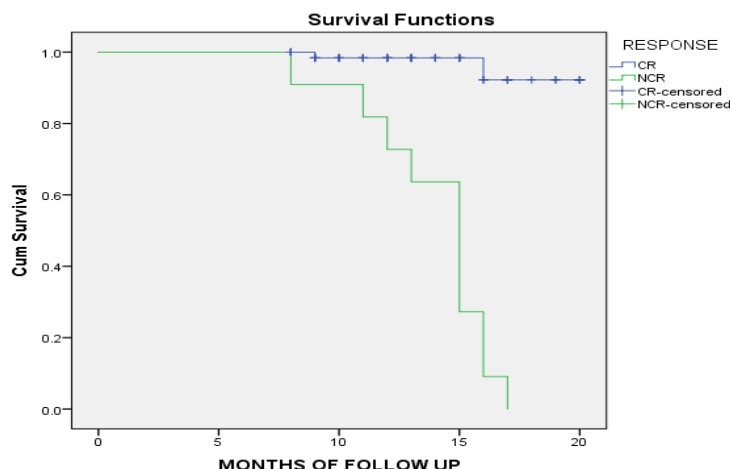


Figure 1:- Kaplan-Meier plot of disease free survival (DFS).

Mean survival time in Complete response category was 19.574 and Non complete response categories collectively was 13.909 (Table-5). All above tests were statistically significant means there was statistically significant difference in survival curves of CR and NCR categories, the disease free survival was better in complete response category than NCR category (Figure -1).

Discussion:-

For almost two decades in patients with bulky IB2–IVA disease CRT has been the standard of care (as endorsed by the National Cancer Institute) which is based on of five randomised trials, three in LACC, demonstrating an improvement in both disease-free survival (DFS) and OS with CRT over standard RT. The absolute survival benefit in FIGO stage I/II disease was 10% for CRT compared with RT alone and 3% for those with FIGO stage III/IVA. The most commonly used regimen is weekly cisplatin 40mg/m², although the meta-analysis also reported significant benefits with non-platinum agents [3-7].

Recurrences in cervical cancer patients can be seen in the form of local pelvic lesion and/ or distant metastases. A 10%-20% recurrence rate has been reported following primary surgery or radiotherapy in women with stage IB-IIA cervical tumors with no evidence of lymph node involvement, while up to 70% of patients with nodal metastases and/or more locally advanced tumors will relapse [22-25]. In bulky pelvic tumors the rate of local disease recurrence/persistence is far more common than developing distant metastases. With RT alone the pelvic failure rate as reported by Perez et al is 10% in stage IB, 17% in stage IIA, 23% in stage IIB, 42% in stage III, and 74% in stage IVA [26]. For patients in stage IA/ IB the reported incidence of distant metastases is 3%, and 16% while in stage IIA/IIB is 26% and 31%, in stage III is 39%, and in stage IVA is 75%.

Lung (21%) is the most common site of distant metastases followed by bone (16%) predominantly involving the lumbar and thoracic spine, para-aortic nodes (11%), abdominal cavity (8%), and supraclavicular nodes (7%). Patients who relapsed in lymph nodes had a median survival of 24 weeks, while those who relapsed in other organs had a median survival of only 12 weeks [27].

Most of the recurrences occurred during the follow up period within two years in stage II and III cervical cancers. Moderately differentiated carcinoma was associated with nodal recurrence while adenocarcinoma with distant metastasis. Histology, stage, age, treatment duration, toxicity gap, ICRT type, response and follow up pattern as variables was undertaken to study recurrences in LACC - of which stage, histology, toxicity gap and follow up pattern were found to effect survival.

New treatment strategies are being investigated for patients who are still potentially curable after radical treatment. However, most women are treated with palliative intent, it is possible to identify subgroups of patients with high potential who would have a substantially better prognosis and in whom the objective of treatment is cure [28-29].

Such approaches include –

(1.1) Neoadjuvant chemotherapy –An ongoing Phase III Multicentre trial of weekly induction chemotherapy followed by standard chemoradiation versus standard chemoradiation alone in patients with LACC- to analyse the overall survival , progression free survival , adverse events, quality of life and patterns of first relapse (local and/or systemic) - results awaited (INTERLACE)^[30].

(1.2) Tang et al^[31] demonstrated that using one cycle of neoadjuvant chemotherapy with paclitaxel and cisplatin before receiving radiation and two cycles of consolidation chemotherapy with the same drugs after radiotherapy at 3-week intervals improved localized disease ,distant metastases,overall and disease-free survival .

(2.1) Adjuvant chemotherapy- A Phase III trial of adjuvant chemotherapy with paclitaxel plus carboplatin to determine improvement in overall survival, progression-free survival, acute and long-term toxicities, patterns of disease recurrence and quality of life (OUTBACK)^[32].

(2.2) Jelavić et al has reported an increase in distant disease free survival with the use of concomitant chemoradiotherapy by adding cisplatin and ifosfamide along with LDR brachytherapy followed by adjuvant chemotherapy for four cycles with the same drugs^[33].

In our study, first follow-up after RT was done at four weeks and adjuvant chemotherapy was given to patients with complete response so as to eradicate the potential micrometastasis in order to prevent local and distant metastasis. This group of patients were found to have better clinical outcome and longer DFS without any unmanageable toxicity. Patients with suboptimal response/residual tumor were given adjuvant chemotherapy with the clinical understanding of their subsequent local and distant pattern of failure to achieve improved outcome and early CR.

Conclusion:-

Considering the poor prognosis of LACC and limited salvage treatment options for the patients with recurrent disease, the use of adjuvant chemotherapy is an attempt to improve the treatment outcome seems reasonable. Incorporating adjuvant chemotherapy with Paclitaxel and Carboplatin after concomitant chemoradiation is highly effective, safe and may be a very promising treatment protocol for advanced cervical carcinoma. We are still enrolling patients in view of encouraging results and in order to get long term follow up and to assess maximum disease free survival. Future large trials are required to demonstrate the need and efficacy, toxicities and QoL.

Disclosure:

The authors declare no conflict of interest.

References:-

1. Ferlay J, Soerjomataram I, Ervik M, et al. (2013) GLOBOCAN 2012 v1.0, Cancer Incidence and Mortality Worldwide: IARC Cancer Base No. 11. Lyon, France: <http://globocan.iarc.fr>. Accessed on 04 Sep 2014
2. Chemoradiotherapy for Cervical Cancer Meta-Analysis Collaboration. Reducing uncertainties about the effects of chemoradiotherapy for cervical cancer: a systematic review and meta-analysis of individual patient data from 18 randomized trials. *J Clin Oncol* 2008; 26: 5802–5812
3. Jemal A, Center MM, DeSantis C, Ward EM. Global patterns of cancer incidence and mortality rates and trends. *Cancer Epidemiol Biomarkers Prev*. 2010;19:1893–907. [PubMed]
4. Rose PG, Bundy BN, Watkins EB, Thigpen JT, Deppe G, Maiman MA, Clarke-Pearson DL and Insalaco S: Concurrent cisplatin-based radiotherapy and chemotherapy for locally advanced cervical cancer. *N Engl J Med* 340: 1144-1153, 1999. deVos et al: Radio-chemotherapy for Primary Cervical Cancer.
5. Morris M, Eifel PJ, Lu J, Grigsby PW, Levenback C, Stevens RE, Rotman M, Gershenson DM and Mutch DG: Pelvic radiation with concurrent chemotherapy compared with pelvic and para-aortic radiation for high-risk cervical cancer. *N Engl J*
6. Keys HM, Bundy BN, Stehman FB, Muddersbach LI, Chafe WE, Suggs CL III, Walker JL and Gersell D: Cisplatin, radiation, and adjuvant hysterectomy compared with radiation and adjuvant hysterectomy for bulky stage IB cervical carcinoma. *N Engl J Med* 340: 1154-1161, 1999.
7. Peters WA, Liu PY, Barrett RJ, et al. Concurrent chemotherapy and pelvic radiation therapy compared with pelvic radiation therapy alone as adjuvant therapy after radical surgery in high-risk early-stage cancer of the cervix. *J Clin Oncol*. 2000; 18:1606–1613.

8. Bevacizumab for advanced cervical cancer: final overall survival and adverse event analysis of a randomised, controlled, open-label, phase 3 trial (Gynaecologic Oncology Group 240) Tewari K S et al. *Lancet*. 2017 Oct 7;390(10103):1654-1663.
9. Vrdoljak E, Omrcen T, Novaković ZS, Jelavić TB, Prskalo T, Hrepić D, et al. Concomitant chemobrachyradiotherapy with ifosfamide and cisplatin followed by consolidation chemotherapy for women with locally advanced carcinoma of the uterine cervix--final results of a prospective phase II-study. *GynecolOncol* 2006;103:494-9.
10. Dueñas-González A, ZarbáJJ, Patel F et al. Phase III, open-label, randomized study comparing concurrent gemcitabine plus cisplatin and radiation followed by adjuvant gemcitabine and cisplatin versus concurrent cisplatin and radiation in patients with stage IIB to IVA carcinoma of the cervix. *J ClinOncol* 2011; 29: 1678–1685.
11. Choi CH, Lee YY, Kim MK, Kim TJ, Lee JW, Nam HR, et al. A matched-case comparison to explore the role of consolidation chemotherapy after concurrent chemoradiation in cervical cancer. *Int J RadiatOncolBiolPhys* 2011;81:1252-7.
12. SZhang MQ, Liu SP, Wang XE. Concurrent chemoradiotherapy with paclitaxel and nedaplatin followed by consolidation chemotherapy in locally advanced squamous cell carcinoma of the uterine cervix: preliminary results of a phase II study. *Int J RadiatOncolBiolPhys* 2010;78:821-7.
13. Kudelka AP, Winn R, Edwards CL, Downey G, Greenberg H, Dakhil SR, Freedman RS, LoCoco S, Umbreit J, Delmore JE, Arbuck S, Loyer E, Gacrama P, Fueger R and Kavanagh JJ: An update of a phase II study of paclitaxel in advanced or recurrent squamous cell cancer of the cervix. *Anticancer Drugs* 8: 657-661, 1997.
14. McGuire WP, Blessing JA, Moore D, Lentz SS and Photopulos G: Paclitaxel has moderate activity in squamous cervix cancer. A Gynaecologic Oncology Group study. *J ClinOncol* 14: 792-795, 1996.
15. Chen MD, Paley PJ, Potish RA and Twigg LB: Phase I trial of taxol as a radiation sensitiser with cisplatin in advanced cervical cancer. *GynecolOncol* 67: 131-136, 1997.
16. Piver MS, Ghamande SA, Eltabbakh GH and O'Neill-Coppola C: First-line chemotherapy with paclitaxel and platinum for advanced and recurrent cancer of the cervix - a phase II study. *GynecolOncol* 75: 334-337, 1999.
17. Chougule PB, Akhtar MS, Akerley W, Ready N, Safran H, McRae R, Nigri P, Bellino J, Koness J, Radie-Keane K and Wanebo H: Chemoradiotherapy for advanced inoperable head and neck cancer: a phase II study. *SeminRadiatOncol* 9: 58-63, 1999.
18. Greco FA, Burris HA, III, Gray JR, Raefsky EL, Dobbs C, Smith S, Rinaldi D, Morrissey LH, Erland JB, Litchy S and Hainsworth JD: Paclitaxel and carboplatin adjuvant therapy alone or with radiotherapy for resected non-small cell lung carcinoma: a feasibility study of the Minnie Pearl Cancer Research Network. *Cancer* 92: 2142-2147, 2001.
19. Socinski MA, Rosenman JG, Schell MJ, Halle J, Russo S, Rivera MP, Clark J, Limentani S, Fraser R, Mitchell W and Detterbeck FC: Induction carboplatin/paclitaxel followed by concurrent carboplatin/paclitaxel and dose-escalating conformal thoracic radiation therapy in unresectable stage IIIA/B nonsmall cell lung carcinoma: a modified phase I trial. *Cancer* 89: 534-542, 2000.
20. Corn BW, Micaily B, Dunton CJ, Heller P, ValicentiRK, Anderson L and Hernandez El: Concomitant irradiation and dose-escalating carboplatin for locally advanced carcinoma of the uterine cervix: an updated report. *Am J ClinOncol* 21: 31-35, 1998.
21. Muderispace LI, Curtin JP, Roman LD, Gebhardt JA, Klement V, Qian D, Morrow CP, Felix JC, Formenti SC and Muggia FM: Carboplatin as a radiation sensitiser in locally advanced cervical cancer: a pilot study. *GynecolOncol* 65: 336-342, 1997.
22. Delgado G, Bundy B, Zaino R et al. Prospective surgical-pathological study of disease-free interval in patients with stage IB squamous cell carcinoma of the cervix: a Gynecologic Oncology Group study. *GynecolOncol* 1990; 38:352–357.
23. Zaino RJ, Ward S, Delgado E et al. Histopathologic predictors of the behavior of surgically treated stage IB squamous cell carcinoma of the cervix. A Gynecologic Oncology Group study. *Cancer* 1992;69:1750–1758.
24. Burghardt E, Baltzer J, Tulusan AH et al. Results of surgical treatment of 1028 cervical cancers studied with volumetry. *Cancer* 1992; 70:648–655.
25. Stehman FB, Bundy BN, DiSaia PJ et al. Carcinoma of the cervix treated with radiation therapy. I. A multi-variate analysis of prognostic variables in the Gynecologic Oncology Group. *Cancer* 1991;67:2776–2785.
26. Perez CA, Grigsby PW, and Camel HM et al. Irradiation alone or combined with surgery in stage IB, IIA, and IIB carcinoma of the uterine cervix: update of a nonrandomized comparison. *Int J RadiatOncolBiolPhys* 1995; 31:703–716.

27. Fagundes H, Perez CA, Grigsby PW et al. Distant metastases after irradiation alone in carcinoma of the uterine cervix. *Int J Radiat Oncol Biol Phys* 1992; 24:197–204.
28. Pattern of Failure with Locally Advanced Cervical Cancer– A Retrospective Audit and Analysis of Contributory Factors. Anis Bandyopadhyay, *Asian Pac J Cancer Prev*, 2017, 19- (1), 73-79
29. Tangjitgamol S, Tharavichitkul E, Tovanabutra C, Rongsriyam K, Asakij T, Paengchit K, et al. A randomized controlled trial comparing concurrent chemoradiation versus concurrent chemoradiation followed by adjuvant chemotherapy in locally advanced cervical cancer patients: ACTLACC trial. *J Gynecol Oncol*. 2019; 30:e82.
30. Available from: [https:// clinicaltrials. gov/ ct2/ show/ NCT01566240](https://clinicaltrials.gov/ct2/show/NCT01566240)
31. Tang J, Tang Y, Yang J, et al. Chemoradiation and adjuvant chemotherapy in advanced cervical adenocarcinoma. *Gynecol Oncol* 2012; 125:297–302.
32. Cisplatin and radiation therapy with or without carboplatin and paclitaxel in patients with locally advanced cervical cancer. Available from: [https:// clinicaltrials. gov/ ct2/ show/ NCT01414608](https://clinicaltrials.gov/ct2/show/NCT01414608)
33. Jelavić TB, Miše BP, Strikic A, et al. Adjuvant chemotherapy in locally advanced cervical cancer after treatment with concomitant chemoradiotherapy--room for Improvement? *Anticancer Res* 2015; 35:4161–5.