



Journal Homepage: - www.journalijar.com

INTERNATIONAL JOURNAL OF ADVANCED RESEARCH (IJAR)

Article DOI: 10.21474/IJAR01/12367

DOI URL: <http://dx.doi.org/10.21474/IJAR01/12367>



RESEARCH ARTICLE

MANAGEMENT OF DISTAL FEMUR FRACTURES IN ADULT WITH LOCKING COMPRESSION PLATE

Dr. Mohammed Moustafa Hamid Ali Nasser¹, Dr. Ali Tawfik Elalfy², Dr. Mohammed Elsadek Atia³ and Dr. Sameh Mohammed Holail⁴

1. Post Graduate Resident, Dept of orthopedics, Kafr Saad Hosiptal, Egypt.
2. Professor, Dept of orthopedics, Zagazig University, Egypt.
3. Assistant Professor, Dept of orthopedics, Zagazig University, Egypt.
4. Lecturer, Dept of orthopedics, Zagazig University, Egypt.

Manuscript Info

Manuscript History

Received: 25 November 2020

Final Accepted: 28 December 2020

Published: January 2021

Key words:-

Distal Femur, Locking Plate, Osteosynthesis, Functional Outcomes

Abstract

Objective: To evaluate the clinical outcomes and radiological union of distal third femur fractures by using distal femur locking plate, in Zagazig university hospitals and KafrSaad emergency hospital.

Design: Clinical trial.

Methods: Data collected for the study was from the patients admitted in orthopedic department in Zagazig university hospitals and KafrSaad emergency hospital, with distal femur fracture AO 33, during the period of August 2019 to July 2020 and treated with open reduction and internal fixation with distal femur locking compression plate with 4.5 system. All patients were followed up for an average of 6 months. Outcomes were assessed by Neer's score.

Results: Out of 12 patients (4 were females & 8 were males), mean age was 45.6 years (20 to 70 years). 10 cases were due to high energy trauma and 2 cases were due to low energy trauma. 5 out of total 12 cases had open fractures and rest 7 cases had closed fractures. Out of total 12 cases, five cases were extra-articular and rest 7 cases were intra-articular. Out of 12 fractures treated, 8 fractures showed radiological signs of union within 12-16 weeks, 3 fractures showed radiological signs of union within 20 weeks and one fracture showed radiological signs of union within 24 weeks. 1 patient got superficial infection and no implant failure, mean range of motion of all patients was 113°.

Conclusion: ORIF of distal femur fractures with locking compression plate provides good angular stability, restoration of limb alignment, length, rotation and give a good purchase in osteoporotic patients with minimal complications. Best results are obtained when standard protocol of locking plate fixation is followed with good soft tissue care, early knee bending exercises and physiotherapy.

Copy Right, IJAR, 2021,. All rights reserved.

Corresponding Author:- Dr. Mohammed Moustafa Hamid Ali Nasser

Address:- Post Graduate Resident, Dept of Orthopedics kafr Saad Hosiptal, Egypt.

Introduction:-

Distal femoral fractures are serious injuries that involve distal 15 cm measured from joint line and compromise both supracondylar and intercondylar fractures. (1) Distal femoral fractures have a bimodal distribution, in young patients due to road traffic accidents and in elderly due to osteoporotic bone. In old age these fractures are associated with high morbidity and mortality. (2) Distal femoral fractures contribute to 6% of all femoral fractures (3) and less than 1% of all fractures. Distal femoral fractures pose a challenge to orthopedic surgeons. (5,6) Proper anatomical reduction of articular surface and rigid fixation is required, if not done leads to morbidity like knee pain, decreased range of motion, stiffness and malunion. (7) Variety of implant choices are available for treating distal femoral fracture like dynamic condylar screw (DCS), condyle buttress plate, intramedullary nail, external fixation and locking compression plate. Locking plate has become increasingly popular since late 1990s. (8) Locking plate had fixed angle at each screw holes and head is secured to the plate by locking plate mechanism (9,11), preserve the periosteal blood supply (12,13) and are very useful in osteoporotic bone as it resists varus collapse. (14) Our purpose in this clinical study was to study functional and radiological outcomes of distal femoral fractures treated with distal femoral locking plate by lateral approach. Scoring system used was Neer et al score. (15)

Materials And Methods:-

This clinical study was conducted in Zagazig university hospitals and Kafr Saad emergency hospital between August 2019 to July 2020.

Ethical committee clearance was taken from our institution and informed consent was taken from all the patients who were included in the study. The classification system used was AO classification which was earlier called as Muller's classification.

Inclusion criteria:

1. Distal femur fractures type 33A, 33B and 33C.
2. Age more than 18 years.
3. Patients with osteoporosis.
4. Closed or open distal third femur fractures up to Gustilo - Anderson's classification type I, II and IIIA.
5. Patients willing for treatment and given informed consent.

Exclusion criteria:

1. Age less than 18 years.
2. Patients managed conservatively.
3. Patients with Gustilo Anderson type IIIB open fractures.
4. Pathological fractures other than osteoporosis.
5. Patients with associated tibial plateau fractures.

In emergency room, initial treatment for distal femur fractures was done by splinting the limb with Thomas splint or high above knee slab after resuscitating the patient thermodynamically. For open fractures, intravenous antibiotics like 2nd generation cephalosporins and gentamicin were given. Routine pre-operative investigations were done and anesthesia clearance was taken. In operating room under spinal anesthesia in supine position, limb was prepared and scrubbed, painted and draped. Lateral approach was used in the plane between vastus lateralis and lateral intermuscular septum and to address the intra-articular involvement lateral para patellar arthrotomy was done by using the swashbuckler approach. Anatomical reduction of articular fragments and rigid fixation by using 4.5 system distal femoral locking plate, proximal fragment with locking and non-locking screws and distal fragment by locking screws. Drain was placed. Wound closed in layers, sterile compressive dressing done, drain removed after 3 days, first dressing was done on 3rd day and knee movements were advised. IV antibiotics were given for 2 days and oral antibiotics for 1 week. Patient was mobilized with crutches or walking aids on 6 to 12 weeks post-operative. Full weight bearing was allowed after 3 to 4 months when radiological evidence was seen. Stitches were removed on 14th day and patient was discharged and patient was followed up at 1, 2, 3, 6 months and at the end of 1 year.

Table 1:- The patient's data according to gender and sex.

| Percentage | Total patients | Number of cases | Age in years | |
|------------|----------------|-----------------|--------------|--|
| 8.30% | 12 | 1 | 20-30 | |
| 8.30% | 12 | 1 | 31-40 | |

| | | | | |
|--------|----|---|-------|--|
| 50% | 12 | 6 | 41-50 | |
| 33.30% | 12 | 4 | 51-70 | |

Table 2:- The patient's data according to gender.

| Method | Frequency | Percent |
|---------|-----------|---------|
| Males | 8 | 66.7 % |
| Females | 4 | 33.3% |
| Total | 12 | 100% |

Table 2:- Distribution according to the mechanism of trauma.

| Mechanism of trauma | No. | Percent |
|---------------------|-----|---------|
| High motor energy | 10 | 83.3% |
| Low motor energy | 2 | 16.6% |

Highenergy trauma more common in young and middle age and in male patient, low energy trauma more common in old age especially infemales duo to osteoporosis.

Results:-

Out of 12 cases in our study, lowest age of patients was 20 years and highest age was 70 years and mean age was 45.6. Out of 12 cases, 4 were females (33.3%) and 8 were males (66.7%). High energytraumalike RTA in 10 cases (83.3%), low energy trauma in 2 cases (16.7%). Out of total 12 cases, 5 case were extra-articular and rest 7 cases were intra-articular. Most of the cases, 7 out of total 12 (58%) were typeC and 5 caseshad type A fracture (42%). Five out of total 12 cases had open fracture, and rest 7 cases had closed fracture. Open fractures were treated with intravenous antibiotics and tetanus prophylaxis. One case out of total 5 open fractures (20%), needed initial debridement and temporary stabilization in the form of external fixator before putting the locking plate. Two patients had fracture of ulna and 1 patient had fracture of patella. Out of 12 cases, we got ROM>1150 in 8 cases, ROM up to 1100 in 3 cases and 700 in 1 case who improved by physiotherapy and no case we got less than 700 ROM. Average range of motion was 1130. Post-operative complications divided into early and late complications. In our study we came across early post-operative complications like superficial infection of wound in 1 case, associated risk factor DM and only 1 case with delayed union, no neurovascular and thromboembolic complications. Radiographic healing occurred ranged from 12–24 weeks. 8 fractures healed within 12-16 weeks, 3 fractures healed within 20 weeks and one fracture healed within 24 weeks. Functional outcome was assessed by using Neer criteria, it includes 5 subscales like pain, function, motion, shortening (cm), angulation (in degrees) and interpretation of outcome like excellent (16-20 points), good (12-16), fair (8-12), failure (4-8). Excellent score in 7 patients, 3 patients got good results and 1 patientgot fair results. In our study we got overall good positive results with distal femoral fractures treating with locking plate by open reduction technique and early knee range of motion exercises.

Post-operative complications Early:

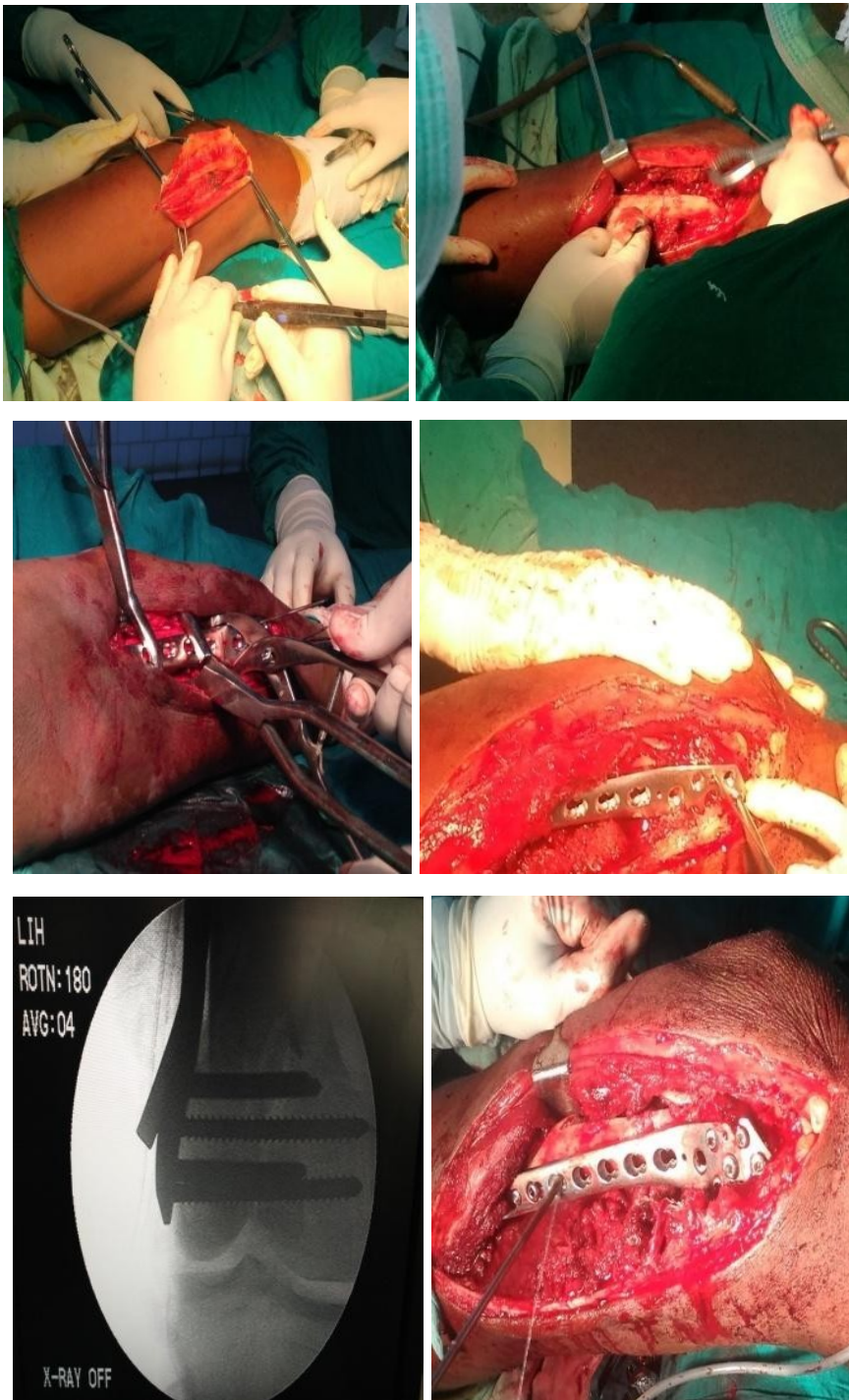| Complications | Number of Cases | % |
|-----------------------|-----------------|------|
| Thromboembolic Events | | |
| Superficial Infection | 1 | 8.3% |
| Deep Infection | | |
| Neurovascular Injury | | |

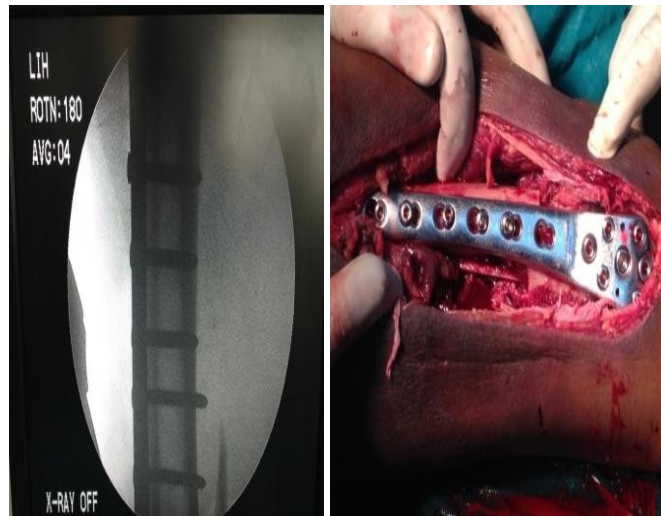
Latecomplications

| Complications | Number of Cases | % |
|-----------------|-----------------|---|
| Late Infection | | |
| Implant Failure | | |
| Malunion | | |
| Stiffness | | |

| | | |
|---------------|---|------|
| Delayed Union | 1 | 8.3% |
|---------------|---|------|

| | | | |
|--------------------|-----------|----------------|-----------------|
| Radiological Union | 12-16week | Within 20weeks | Within 26 weeks |
| Number of Cases | 8 | 3 | 1 |

Intraoperative Images



Discussion:-

We achieved union in all distal femoral fractures cases treating with distal femoral locking plate by open technique and average range of motion at knee joint was 1130, similar results were obtained by rademaker et al., in study of 67 patients and one year follow up with mean ROM 1110.(16)The mechanical advantage of screw head getting locked in the plate which converts the whole implant into one single solid angular stable construct, makes it very useful in comminuted fractures and also in elderly patients with osteoporotic bone. The “combi hole” in the plate offers the dual advantage of applying normal screws in a compression mode as well locking screws in fractures where traditional screw purchase is compromised. This function of locked fixation and its angular stability helps in sparing periosteal blood supply. Also, since no contouring of the plate is required and toggle at the screw- plate interface is minimized, the holding power of the implant is increased.(17)In our study we used in all cases stainless steel. We achieved union finally in all cases and good amount of callus. Henderson et al found less callus in patient treating with stainless steel compare to titanium plate.(18)we used open technique in all cases showing positive results and many studies also shows positive results treating by less invasive stabilization system (LISS) method (19-20). A study by Krishna et al., showed that average duration of radiological union was 15.36 weeks. (21) ,Weight and Collinge found it to be 13 weeks, (22) ,Malik A et al., found it to be 16 weeks. (21)

Conclusion:-

To conclude, locking compression plate is an important modality intreatment of distal femur fractures especially when fracture is severely comminuted and in situations of osteoporosis with minimal complications.

Clinical And Radiological Pictures:

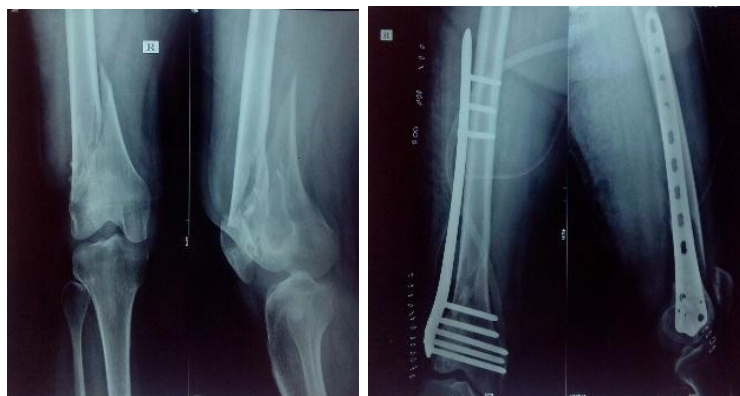

Fig 1:- Pre and post op xrays.

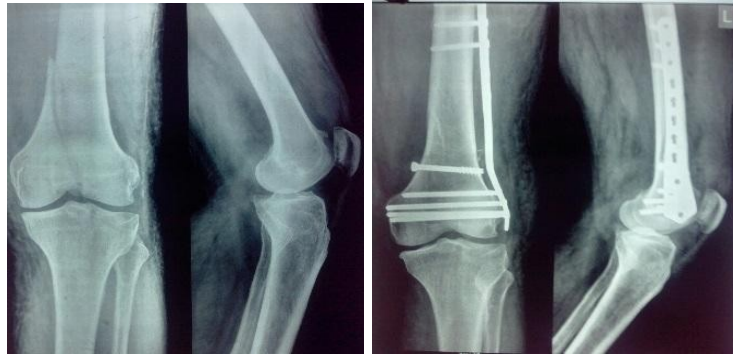

Fig 2:- Pre and post opx-rays.

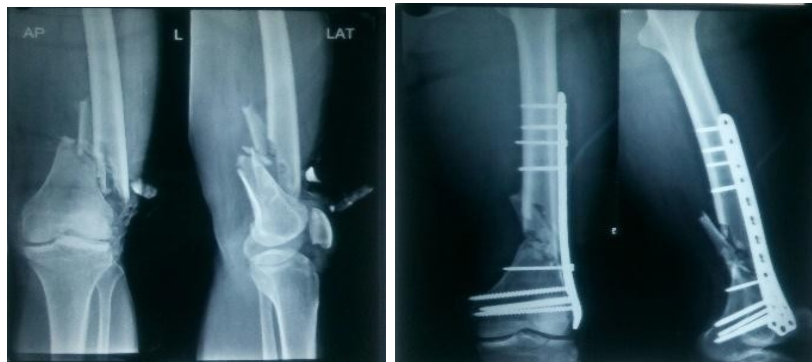

Fig 3:- Pre and post opx-rays.

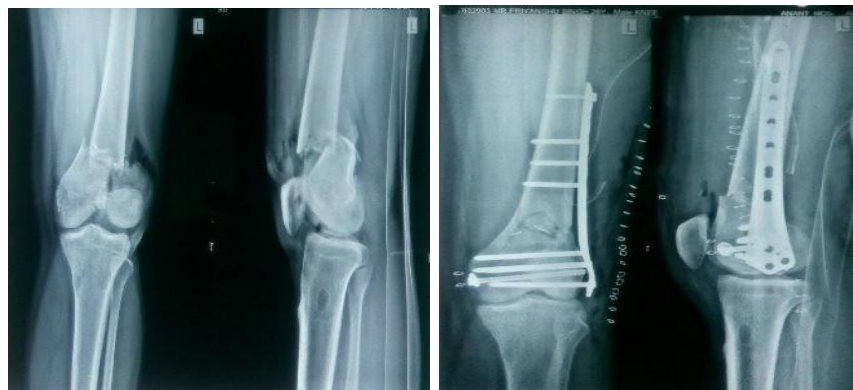

Fig 4:- Pre op and post op x-rays.

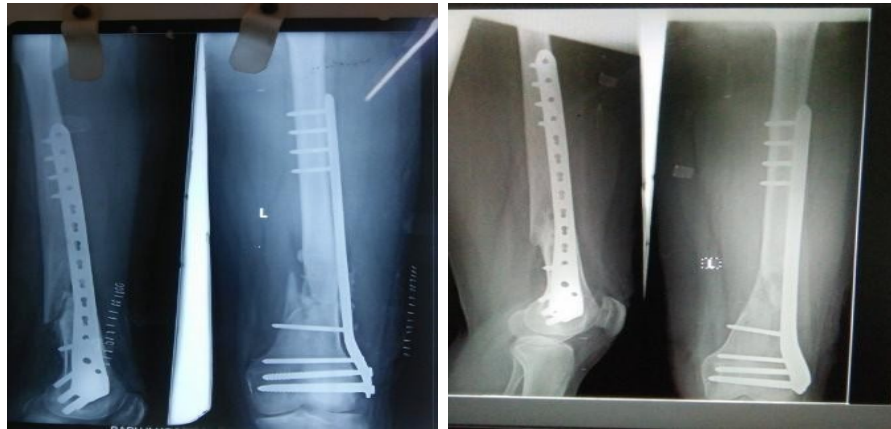
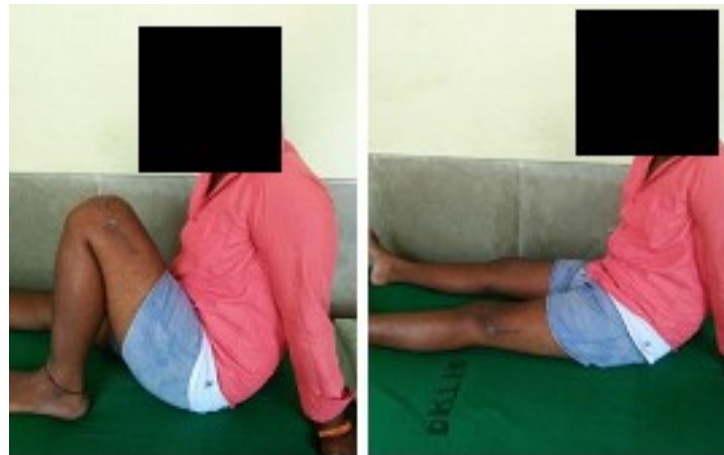
Fig 5:- Three months and one year end follow up xrays.

Three months and one year end follow up xrays.

Clinical follow up:



Flexion and extension at knee joint

References:-

1. Xing, W., Lin, W., Dai, J., Kong, Z., Wang, Y., Sun, L., ... & Sun, L. (2018). Clinical effect of locking compression plate via posterolateral approach in the treatment of distal femoral fractures: a new approach. *Journal of orthopaedic surgery and research*, 13(1), 57.
2. Kammerlander, C., Riedmüller, P., Gosch, M., Zegg, M., Kammerlander-Knauer, U., Schmid, R., & Roth, T. (2012). Functional outcome and mortality in geriatric distal femoral fractures. *Injury*, 43(7), 1096-1101.
3. Martinet, O., Cordey, J., Harder, Y., Maier, A., Bühler, M., & Barraud, G. E. (2000). The epidemiology of fractures of the distal femur. *Injury*, 31, 62-94.
4. Ng, A. C., Drake, M. T., Clarke, B. L., Sems, S. A., Atkinson, E. J., Achenbach, S. J., & Melton, L. J. (2012). Trends in subtrochanteric, diaphyseal, and distal femur fractures, 1984–2007. *Osteoporosis International*, 23(6), 1721-1726.
5. Ebraheim, N. A., Buchanan, G. S., Liu, X., Cooper, M. E., Peters, N., Hessey, J. A., & Liu, J. (2016). Treatment of distal femur nonunion following initial fixation with a lateral locking plate. *Orthopaedic surgery*, 8(3), 323-330.
6. von Keudell, A., Shoji, K., Nasr, M., Lucas, R., Dolan, R., & Weaver, M. J. (2016). Treatment options for distal femur fractures. *Journal of orthopaedic trauma*, 30, S25-S27.
7. Crist, B. D., Della Rocca, G. J., & Murtha, Y. M. (2008). Treatment of acute distal femur fractures. *Orthopedics*, 31(7).

8. Rodriguez, E. K., Boulton, C., Weaver, M. J., Herder, L. M., Morgan, J. H., Chacko, A. T., ... & Vrahas, M. S. (2014). Predictive factors of distal femoral fracture nonunion after lateral locked plating: a retrospective multicenter case-control study of 283 fractures. *Injury*, 45(3), 554-559.
9. Greiwe, R. M., & Archdeacon, M. T. (2007). Locking plate technology: current concepts. *The journal of knee surgery*, 20(1), 50-55.
10. Cantu, R. V., & Koval, K. J. (2006). The use of locking plates in fracture care. *JAAOS-Journal of the American Academy of Orthopaedic Surgeons*, 14(3), 183-190.
11. Egol, K. A., Kubiak, E. N., Fulkerson, E., Kummer, F. J., & Koval, K. J. (2004). Biomechanics of locked plates and screws. *Journal of orthopaedic trauma*, 18(8), 488-493.
12. Perren, S. M. (2002). Evolution of the internal fixation of long bone fractures: the scientific basis of biological internal fixation: choosing a new balance between stability and biology. *The Journal of bone and joint surgery. British volume*, 84(8), 1093-1110.
13. Broos, P. L. O., & Sermon, A. (2004). From unstable internal fixation to biological osteosynthesis a historical overview of operative fracture treatment. *Acta chirurgica Belgica*, 104(4), 396-400.
14. Ehlinger, M., Ducrot, G., Adam, P., & Bonnomet, F. (2013). Distal femur fractures. Surgical techniques and a review of the literature. *Orthopaedics & Traumatology: Surgery & Research*, 99(3), 353-360.
15. Arunkamal, C. (2008). A Prospective Analysis of Functional outcome of Displaced Distal Femoral Fractures Internally Fixed using Locking Compression Condylar Plates (Doctoral dissertation, Kilpauk Medical College, Chennai).
16. Virk, J. S., Garg, S. K., Gupta, P., Jangira, V., Singh, J., & Rana, S. (2016). Distal femur locking plate: the answer to all distal femoral fractures. *Journal of clinical and diagnostic research: JCDR*, 10(10), RC01.
17. Virk, J. S., Garg, S. K., Gupta, P., Jangira, V., Singh, J., & Rana, S. (2016). Distal femur locking plate: the answer to all distal femoral fractures. *Journal of clinical and diagnostic research: JCDR*, 10(10), RC01.
18. Henderson, C. E., Lujan, T. J., Kuhl, L. L., Bottlang, M., Fitzpatrick, D. C., & Marsh, J. L. (2011). 2010 mid-America Orthopaedic Association Physician in Training Award: healing complications are common after locked plating for distal femur fractures. *Clinical Orthopaedics and Related Research®*, 469(6), 1757-1765.
19. Marti, A., Fankhauser, C., Frenk, A., Cordey, J., & Gasser, B. (2001). Biomechanical evaluation of the less invasive stabilization system for the internal fixation of distal femur.
20. Kanabar, P., Kumar, V., Owen, P. J., & Rushton, N. (2007). Less invasive stabilisation system plating for distal femoral fractures. *Journal of orthopaedic surgery*, 15(3), 299-302.
21. Malik, A. L., Siddique, M., Niazi, N. S., & Niazi, S. N. K. (2015). Outcome of locking compression plate in supracondylar fracture of distal femur by minimally invasive plate osteosynthesis. *Pakistan J Med Heal Sci*, 9(1), 31-3.