



Journal Homepage: - www.journalijar.com

INTERNATIONAL JOURNAL OF ADVANCED RESEARCH (IJAR)

Article DOI: 10.21474/IJAR01/12495

DOI URL: <http://dx.doi.org/10.21474/IJAR01/12495>



RESEARCH ARTICLE

RESECTION OF A LARGE DESMOID TUMOR OF THE ABDOMINAL WALL WITH A SIGNIFICANT LOSS OF SUBSTANCE: A CASE REPORT AND LITERATURE REVIEW

Prosper Nsengiyumva¹, Youssef El Mahdaoui¹, Yousra Ouhammou¹, Yasser El Brahmi², Mohammed El Fahssi³, Abdelkader Ehrichtou³, Aziz Zentar⁴ and Abdelmounaim Ait Ali⁵

1. MD, resident in visceral surgery department II, Mohammed V Training Military Hospital, Mohammed V University, Faculty of Medicine and Pharmacy, Rabat, Morocco.
2. Specialist, visceral surgery department II, Mohammed V Training Military Hospital, Mohammed V University, Faculty of Medicine and Pharmacy, Rabat, Morocco.
3. Professor, visceral surgery department II, Mohammed V Training Military Hospital, Mohammed V University, Faculty of Medicine and Pharmacy, Rabat, Morocco.
4. Professor, director of the visceral and digestive surgery pedagogy and research unit, Mohammed V Training Military Hospital, Mohammed V University, Faculty of Medicine and Pharmacy, Rabat, Morocco.
5. Professor, chief of visceral surgery department II, Mohammed V Training Military Hospital, Mohammed V University, Faculty of Medicine and Pharmacy, Rabat, Morocco.

Manuscript Info

Manuscript History

Received: 15 December 2020

Final Accepted: 18 January 2021

Published: February 2021

Key words:-

Large Desmoids Tumor, Abdominal Wall, Significant Loss Of Substance, Synthetic Prosthesis

Abstract

Introduction: Desmoid tumors are rare entities, can occur at any age and may be located intra or extra-abdominal. Their recidival locally nature without metastasis remains a subject of discussion especially if it is necessary to decide on a surgical or medical treatment.

Case report: In the present report, it was described the case of a 25-year-old male with no specific medical or surgical history who consulted for a mass of the abdominal wall evolving for a few months and having caused intermittent pain and discomfort.

The physical examination was unremarkable apart from an arch and a palpable large mass in the left para-umbilical.

The abdominal Computer Tomography (CT) scan confirmed the existence of a large tumor developing at the expense of the left rectus muscle. The patient underwent a surgical treatment. The resection of the tumor was the cause of a significant loss of substance.

So, a synthetic prosthesis had to be used to reconstruct the abdominal wall.

Conclusion: Although desmoid tumors are benign, radical treatment should be undertaken given their recurrent nature.

Copy Right, IJAR, 2021.. All rights reserved.

Introduction:-

Desmoid tumors, called aggressive fibromatosis, are part of deep fibromatosis, themselves integrated into soft tissue tumors [1]. They are proliferation of fibroblastic tissues, infiltrating, not metastasizing. But it is above all their recurrent nature that is at the origin of the therapeutic difficulties [2].

Desmoid tumors develop from the muscle sheaths, fascia and aponeuroses [3].

Corresponding Author:- Prosper Nsengiyumva

Address:- MD, resident in visceral surgery department II, Mohammed V Training Military Hospital, Mohammed V University, Faculty of Medicine and Pharmacy, Rabat, Morocco.

They are rare tumors, they represent less than 0.03% of all neoplasias and approximately 3.5% of fibrous tumors [3, 4].

Their annual incidence varies between 2.4 and 4.3 per million inhabitants and multiple locations have been described to them [3, 5].

Case Report:

We report a case of a 25-year-old young man with no specific medical or surgical history who consulted for a mass of the abdominal wall evolving for a few months and having caused intermittent pain and discomfort.

The physical examination was unremarkable apart from an arch and a palpable large mass in the left para-umbilical.

The abdominal Computer Tomography (CT) scan confirmed the existence of a tumor developing at the expense of the left rectus muscle (Figure1). Our patient underwent, under general anesthesia, a laparotomy with infraumbilical incision and enlarged in supraumbilical. On exploration, it is a large tumor of the left rectus muscle reaching the opposite muscle (Figure 2 A and B). Its resection was the cause of a significant loss of substance but respecting the abdominal viscera (Figure4).

The reconnection of the abdominal wall was carried out by the establishment of a prolene plate, abdominoplasty. The immediate postoperative consequences were simple.

The patient was authorized to discharge from hospital five days after the surgery.

Macroscopically the tumor was 13x8x9 cm in size, the section boundaries were healthy.

Microscopically, fairly cellular tumor proliferation of spindle-cell architecture infiltrating adjacent muscle tissue.

This proliferation was made up of stellate cells of fibroblastic appearance, organized in wavy bundles. These cells had small-elongated nuclei without true cytonuclear atypia with scarcity of their mitosis. The stroma was small, rich in gaping vessels.

The immunohistochemical study showed, anti smooth muscle actin and β -catenin antibodies partially positive labeling of tumor cells. Anti epithelial membrane antigen (EMA), CD34, PS100 and Desmine antibodies were negative; Ki-67 estimated at 5%.

There fore, morphological appearance and immunohistochemical profile of a desmoid tumor.

Discussion:-

Desmoid tumors can occur either sporadically or associated with risk factors such as: familial adenomatosis polyposis (FAP) or Gardner syndrome. Thus, in a patient with FAP, the risk of suffering from a desmoid tumor is 852 to 1000 times greater than in the general population [3, 6, 7, 8]. Desmoid tumors associated with FAP represent 2% of all desmoid tumors [9]. In addition, other factors have been described: trauma surgical or accidental and represent 25 to 30% of cases [10, 11, 12]. In 65 to 86% of cases, according to the authors, desmoid tumors appear after surgery: appendectomy, caesarean section, prophylactic colectomy in cases of FAP and within an average of 2 to 3 years at the operating site [9, 13, 14, 15].

Desmoid tumors can also appear on scars from wounds or burns [1], sites of implantation of laparoscopy trocars [2], on colostomy sites after abdominoperineal amputation for rectal cancer [16], after implantation of silicon breast prosthesis [1,17] or after placement of a venous catheter [18].

However, the causal relationship has not been proven and the physiopathological arguments are rare, rather an alteration of the phenomena of repair and scarring is questioned [19].

The occurrence of desmoid tumors is equitable according to age. Thus, cases have been described in subjects under 1 month [20] to 88 years old [21] with a peak incidence between 28 years and 31 years [6, 7, 9].

Sporadic desmoid tumors preferentially affect women with a sex ratio of 2/1 to 5/1 [5, 19]. This female predominance can be explained by hormonal impregnation, especially during pregnancy, after childbirth or during oral contraception [7, 13]. Whereas it regresses after menopause, oophorectomy or during the use of anti-estrogens [4, 6, 9].

With regard to the form associated with FAP, this female predominance would be less marked [8], non-existent [6, 22], reversed [23].

The same is true for men treated with high doses of Estradiol for prostate cancer; a spontaneous regression is observed when the therapy is stopped [24].

According to the study by Reitamo et al. [13], the growth rate of desmoid tumor in males is 7.4 ± 1.7 cm per year regardless of the age group. In young girls, it is 4.3 ± 2.5 cm per year to reach its maximum in pre-menopause with 33.9 ± 13.2 cm per year before dropping to 13.3 ± 6.8 cm per year after menopause.

The extra-abdominal localization of desmoid tumors remains the most frequent whereas intra abdominal desmoid tumors are very rare [5, 20].

Although very rare, intra-abdominal desmoid tumors pose a diagnostic problem because most of the time they reveal themselves by a complication: occlusive syndrome, digestive fistula by tumor necrosis, hydronephrosis by ureteral compression, intestinal ischemia by compression of mesenteric vessels, sensory-motor deficits by nerve compression and deep vein thrombosis [9].

Desmoid tumors of the abdominal wall may manifest clinically as firm, palpable, sometimes-painful masses at the expense of the rectus abdominis and oblique muscles of the abdomen. They cause difficulties when closing the wall after resection in the event of a large tumor or repeated intervention [1, 2, 3].

The mammary location of desmoid tumors poses a differential diagnostic problem with other mainly malignant breast tumors. Only the histological examination provides a positive diagnosis [25, 26, 27, 28].

However, multilocular desmoid tumors have been described in the same patient in 5 to 38% of cases [8, 22, 29].

The existence of a genetic predisposition is very well documented in the case of an association with FAP. It is a hereditary disease with autosomal dominant transmission linked to a constitutional mutation of the Adenomatous Polyposis Coli (APC) gene which is a tumor suppressor located on chromosome 5q22 [6, 9].

The tumor appears when this constitutional mutation continues somatically on the other APC allele [30, 31]. Some authors have reported that desmoid tumors frequently occur in patients with a mutation downstream from codon 1444 to the 3' end of the APC gene always causing a premature stop codon and thus producing a truncated or inactive APC protein [2, 6, 9, 19, 32].

In sporadic tumors, mutations are found rather affecting the gene for β -catenin (CTNNB1) located on chromosome 2p22 [30, 33].

APC protein, when activated, forms a multi-protein complex with several other proteins including GSK-3 β (Glycogen Synthase Kinase). This complex attaches through the binding sites of the APC protein with β -catenin resulting in its inactivation and degradation.

In tumorigenesis, the APC protein functions as a tumor suppressor while β -catenin acts as an oncogenic protein [30]. Mutations affecting the CTNNB1 gene are responsible for overexpression of the β -catenin protein. This is confirmed by the presence of high levels of the β -catenin in the cytoplasm and nuclei of desmoid tumor cells in comparison with tissue cells neighbors [31].

Medical imaging finds its preponderant role in the topographic diagnosis of desmoid tumors; ultrasound allows the exploration of superficial locations showing hypoechoic and homogeneous lesions with variable vascularization on Doppler [34].

On computer tomography (CT), the lesions appear well demarcated, isodense to muscles in spontaneous contrast, they may or may not be enhanced after injection of iodinated contrast product [35].

However, Magnetic Resonance Imaging (MRI) remains the exam of choice for the exploration of desmoid tumors. Its excellent contrast resolution in the analysis of soft tissues makes it precise to study the extent of lesions and their relationship with neighboring structures; making it possible to orient the therapeutic attitude and the follow-up of patients [34, 36, 37].

Colonoscopy coupled with biopsies is performed on discovery of a desmoid tumor without a particular context, looking for colo-rectal polyposis. As for eso-gastro-duodenal fibroscopy, it is indicated if the colonoscopy is non-contributory [3, 7, 38].

From an anatomopathological point of view, the parietal desmoid tumor is confined to the muscle or its aponeurosis or fascia. Sometimes when it is large it can invade the subcutaneous tissue or the periosteum but never the skin [1, 2, 39]. The size of the tumor varies between 5cm and 10cm in diameter sometimes it can reach 20cm and more [1, 2]. Extreme cases have been reported by Rokitsansky and Paget with tumors that weighed 17 kg and 22 kg respectively [39, 40].

In optical microscopy, the lesion is poorly limited with infiltration of adjacent tissues, in particular muscle. The tumor is made of elongated, spindle-shaped cells of small size, which are arranged in bundles and separated from each other by an abundant collagen tissue. Nuclei are small, clear, regular chromatin with one to three nucleoli without atypia or noticeable mitotic activity [1, 2, 39].

The center is acellular while the periphery has a high cell density simulating a fibrosarcoma [5, 7, 9, 40]. Immunohistochemistry can confirm the myofibroblastic origin of these tumors by the positivity of certain markers: Desmine (intermediate filament of muscle cells), Vimentin (intermediate filament of connective cells), Alpha actin smooth muscle (marker of muscle cells smooth). On the other hand, the negativity of anti-desmin and anti-alpha actin smooth muscle antibodies makes it possible to eliminate fibrosarcomas for which they are generally positive. The CD117, CD34 and PS100 antibodies make it possible to differentiate desmoid tumors from gastrointestinal stromal tumors (GIST). They are positive for GIST [41].

Other markers have been studied making it possible to differentiate fibrosarcomas from desmoid tumors: Ki-67, Bcl-2, pRB and p53 for which desmoid tumors are negative [42, 43]. The diagnostic arsenal was also enriched by another marker, nuclear β -catenin, which makes it possible to distinguish desmoid tumors from their counterparts [44].

Therapeutic means:

The therapeutic means, as described in the literature namely, surgery but which also has its constraints; especially in the face of a benign pathology, of slow evolution but recurrent. It is preferable to carry out a wide surgical resection with obtaining histologically healthy margins at least 1cm [12]. Surgery must not be mutilating and no longer partial because it would lead to an acceleration of tumor growth processes [3, 38]. with regard to radiotherapy, some studies have shown its usefulness in the event of residual tumors after incomplete surgery, with invaded margins, unresectable tumor [45, 46, 47], in case of tumor recurrence, as an alternative to mutilating or disabling surgery [6].

However, the use of radiotherapy in the treatment of desmoid tumors is limited by its potentially serious side effects such as sarcomatous malignant degeneration and development of secondary malignancies [2].

Chemotherapy is reputed to have low efficiency because desmoid tumors, being of slow evolution, are supposed to have a low chemosensitivity. Thus, Anthracyclines have been tried with some success allowing long-term stabilization but late regressions [3].

In children, it is the protocol combining: Vincristine, Actinomycin, Cyclophosphamide which has given better results despite its toxicity [45].

The low-dose combination of Methotrexate and Vinblastine is preferred especially in young patients for whom the low toxicity of the treatment should be a major concern. Its efficiency is estimated at 70% of cases with few adverse effects [48].

Remission rates of more than 70% of which 30% of complete remission were obtained with the combination of Doxorubicin and Dacarbazine [49, 50]. This displayacity is justified by the fact that the Desmoid tumors arise from tissues similar to those of fibrosarcomas for which the two molecules have shown their efficiency [7].

On an other hand, the combination of toxicity and the use of systemic treatment for a local tumor reduced the use of chemotherapy for desmoid tumors.

Other options, such as hormone therapy have been proposed since desmoid tumors have a proven hormone-dependent character. The anti-estrogens; Tamoxifen (Nolvadex®) and progestins such as Medroxyprogesterone Acetate (Depo Provera®) have been used and in some series have given approximately 50% objective response ranging from stabilization to complete regression [3, 6, 7, 45, 51].

Non-steroidal anti-inflammatory drugs have demonstrated their effectiveness on cells from desmoid tumors for two molecules: Sulindac and Indomethacin. This treatment requires high doses per day and the response is obtained after several months of treatment, sometimes ignoring the duration of obtaining a remission. On the other hand, their side effects limited their use to the benefit of new molecules with less gastric toxicity [7, 52, 45, 53, 54].

Other medical treatments have been tested with less convincing results: Interferon α [55], Interferon σ [51] corticosteroids [57], Warfarin, Testolactone [58], Colchicine, Interleukine [2] and Theophylline [7].

Tumoral necrosis factors alpha (TNF- α) and Melphalan have been used to prevent amputations in recurrent soft tumors of the extra-abdominal site [2, 3, 4].

Therapeutic indications:

Extra-abdominal and parietal desmoid tumors:

The first-line treatment remains surgery for extra-abdominal tumors and those of the wall despite high rates of recurrence after resection [9, 59]. When the tumor is resectable, R0 surgery should be performed with a margin of safety of at least 1 cm [2, 3].

Faced with the significant risk of recurrence, several authors have recommended the use of radiotherapy as an adjuvant treatment, especially when resection could not be performed with satisfactory resection margins [7, 60].

The loss of substance, in the case of a large desmoid wall tumor, can be significant; different techniques are described for wall repair: directed healing to treat a loss of superficial substance [61]; Parietorrhaphy, repair of the abdominal wall by plane closure by plane of the different elements [62]; thin or semi-thick skin graft. This is a method used when the areas recipients are well vascularized, non-haemorrhagic, non-oozing and free from virulent infection. The graft must respect the deep part of the dermis allowing spontaneous healing [63, 64].

Flaps with or without skin: these are muscular tissues initially alive; grafts whose survival depends on spontaneous revascularization of the recipient area. Thus, several flaps were used: rectus muscle, tensor muscle of the fascia-lata, etc, [65].

The use of synthetic prostheses has been described in the literature, in particular: Mersilene plate®, Prolene®, Gore-tex®, Vicryl®, Mersuture plate®, etc. The choice of the prosthesis is dictated by its physical qualities of resistance and plasticity, its good biologic tolerance and the possibility of its colonization by the tissues [66].

Combinations of these methods are possible: for example, reconstruction of the deep plane with prosthesis protected by a musculo-cutaneous flap [67].

Intra-abdominal desmoids tumors:

It is important to point out that in front of these tumors, surgery has a double interest, therapeutic if the tumor is resectable and diagnosis with certainty through biopsies [68].

For unresectable and uncomplicated intra-abdominal desmoid tumors, the treatment of choice is medical by non-steroidal anti-inflammatory drugs or anti-estrogens in women; this for at least eight months [7, 52].

The combination of an anti-estrogen and a non-steroidal anti-inflammatory drug is recommended in the event of tumor progression. The indications for chemotherapy are currently aggressive (rapidly progressive) desmoid tumors, inextirpable and resistant to conventional medical treatment [7].

For desmoid tumors initially unresectable, surgery becomes imperative in the following cases: digestive fistula, acute intestinal obstruction, resistance to medical treatment.

For this, some surgical procedures are reported in the literature: a wide exeresis usually associated with a visceral sacrifice (the small intestine for example), digestive diversions [68, 69].

Ureteral compression by desmoides tumors is remedied by the placement of a double J probe, percutaneous nephrostomy, ureteral plasty (prosthetic plasty of the ureter, uretero-ileoplasty) [70].

Conclusion:-

Desmoid tumors can appear in different clinical aspects related to their various locations.

Their main etiology is genetic but sporadic cases are described. They are benign, sometimes recurrent.

The role of positive diagnosis returns to the anathomopathologist so that we can rule out other differential diagnoses.

The available therapeutic means remain to be discussed on a case-by case basis.

Figures:-

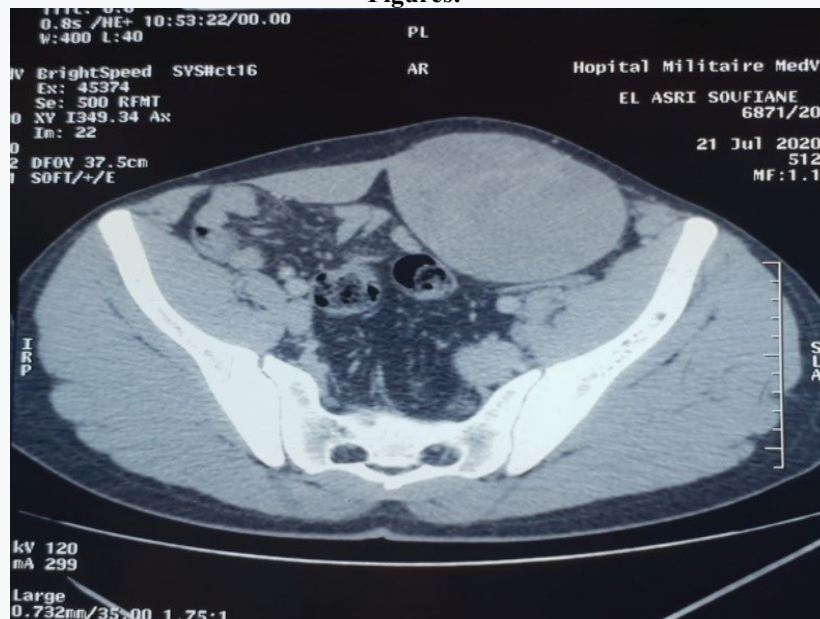

Figure 1:- Frontal abdominal CT Scan showing a large tumor located at the expense of the left rectus muscle.

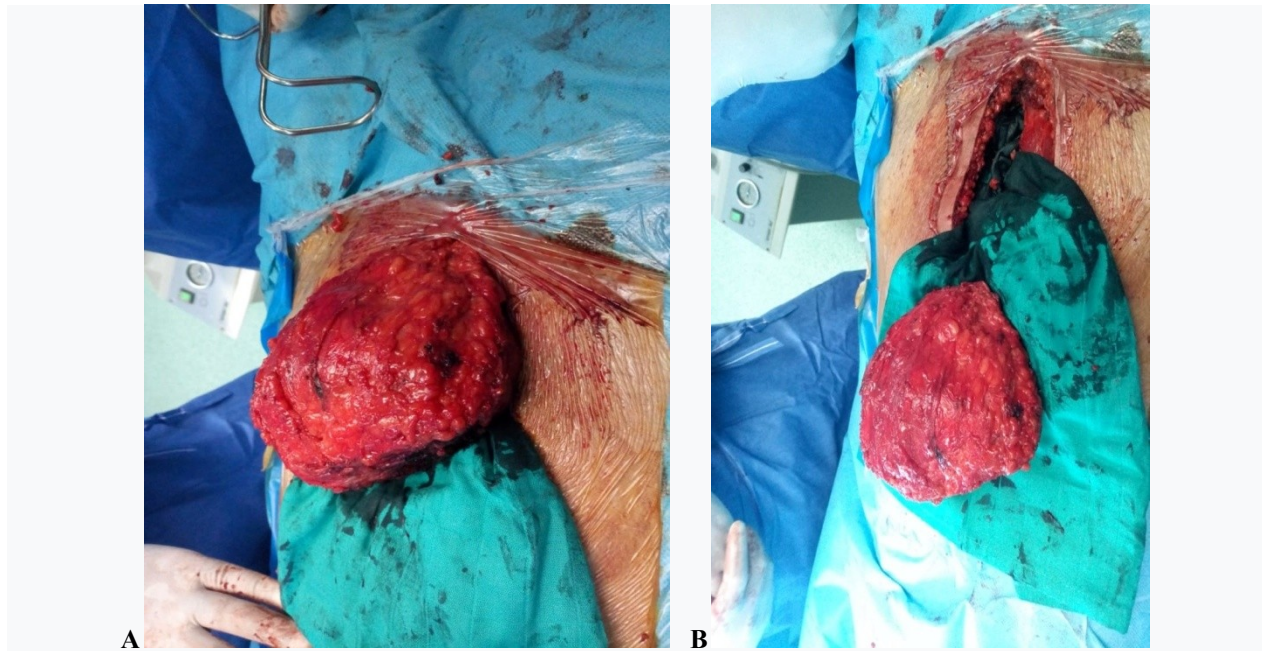


Figure 2:-(A, B): Per-operative image showing a large tumor of the abdominal wall.

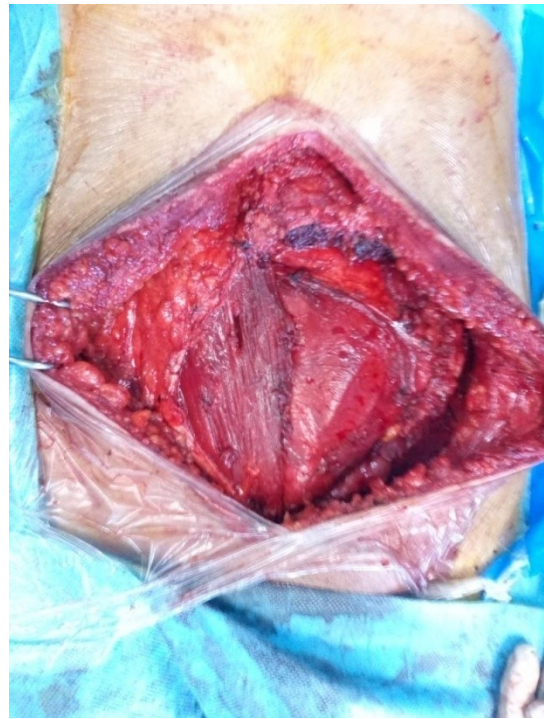


Figure 3:-Per-operative image showing a significant loss of substance after tumor resection.

References:-

1. Enzinger F M, Weiss SW. Fibromatoses, In Soft tissue tumors. St Louis, Mosby 1988(second edition):136-63.
2. Mignot L. Les tumeurs desmoïdes. www.orpha.net/data/patho/FR/fr-desmoide.pdf
3. Montaglini L, Duverger V. Les tumeurs desmoïdes. J Chir 2008;145(1):20-6.
4. Shields C J, Winter D C, Kirwan W O, Redmond h P. Desmoid tumors. Eur J Surg Oncol 2001;27(8):701-6.
5. Reitamo J J, Häyry P, Nykyri E, Saxen E. The desmoid tumor I.: Incidence, sex-, age- and anatomical distribution in the Finnish population. Am J Clin Pathol 1982;77(6):665-73.

6. Kulaylat M N, Karakousis C P, Keaney C M. Desmoid tumour : a pleomorphic lesion. *Eur J Surg Oncol* 1999;25(5):487-97.
7. Cotte E, Glehen O, Monneuse O, Cotton F. Tumeurs desmoïdes associées à la polypose adénomateuse familiale. *Gastroenterol Clin Biol* 2004;28:574-81.
8. Gurbuz A K, Giardiello F M, Petersen G M. Desmoid tumors in familial adenomatous polyposis. *Gut* 1994;35(3):377-81.
9. Clark S K, Phillips R K S. Desmoids in familial adenomatous polyposis. *Br J Surg* 1996;83(11):1494-504.
10. Lopez R, Kemalyan N, Moseley HS, Dennis D. Problems in diagnosis and management of desmoid tumors. *Am J Surg* 1990;159(5):450-3.
11. Schlemmer M. Desmoid tumors and deep fibromatoses. *Hematol Oncol Clin North Am* 2005;19(3):565-71.
12. Rampone B, Pedrazzani C, Marrelli E, Pinto E. Updates on abdominal desmoid tumors. *World J Gastroenterol* 2007;13(45):5985-8.
13. Reitamo JJ, Scheinin TM, Häyry P. The desmoid syndrome: New aspects in the cause, pathogenesis and treatment of the desmoid tumor. *Am J Surg* 1986;151(2):230-7.
14. Gouin F, Tesson A, Vasseur AB, Cassagnau E. Etude de la croissance tumorale des tumeurs desmoïdes extra- abdominales primitives ou récidivées non opérées. *Revue de chirurgie orthopédique* 2007;93:546-54.
15. Penick RM. Desmoid tumors developing in operative scars. *Intern. Surg Digest* 1937;23:323-9.
16. Oguz M, Bedirli A, Gultekin A, Dursun A. Desmoid tumor arising at the colostomy site after abdomino perineal resection for rectal carcinoma: Report of a case. *Dis Colon Rectum* 2006;49(9):1445-8.
17. Aaron AD, O'mara JW, Legendre KE, Evans SR. Chest wall fibromatosis associated with silicone breast implants. *Surg Oncol* 1996;5(2):93-9.
18. Skhiri H, Zellama D, Frih M A, Moussa A. Tumeur desmoïde cervicale après pose d'un cathéter jugulaire interne. *La Presse Médicale* 2004;33(2):95-7.
19. Fadel C, Guimbaud R, Garat P, Bachaud J-M. Les tumeurs desmoïdes: tumeurs bénignes à malignité locale. *Revue de la littérature ; à propos d'un cas clinique. Cahiers d'Oncologie* 1998;7(4):169-73.
20. Sørensen A, Keller J, Nielsen O S, Jensen O M. Treatment of aggressive fibromatosis: A retrospective study of 72 patients followed for 1–27 years. *Acta Orthop Scand* 2002;73(2):213-9.
21. Lev D, Kotilingam D, Wei C, Ballo M T. Optimizing treatment of desmoid tumors. *J Clin Oncol* 2007;25(13):1785-91.
22. Mcadam W A, Goligher J C. The occurrence of desmoids in patients with familial polyposis coli. *Br J Surg* 1970;57(8):618-31.
23. Rodriguez-bigas M A, Mahomey M, Karakousis C. Desmoid tumors in patients with familial adenomatous polyposis. *Cancer* 1994;74(4):1270-4.
24. Svanvik J, Knutsson F, Jansson R, Ekman H. Desmoid tumor in the abdominal wall after treatment with high dose estradiol for prostatic cancer. *Acta Chir Scand* 1982;148(3):301-3.
25. Smarrito S, Salmon R. Tumeur desmoïde du sein chez l'homme dans le cadre d'un syndrome de Gardner. *Ann Chir* 2005;130(1):40-3.
26. Roman H, Caron P, Verspyck E, Vercoustre L. Fibromatose primitive du sein. *Ann Chir* 2001;126(6):561-4.
27. Rosen P P, Ernsberger D. Mammary fibromatosis: A benign spindle-cell tumor with significant risk for local recurrence. *Cancer* 1989;63(7):1363-9.
28. Neuman H B, Brogi E, Ebrahim A, Brennan E F. Desmoid tumors (Fibromatoses) of the breast: A 25-year experience. *Ann Surg Oncol*. 2008;15(1):274-80.
29. Wagstaff MJD, Raurell A, Perks AGB. Multicentric extra-abdominal desmoid tumours. *Br J Plast Surg* 2004;57(4):362-5.
30. Lips DJ, Barker N, Clevers H, Hennipman A. The role of APC and β -catenin in the etiology of aggressive fibromatosis. *Eur J Surg Oncol*. In press.
31. Alman BC, Li C, Pajerski ME. Increased β -catenin protein and somatic APC mutations in sporadic aggressive fibromatoses (desmoid tumors). *Am J Pathol* 1997;151(2):329-34.
32. Saurin J C. La polypose adénomateuse familiale (PAF) atténuée : une entité à connaître. *Gastroenterol Clin Biol* 2008;32(5P2):158-65.
33. Shitoh K, Konishi F, Iijima T, Ohdaira T. A novel case of a sporadic desmoid tumour with mutation of the beta catenin gene. *J Clin Pathol* 1999;52(9):695-6.
34. Shinagare AB, Ramaiya NH, Jagannathan JP, Krajewski KM, Giardino AA, Butrynski JE, et al. A to z of desmoid tumors. *AJR Am J Roentgenol* 2011;197(6):W1008-14.
35. Casillas J, Sais GJ, Greve JL, Iparraguirre MC, Morillo G. Imaging of intra- and extraabdominal desmoid

- tumors. *Radiographics* 1991;11(6):959-68.
36. Lee JC, Thomas JM, Phillips S, Fisher C, Moskovic E. Aggressive fibromatosis: MRI features with pathologic correlation. *AJR Am J Roentgenol* 2006;186(1):247-54.
 37. Murphey MD, Ruble CM, Tyszkowski SM, Zbojnicki AM, Potter BK, Miettinen M. From the archives of the AFIP: musculoskeletal fibromatoses: radiologic-pathologic correlation. *Radiographics* 2009;29(7):2143-73.
 38. Dequanter D, Gebhart M. Tumeurs desmoïdes. *J Chir* 2002;139(4):236-9.
 39. Hajdu S I. Tumors of fibrous tissue. In *Pathology of soft tissue tumors Philadelphia, Lea & Febiger*:57-164.
 40. Häyry P, Scheinin TM. The desmoid (Reitamo) syndrome: etiology, manifestations, pathogenesis, and treatment. *Curr Probl Surg* 1988;25(4):233-320.
 41. Ferenc T, sygut J, Kopczyński J, Mayer M. Aggressive fibromatosis (Desmoid tumors): Definition, occurrence, pathology, diagnostic problems, clinical behavior, genetic background. *Pol J Pathol* 2006;57(1):5-15.
 42. Hoos A, Lewis J, Antonescu C R, Dudas ME. Characterization of molecular abnormalities in human fibroblastic neoplasms: A model for genotype-phenotype association in soft tissue tumors. *Cancer Res* 2001;61(7):3171-5.
 43. Leithner A, Gapp M, Radl R, Pascher A. Immunohistochemical analysis of desmoid tumours. *J Clin Pathol* 2005;58(11):1152-6.
 44. Bhattacharya B, Dilworth HP, Donahue CI. Nuclear β -Catenin expression distinguishes deep fibromatosis from other benign and malignant fibroblastic and myofibroblastic lesions. *Am J Surg Pathol* 2005;29(5):653-9.
 45. Hosalkar HS, Fox EJ, Delaney T, Torbert JT. Desmoid tumors and current statut of management. *Orthop. Clin. North Am* 2006;37(1):53-63.
 46. Shih HA, Hornicek FJ, Delaney TF. Fibromatosis: Current strategies for treatment. *Current Opin Orthop* 2003;14(6):405-12.
 47. Micke O, Seegenschmiedt MH. Radiation therapy for aggressive fibromatosis (desmoid tumors): Results of a national patterns of care study. *Int J Radiat Oncol Biol Phys* 2005;61(3):882-91.
 48. Azzarelli A, Gronchi A, Bertulli R. Low-Dose chemotherapy with Methotrexate and Vinblastine for patients with advanced aggressive fibromatosis. *Cancer* 2001;92(5):1259-64.
 49. Patel SR, Benjamin RS. Desmoid tumors respond to chemotherapy: Defying the dogma in oncology. *J Clin Oncol* 2006;24(1):11-2.
 50. Gega M, Yanagi H, Yoshikawa R, Noda M. Successful chemotherapeutic modality of Doxorubicin plus Dacarbazine for the treatment of desmoid tumors in association with familial adenomatous polyposis. *J Clin Oncol* 2006;24(1):102-5.
 51. Bauernhofer T, Stoger H, Schmid M, Smola M. Sequential treatment of recurrent mesenteric desmoid tumor. *Cancer*, 1996;77(6):1061-5.
 52. Tsukada K, Church JM, Jagelman DG. Non-cytotoxic drug therapy for intra-abdominal desmoid tumor in patients with FAP. *Dis Colon Rectum* 1992;35(1):29-33.
 53. Janinis J, Patriki M, Vini L. The pharmacological treatment of aggressive fibromatosis: A systematic review. *Ann Oncol* 2003;14(2):181-90.
 54. Tanaka K, Yoshikawa R, Yanagi H, Gega M. Regression of sporadic intra-abdominal desmoid tumour following administration of non-steroidal anti-inflammatory drug. *World J Surg Oncol* 2008;6:17.
 55. Geurs F, Kok TC. Regression of a great abdominal desmoid tumour by interferon alpha. *J Clin Gastroenterol* 1993;16(3):264-5.
 56. Umemoto S, Makuuchi H, Amemiya T, Yamaguchi H. Intra-abdominal desmoid tumors in familial polyposis coli: A case report of tumor regression by prednisolone therapy. *Dis Colon Rectum* 1991;34(1):89-93.
 57. Waddell W R, Kirsch WM. Testolactone, sulindac, wafarin, and vitamin K1 for unresectable desmoid tumors. *Am J Surg* 1991;161(4):416-21.
 58. Reitamo JJ. The desmoid tumor IV: Choice of treatment, results and complications. *Arch Surg* 1983;118(11):1318-22.
 59. Ayadi K, Trigui M, Zribi M, Keskes H. Tumeurs desmoïdes extra-abdominales: Résultats du traitement chirurgical, 12 cas avec un recul moyen de 7 ans. *Revue Chir Orthop Rép App Moteur* 2003;89(5):385-92.
 60. Arnaud E, Couturaud B, Revol M, Servant JM. Chirurgie réparatrice des pariéctomies. *Ann Chir Plast Esthet* 1999;44(4):357-72.
 61. Grevious M A. Abdominal wall reconstruction. www.emedicine.com/plastic/TOPIC441.HTM
 62. Lazar CC, Mure JP, Denis MHI. Reconstruction par greffe de peau d'un cas inhabituel de perte de substance étendue de la paroi abdominale secondaire à une compression ischémique prolongée. *Ann Chir Plast Esthet* 2006;51(1):91-93.

63. McGREGOR I A. The use of dermis to reconstruct the musculo-aponeurotic element of the anterior abdominal wall. *Br J Plast Surg* 1991;44(8):619-21.
64. Sledzianowski J F, Suc B, Hezard L, Ghannem Y. Pariéctomie abdominale étendue pour récidence pariétale tardive d'un cancer colique: Reconstruction par un lambeau libre de muscle grand dorsal à insertion différée. *Ann Chir* 2001;126(8):789-93.
65. Danino A, Saito S, Mamlouk K, Cuminet J. Reconstruction des pertes de substance totales transfixiantes du thorax par combinaison Gore-Tex®/Marlex®/lambeau musculo-cutané. *Ann Chir Plast Esthet* 2003;48(2):86-92.
66. Brenner P, Rammelt S. Abdominal wall and foot reconstruction after extensive desmoid tumor resection with free tissue transfer. *Langenbecks Arch Surg* 2002;386(8):592-7.
67. Tryphonopoulos P, Weppler D, Levi DM. Transplantation for the treatment of intra-abdominal fibromatosis. *Transplant Proc* 2005;37(2):1379-80.
68. Chatzipetrou M A, Tzakis A G, Pinna AD. Intestinal transplantation for the treatment of desmoid tumors associated with familial adenomatous polyposis. *Surgery* 2001;129(3):277-81.
69. Bruyere F, Barat D, Peyrat L, Haillot O. Compressions urétérales par des tumeurs desmoïdes du mésentère. *Progrès en Urologie* 1999;9:1111-2.