

 <p>ISSN NO. 2320-5407</p>	<p>Journal Homepage: -www.journalijar.com</p> <p>INTERNATIONAL JOURNAL OF ADVANCED RESEARCH (IJAR)</p> <p>Article DOI:10.21474/IJAR01/12613 DOI URL: http://dx.doi.org/10.21474/IJAR01/12613</p>	 <p>INTERNATIONAL JOURNAL OF ADVANCED RESEARCH (IJAR) ISSN 2320-5407 Journal Homepage: http://www.journalijar.com Article DOI:10.21474/IJAR01</p>
---	--	---

RESEARCH ARTICLE

UTERINE ADENOSARCOMA AND ADULT OVARY GRANULOSA TUMOR

Hamza Messaoudi¹, Yassine Bouhtouri, Khalid Guelzim, Moulay abdellah baba habib, Moulay El Mehdi el Hassani¹, Mohamed Amine Essaoudi² and Jaouad Kouach¹

1. Department of Gynecology and Obstetrics Mohammed V Military Hospital.
2. Anatomopathologist Department Mohammed V Military Hospital.

Manuscript Info

Manuscript History

Received: 20 January 2021

Final Accepted: 24 February 2021

Published: March 2021

Key words:-

Uterine adenosarcoma, Adult Granulosa Tumour, Post Menopausal metrorrhagia, Polyploid hypertrophy

Abstract

Uterine adenosarcoma with an adult granulosa tumour is rarely described in the literature. The paucity of studies concerning this association makes it difficult both diagnostically and therapeutically. We report a rare case of this association in a menopausal patient admitted to our training course for post-menopausal metrorrhagia. The evolution was favorable in this patient after radical treatment, which was based on a total hysterectomy with bilateral adnexectomy without adjuvant treatment.

Copy Right, IJAR, 2021,. All rights reserved.

Introduction:-

Uterine adenosarcomas consist of a benign epithelial component and a malignant mesenchymal component [1,2]. There is minimal data to guide treatment decisions for this rare uterine sarcoma. Our report of a very rare case that has never been reported before is a case that associates a uterine adenosarcoma and a tumor of the adult granulosa.

Granulosa cell tumors are neoplasms of the stromal cells of the ovarian sex cord and represent 2 to 5% of all ovarian cancers [3-4]. almost all of them are capable of synthesizing estradiol. Prolonged exposure of the endometrium to high levels of estrogen is responsible for pathological changes ranging from endometrial hyperplasia to endometrial cancer [5].

Observation:-

She was a 76 year old patient, menopausal for 20 years, G9P9, with nine vaginal deliveries. For her medical history she was hypertensive under medical treatment, and her surgical and family history was without particularity.

Symptomatology goes back to six months by the installation of post-menopausal metrorrhagia without any other accompany sign, the whole evolving in a context of conservation of the general state, which motivated her consultation in our training for care. At the general examination found a patient in good general condition, hemodynamically stable (BP: 13/8cmhg), afebrile, the weight was 70kg for a height of 1.80m, the conjunctiva was normally colored. The examination of thyroid and senological logs was without particularity, the abdominal examination detected a localized sensitivity at the level of the left iliac fossa without any palpation mass. The gynecological examination at the vulvoperineal inspection was without particularity, at the speculum the cervix was aspirated with a healthy aspect without bleeding or leucorrhoea. At the vaginal touch the uterus was increased in size through two fingers of the pubic symphysis and at the rectal touch the vaginal septum and the parameters were without particularity. The rest of the somatic examination was unremarkable.

Corresponding Author:- Hamza Messaoudi

Address:- Department of Gynecology and Obstetrics Mohammed V Military Hospital.

Pelvic ultra sound showed an enlarged lobular uterus measuring 8/7cm with the presence of an intra cavity image, occupying the majority of the uterine cavity of heterogeneous hyperechogenic appearance measuring 7/5cm, not vascularized on Doppler, the ovaries not seen, no effusion or latero-uterine mass, the douglas was empty.

A diagnostic hysteroscopy was performed and revealed the presence of a richly vascular polypoid hypertrophy richly vascularized, without any other notable sign, the biopsy was without particularity. The cervico vaginal smear showed a very inflammatory and atrophic smear.

Mammography and breast ultrasound was unremarkable.

A total hysterectomy with bilateral adnexectomy was performed under general anesthesia, the incision of pfannetial type, at the opening of the peritoneal cavity: the liver, the stomach, the omentum, the lumbo-aortic and pelvic areas are all free of The uterus was increased in size and the ovaries without any particularity. A peritoneal cytology was performed. The histopathological examination of the surgical specimen showed a morphological aspect of adenosarcoma of the uterus (figure a) of 3 cm, long axis without myometrial invasion, and a tumor of the adult granulosa of the left ovary (figure b) with capsular effraction. The adnexa, the uterine cervix and the vaginal collars were free of tumor infiltration, and the peritoneal cytology was unremarkable.

Discussion:-

The association of a uterine adenosarcoma and a tumor of the adult granulosa of the ovary is very rare and has not been reported. usually the tumor of the adult granulosa of the ovary are associated with uterine carcinosarcoma or adenocarcinoma increased secretion of estrogen. Surgery is the basic treatment and consists of a total hysterectomy with bilateral adnexectomy [6], which is sufficient, especially if the tumor is located in the uterus, allowing a 5-year survival rate of almost 50%, where as pelvic lymphadenectomy remains controversial. Uterine adenosarcoma represents 8% of uterine sarcomas [7,8]. Clement and Scully performed a literature review and found only a hundred or so cases described in a usable way. It is a postmenopausal cancer with an average age of 58 years. The clinical symptoms are very varied, dominated by metrorrhagia (71% of cases) [9] as in our case. To make the diagnosis, it is only after hysterectomy that the anatomopathological examination confirmed a positive diagnosis which highlights the two malignant mesenchymal and benign epithelial contingents. Macroscopically, uterine adenosarcoma appears as an enormous polypous, greyish or yellowish formation, usually originating in the endometrium (87% of cases), sometimes in the cervix (9% of cases). Multicentric or extrauterine locations are exceptional [7]. Numerous differential diagnoses can be discussed, on the one hand mixed malignant Mullerian tumors where both components are malignant: carcinosarcomas and mulleroblastomas with an unfavorable prognosis [10] and on the other hand papillary adenofibroma characterized by a benign proliferation of both the epithelial and conjunctive components.

Figure 1:- Histological microscopic section of a uterine adenosarcoma Standard stain ,hemalum eosin x25

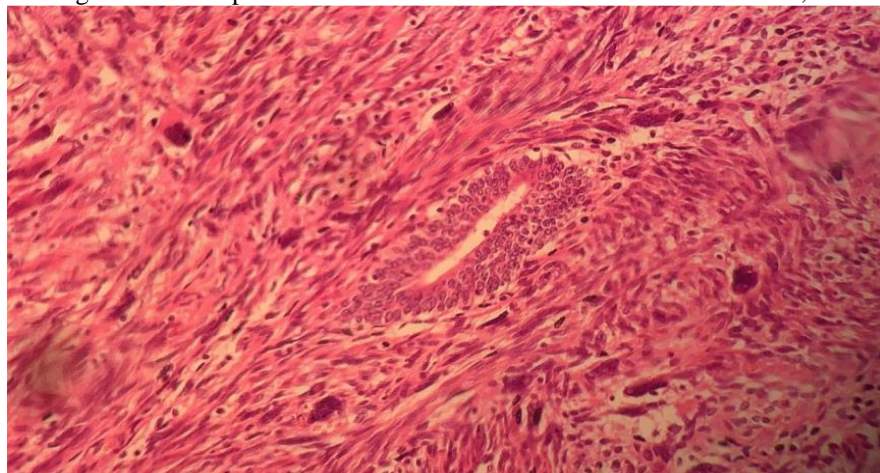
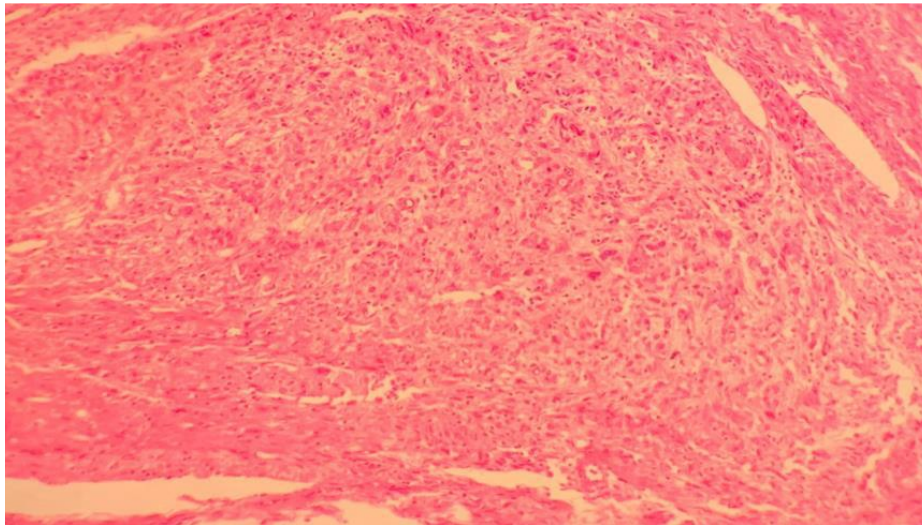


Figure 2:-Histological microscopic section of an adult granulosa tumor of the ovary Standard staining ,hemalun eosin x 25.



Conclusion:-

The association of uterine adenosarcoma and a tumor of the granulosa of the ovary is very rare the diagnosis is usually made in post surgery ,its treatment is total hysterectomy with bilateral adnexectomy and the prognosis is favorable.

Conflicts of interest:

The authors declare no conflict of interest

References:-

- [1] Clement PB, Scully RE. Mullerianadenosarcoma of the uterus. Hum Pathol. 1990;21:363–81.
- [2] aku T, Silverberg SG, Major FJ, et al. Adenosarcoma of the uterus. Int J GynecolPathol.1992;11:75–88
- [3] Evans AT, Gaffey TA, Malkasian GD Jr. Clinicopathologicreview of 118 granulosa and 82thecacelltumors. ObstetGynecol.1980;55:231-238.
- [4] Unkila-Kallio L, Tiitinen A, Wahlstrom T, et al. Reproductive features in women developingovarian granulosa celltumour at a fertile age. Hum Reprod.2000;15: 589-593.
- [5] Stenwig JT, HazekampJT ,Beecham JB. Granulosa celltumors of the ovary. Gynecol Oncol.1979;7:136-152.
- [6] Pectasides D, PectasidesE ,Psyrris A . Granulosa celltumorof the ovary. Cancer TreatRev.2008; 34: 1-12.
- [7] Fatnassi R, Amri. L'adénosarcomeutérin à propos d'un cas. J GynecolObstet Biol Reprod.2005; 34:270-272.
- [8] Piura B, Rabinovich A, MeirovitzM,et al . Mullerianadenosarcoma of the uterus. Eur J GynaecolOncol.2000;21: 387-390.
- [9] H Farhat M, Hobeika E.M, MoumnehG,et al. Uterine Mullerian adenosarcomawithSarcomatousovergrowth fatalrecurrencewithintwoweeks of diagnosis. Journal of MedicalCase Reports.2007;1:103.
- [10] Kabwa L, Mattei JP, Eloit S, et al. Un casd'adénosarcomeutérin et vaginal dansUncontexte de prolapsusgénitalremanié. J Chir .1997;134:80-5.