



Journal Homepage: [-www.journalijar.com](http://www.journalijar.com)

## INTERNATIONAL JOURNAL OF ADVANCED RESEARCH (IJAR)

Article DOI:10.21474/IJAR01/12673  
DOI URL: <http://dx.doi.org/10.21474/IJAR01/12673>



### RESEARCH ARTICLE

#### USE OF CHLOROQUINE IN ASYMPTOMATIC ELDERLY COVID19 PATIENTS, A PLACEBO OR RATHER A SOURCE OF COMPLICATIONS: A CASE REPORT

**Benyamna I**

Cardiologist and PhD at Ibn Zohr University, Agadir, Morocco, Provincial Hospital Ibnou Baja, Taza, Morocco.

#### Manuscript Info

##### Manuscript History

Received: 05 February 2021  
Final Accepted: 10 March 2021  
Published: April 2021

##### Key words:-

Covid 19, Elderly, Chloroquine Phosphate, Thromboembolic Events and Covid19, Side Effects, Cerebral Venous Thrombosis

#### Abstract

Coronavirus 19 is a virus that caused a pandemic that started in Wuhan, CHINA in December 2019. Whatever it is a respiratory tropism virus, it can cause thromboembolic complications. The disease seems to be more severe in older patients with this virus. However, the introduction of treatment for this purpose remains to be discussed in asymptomatic older subjects. We report the case of a 90-year-old man positive for covid 19 but totally asymptomatic on admission. The administration of chloroquine combined with azithromycin caused digestive side effects leading to dehydration, probably resulting in cerebral venous thrombosis on the 5th day of treatment. The review of the literature and in the absence of large cohort studies demonstrating the value of these treatments, leads us to propose treatment on a case-by-case basis and even better to avoid it in asymptomatic elderly subjects without comorbidities.

*Copy Right, IJAR, 2021., All rights reserved.*

#### Introduction:-

Coronavirus disease 19 'COVID 19' is caused by severe acute respiratory syndrome 'SARS COV2' coronavirus 2. It first appeared in Wuhan in China then spread around the world in a pandemic form. Covid 19 is primary an acute respiratory infection with a variable severity. However, it may predispose to both venous and arterial thromboembolism due to excessive inflammation, hypoxia, immobilization and intravascular vasculopathy. We report a case of cerebral venous thrombosis in a covid 19 positive nanogenitor.

#### Case description

A 90 year old man was referred to our COVID 19 unit by the epidemiological team after a survey that has been performed in Oudamlil, a village that is located 20 km from Taza, a city in the northern east of Morocco.

He neglected a benign flu like syndrome that occurred 2 weeks after a trip back from Italy and so a nasopharyngeal covid 19 swab was taken 46 days after his return, which confirmed active covid 19 infection.

The patient has no past medical history a part from blindness in early childhood.

On admission, he had neither respiratory signs nor neurological symptoms, and no fever. Blood pressure was 120/70 mmHg. Oxygen saturation on room air was 99 percent and respiratory rate was 18 breaths per minute. Laboratory findings are reported in table 1.

**Corresponding Author:- Benyamna I**

Address:- Cardiologist and PhD at Ibn Zohr University, Agadir, Morocco.

Chest radiography showed soft bilateral infiltrates (figure1). We completed by a chest CT that showed bilateral frosted glass opacities with an estimated 20 percent parenchymal damage (figure 2). We have instituted a chloroquine treatment combined with azithromycin.

He had digestive side effects which were controlled with symptomatic treatment. Later, he presented neurological signs on the fifth day of treatment, first he presented dizziness with incoherent speech then he had a partial right hemiparesis deficit, the Glasgow score has been calculated at 13. Cerebral CT scan showed hyper density within the upper longitudinal sinus suggestive of venous thrombosis (figure 4); it has also viewed left external capsular ischemic lacunar lesions. Electrocardiogram showed a sinus rhythm without any abnormalities (figure 5). Laboratory test showed hyponatremia at 123mEq/l, elevated blood cell count and a high C reactive protein level. A urinary tract infection was identified with a negative culture. The patient was treated with low molecular weight heparin LMWH and ceftriaxone 2g per day. A second control injection scan was carried out after 24 hours and confirmed persistent venous thrombosis without any worsening of images. No endovascular intervention has been performed. After 48H, following rehydration, the Glasgow score improved to 15 and the body deficit has regressed. The biological parameters also improved as resumed in table 1. PCR covid19 test being negative twice at the 9<sup>th</sup> and 10<sup>th</sup> day of treatment respectively, patient was deemed suitable for discharge and commenced Rivaroxaban 20 mg daily for three months and salicylic acid 75 mg per day. Evolution was favourable.

### **Discussion:-**

CVT is a rare cause of stroke which nearly represents 0, 5 percent of all stroke cases (1, 5, 6, 8). Most series reported predominance in young people (7, 8, 23, 24). Clinical symptoms are highly variable and are summarized in table 2; the most common are headache and alteration of mental status (1).

Risk factors are listed in table 3. In our case, dehydration and urine infection seemed to be the anticipating factors.

The superior sagittal sinus is the more frequently reported location (1). Deep CVT have usually a poor prognosis leading to death or severe neurologic sequelae (5, 6, 9).

In a pooled analysis, cerebrovascular disease was found to be associated with a 2.5-fold increased disease severity in patients with COVID-19 (15). Authors hypothesized that like all six beta coronaviruses already identified; SARS cov2 is also neurotropic (12). The physiopathological mechanisms would associate direct brain invasion by the virus or a mediated penetration via the angiotensin converting enzyme 2 "ACE2" (12,13), which would trigger a massive neuro inflammatory cascade more or less associated with damage caused by systemic inflammation and hypoxia. Simultaneous immune injury has been also suggested as an additive factor in the neuropathology. Wu and al have identified coagulation abnormalities that may increase the risk of neurological complications in patients infected with covid19 (19). A few cases of CVT have been reported in covid19 positive patients' series. Asadipooya and Simani reported 1 case, as did Li and al. Daniel D Cavalcanti reported three fatal CVT in young previously healthy people. UK and Spanish authors reported younger cases of CVT with good prognosis (2).

As for imaging diagnosis, we used in our case a non-contrast computed tomography (NCCT) which was suggestive for CVT, followed by a contrast enhanced CT (CECT) that confirmed CVT.

Despite CT is widely used as the first line neuroimaging test, it usually remains insensitive depending on the time of its realization and the presence or absence of venous anatomical variations. CECT may show the classic "empty delta" sign. CT venography CTV may strengthen the diagnostic arsenal in late-onset cases. However, magnetic resonance imaging MRI is more sensitive for the detection of CVT than CT at each stage of thrombosis (1). Thus, it's recommended as the initial neuroimaging test by the ACC (8).

Concerning the treatment, our patient was initially treated by LMWH according to the guidelines (8), and then switched to continue oral anticoagulation by rivaroxaban for three months.

Neither the ACC (2011 guidelines), nor the European stroke organization endorsed by the European Academy of neurology in 2017 recommended the use of direct oral anticoagulants DOA in CVT regarding the lack of evidence (8, 14). Nevertheless, several publications, even for small cohorts, have shown that the use of DOA was safe and that there was no inferiority or excess risk of hemorrhage compared to warfarin in this indication (14). In our case, after almost three months of follow up, our patient was well without any hemorrhagic complication.

Was the introduction of chloroquine justified?

Referring to the literature, it has been found that people of all ages are generally susceptible to the new virus covid19, but the elderly and patients with multiple chronic diseases have the highest rates of severe illness and mortality (18).

Chloroquine (CQ) was first shown to effectively suppress Severe Acute Respiratory Syndrome Coronavirus 2 (SARS-CoV-2) in in vitro assay ( 21,22 ), and has been subsequently suggested to be efficacious in slowing the deterioration of pneumonia, improving lung imaging results, decreasing viral load, and thus shorten disease duration.

Hydroxychloroquine HXQ was preferred over chloroquine as adjunctive emergency treatment since the first release of this guidance (13th of March, 2020), taking also into account that therapy would be likely required mostly in older patients and/or in case of severe disease. The initial clinical study that suggested a shorter viral shedding in hydroxychloroquine-treated patients (compared to controls) had however several major limitations (small sample size, non-homogeneous compared groups, and rather late HXQ administration) making it a very weak evidence base. Recovery trial has stopped enrolling patients on the 5th of June after finding no beneficial effect of hydroxychloroquine (9600 mg over 10 days) in patients hospitalized with COVID-19 (4). Moreover, based on the encouraging ‘‘ in vitro ‘‘ results, clinical trials of chloroquine were conducted in hospitals in Beijing and Guangdong province, and the results showed that chloroquine phosphate may be effective in treating covid19 (22). Xuelin Sun and al published a paper on March that guides using of chloroquine phosphate in elderly covid19 positive patients, they recommended for patients with a bodyweight of more than 50 kg, chloroquine phosphate 500 mg orally, bid, for 7 days, for those with a bodyweight of 50 kg or less, 500 mg, bid, on the 1<sup>st</sup> and 2nd days, and 500 mg daily on the 3rd to 7th days.

Cheng Cui and al proposed a physiologically based pharmacokinetic model(PBPK) to optimize the use of CQ in covid19 patients (17). They thus recommended 250mg bid during 5 days for geriatrics (65 to 98 years old), cirrhotic, patients whose glomerular filtration ratio GFR is less than 30ml/mn or between 30 and 60, pregnant women and children. Our 90 years old patient had a GFR 38 ml/mn, with no comorbidities. Despite lack of symptoms at admission, He has an estimated 20 per cent pulmonary parenchymal damage which has increased to 40 percent (figure 3) under chloroquine therapy 500 mg bid during 10 days, associated with azithromycin 500mg the 1<sup>st</sup> day followed by 250mg from 2<sup>nd</sup> to 7<sup>th</sup> day.

Instead of radiological improvement, the patient experienced hypoglycemia and digestive side effects with nausea, abdominal cramps, vomiting, diarrhea and anorexia contributing to dehydration, severe hyponatremia, which most likely contributed to the CVT.

#### Tables and figures:

**Table 1:-** Evolution of biologic parameters during hospitalization.

| biochemical parameters |                             | value 1st day | 5th day | 10th day |
|------------------------|-----------------------------|---------------|---------|----------|
| Parameters             | Unit                        |               |         |          |
| hemoglobin(Hb)         | g/dl                        | 14,8          | 13,7    | 14       |
| White cells (WC)       | $\times 10^3 / \text{mm}^3$ | 8,86          | 13,4    | 8,89     |
| Neutrophils (NPN)      | $\times 10^3 / \text{mm}^3$ | 5,45          | 11,2    | 6,1      |
| Lymphocytes            | $\times 10^3 / \text{mm}^3$ | 2,09          |         | 1,9      |
| platlets               | $\times 10^3 / \text{mm}^3$ | 376           | 340     | 320      |
| C Reactive protein     | mg/l                        | 1,5           | 179     | 123      |
| Ferritin               | ng/ml                       | 93,8          |         |          |
| Protein                | g/l                         | 67            | 70      | 76       |
| creatinin              | mg/l                        | 10,4          | 11      |          |
| Sodium                 | mEq/l                       |               | 123     | 131      |
| potassium              | mEq/l                       |               | 5,3     |          |
| Glycemia               | g/l                         | 0,7           | 0,5     | 0,6      |
| Calcium                | mg/l                        | 84,5          | 87      |          |
| Alcalin Reserve        | mEq/l                       |               |         | 17       |

**Table 2:-** Clinical presentation of cerebral venous thrombosis (7, 23).

|   |
|---|
| <p><b>Symptoms</b></p> <p>Headache</p> <p>Papilloedema</p> <p>Motor deficit</p> <p>Sensory deficit</p> <p>Seizures</p> <p>Delirium</p> <p>Aphasia</p> <p>Amazement</p> <p>Coma</p> <p>Oculomotor paresie</p> <p>Visual disturbances</p> <p>Meninjes signs</p> <p>Hemianopsia</p> <p>Cerebella signs</p> <p>Pulsatile tinnitus</p> <p>Vertigo</p> <p>Optic ataxia</p> <p>Cranial breath</p> <p>Forced gaze deviation</p> <p>Heminegligence</p> <p>unintentional movements</p> <p>other cranial nerve paresis</p> <p><b>Presentation syndromes</b></p> <p>Focal syndrome</p> <p>Encephalopathy</p> <p>Intracranial hypertension</p> |
|---|

**Table 3:-** Risk factors for cerebral venous thrombosis (7, 23).

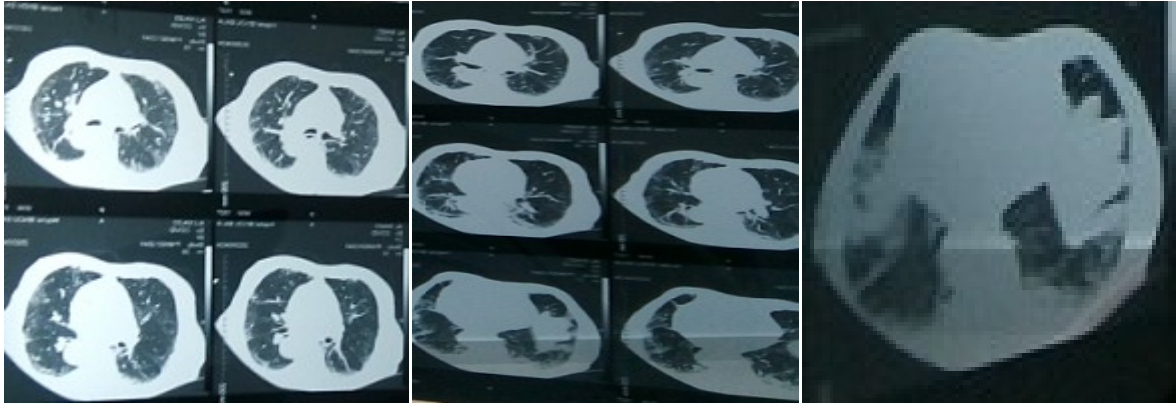
|  |
|--|
| <p><b>Prothrombotic conditions</b></p> <p>Abnormal coagulation factors: deficiency or resistance, Hyperhomocysteinemia</p> <p><b>Pregnancy and puerperium</b></p> <p><b>Cancers</b></p> <p><b>Infections</b></p> <p><b>Drugs</b></p> <p>Oral contraceptives, Androgen, Danazol, lithium, vitamin A, intravenous immunoglobulin, ecstasy</p> <p><b>Dehydration</b></p> <p><b>Mechanical precipitants</b></p> <p>Epidural blood patch, spontaneous intracranial hypotension, Lumbar puncture</p> <p><b>Other hematologic disorders</b></p> <p>Paroxysmal nocturnal hemoglobinuria</p> <p>Iron deficiency anemia</p> <p>Nephrotic syndrome</p> <p>Polycythemia, thrombocythemia</p> <p><b>Systemic diseases</b></p> <p>Systemic lupus erythematosus</p> <p>Behcet disease</p> <p>Inflammatory bowel disease</p> <p>Thyroid disease, Sarcoidosis</p> |
|--|

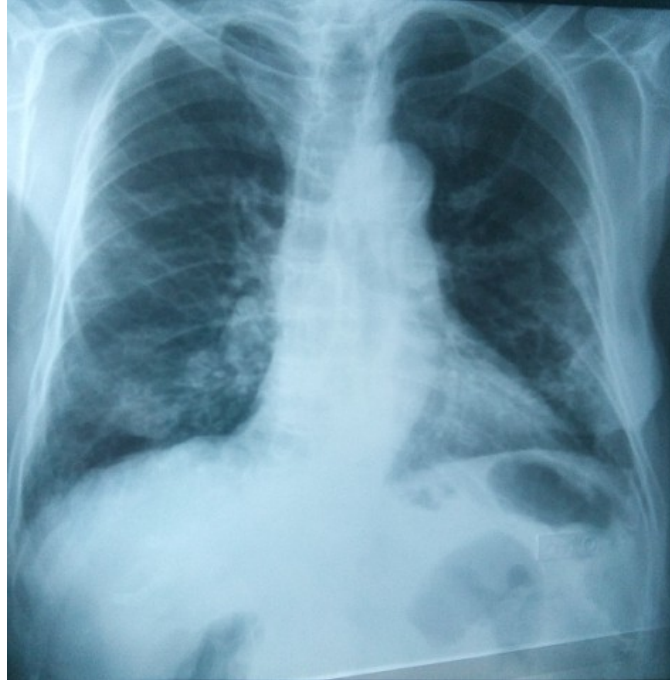

Figure 1:- Chest x-ray at admission.

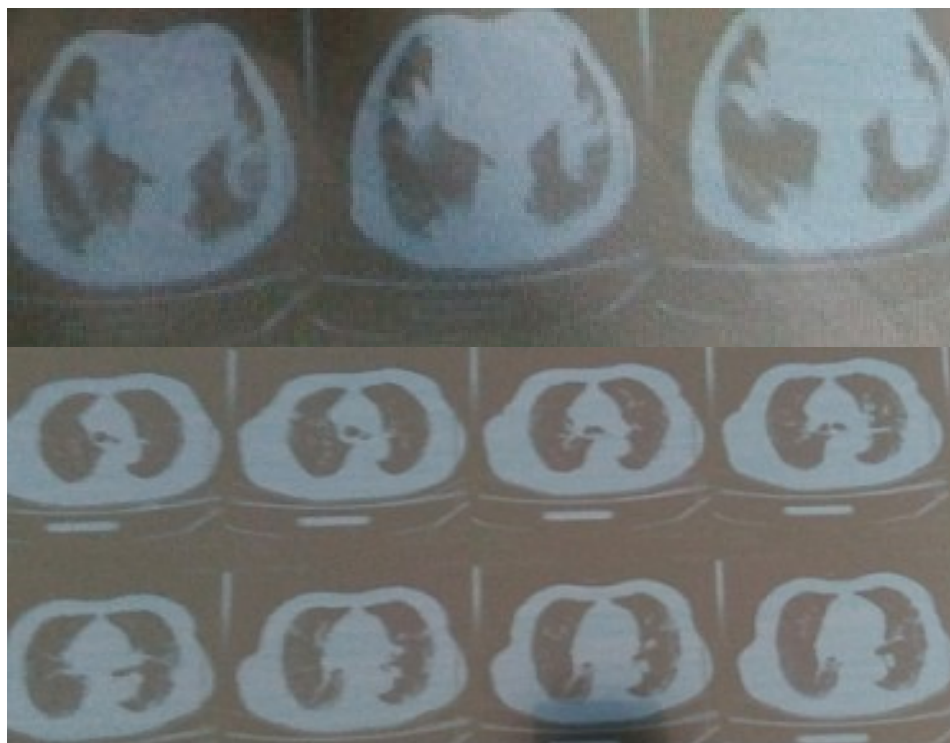

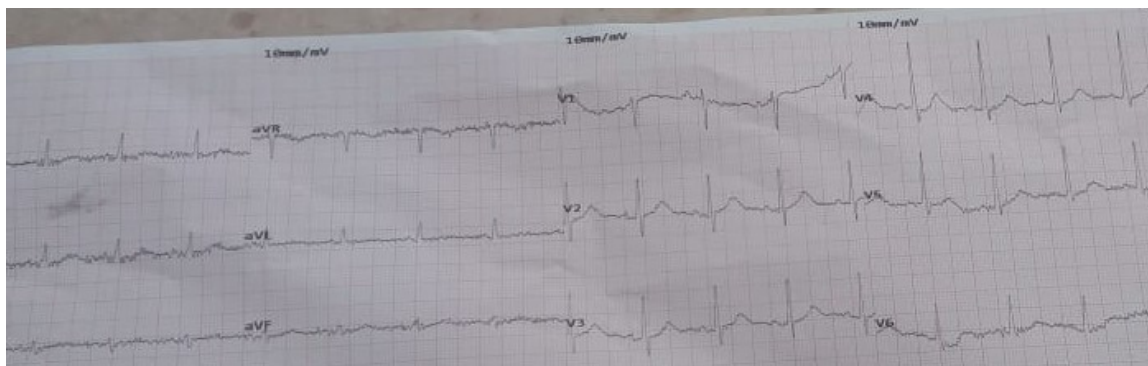
Figure 2:- Thoracic computed tomography at admission.



**Figure 3:-** Thoracic computed tomography after Chloroquine use.



**Figure 4:-** Cerebral computed tomography showing cerebral venous thrombosis.



**Figure 5:-** EKG at admission (redone several times during hospitalization, remained unchanged).

### **Conclusion:-**

It might be wiser not to use chloroquine in asymptomatic, previously healthy, elderly Covid 19 patients with mild or moderate pneumonia and to restrict therapeutic intervention to thromboembolic prophylaxis in high-risk subjects, with close monitoring. Viral load study could be a selection criterion, as chloroquine could be proposed in patients with a very high viral load especially in the presence of co-morbidities.

### **Acknowledgments:-**

The author thanks the entire medical teams that operates the Covid 19 hospital unit at Ibnou Baja Hospital and are Dr:

El Filali Mohamed, El Hassani Mohamed, Benosman Nabil, NfissiLoubna, El machichiAlami Sabah, Jamal Laila, HammoutiLahbib, KerbouteNisrine, BoudouhElhassane, OuazzaneAbdellah, Ammour Hicham, Atik Saida, Khalil Najat, Najoui Mohamed, El mali Aziza, HafidImane, BelamahiRajae, Boujarnija Hajar, BougaiziKhaoula, Benhaddou Nouredine, KhalkanNoujoud, CherradiLachhabIhssane, Sedki Hafssa, LahlouKenza, SbiyaaMohsine, LemamiMeryem, El Ayyoubi Naima, Bounoual Mohamed, Bounjoua Mustapha, RouhHoumane Amine, EnnaciriBadr, Ait Mansour M'hamed, GhafouliZakia, Mazar Aziza, Laarraj Mohamed, Eddaamouch Nadia, Abdeljalil Zahra, El HafidiHafida, El makriniAicha, Misbah Abdeladim, KourrichWijdane, Zerious Layla, Benzekri Younes, ChouyakhIchrak, Daoudi Fatima Zahra, DoudouhAthman, Zarrouki Mohamed, ZalrhiOmaima and El HasnaouiAmeur.

Author also thanks the nursing and paramedic staff.

### References:-

- 1/ Saposnik G, Barinagarrementeria F, Brown RD Jr, Bushnell CD, Cucchiara B, Cushman M, deVeber G, Ferro JM, Tsai FY; on behalf of the American Heart Association Stroke Council and the Council on Epidemiology and Prevention. Diagnosis and management of cerebral venous thrombosis: a statement for healthcare professionals from the American Heart Association/American Stroke Association. *Stroke*. 2011; 42:1158–1192.
- 2/ Hughes C, Nichols T, Pike M, Subbe C, Elghenzai S. Cerebral venous sinus thrombosis as a presentation of COVID-19. *EJCRIM* 2020;7: doi: 10.12890/2020\_001691.
- 3/ Daniel D. Cavalcanti, Eytan Raz, Maksim Shapiro, SeenaDehkharghani, ShadiYaghi, Kaitlyn Lillemoe, ErezNossek, Jose Torres, Rajan Jain, Howard A. Riina, Alireza Radmanesh, Peter Kim Nelson. Cerebral Venous Thrombosis associated with COVID-19. *American Journal of Neuroradiology*.  
<http://dx.doi.org/10.3174/ajnr.A6644>
- 4/ Sun X, Li Sh, Li K, Hu X. Pharmaceutical care of chloroquine phosphate in elderly patients with coronavirus pneumonia (COVID-19). *Aging Medecine* March 2020, DOI: 10.1002/agm2.12104.
- 5/ WANG X, SUN X and LIU H. Clinical analysis and misdiagnosis of cerebral venous thrombosis. *EXPERIMENTAL AND THERAPEUTIC MEDICINE* 4: 923-927, 2012.
- 6/ DevasagayamSh, Wyatt B, Leyden J, Kleinig T. Cerebral Venous Sinus Thrombosis Incidence Is Higher Than Previously Thought, a Retrospective Population-Based Study. *Stroke*. 2016; 47:2180-2182. DOI: 10.1161/STROKEAHA.116.013617.
- 7/ Allroggen H, Abbott RJ. Cerebral venous sinus thrombosis. *Postgrad Med J*2000;76:12–15.
- 8/ Saposnik G, Barinagarrementeria F, Brown RD, Bushnell Ch D, Cucchiara B, M Cushman, deVeber G, J M. Ferro, F Y. Tsai, on behalf of the American Heart Association Stroke Council and the Council on Epidemiology and Prevention. A Statement for Healthcare Professionals from the American Heart Association/American Stroke Association. *Stroke*. 2011; 42:1158-1192.
- 9/ D'Amore A, Conte G, Vighianesi A, Muscoso EG, Chiamonte R, Chiamonte I. Elderly patient with dural sinus thrombosis leading to abnormal medullary veins and cerebral venous infarctions. *Radiology Case Reports*, Volume 7, Issue 2, 2012.
- 10/ Mao L, Wang M, Chen S, et al.: Neurological manifestations of hospitalized patients with COVID-19 in Wuhan, China: a retrospective case series study. *MedRxiv*. 2020, 10.1101/2020.02.22.20026500.
- 11/ Sheraton M, Deo N, Kashyap R, Surani S. A Review of Neurological Complications of COVID-19. DOI: 10.7759/cureus.8192.
- 12/ Zhou Z, Kang H, Li Sh, Zhao X. Understanding the neurotropic characteristics of SARSCoV2: from neurological manifestations of COVID19 to potential neurotropic mechanisms. *Journal of Neurology*, <https://doi.org/10.1007/s00415-020-09929-7>.
- 13/ Roman GC, Spencer PS, Reis J, Buguet A, El Alaoui Faris M, Katrak SM, Lainez M, Medina MT, Meshramj CH, Mizusawa H, Ozturk S, Wasay M, on behalf of the WFN Environmental Neurology Specialty Group. The neurology of COVID-19 revisited: A proposal from the Environmental Neurology Specialty Group of the World Federation of Neurology to implement international neurological registries. *Journal of the Neurological Sciences* 414 (2020) 116884.
- 14/ Ima A Kusuma. The use of new oral anticoagulant in cerebral venous sinus thrombosis: Alternative therapy with excellent result. *J Clin Exp Cardiol* 2017, 8:5 (Suppl) <http://dx.doi.org/10.4172/2155-9880-C1-068>.
- 15/ Gaurav A, Giuseppe L, and Brandon M H, Cerebrovascular disease is associated with an increased disease severity in patients with Coronavirus Disease 2019 (COVID-19): A pooled analysis of published literature. *International Journal of Stroke* 0(0) 1–5. DOI: 10.1177/1747493020921664.
- 16/ Baumgartner RW, Studer A, Arnold M, Georgiadis D. Recanalisation of cerebral venous thrombosis. *J Neurol Neurosurg Psychiatry* 2003; 74:459–461.

- 17/ Cui Ch, Zhang M, Yao X, Tu S, Hou Z, Sia JieEn V, Xiang X, Lin J, Cai T, Shen N, Song Ch, JieQiao, Shun Zhang, Haiyan Li, Dong-yang Liu, Dose selection of chloroquine phosphate for treatment of COVID-19 based on a physiologically based pharmacokinetic model. *Acta Pharmaceutica Sinica B* 810\_proof. 22 April 2020. 1/12. <https://doi.org/10.1016/j.apsb.2020.04.007>.
- 18 / Chen N, Zhou M, Dong X, et al. Epidemiological and clinical characteristics of 991 cases of 2019 novel coronavirus pneumonia in Wuhan, China: a descriptive study. *Lancet* 2020; 395:507-513
- 19/ Li Y, Wang M, Zhou Y, et al. Acute Cerebrovascular Disease Following COVID-19: A Single Center, Retrospective, Observational Study (3/3/2020). *TheLancet* 2020; Available at SSRN: <https://ssrn.com/abstract=3550025> or <http://dx.doi.org/10.2139/ssrn.3550025>.
- 20/ Wang W, Sun Q, Bao Y, et al. Analysis of Risk Factors for the Thromboembolic Events from 88 Patients with COVID-19 Pneumonia in Wuhan, China: A Retrospective Report. *The Lancet* 2020; Available at SSRN: <https://ssrn.com/abstract=3559633> or <http://dx.doi.org/10.2139/ssrn.3559633>.
- 21/ Colson P, Rolain JM, Raoult D. Chloroquine for the 2019 novel coronavirus SARS-CoV-2. *Int J Antimicrob Agents* 2020; 55:105923.
- 22/ Gao J, Tian Z, Breakthrough Yang X. Chloroquine phosphate has shown apparent efficacy in treatment of COVID-19 associated pneumonia in clinical studies. *Biosci Trends* 2020; 14:72e3.
- 23/ Souirti Z, Messouak O, Belahsen F. Cerebral venous thrombosis: a Moroccan retrospective study of 30 cases. *Pan African Medical Journal*. 2014; 17:281 doi:10.11604/pamj.2014.17.281.165
- 24/ Darshan Lal, Arunodaya R. Gujjar, Nandagopal Ramachandiran, Ammar Obaidi, Sunil Kumar, Mortada El-Tigani, Faizal Al-Azri, Abdullah R. Al-Asmi. Spectrum of Cerebral Venous Thrombosis in Oman. *Sultan Qaboos University Med J*, August 2018, Vol. 18, Iss. 3, pp. e329–337, Epub. 19 Dec 18.
- 25/ Asadi-Pooya AA, Simani L: Central nervous system manifestations of COVID- 19: a systematic review. *J Neurol Sci*. 2020, 413:116832. 1016/j.jns.2020.116832
- 26/ Wu Y, Xu X, Chen Z, et al.: Nervous system involvement after infection with COVID-19 and other coronaviruses. *Brain Behav Immun*. 2020, 10.1016/j.bbi.2020.03.031.