



Journal Homepage: - www.journalijar.com

INTERNATIONAL JOURNAL OF ADVANCED RESEARCH (IJAR)

Article DOI: 10.21474/IJAR01/12695

DOI URL: <http://dx.doi.org/10.21474/IJAR01/12695>



RESEARCH ARTICLE

AMNIOTIC MEMBRANE TRANSPLANT IN INFLAMMATORY CORNEAL ULCERS: INTEREST AND MODALITY OF FOLLOW-UP BY ANTERIOR SEGMENT OCT

Taieb El Baroudi, Sarah Belghmaidi, Darfaoui Zainab, Ibtissam Hajji, Abdeljalil Moutaouakil and Hassna Soummane

Manuscript Info

Manuscript History

Received: 05 February 2021

Final Accepted: 10 March 2021

Published: April 2021

Abstract

Copy Right, IJAR, 2021,. All rights reserved.

Introduction:-

Corneal ulcers are a major cause of ocular morbidity (1-2). Its etiologies are numerous, mainly predominated by traumatic causes, and they stem from inflammatory, neurotrophic or infectious origins (3). Inflammatory corneal ulcers have a common immune origin and they are considered non-infectious diseases, however, in some cases, they are mediated by infectious agents. The general prognosis of this condition as well as the integrity of the eyeball and vision are generally compromised, urging thus the therapeutic management to be fast and appropriate.

The treatment is mainly medical but in the case of advanced or pre-perforative ulcer, the surgical intervention is required in order to preserve the eyeball's tightness and prevent infectious complications. Interestingly, the amniotic membrane allows a permanent or temporary reconstruction of the corneal surface especially in countries where the availability of corneas is limited (4).

The objectives of our study are to:

1. Describe the epidemiological, clinical and therapeutic characteristics of inflammatory ulcers.
2. Show the added value of amniotic membrane transplantation in the management and therapeutic management of inflammatory corneal ulcers.
3. Analyze the structural characteristics and assess changes in the cornea and membrane after its integration using anterior segment OCT.

Patients And Methods:-

The present work is a prospective study conducted in the Ophthalmology Department of the Mohammed VI Hospital in Marrakech, Morocco between January 2015 and September 2020, covering 87 cases of inflammatory corneal ulcer.

All patients received a comprehensive etiological assessment in internal medicine (Complete Blood Count, C-Reactive Protein, protein electrophoresis, viral hepatitis serology, TPHA, VDRL, ANCA and C-ANCA, anti SSA and SSB antibodies, anti-DNA antibodies, anti SM antibodies, rheumatoid factor, anti-CCP antibodies, research of circulating immune complexes, serum complement dosage, or even HLA typing...) and medical therapeutic management (corticosteroid bolus, immunosuppressants, etc.) and urgent surgical management represented by an amniotic membrane transplant in case of pre-perforative ulcer.

The monitoring parameters were:

1. Clinical assessment and photographs at the slit lamp at D2, D8, D25 then monthly.
2. OCT of the anterior segment in the case of Amniotic membrane transplant (assessment of the thickness of the amniotic membrane and receptor cornea, degree of membrane integration with corneal stroma, epithelialization of the amniotic membrane and stability of the thickness of the corneal stroma).

Results:-

We included 87 patients, 48 men and 39 women and a sex ratio of 55.17%. The average age was 53.15 years (ranging between 32 and 92 years). The main reasons for consultation were; photophobia and eye pain.

The corneal impairment was unilateral in 57% cases and central location in 51% cases and an ulcer size that varied between 2 to 5.5mm. Etiologies were dominated by rheumatoid arthritis (22 patients), Gougerot syndrome (18 patients), ocular rosacea in 2 patients, 1 case of ocular pemphigoid, 2 cases of inflammatory psoriasis, 3 patients followed for ankylosing spondylitis, 1 case of Crohn disease revealed by an eye injury and an idiopathic ulcer in 38 patients (Fig.1).

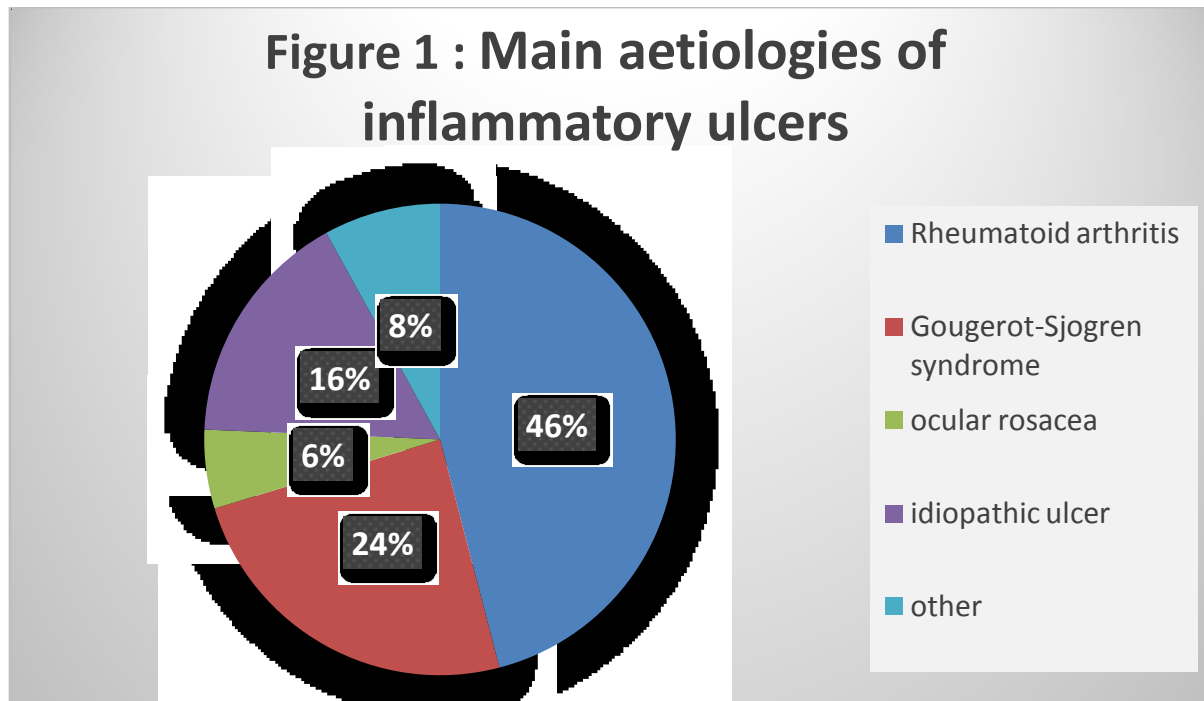


Figure 1:- Main aetiologies of inflammatory ulcers in our series.

Medical therapeutic management: 27 patients received corticosteroid bolus type methylprednisolone, 12 patients were under immunosuppressants (Methotrexate, Azathioprine or Cyclosporin) and all our patients used local corticosteroid and lubricants. Biotherapy has been exclusive for severe and recurrent forms (2 patients).

41 patients developed a pre-perforative ulcer requiring an amniotic membrane transplant:

1. 24 patients received an amniotic membrane transplant in multilayer technique Inlay sutured with Monofil 10/0) (Fig. 2),
2. 17 patients received an amniotic membrane transplant and Overlay patch technique.

5 patients received a conjunctiva resection.

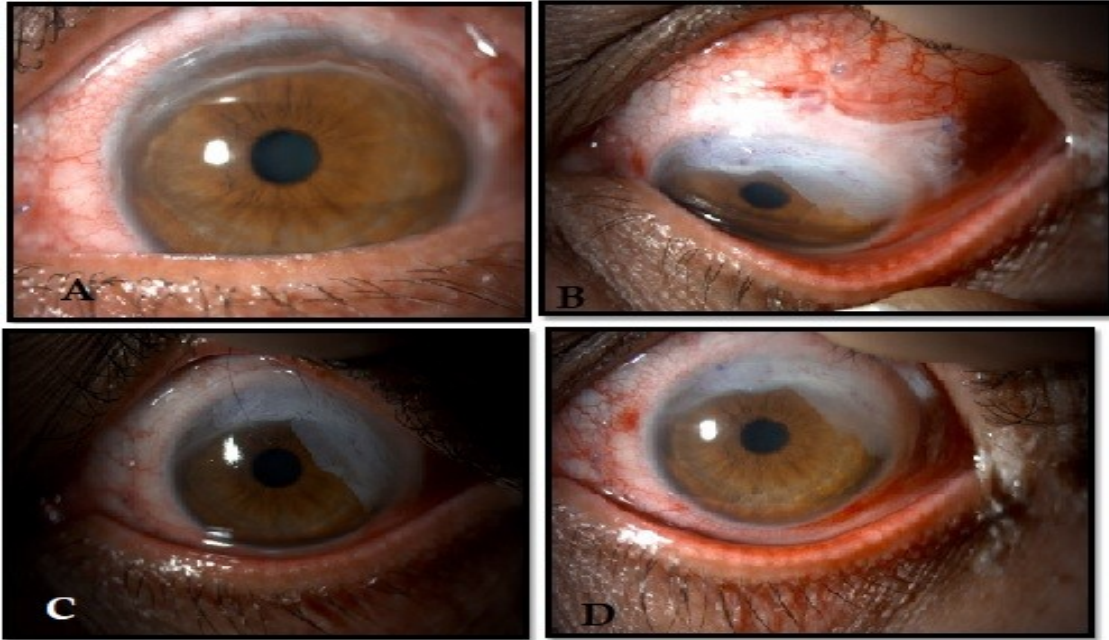


Figure 2:- Upper marginal corneal ulcer in the case of a woman treated for rheumatoid arthritis polyeydic, she has benefited from a multi-layered amniotic membrane transplant: A. The ulcer aspect before surgery /B: The ulcer aspect postoperatively at day1 /C and D: The ulcer aspect postoperatively at day7 with the beginning of integration of the amniotic membrane to the corneal stroma.

Anatomical result.

Complete recovery was obtained in 62% of our patients, the average recovery time was 33 days. A recurrence was reported in 11 patients. The anterior segment OCT was performed before the surgical procedure whenever it was possible. At day 2, the average thickness of the inlay amniotic membrane was $226 \pm 129 \mu\text{m}$. At day 8, this thickness has decreased to $109 \pm 40 \mu\text{m}$. At day 25, more than 90% of patients integrated the membrane into the corneal thickness, with an average corneal thickness of $489 \pm 83 \mu\text{m}$. The integration of this membrane has been associated with partial fibrosis, allowing thus the anatomical restitution of corneal thickness and corneal regeneration in 100% of patients. The epithelialization of the graft was obtained after an average of 5 weeks (Fig. 3).

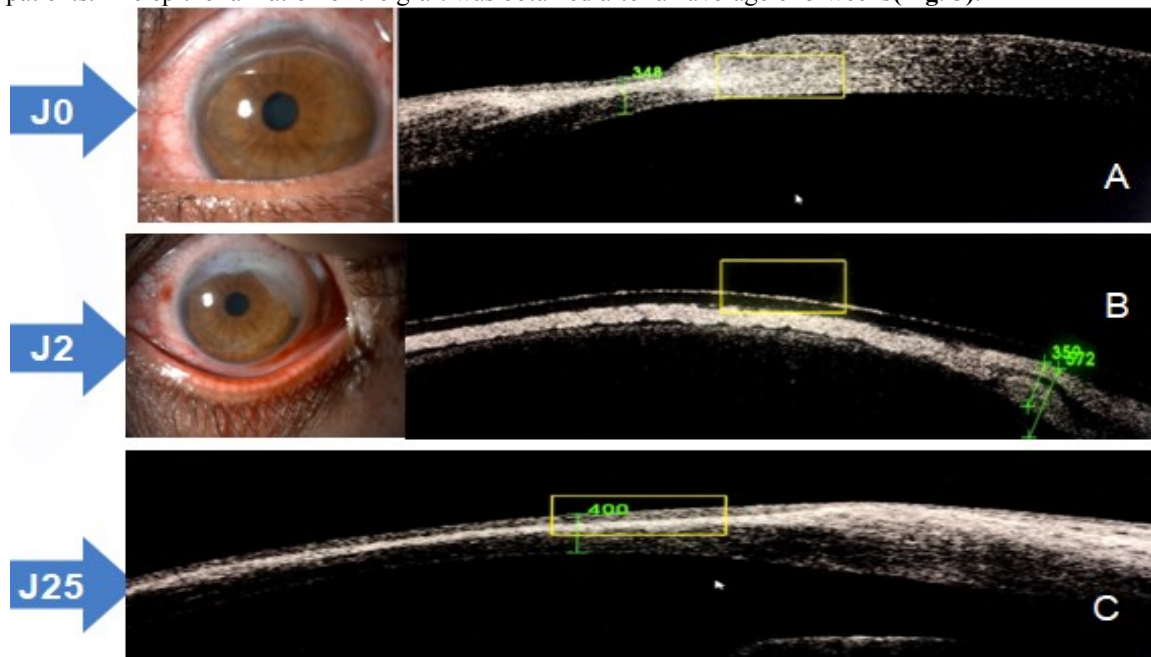


Figure 3:- A: Marginal ulcer with corneal thinning visible in the OCT SA image, corneal thickness 348 m. B: Aspect of day 2 ulcer after GMA multilayer technique, OCT SA showing the hyper reflective amniotic membrane filling the bottom of the ulcer. Image C: OCT SA postoperative aspect at day 25, total amniotic membrane integration to corneal stroma and return of corneal thickness 400 m.

Functional recovery result.

The appreciation of functional recovery consisted on measuring visual acuity under correction for all our patients. After an average decline of 6 months, the best visual acuity under correction was more than 5/10 in 39 patients, between 1/10 and 5/10 in 28 patients and lower than 1/10 in 11 patients, 85% of patients retained central or peripheral sequellar opacity and only 1 patient displayed anatomical and functional loss of the globe (Fig. 4).

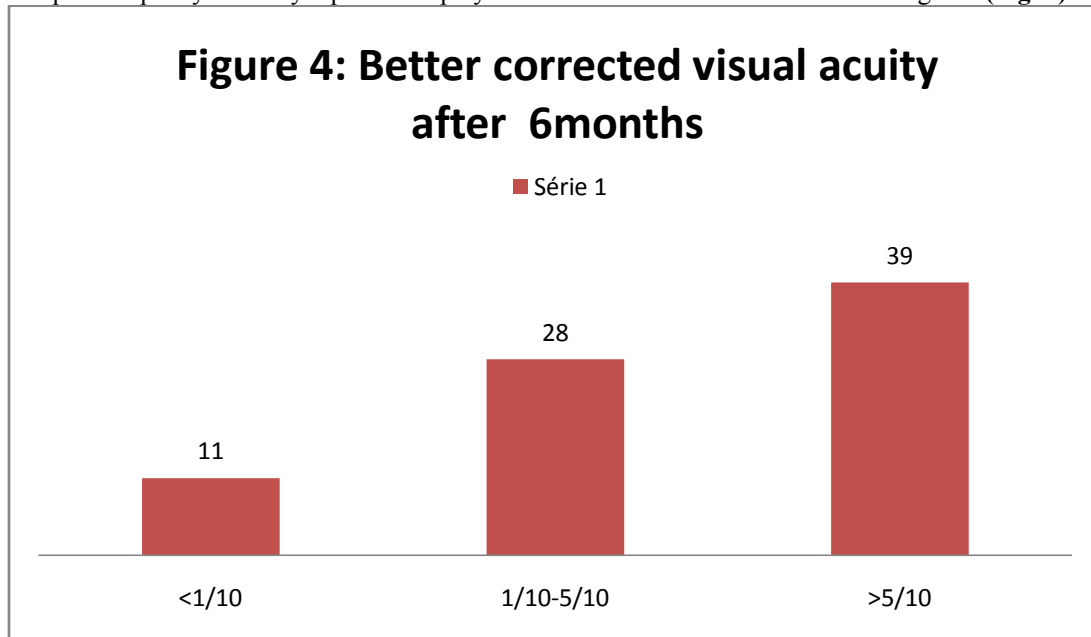


Figure 4:- Better corrected visual acuity after 6 months.

Discussion:-

Inflammatory pre-perforative ulcers and pre-perforating ulcers are rare and severe situations that involve the anatomical and functional prognosis of the eye. The etiologies are multiple and diverse resulting mainly from autoimmune rheumatic diseases. The immunological mechanisms involved in the ontogeny of these diseases are variable, involving either cellular or humoral immunity mechanisms of immediate hypersensitivity.

The clinical diaspora is rich but insufficient to make an adequate and accurate etiological diagnosis. Multidisciplinary management is therefore essential involving ophthalmologists, internists and dermatologists.

Complementary explorations are considered as corner stones in the diagnosis of these pathologies: immunological blood check-up, radiological examination, scratching of a corneal ulcer, conjunctival smear, conjunctiva biopsy with immunohistochemical study, detection of IgE in tears, electrophoresis of tears.

The treatment of these ulcers must be early and aggressive, it consisted mainly on local applications of anti-inflammatory and immunosuppressive drugs (corticosteroids, ciclosporin) and/or general applications (intravenous methylprednisolone bolus, cyclophosphamide in monthly intravenous courses in cases of pathologies involving humoral immunity therapy, biotherapy. Finally, orally, prednisone or various immunosuppressants such as mycophenolate mofetil can be used).

The choice of the surgical techniques to be used depend upon the size and location of the perforation and ulcer: conjunctiva resection exposing the sclera, the application of cyanoacrylic glue on the bottom of the ulcer, amniotic membrane transplantation, peripheral lamellar keratoplasty, or even transfixitic keratoplasty(3).

Among these surgical techniques, amniotic membrane transplantation is a simple and effective technique for definitive or temporary reconstruction of the corneal surface, especially in countries where the availability of corneas is limited (4). The surgical use of the human amniotic membrane in pathology goes back to several decades. In context of ophthalmology, it was first used in the treatment of symblephons and conjunctival deficits (5). In 1995, Tseng (6) reassessed this technique in the treatment of surface eye pathologies. In 1997, Lee and Tseng (7) conducted for the first time a clinical study reporting the outcomes of amniotic membrane usage in the treatment of trophic corneal ulcers.

The amniotic membrane serves as a substrate for deficient epithelial regrowth and partially replaces the matrix of the missing stroma. The surgeon aims to integrate the amniotic membrane into the cornea; it is then used in corneal epithelial and stromal ulcers. In the case of loss of stromal substance, the best technique is to perform a multi-layered amniotic transplant. This technique has been reported for the first time by Kruse (8) in the management of deep ulcers. Amniotic membrane transplantation has also demonstrated its effectiveness in repairing corneal perforations in several studies (9-10).

In the follow-up of the amniotic membrane transplant, the examination with the slit lamp remains essential, hence allowing to appreciate the formation of the anterior chamber, the presence of a Seidel, the epithelialization of the amniotic membrane and the stability of the thickness of the corneal stroma.

Optical coherence tomography (OCT) of the anterior segment is an imaging technique that allows real-time, good-resolution images of the entire anterior chamber and cornea (11).

The OCT is usually performed before surgery allowing the examination of morphological parameters of the receptor cornea and ulcer (size, depth) (12) (13). OCT has also tremendous benefits in the case of keratitis since it allows an accurate appreciation of necrosis and infiltration areas (14) and the detection of eventual presence of inflammatory reactions within the anterior chamber (15).

Immediate postoperative; OCT allows the assess of the formation of the anterior chamber in case of perforation and of the filling of multilayer amniotic membrane in the basal area of the ulcer or perforation (12).

The integration of the amniotic membrane with the corneal stroma is gradual. In 2006, Resch et al. (16,17) describes that the amniotic membrane (AM) can be integrated into the stroma in three different models: sub-epithelial integration of AM (a corneal epithelium covering the top of AM), global intra-epithelial integration of AM (corneal epithelium sandwich trap AM) and intra-stromal integration of AM (MA integrated into the corneal stroma).

The demarcation line remains visible at OCT until the third month in the form of a hyper-reflective line between the transplanted amniotic membrane and the residual corneal stroma. Subsequently, the demarcation line becomes less visible and the amniotic tissue could no longer be distinguished from the surrounding corneal stroma (18). Monitoring by OCT complements clinical monitoring and makes better quantification of corneal thickness, which tends to decrease before stabilizing around the 6th month (15,18).

Conclusion:-

Immune pathologies of the cornea have in common the immune-like inflammation of the cornea. Therapeutic management must be rapid because the anatomical and functional integrity of the globe is often threatened.

Our study demonstrate clearly that the amniotic membrane transplantation remains the best surgical alternative in the management of deep or pre-perforative ulcers. Its integration with corneal thickness is always associated with the re-epithelialization. The OCT is therefore the best assessment to monitoring the integration of this membrane.

References:-

- 1) Boruchoff S.A., Donshik P.C. Medical and surgical management of corneal thinnings and perforations *Int Ophthalmol Clin* 1975; 15: 111-123
- 2) Portnoy S.L., Insler M.S., Kaufman H.E. Surgical management of corneal ulceration and perforation *Surv Ophthalmol* 1989; 34: 47-58

3. 3)Jhanji V., Young A.L., Mehta J.S., and al. Management of corneal perforation *SurvOphthalmol* 2011; 56: 522-538
4. 4)Solomon, A., Meller, D., Prabhasawat, P., John, T., Espana, E., Steuhl, K. and Tseng, S. (2002). Amniotic membrane grafts for nontraumatic corneal perforations, descemetocoeles, and deep ulcers. *Ophthalmology*, 109(4), pp.694-703.
5. 5)From Rätth A. Plastic repair of conjunctival defects with fetal membrane. *Arch Ophthalmol* 1940; 23: 522-5.
6. 6)Kim JC, Tseng SC. Transplantation of preserved human amniotic membrane for surface reconstruction in severely damaged rabbit corneas. *Cornea* 1995; 14: 473-84.
7. 7)Lee SH, Tseng SC. Amniotic membrane transplantation for persistent epithelial defects with ulceration. *Am J Ophthalmol* 1997; 123: 303-12.
8. 8)Kruse FE, Rohrschneider K, Volcker HE. Multilayer amniotic membrane transplantation for reconstruction of deep corneal ulcers. *Ophthalmology* 1999; 106: 1504-10; discussion 1511.
9. 9)Rodriguez-Ares M.T., Tourino R., Lopez-Valladares M.J., and al. Multilayer amniotic membrane transplantation in the treatment of corneal perforations *Cornea* 2004; 23: 577-583
10. 10)Hick S., Demers P.E., Brunette I., and al. Amniotic membrane transplantation and fibrin glue in the management of corneal ulcers and perforations: a review of 33 cases *Cornea* 2005; 24: 369-377
11. 11)Baudouin C., Labbé A., El Maftouhi A., Hamard P. Application of anterior segment OCT in the study of glaucoma *Ophthalmology Service III, National Hospital for Ophthalmology of the Fifteen-Vingt JFO-07-2008, Vol 31*
12. 12)Manolova Y, Stoycheva Z, Yordanov Y, Grupcheva C. Amniotic membrane transplantation - Analysis of structural characteristics in amniotic membrane transplant and corneal ulcers. *Scripta Scientifica Medica*. 2017;49 (1):12.
13. 13)Ramos JL, Li Y, Huang D. Clinical and research applications of anterior segment optical coherence tomography - a review. *Clin Experiment Ophthalmol*. 2009;37:81-9.
14. 14)Hixson A., Blanc S., and Sowka J., "Monitoring keratitis resolution with optical coherence tomography," *Optometry and Vision Science*, 91, no. 4, pp. S40-S45, 2014.
15. 15)Igbre AO, Rico MC, Garg SJ. High-speed optical coherence tomography as a reliable adjuvant tool to grade ocular anterior chamber inflammation. *Retina* 2014;34: 504-508.
16. 16)DUA H. Amniotic membrane transplantation. *Br J Ophthalmol*. 1999 Jun;83(6):748-52.
17. 17)Resch MD, Schlotzer-Schrehardt U, Hofmann- Rummelt C, Sauer R, Kruse FE, Beckmann MW, et al. Integration patterns of cryopreserved amniotic membranes into the human cornea. *Ophthalmology*. 2006 Nov;113(11):1927-35.
18. 18)Nubile M, Dua H, Lanzini M, Ciancaglini M, Calienno R, Said D et al. In Vivo Analysis of Stromal Integration of Multilayer Amniotic Membrane Transplantation in Corneal Ulcers. *American Journal of Ophthalmology*. 2011;151(5):809-822.e1.