



Journal Homepage: [-www.journalijar.com](http://www.journalijar.com)

INTERNATIONAL JOURNAL OF ADVANCED RESEARCH (IJAR)

Article DOI:10.21474/IJAR01/12701
DOI URL: <http://dx.doi.org/10.21474/IJAR01/12701>



RESEARCH ARTICLE

GIANT SOLITARY CUTANEOUS ANGIOSARCOMA OF THE FOREARM OCCURRING OUTSIDE THE SETTING OF LYMPHEDEMA

S. Belanouane¹, F. Hali¹, F. Marnissi² and S. Chiheb¹

1. Dermatology and Venerology Department, UHC of IBN ROCHD, Casablanca, Morocco.
2. Anatomic-Pathology Department, UHC of IBN ROCHD, Casablanca, Morocco.

Manuscript Info

Manuscript History

Received: 05 February 2021
Final Accepted: 10 March 2021
Published: April 2021

Abstract

Angiosarcoma (AS) is an aggressive vascular malignancy that can affect various anatomic sites. Although rare, cutaneous angiosarcoma (CAS) is the most common clinical manifestation of AS, accounting for approximately 50% to 60% of all AS. CAS is typically known to occur in three settings: (1) idiopathic, (2) following radiation treatment, or (3) is classically diagnosed following mastectomy with subsequent chronic lymphedema (known as Stewart Treves syndrome). We present a case of CAS on the forearm in a man with no history of lymphedema or radiation therapy, highlighting the necessity to discuss this diagnosis even outside the setting of conventional angiosarcomas.

Copy Right, IJAR, 2021.. All rights reserved.

Introduction:-

Cutaneous angiosarcoma (CAS) is a rare malignant vascular tumor located in 96% of the cases on the head and neck. They typically occur following chronic lymphedema or radiation treatment [1]. We present a case of CAS on the forearm in a man without lymphedema or any other risk factor for angiosarcoma.

Case Report:

A 54-year-old man with no medical history presented to the dermatology office after he developed, over the preceding year, a painful violaceous nodule on his left forearm. The lesion was initially mistaken for a bruise, leading to a delayed presentation. The nodule later progressed to a 12x14 cm tumor with significant infiltration and fixation to the underlying structures, with overlying hemorrhagic-necrotic crust and bloodstained discharge (Figure 1). The physical exam did not objectify lymphedema. No satellite or distant lesions were noted. Sensation and motor function were intact.

The histologic analysis revealed a proliferation of irregular vascular clefts, separated by collagen fibers, with considerable cell atypia, prominent towards the lumen; the lesion exhibited cohesive epithelioid masses of atypical, large, rounded cells with eosinophilic cytoplasm and high indexed mitotic figures in the dermis. The cells stained positive for CD34 and ki-67, consistent with CAS (Figure 2, 3). Computed tomography did not show lymph node or distant metastases. The TNM staging system for soft tissue sarcoma of the trunk and extremities was IIIB. A wide excision of the tumor was performed and revealed positive margins imposing further excision. Additional treatment options were explained to the family, including radiation therapy, chemotherapy or amputation. The patient and his family chose the latter option. After the procedure, he was subsequently lost to follow-up.

Corresponding Author:- S. Belanouane

Address:- Dermatology and Venerology Department, UHC of IBN ROCHD, Casablanca, Morocco.

Discussion:-

The CAS occurs preferably on the scalp and face, and when it is localised on the upper extremities it is usually in the context of lymphedema [1]. Only few cases were reported on the extremities without prior predisposing factors [2-4] (Table 1). To our knowledge, this is the first report of CAS occurring on the upper limb without preceding lymphedema. Suchak published a series of thirteen idiopathic cases of CAS on the extremities; none was located on the upper limbs [4]

Clinical and histological diagnosis of sporadic CAS is challenging. The CD31 is until now the only best immunohistochemical marker with a high sensitivity and specificity.

There have been a few reports of CAS on the extremities treated with amputation without signs of recurrence or metastasis [4, 5]. Our patient was lost to follow-up and this contingency could not be verified.

In conclusion, we presented this case to highlight the rare occurrence of CAS in a patient outside the setting of conventional lymphedema or radiation on the upper extremity, highlighting the necessity to discuss this diagnosis even outside the conventional setting of angiosarcomas as timely recognition is necessary for further management and immediate treatment in order to optimize survival.

Table 1:- Comparative analysis of some cases of cutaneous angiosarcoma outside the setting of lymphedema reported in the literature.

	Huber et al [2]	Cooper et al [3]	Linda et al [5]	Suchak et al. [4]	Our case
Age	88	71	76	46	54 years old
Gender	Female	Male	Female	Female	Male
Location	Left lower leg	Lower Leg	Lower Leg	Left big toe	Forearm
Delay before Diagnosis	3 years	2 years	-	-	A year
Metastasis	None	-	None	None	None
Treatment	Surgical Excision	Local Excision Declined Radiotherapy	Amputation	Amputation	Amputation
Evolution	Amputation after 2 recurrences	Referred to oncology center	Eleven months free of recurrence	6 months free of Recurrence	Lost to follow-up

Legend:

Figure 1:- Cutaneous angiosarcoma presenting as a large angiomatous tumor on the dorso-lateral side of the left forearm without lymphedema.

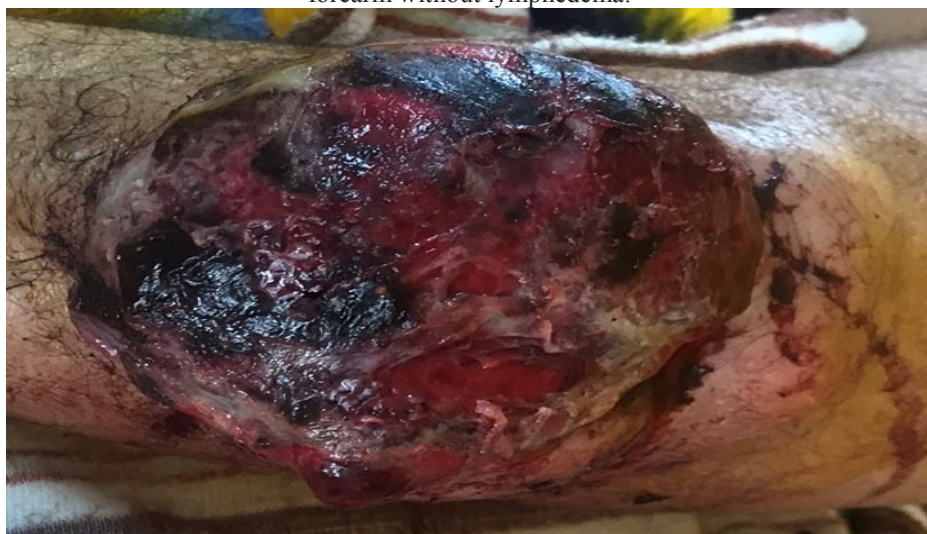

Figure 2a:- Histologic analysis revealed a poorly differentiated vascular neoplasm extending through the dermis (H&E, original magnifications ×20).

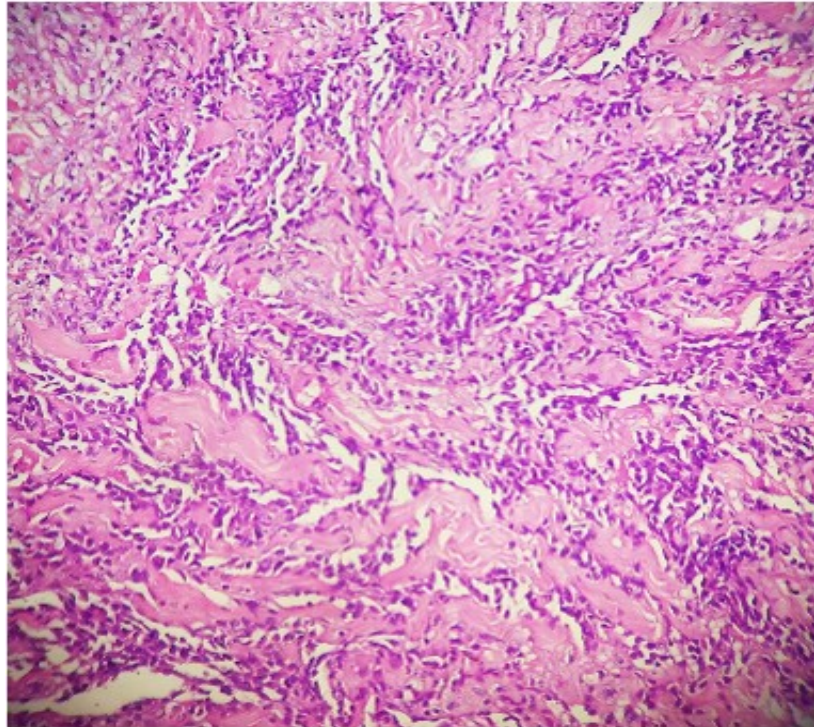


Figure 2b:- The upper dermis shows thin walled vessels with jagged lumina lined with endothelial cells with protuberant nuclei (H&E, original magnifications ×40).

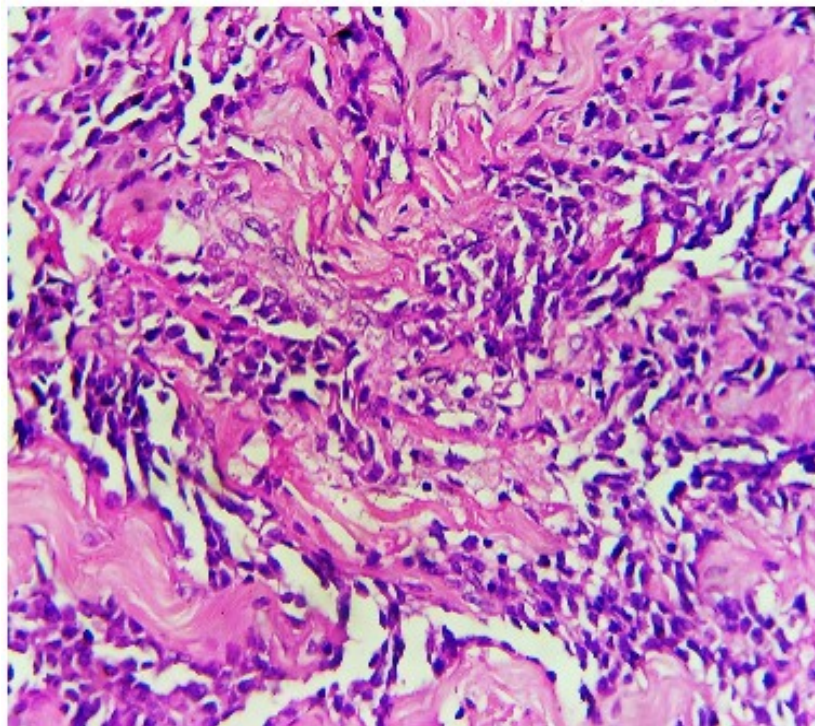
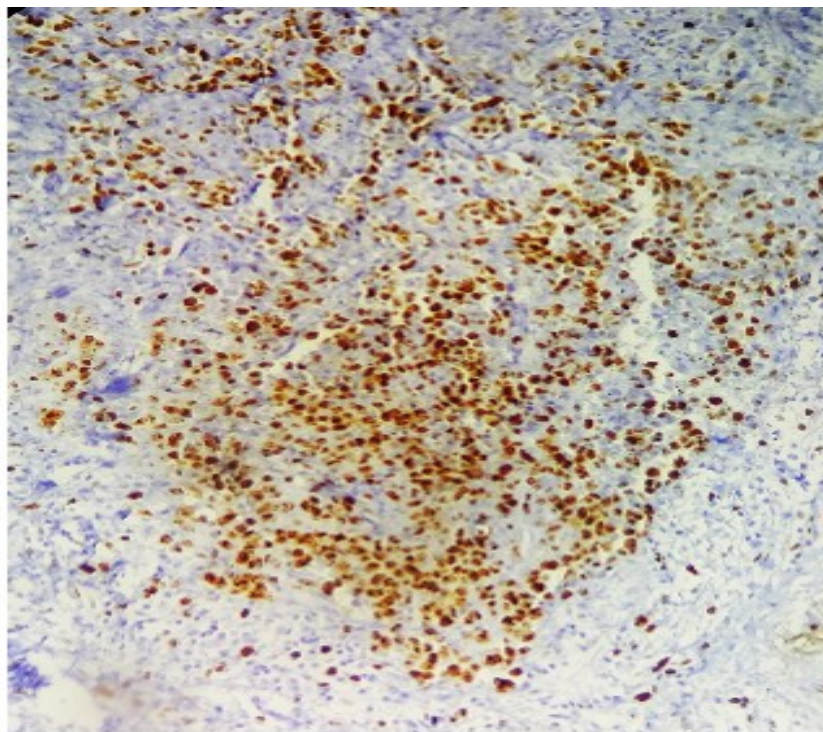
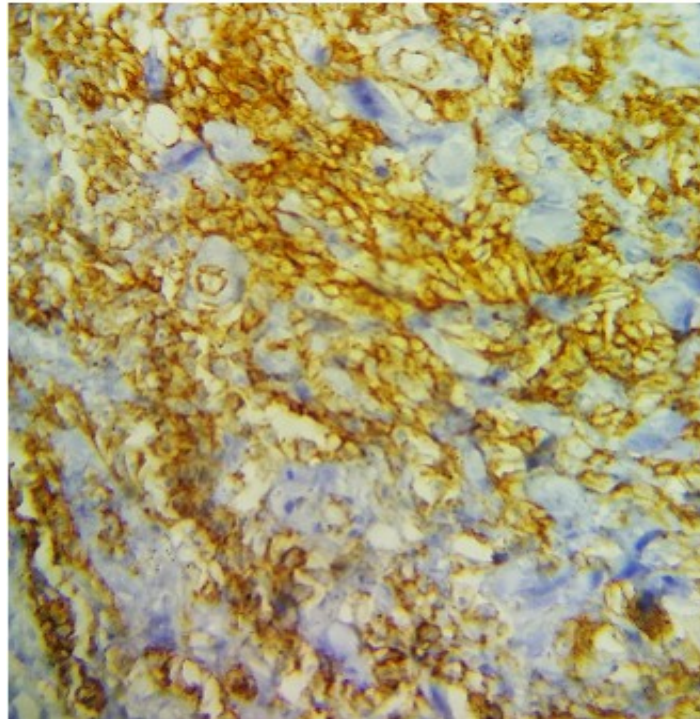


Figure 3:- Positive CD31 staining (A) (B) positive ki-67 staining (C).



References:-

1. Morgan MB, Swann M, Somach S, et al. Cutaneous angiosarcoma: a case series with prognostic correlation. *J Am Acad Dermatol.* 2004;50:867-874

2. Huber MA, Weber L, Kaskel P, Warszawski A, Schmidt R, Peter RU, Krähn G. Cutaneous angiosarcoma afflicting the lower aspect of the left leg in an elderly woman. *Int J Dermatol.* 2000 Jun;39(6):458-60. doi: 10.1046/j.1365-4362.2000.00981-1.x. PMID: 10944093.
3. Cooper H, Farsi M, Dorton D, Miller R. Cutaneous angiosarcoma of the leg. *Dermatol Online J.* 2019 Dec 15;25(12):13030/qt3hq6r0b0. PMID: 32045163.
4. Suchak R, Thway K, Zelger B, Fisher C, Calonje E. Primary cutaneous epithelioid angiosarcoma: a clinicopathologic study of 13 cases of a rare neoplasm occurring outside the setting of conventional angiosarcomas and with predilection for the limbs. *Am J SurgPathol.* 2011 Jan;35(1):60-9. doi: 10.1097/PAS.0b013e3181fee872. Erratum in: *Am J SurgPathol.* 2011 Apr;35(4):619. PMID: 21164288.
5. Linda DD, Harish S, Alowami S, et al. Radiology-pathology conference: cutaneous angiosarcoma of the leg. *Clin Imaging.* 2013;37:602-607.