



Journal Homepage: -[www.journalijar.com](http://www.journalijar.com)

## INTERNATIONAL JOURNAL OF ADVANCED RESEARCH (IJAR)

Article DOI:10.21474/IJAR01/13602  
DOI URL: <http://dx.doi.org/10.21474/IJAR01/13602>



### RESEARCH ARTICLE

#### HEPATIC LYMPHOMA: TWO CASES REPORT

**Mohammed Najih, Mohamed Bouzroud, El Mehdi Aboulfeth, Sidi Mohamed Bouchentouf, Hakim El Kaoui, Montassir Moujahid and Ahmed Bounaim**

Surgery Department (I), Military Hospital, Rabat, Morocco.

Faculty of Medicine, Sidi Mohamed Ben Abdellah University, Fes, Morocco.

#### Manuscript Info

##### Manuscript History

Received: 28 August 2021

Final Accepted: 30 September 2021

Published: October 2021

#### Abstract

**Introduction:** Hepatic lymphoma is defined as primary when there is an attack on the liver without affecting the spleen, the bone marrow or another lymphatic organ. The primary hepatic attack is a very rare variant estimated at 1% of all extra lymphomas.

**Case report:** We report two cases, the first concerning a patient aged 65 years, without pathological history, admitted for chronic abdominal pain associated with a febrile syndrome, the initial diagnosis revealed a liver tumor at the level of segment I. The patient was operated, the pathological examination of an extemporaneous biopsy concluded to a primitive lymphoma of the liver. The patient was referred to oncology for chemotherapy. Her evolution was satisfactory with a 2-year follow-up. The second patient, 50 years old, without notable pathological history, admitted for generalized jaundice, the physical examination reports a palpable mass in the right hypochondrium. The initial diagnosis revealed the presence of a process involving segment I of the liver, an echo endoscopy showed several mesenteric celiomentaladenopathies and a main biliary tract with stenosis, a sphincterotomy was scheduled, an anatomopathological examination with complementary immunohistochemical study showed a diffuse large cell B lymphoma and the patient was referred to the oncology department.

**Discussion:** Lymphomas of the liver is a rare condition. They predominate in middle-aged adults and males. Clinical presentations are diverse. Radiological aspects and biological disturbances are variable. Treatment modalities are variable, combining surgery, chemotherapy and radiotherapy.

**Conclusion:** The diagnosis of lymphomas of the liver is difficult. The therapeutic decision must take into account the extent of the disease, the general condition of the patient. Chemotherapy remains the cornerstone of treatment.

Copy Right, IJAR, 2021., All rights reserved.

**Corresponding Author:- Mohammed Najih**

Address:- Surgery Department (I), Military Hospital, Rabat, Morocco.

**Introduction:-**

Malignant lymphomas are malignant tumors of the lymphatic system that can only affect lymph nodes or other lymphoid organs, but they can also affect other organs such as the brain, stomach, intestine, liver, lungs, salivary glands, skin, or testicles. It is an extra ganglionic lymphomas.

Hepatic lymphoma is a malignant tumor of the lymphatic system and is primary when liver involvement is isolated [1]. It is an exceptional variety estimated at 1% of all extra-nodal lymphomas [2].

Liver lymphomas is unusual and remains misdiagnosed with many nuances about its spontaneous evolution, ideal treatment and its response to treatment.

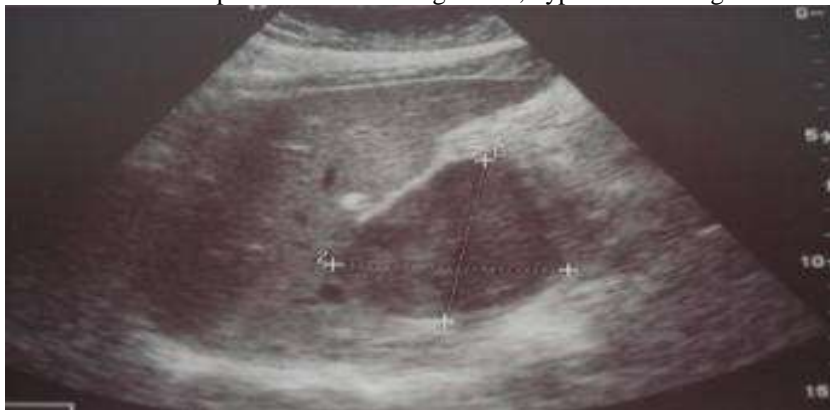In this article we report the observations of two patients managed at the service of visceral surgery of the military hospital of instruction Mohammed V of Rabat, we also report data from the literature concerning the diagnosis and treatment of this rare condition.

**Case 1**

65 year old woman, with no notable pathological history, presented since 4 months a chronic abdominal pain, a fever of 38.5 with alteration of the general state. The clinical examination was unremarkable, notably no hepatomegaly or splenomegaly, and the lymph nodes area were free.

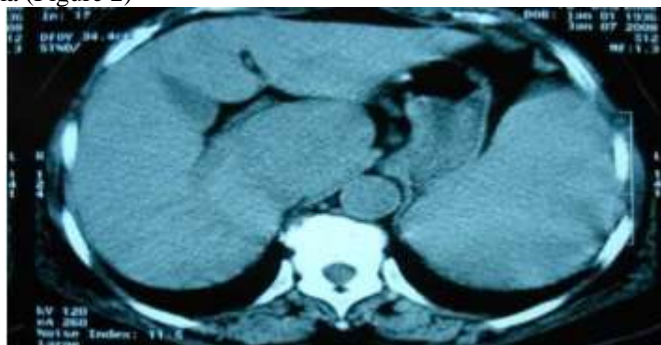
Biological exams showed: normal blood count, normal hepatic assessment, hepatitis serologies are negative and the CRP rate was 60 mg/l.

Abdominal ultrasound revealed a hepatic mass measuring 08 cm, hypoechoic in segment I of the liver.

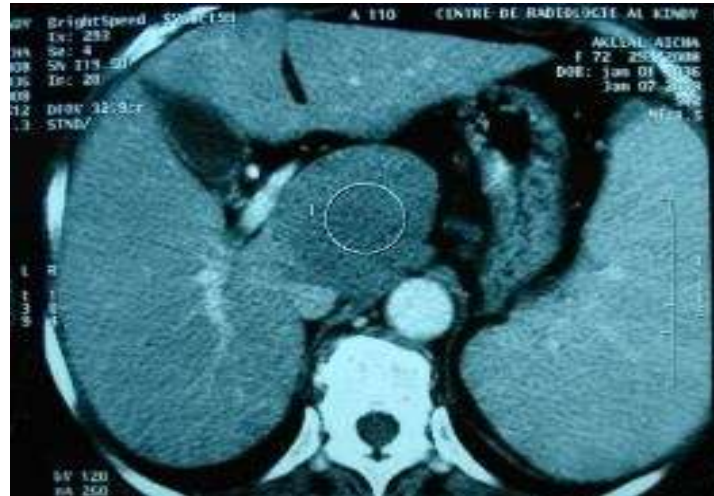

**Figure 1:-** Abdominal ultrasound image showed anhypoechoic mass in the hepatic segment I with regular contours measuring almost 08 cm.

Abdominal CT scan showed a 10cm/07cm segment I liver mass that was mildly hypodense in favor of hepatocellular carcinoma (Figure 2)



**Figure 2:-** Abdominal CT section without contrast injection showing a slightly hypodense mass in front of the hepatic segment I with regular contours.



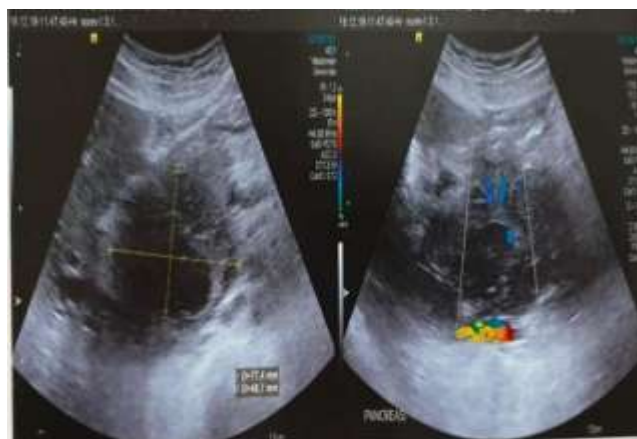
**Figure 3:-** Abdominal CT scan with injection of contrast medium showing anhypodense tumor mass at the expense of the caudate lobe of the liver, with visible and regular contours, taking up some contrast medium.

The diagnosis of hepatocellular carcinoma (in healthy) has been retained and the patient underwent surgery. Intraoperative exploration discovered a well vascularized and encapsulated tumor of segment I of the liver. A biopsy was performed. Anatomopathological examination concluded to a liver primary lymphoma of type B. The patient benefited from chemotherapy with good clinical evolution. The follow-up of 4 years is uneventful.

## Case 2

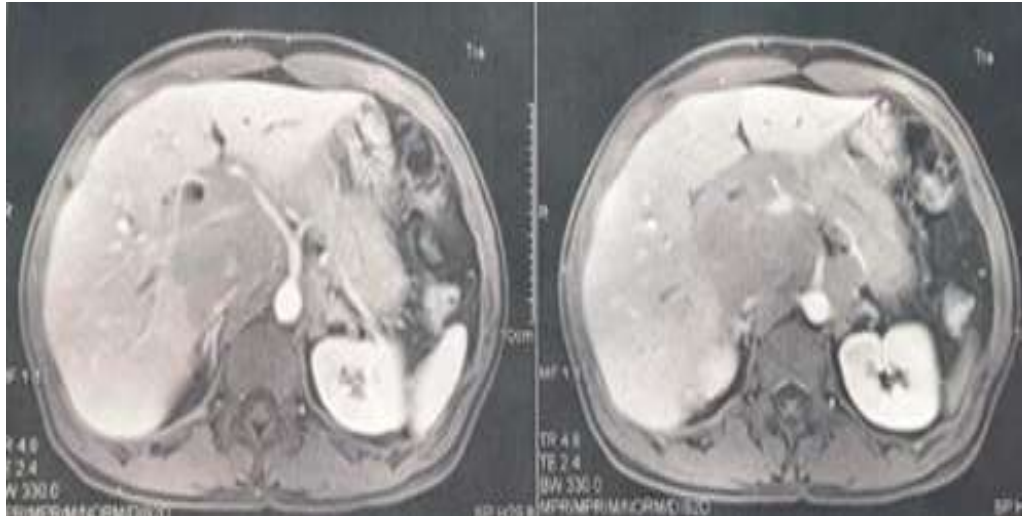
A 50-year-old man with no notable pathological history has been suffering from cholestatic jaundice for the 2 past months and has lost 5 kg of weight. Abdominal examination revealed a palpable painful mass in the right hypochondrium and hepatomegaly with a non-sharp lower border.

Abdominal ultrasound showed a hypoechoic, heterogeneous lesion process of the liver in contact with the head of the pancreas measuring 77x44mm, poorly limited, with poly-lobed contours, vascularized on Doppler with dilatation of the intra- and extra-hepatic bile ducts with several hypoechoic, heterogeneous, peri-lesional nodes (**figure 4**) .



**Figure 4:-** Abdominal ultrasound showing a heterogeneous hypoechoic lesion process of the liver in contact with the head of the pancreas.

Hepatic MRI showed a process involving segment 1 of the liver with the presence of lymph node magma coelio mesenteric and around the hepatic pedicle. Nodes involves the hepatic pedicle with dilatation of the upstream bile ducts. The pancreas is pushed forward (figure 5).



**Figure 5:-** Abdominal MRI showing a process involving segment I of the liver with the presence of lymph node magma and multiple coelio mesenteric and hepatic pedicle adenopathy in favor of a lymphomatous origin.

An echo endoscopy showed the presence of several hypo echogenic nodes in the retro pancreatic area with several coeliac nodes and a stenosis of main biliary tract below the biliary convergence.

Nodes biopsies were taken and a sphincterotomy was performed for the tight stenosis with placement of a plastic biliary prosthesis and another prophylactic pancreatic one.

The morphological appearance and immunohistochemical profile were compatible with a diffuse large cell B lymphoma of the non-germline type.

The patient received chemotherapy and was subsequently lost to follow-up.

### Discussion:-

Primary hepatic non-Hodgkin's lymphomas are very exceptional, they represent 1% of extra nodal lymphomas [3] and constitute 0.016% of all cases of non-Hodgkin's lymphoma [4].

They provided in heterogeneous forms, making their diagnosis complicated [5].

Hepatic lymphomas can be revealed by early functional signs (fever, weight loss and abdominal pain are the most frequent), by a liver mass or hepatomegaly on imaging or physical examination, and in 10% of cases they are discovered by chance [6].

No imaging is typical for the diagnosis of lymphoma in the liver. Most frequently, a single mass (55-60%), multiple masses (35-40%) or more exceptionally a diffuse infiltration is found, which indicates a poor prognosis [7].

PET scan is necessary for the diagnosis of primary hepatic non-Hodgkin's lymphoma by demonstrating FDG uptake at the sites of liver lesions [8].

In the first case, our patient underwent an abdominal ultrasound scan which revealed a hypoechoic mass in segment I of the liver.

The CT scan showed a hypodense mass in front of the hepatic segment I taking the contrast medium after injection. About the 2nd case, our patient had an initial ultrasound exam which showed a hypo echogenic, heterogeneous lesion process of the liver in contact with the head of the pancreas, poorly limited with poly-lobed contours with several hypo echogenic, heterogeneous peri-lesionaladenopathies.

Our patient benefited from a hepatic MRI which showed the presence of a process involving segment I of the liver with the presence of lymph node magma and multiple coelio mesenteric and hepatic pedicle adenopathies in favor of

a lymphomatous origin. Cytolysis or cholestasis is noted in about 70% of cases. LDH is increased in 30-80%. It reflects an increased aggressiveness of the lymphoma [9].

Hypercalcemia is reported in 40% of patients and is the consequence of calcitriol secretion by the tumor [10]. Histological evidence remains essential to make the diagnosis and is obtained by aspiration, ultrasound-guided biopsy (60-70%) or laparoscopy, or Theimmunohistochemical study is essential for the diagnosis of lymphomas of other malignant tumors. Most of the primary hepatic lymphomas resemble diffuse large cell lymphomas, mainly of type B [11].

About the 1<sup>st</sup> case, the anatomopathological study was in favor of a primary hepatic lymphoma of B phenotype. In the second case, the anatomopathological examination showed a ganglion parenchyma completely erased by a lymphomatous proliferation, and the complementary immunohistochemical study showed a strong and diffuse expression of D20 and D10 antibodies, the anti D-3 marked the reactionary T lymphocytes,

Thus, a morphological appearance and immunohistochemical profile were compatible with a diffuse large cell B lymphoma of the non-germline type.

Primary hepatic lymphoma is confused with hepatitis, primary hepatic tumors, hepatic metastases and secondary infiltration of the liver by systemic lymphoma [1].

The treatment cited in the literature combin surgery, chemotherapy, and radiotherapy [8],the surgical indication depends on the tumor size, liver function and general condition of the. However, a localized hepatic lymphoma can be treated by surgical resection. Surgery is also used for the purpose of tumor size reduction before or after chemotherapy.

The medical judgment must take into account the patient's condition, the evolution of the disease and the available therapeutic means.

Polychemotherapy is the basis of treatment. but Surgery can be proposed in nodular and respectable forms, with postoperative chemotherapy aiming to reduce the risk of extrahepatic recurrence.

The place of radiotherapy are limited.

### Conclusion:-

Hepatic lymphoma is an exceptional malignant tumor, frequently misunderstood. The rarity of the pathology leads to many difficulties in diagnosis and management. The adapted treatment is not yet clear and the results are eventual.

The diagnosis of a hepatic lymphoma must be made in front of a hepatic mass, and biologically an increase of LDH with negative tumor in a context of immunodepression. Frequently it is a diffuse large cell lymphoma with a good prognosis than the hepatocellular carcinoma and the secondary hepatic invasion by a lymphoma. With new treatment recommendations such as Rituximab, we can expect better long-term survival results.

### References:-

1. VassiliosSpiridonAvlonitis DL. Primary Hepatic Lymphoma: a Review. Eur J Surg 1999;165:725–9.
2. M. Aitelhaj , S. Lkhouyaali, K. Elbakraoui, H. Mrabti, S. Boutayeb, H. Errihani. Revue de la littérature à propos d'un cas de lymphome hépatique primitif, tumeur exceptionnelle. Cancer/Radiothérapie, Volume 15, Issues 6-7, October 2011, Page 636. Doi : 10.1016/j.canrad.2011.07.213.
3. Freeman C, Berg JW, Cutler SJ. Occurrence and prognosis of extranodal lymphomas. Cancer. 1972 Jan;29(1):252-60.
4. Noronha V, Shafi NQ, Obando JA, Kummar S. Primary non- Hodgkin's lymphoma of the liver. rit Rev OncolHematol 2005;53:199– 207.
5. Atkins CD. A predictive model for non-Hodgkin's lymphoma. N Engl J Med. 1994 Feb 24;330(8):574; author reply 574-5. doi: 10.1056/NEJM199402243300815. PMID: 8302331.
6. Primary Non-Hodgkin's Lymphoma of the Liver: Leukemia& Lymphoma: Vol 29, No 3-4

7. Maher MM, McDermott SR, Fenlon HM, Conroy D, O'Keane JC, Carney DN, Stack JP. Imaging of primary non-Hodgkin's lymphoma of the liver. ClinRadiol. 2001 Apr;56(4):295-301.
8. Noronha V, Shafi NQ, Obando JA, Kummar S. Primary non- Hodgkin's lymphoma of the liver. rit Rev OncolHematol 2005;53:199– 207.
9. Finzi L, Mariette C, Triboulet JP. [Primary lymphoma of the liver]. Ann Chir2001;126:812–3.
10. Appelbaum L, Lederman R, Agid R, Libson E. Hepatic lymphoma: an imaging approach with emphasis on image-guided needle biopsy. Isr Med Assoc J. 2005 Jan;7(1):19-22. PMID: 15658140.
11. Maes M, Depardieu C, Dargent J-L, Hermans M, Verhaeghe J-L, Delabie J, et al. Primary low-grade B-cell lymphoma of MALT-type occurring in the liver: a study of two cases. J Hepatol 1997;27:922–7.