



ISSN NO. 2320-5407

Journal Homepage: -[www.journalijar.com](http://www.journalijar.com)

## INTERNATIONAL JOURNAL OF ADVANCED RESEARCH (IJAR)

Article DOI:10.21474/IJAR01/14047  
DOI URL: <http://dx.doi.org/10.21474/IJAR01/14047>



### RESEARCH ARTICLE

#### SARCOMATOID UROTHELIAL CARCINOMA OF BLADDER - A RARE HISTOLOGICAL VARIANT

**Dr. Ravindra M. Shinde<sup>1</sup>, Dr. Lavi Tyagi<sup>2</sup>, Dr. Isha Mishra<sup>2</sup>, Dr. Sunita B. Patil<sup>1</sup> and Dr. Akshay P. Vadavadi<sup>2</sup>**

1. Associate Professor, Department of Pathology, D. Y. Patil Medical College, Kolhapur.
2. Postgraduate student, Department of Pathology, D. Y. Patil Medical College, Kolhapur.

#### Manuscript Info

##### Manuscript History

Received: 10 November 2021

Final Accepted: 14 December 2021

Published: January 2022

##### Key words:-

Urothelial	Carcinoma	Bladder,
Sarcomatoid	Variant,	Biphasic
Neoplasm		

#### Abstract

**Introduction:** Urothelial carcinoma (UC) is the most common histological type of bladder cancer. Around 75% of bladder cancers are classified as pure UC, and 25% are urothelial and nonurothelial histological variants. Sarcomatoid UC is a rare variant, accounts for 0.1%–0.3% of all urothelial carcinomas of bladder. It is a biphasic malignant neoplasm with morphologic and immunohistochemical evidence of both epithelial and mesenchymal differentiation.

**Objective:** To study the histomorphological and immunohistochemical features of sarcomatoid urothelial carcinoma.

**Methods:** We received TURBT (Trans Urethral Resection of Bladder Tumor) specimen for histopathological evaluation in the department of pathology, DY Patil medical college, Kolhapur. Routine tissue processing of bits was done and H & E stained sections were subjected for detailed microscopic evaluation and various immunohistochemical markers were applied on the paraffin embedded tissue blocks.

**Results:** A 95 years old female patient presented with hematuria and anemia. On cystoscopy polypoidal lesion seen in the lateral wall of urinary bladder. No history of previous surgery on urinary bladder. TURBT done. On gross, there were multiple, irregular, grey white strips of tissue altogether weighing 160gms. On microscopy, neoplasm with papillary architecture was seen invading lamina propria. Chondromyxoid, rhabdoid and malignant fibrohistiocytic tumor like areas noted. Immunohistochemical workup revealed positive staining with cytokeratin, vimentin and GATA3 and negative with H-Caldesmon, SMA and Myogenin.

**Conclusion:** Sarcomatoid UC is seen in elderly. Morphologically, the lesion mimics sarcoma, immunohistochemistry workup aids in definitive diagnosis, as it has poor prognosis compared to pure UC.

Copy Right, IJAR, 2022,. All rights reserved.

#### Introduction:-

Urinary bladder cancer is one of the commonly diagnosed type of cancer.<sup>1</sup> Urothelial carcinoma (UC) is the most common histologic type of bladder cancer. Squamous, glandular, micropapillary, nested, lymphoepithelioma-like, plasmacytoid, and sarcomatoid are some of the histological variants.<sup>2</sup> Around 75% of bladder cancers are classified

**Corresponding Author:- Dr. Sunita B. Patil**

Address:- Associate Professor, Department of Pathology, D. Y. Patil Medical College, Kolhapur.

as pure Urothelial Carcinoma and 25% are nonurothelial and urothelial histological variants.<sup>3</sup> Bladder urothelial carcinoma is a leading source of illness and mortality in the globe, with an estimated 150,000 fatalities each year.<sup>4</sup>

Sarcomatoid UC is a rare variant, accounts for 0.1%–0.3% of all urothelial carcinomas of bladder.<sup>5</sup> It is thought to be an aggressive form of bladder cancer.<sup>6</sup> It is a biphasic malignant neoplasm with morphologic and immunohistochemical evidence of both epithelial and mesenchymal differentiation.<sup>7</sup> On histology, diagnosis can be challenging at times, and immunohistochemistry plays a significant part in determining the diagnosis.<sup>2</sup> it has poor prognosis compared to pure Urothelial Carcinoma.<sup>8</sup>

#### Case Report:

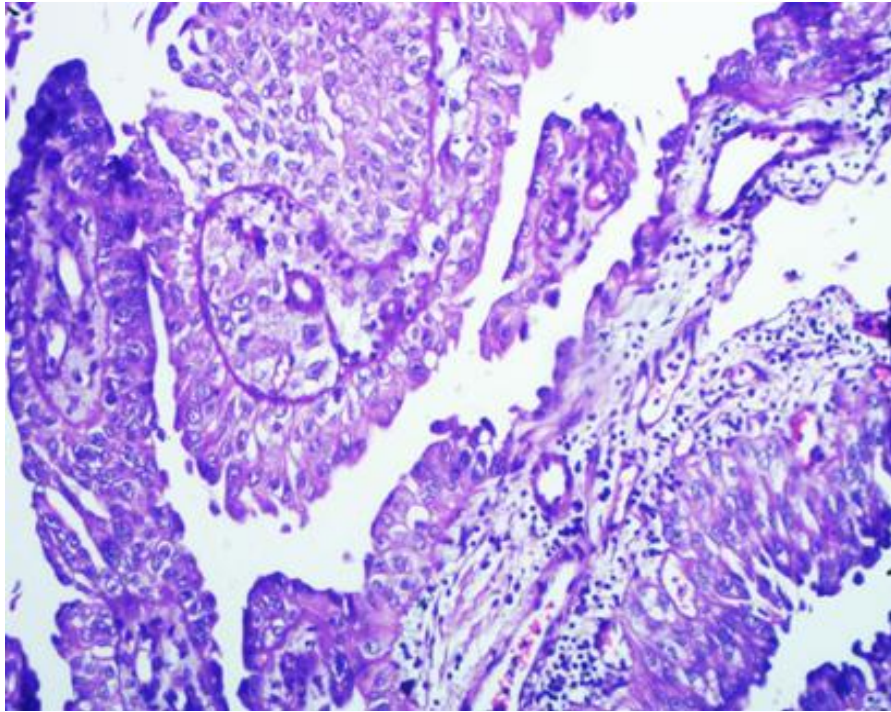
A 95years old female presented with hematuria and anemia. On cystoscopy polypoidal lesion was seen in the lateral wall of urinary bladder. No history of previous surgery on urinary bladder. TURBT(Trans Urethral Resection of Bladder Tumor) done.

TURBT specimen was received in the department of pathology, DY Patil medical college, Kolhapur for histopathological evaluation. On gross, there were multiple, irregular, grey white strips of tissue altogether weighing 160gms (Fig 1). Routine tissue processing of bits was done and H &E stained sections were subjected for detailed microscopic evaluation. On microscopy, neoplasm with papillary architecture was seen invading lamina propria (Fig 2). Chondromyxoid, rhabdoid and malignant fibrohistiocytic tumor like areas were noted (Fig 3&4). Immunohistochemical workup revealed positivestaining with cytokeratin, vimentin and GATA3 (Positive IHC panel Fig 5-7) and negative with H-Caldesmon, SMA and Myogenin.

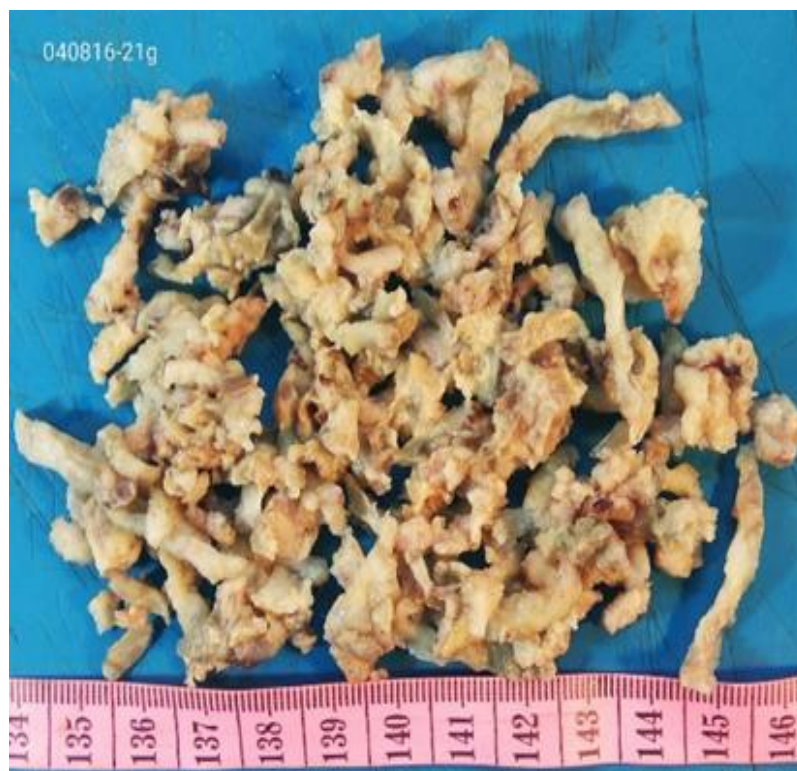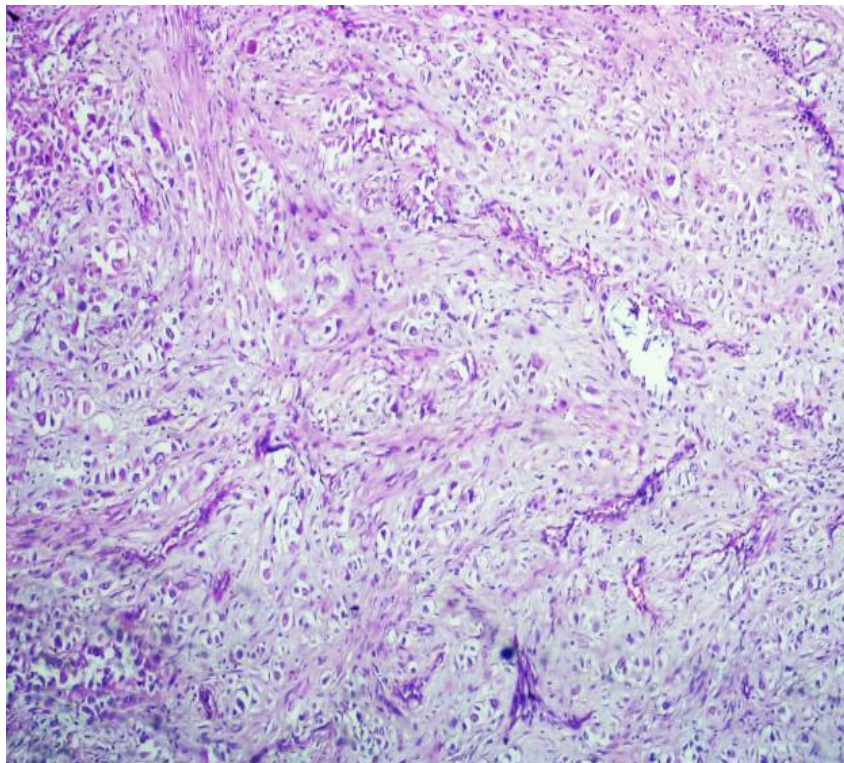


Figure 1:- TURBT bits.



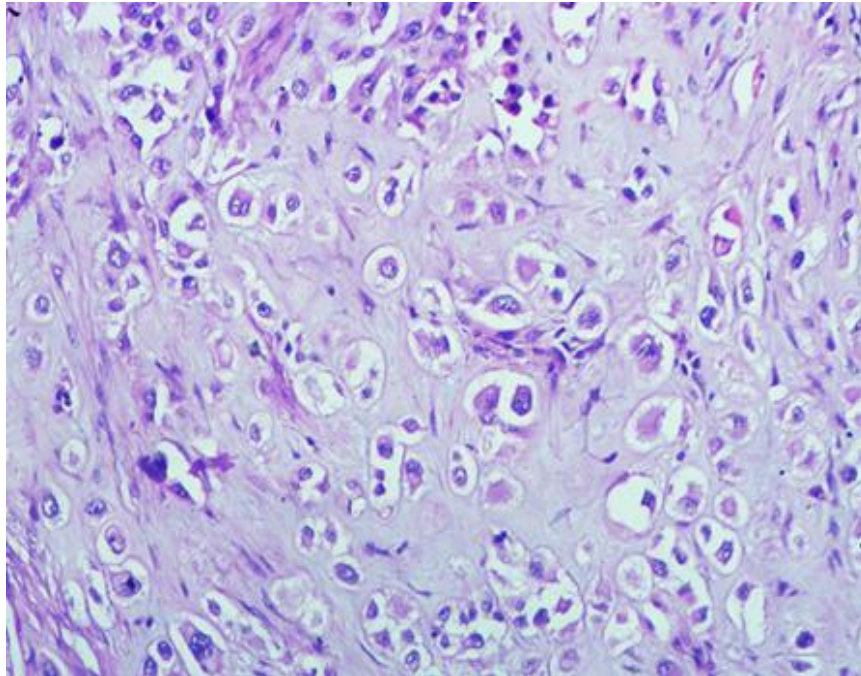


**Figure 2:-** Papillary pattern, H&E.

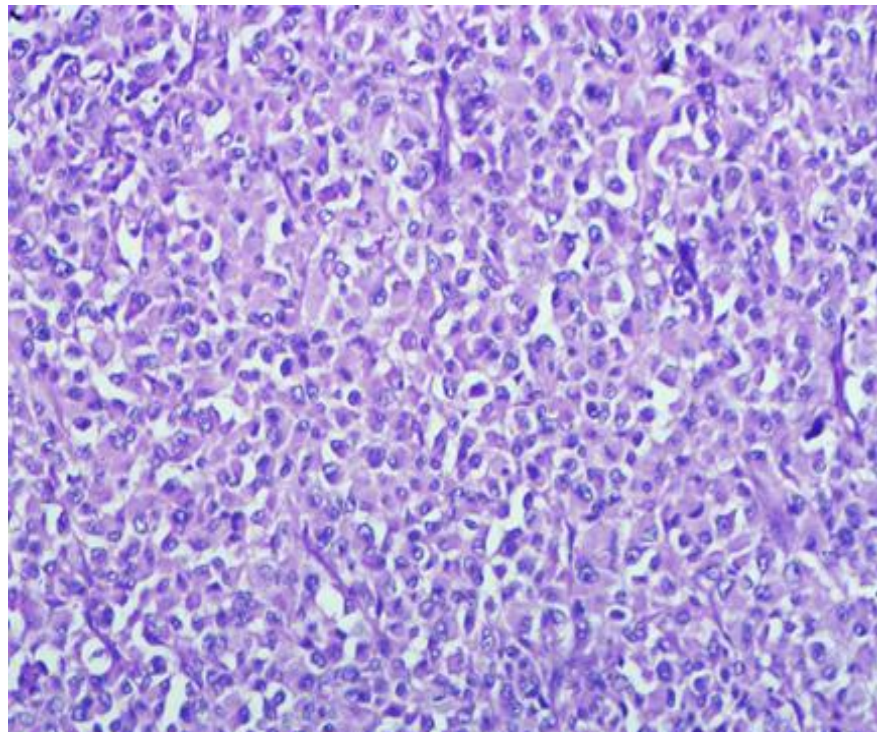


**Figure 3:-** Chondromyxoid areas, H&E.

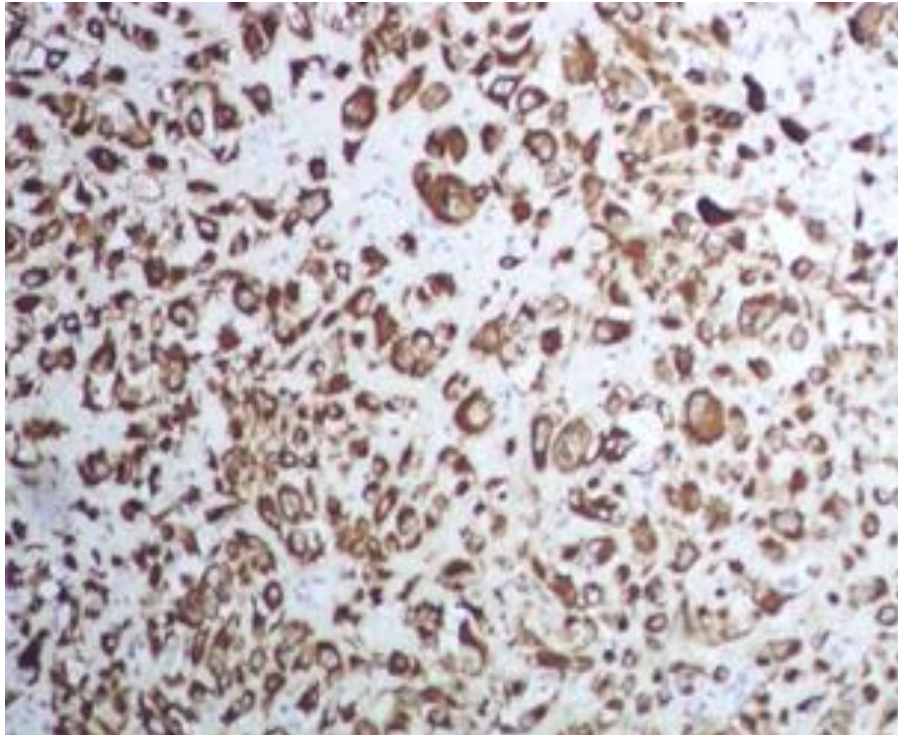




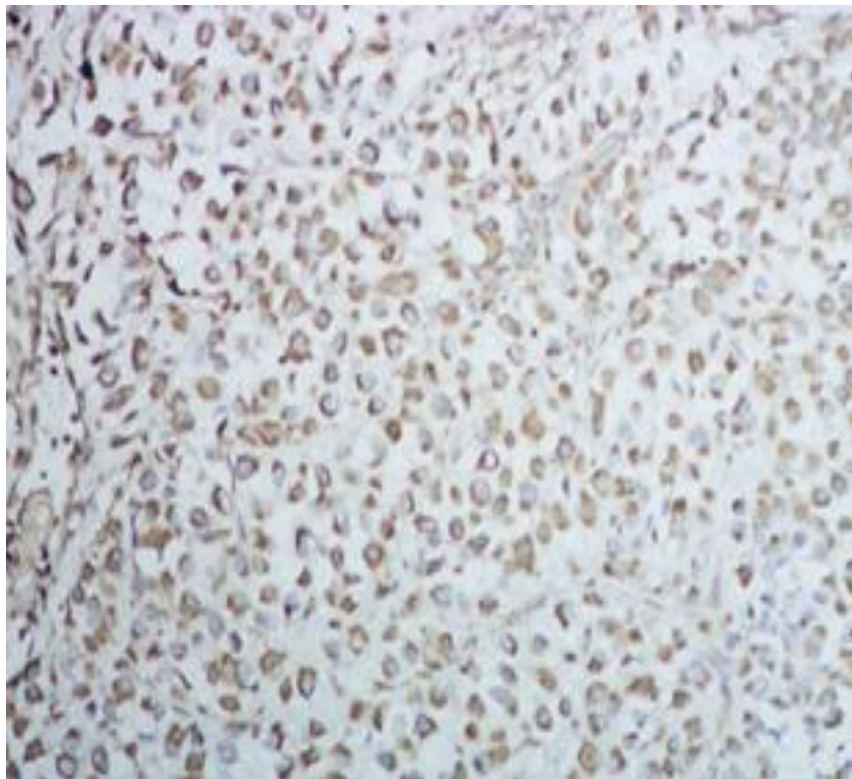
**Figure 4:-** Chondrosarcomatous areas, H&E.



**Figure 5:-** Rhabdoid areas, H&E.

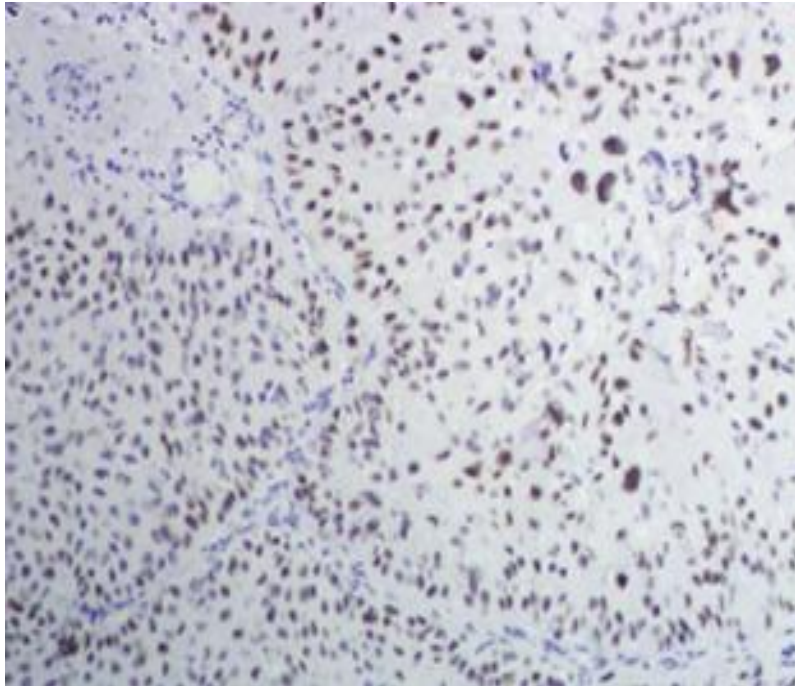


**Figure 6:-** Cytokeratin, IHC.



**Figure 7:-** Vimentin, IHC.





**Figure 8:-** GATA 3, IHC.

### **Discussion:-**

Carcinosarcomas and sarcomatoid carcinomas were considered distinct entities. However, Urologic Pathologists now agree that the term "sarcomatoid carcinoma" should be used for all biphasic malignant neoplasms of the bladder.<sup>7</sup> The exact histogenesis of the tumor is still unknown, though it is postulated to represent either multiclonal collision tumors or monoclonal cancers with divergent differentiation.<sup>9</sup>

Urothelial carcinoma (formerly known as transitional cell carcinoma or "TCC") accounts for over 90% of all primary bladder cancers.<sup>10</sup> Micropapillary, squamous differentiation, glandular differentiation, sarcomatoid differentiation, inverted or nested pattern are some of the recognised histological types. Sarcomatoid differentiation is rather uncommon.<sup>2</sup> Sarcomatoid UC is a malignant spindle cell tumour, immunohistochemical tests or ultrastructural studies are sometimes required to recognize epithelial differentiation.<sup>8</sup>

Sarcomatoid urothelial carcinoma of the urinary bladder primarily affects the elderly.<sup>7</sup> It often manifests with a median age of 66 years, and is more frequent in males, with male:female sex ratio of 3:1.<sup>11</sup> In contrast our case was female with older age (95yrs). In industrial areas, bladder cancers are more prevalent.<sup>10</sup> Tobacco use, prior urothelial carcinoma, recurrent cystitis, diabetes, neurogenic bladder, and bladder diverticulum are all common risk factors.<sup>7</sup> The exact cause is unknown, however it has been linked to radiation and cyclophosphamide exposure.<sup>8,12,13</sup> In our case none of the above mentioned risk factors were associated with UC. It is frequently identified at an advanced stage because of its aggressive nature.<sup>13</sup>

The sarcomatoid variety of urothelial cancer appears as a big polypoidal intraluminal mass grossly.<sup>14</sup> In our case also, it was a polypoidal mass. Histologically, the tumor may have a combination of carcinomatous and sarcomatoid components in variable proportions, but the sarcomatoid component always forms a major part of the tumor. Transitional cell carcinoma, squamous cell carcinoma, carcinoma in situ, small cell carcinoma, and adenocarcinoma are all epithelial cancers. There might be several types of heterologous differentiation present, leiomyosarcoma, chondrosarcoma, rhabdomyosarcoma, and, in rare cases, liposarcoma.<sup>15</sup>

Sarcomatoid Urothelial Carcinoma is frequently confused with other mesenchymal tumors like leiomyosarcoma and osteosarcoma. IHC helps in diagnosis with confirmation of both epithelial and mesenchymal differentiation. Also there is need for differentiate it from Inflammatory myofibroblastic tumor (IMT) as it can show positivity to

pancytokeratin.<sup>16</sup> IHC markers such as vimentin, cytokeratin, epithelial membrane antigen, and/or smooth muscle antigen are used to confirm the diagnosis.<sup>13</sup>

Sarcomatoid urothelial carcinoma is a high-grade cancer with an advanced starting stage and a poor outcomes.<sup>7</sup> In sarcomatoid variations, the histopathological stage is the largest predictor of survival. The definitive treatment modality has not been reported due to the small number of cases available; however, radical cystectomy with adjuvant chemotherapy and radiation is the preferred treatment.<sup>14</sup> Negative surgical margins and the lack of metastatic disease at the time of presentation are both good prognostic markers.<sup>8</sup> The prognosis is poorer than that of high-grade urothelial carcinoma.<sup>11</sup>

### Conclusion:-

Sarcomatoid Urothelial Carcinoma is seen in elderly population and it is an aggressive neoplasm. Morphologically, the lesion mimics sarcoma. Immunohistochemistry helps in diagnosis with confirmation of both epithelial and mesenchymal differentiation.

### Bibliography:-

1. Uemura K, Kawahara T, Ishida H, Nakaigawa N, Tanabe M, Yao M, Uemura H. Sarcomatoid Variant of Bladder Carcinoma: A Case Report. *Case reports in oncology*. 2018;11(3):633-7.
2. Mallik AU, Rahman MZ, Sarker MMR. Sarcomatoid carcinoma of urinary bladder—a case report. *Banglajol*. 2010;4(1):28–29. [Google Scholar] [Ref list]
3. Processali T, Diminutto A, Cerruto M, Antonelli A. The impact of histological variants on bladder cancer outcomes. *AME Medical Journal*. 2020;5:4-4.
4. Cancer Genome Atlas Research Network. Comprehensive molecular characterization of urothelial bladder carcinoma. *Nature*. 2014 Mar 20;507(7492):315.
5. Cheng L, Zhang S, Alexander R, MacLennan G, Hodges K, Harrison B et al. Sarcomatoid Carcinoma of the Urinary Bladder. *American Journal of Surgical Pathology*. 2011;35(5):e34-e46.
6. Sanfrancesco J, McKenney JK, Leivo MZ, Gupta S, Elson P, Hansel DE. Sarcomatoid urothelial carcinoma of the bladder: analysis of 28 cases with emphasis on clinicopathologic features and markers of epithelial-to-mesenchymal transition. *Archives of pathology & laboratory medicine*. 2016 Jun;140(6):543-51.
7. Fatima N, Canter DJ, Carthon BC, Kucuk O, Master VA, Nieh PT, Ogan K, Osunkoya AO. Sarcomatoid urothelial carcinoma of the bladder: a contemporary clinicopathologic analysis of 37 cases. *Can J Urol*. 2015 Jun 1;22(3):7783-7.
8. Bansal A, Kumar N, Sharma SC. Sarcomatoid variant of urothelial carcinoma of the urinary bladder. *Journal of cancer research and therapeutics*. 2013 Oct 1;9(4):571.
9. Sung M, Wang M, MacLennan G, Eble J, Tan P, Lopez-Beltran A et al. Histogenesis of sarcomatoid urothelial carcinoma of the urinary bladder: evidence for a common clonal origin with divergent differentiation. *The Journal of Pathology*. 2007;211(4):420-4
10. Rosai and Ackerman's Surgical Pathology - 2 Volume Set, 11th Edition
11. Wang J, Gillaspie C, Kunadharaju R, Talmon GA, Enke C. Sarcomatoid urothelial carcinoma: a single cancer center experience. *World Journal of Oncology*. 2011 Aug;2(4):175.
12. Daga G, Kerkar P. Sarcomatoid carcinoma of urinary bladder: A case report. *Indian journal of surgical oncology*. 2018 Dec;9(4):644-6.
13. Sanchez JEH, Figueira YR, Gonzalez RT, Lopez RM, Tejeda LMG. Sarcomatoid carcinoma of the urinary bladder: a case report and review of the literature. *J Med Cases*.
14. Shanthi V, Rao SS, Grandhi B, Vaddi S, Ethamakula T. Sarcomatoid Urothelial Carcinoma of Urinary Bladder—A Rare Case Report.
15. Kadouri Y, Ouskri S, El Sayegh H, Benslimane L, Nouini Y. Sarcomatoid carcinoma of the urinary bladder: analysis of five cases and literature review. *The Pan African Medical Journal*. 2020;36.
16. Dabbs D., 2019. Diagnostic Immunohistochemistry. 5th ed. London: Elsevier Health Sciences, p.633.