



Journal Homepage: -[www.journalijar.com](http://www.journalijar.com)

## INTERNATIONAL JOURNAL OF ADVANCED RESEARCH (IJAR)

Article DOI:10.21474/IJAR01/10939

DOI URL: <http://dx.doi.org/10.21474/IJAR01/10939>



### RESEARCH ARTICLE

#### A CASE REPORT OF PERINEAL AND VAGINAL LEIOMYOMA: AN EXCEPTIONAL ENTITY

Sounni A., Belachkar L., Jayi S., Fdili Alaoui FZ, Chaara H. and Melhouf My A

Department of Gynaecology and Obstetrics II, CHU HASSAN II Fez.

#### Manuscript Info

##### Manuscript History

Received: 10 March 2020

Final Accepted: 12 April 2020

Published: May 2020

##### Key words:-

Leiomyoma, Vagina, Perineum, Surgery

#### Abstract

Leiomyoma, known as a pathology of the uterus, made of fusocellular smooth muscle fiber and collagen stroma, is rarely found on other sites. We report here an unusual case of an extrauterine location: the vaginal and perineal level, we also discuss its diagnostic and therapeutic management.

Copy Right, IJAR, 2020.. All rights reserved.

#### Introduction:-

The uterine leiomyoma is a very frequent and well-known pathological entity, the extra uterine location remains rare and presents several diagnostic, therapeutic, as well as prognostic problems.

We report a rare case of a large tumour, developed at the perineal and vaginal level, extended over the entire left lateral side of the vagina and protruding in the left labia majora, in addition, we try to discuss the management problems of this type of tumour.

#### Observation:-

A 40-year-old female patient, grand multipara with an unremarkable medical history, she had antecedents of laborious deliveries such as the use of vacuum extractor and episiotomy, still gets her menstruations and consulted for a perineal tumefaction.

The physical examination showed at the inspection, a round formation at the perineal level, as well as the existence of a well limited and solid formation—measuring 12 cm in its long axis—regarding the tubarischadicum at the palpation. The pelvic ultrasound was normal, but the soft tissue ultrasonography couldn't characterize the mass; hence the decision to complete by a pelvic MRI.

The Pelvic MRI results revealed an ovarian vulvar tumor process having a left posterolateral development, measuring 6-10cm, and invading the posterior wall of the vagina, the anal margin and the left ischioanal fossa (equivalent to the T4 stage of the FIGO classification). It was accordingly decided to perform a resection and enucleation of the two vaginal tumors, in cooperation with general surgeons, whose perioperative exploration objectified a well-encapsulated cystic formation, measuring 10cm and located at the perineal level next to the tubarischadicum.

The histopathological examination of the two surgical excisions revealed a gynecological leiomyoma.

#### Discussion:-

Leiomyomas are solid tumors made of fusocellular smooth muscle fibers and collagen stroma [1], and are developed at the expense of the myometrium.

**Corresponding Author:- Sounni A**

Address:- Department of Gynaecology and Obstetrics II, CHU HASSAN II Fez.

Vulvovaginal localization is very rare. In the literature, the number of described leiomyomas doesn't exceed 120 cases for vulvar location and 300 cases for vaginal location [3,4]. While no vulvovaginal location is reported, vulvovaginal leiomyoma is usually developed after puberty and appears as a single, well-circumscribed and slow-growing tumor, rarely exceeding 5 cm. The clinical presentations are variable, depending on the size and location of the tumor. The principal revealing symptoms are gravity, dyspareunia, vaginal bleeding and signs of urinary and digestive compression (dysuria and constipation). The coincidental diagnosis of the tumor during an examination of another system is also possible [3, 5, 6], and the preoperative diagnosis remains difficult.

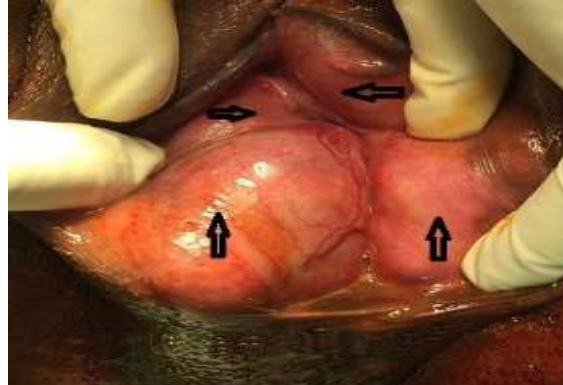
The pelvic CT allows us to characterize a well circumscribed hypodense lesion having a heterogeneous and hyperdense rolling up without any specific signs. The MRI can lead to the diagnosis of leiomyoma by revealing a lesion characterized by a T1 intermediate signal or a hypointense signal and a T2-hypointense signal, which can be reversed by the injection of gadolinium [2, 5, 6]. The diagnosis is established by a histopathological examination and an immunohistochemical study revealing a tumor made of fusiform cells, identified as smooth muscle fibers by highlighting antidesmin and antiactin antibodies as in our case [2, 4].

Monobloc surgical excision remains the only treatment for vulvovaginal leiomyoma. The tumor is usually treated—as in our case—by a perineal approach with an incision next to the tumor and a progressive enucleation [3, 6].

Owing to the rarity of cases described in the literature, there are difficulties in reliably predicting the risk of recurrence and differentiating between benign and malignant tumors; hence the need for long-term follow-up [5].

### Conclusion:-

The vaginal leiomyoma is a benign tumor, very rare compared to the uterine location, frequently asymptomatic, and accidentally diagnosed during a physical examination (it appears as a firm and painless nodule). Imaging allows us to affirm the vaginal origin of the lesion. A surgical excision is indicated due to the possible sarcomatous degenerations. Finally, the diagnosis is established by the histopathological study of the excision.



**Figure 1:-** Vulvar leiomyoma.

### Bibliography:-

1. A. El Khader · M. Lahkim · R. El Barni · A. Achour .Le léiomyome vaginale : une entité exceptionnelle, LAVOISIER SAS 2015-page 1-2.
2. A. Roue, C. Laboisie, N. Winer, E. Darnis, R. Bouquin, P. Lopes. Léiomyome pelvien extra-utérins: diagnostic et prise en charge. Journal de Gynécologie Obstétrique et Biologie de la Reproduction. 37 (2007) 403-408.
3. E. Hissane, H. Fasla, S. Mahdaoui, M. Noun, S. Hermas, N. Samouh. Léiomyome de la vulve : à propos d'un cas et revue de la littérature. Imagerie de la Femme (2011) 21, 179-183.
4. Young SB, Rose PG, Reuter KL. Vaginal fibromyomata: Two cases with preoperative assessment, resection and reconstruction. Obstet Gynecol 1991; 78: 972-4.
5. Shimada K, Ohashi I, Shibuya H, Tanabe F, Akashi T. MR imaging of an Atypical Vaginal Leiomyoma. AJR 2002; 178: 752-4.
6. Elsays KM, Narra VR, Dillman JR, et al. Vaginal Masses: Magnetic Resonance Imaging Features with Pathologic Correlation. Acta Radiol 2007; 8: 921-33.