



Journal Homepage: - [www.journalijar.com](http://www.journalijar.com)

## INTERNATIONAL JOURNAL OF ADVANCED RESEARCH (IJAR)

Article DOI: 10.21474/IJAR01/15625

DOI URL: <http://dx.doi.org/10.21474/IJAR01/15625>



### RESEARCH ARTICLE

#### MECKEL GRUBER SYNDROME- A RARE CASE REPORT

Chinthala Shireesha<sup>1</sup> and A. Manasa<sup>2</sup>

1. Department of Obstetrics and Gynaecology.
2. Kurnool Medical College, Kurnool.

#### Manuscript Info

##### Manuscript History

Received: 31 August 2022

Final Accepted: 30 September 2022

Published: October 2022

#### Abstract

Meckel Gruber Syndrome is a rare and lethal autosomal recessive congenital anomaly syndrome, characterized by a triad of : occipital encephalocele Postaxial polydactyly, bilateral dysplastic cystic kidneys and other occasional features. Diagnosis can be made on ultrasonography with atleast two of the major features. Here we present a pregnant women complicated with meckel gruber syndrome. We relayed on ultrasonography findings and MRI ,pregnancy was terminated at 22weeks of gestational age. Ultrasonography, MRI and clinical examination of bady after termination suggestive of Meckel Gruber Syndrome.

Copy Right, IJAR, 2022,. All rights reserved.

#### Introduction:-

Meckel Gruber Syndrome is a lethal autosomal recessive disorder.

Characterized by triad of Occipital encephalocele, polycystic kidneys and postaxial polydactyly.

Meckel Gruber Syndrome is a multisystemic disorder associated with a mutation affecting ciliogenesis cause dysfunction of cilia and flagella.

#### Case Report:

A 21 year old primigravida with 22weeks of gestational age came for antenatal checkup.

There was no history of consanguineous marriage. Past and family history were insignificant. She was neither exposed to radiation nor on any teratogenic drugs. Routine antenatal scan was done to role anomalies.

Ultrasonography suggestive features were amniotic fluid index less than 2cm, microcephaly, bilateral dysplastic multicystic kidneys (figure 1), hexadactyly, occipital encephalocele. MRI was done suggestive of occipital encephalocele (figure 2), bilateral multicystic kidneys (figure 3), polydactyly.

Termination of pregnancy was undertaken. The aborted fetus on examination weighted 1 kilogram, with

Microcephaly with encephalocele (figure 4) measuring 3cm\*2.5cm\*2cm, polydactyly (figure 5) of both upper limbs,

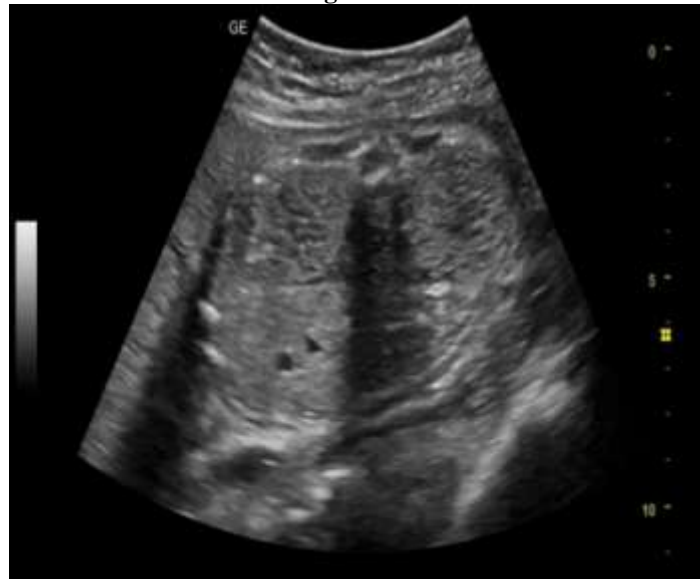
Distended abdomen, normal spine, ears, nose, genetalia, bilateral lower limbs had talipas equinovarus.

**Corresponding Author:- Chinthala Shireesha**

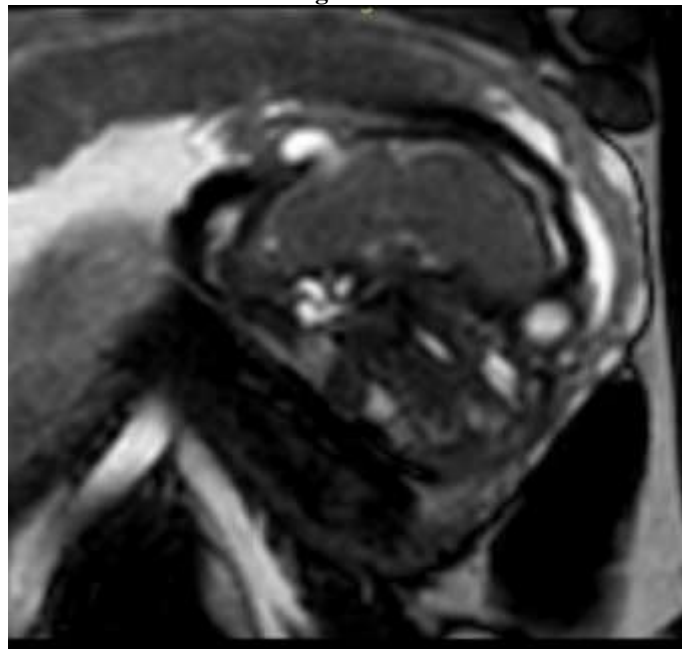
Address:- Department of Obstetrics and Gynaecology.

All the above feature confirmed the diagnosis of Meckel Gruber Syndrome.

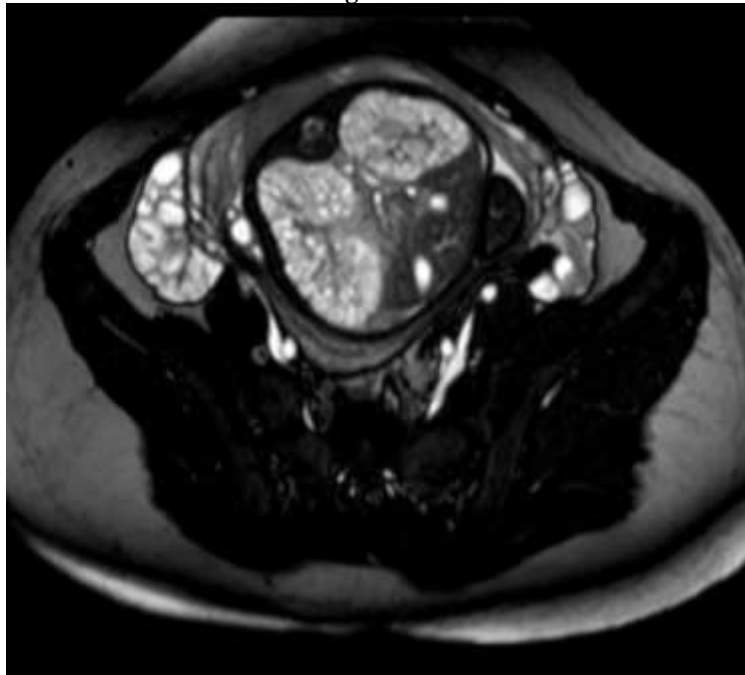
**Figure 1:-**



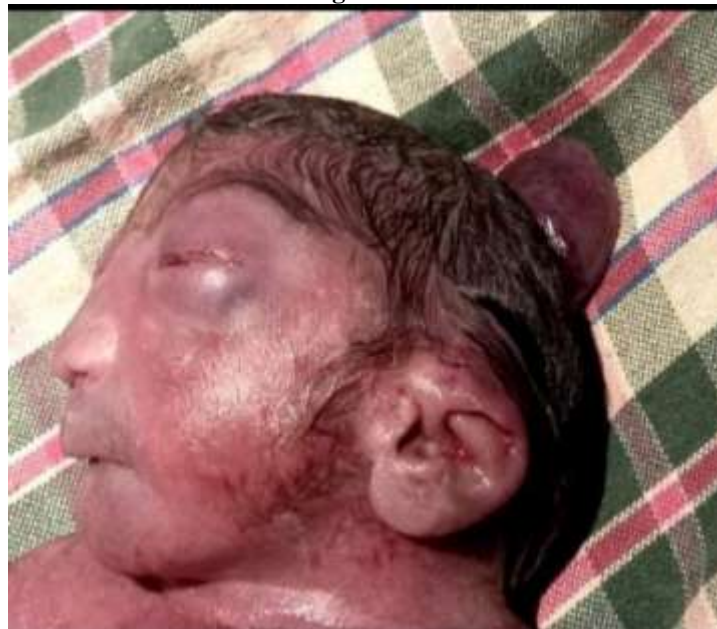**Figure 2:-**



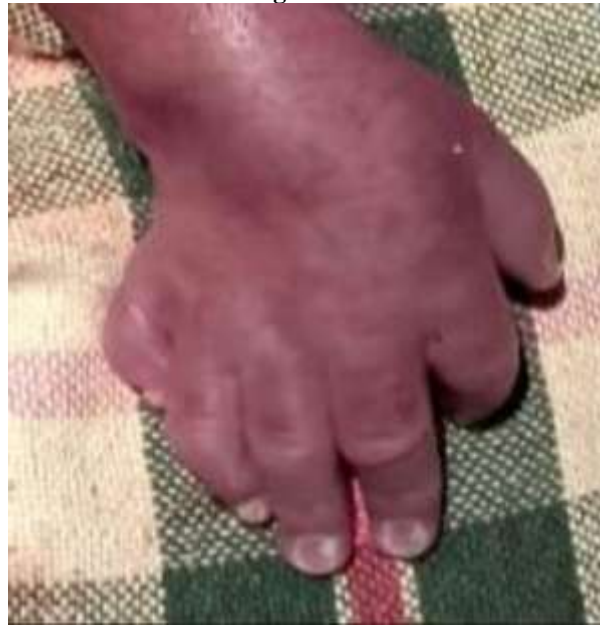**Figure 3:-**



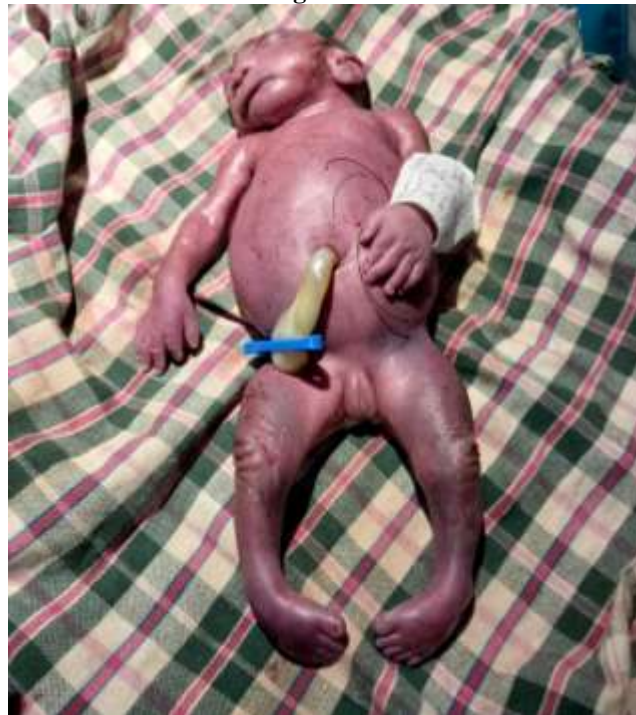**Figure 4:-**



**Figure 5:-**



**Figure 6:-**



**Discussion:-**

Meckel Gruber Syndrome is a rare autosomal recessive, multisystemic congenital anomaly, Associated with mutation in ciliogenesis, other ciliopathies are polycystic liver disease, polycystic kidney disease,

Joubert syndrome, Bardet-Biedl Syndrome, Alstrom Syndrome.

Meckel Gruber Syndrome was first described by Johann Friedrich Meckel in 1822.

In 1969, Opitz and Howe proposed the name "Meckel Syndrome".

Thypical triad having occipital encephalocele, polydactyly, bilateral dysplastic multicystic kidneys but however it is associated with other occasional features such as abnormalities of genitalia, anencephaly, cleft lip and cleft palate, congenital heart disease, CNS abnormalities, bowing and shortening of long bones , cystic dysplasia, retinal colobomata.

**Conclusion:-**

Meckel Gruber Syndrome is a condition ,which can be diagnosed on ultrasonography, Counselling is an integral part of management about the risk of recurrence in subsequent pregnancy. Aim is to spread awareness about these rare and lithal condition.