



Journal Homepage: - www.journalijar.com

INTERNATIONAL JOURNAL OF ADVANCED RESEARCH (IJAR)

Article DOI: 10.21474/IJAR01/15745

DOI URL: <http://dx.doi.org/10.21474/IJAR01/15745>



RESEARCH ARTICLE

MACULAR EDEMA AS UNUSUAL PRESENTATION OF NON-ARTERITIC ISCHEMIC OPTIC NEUROPATHY (NAION)

P. Mahitha, B.V. Kranti and K. Nikitha

Department of Ophthalmology, Santhiram Medical College, Nandyal.

Manuscript Info

Manuscript History

Received: 25 September 2022

Final Accepted: 27 October 2022

Published: November 2022

Key words:-

Non-Arteritic Ischemic Optic Neuropathy, Macular Edema, Subretinal Fluid

Abstract

Introduction: Non-arteritic Ischemic Optic Neuropathy is the most common type of ischemic optic neuropathy. Nearly half of NAION patients presented with 20/30 or better visual acuity. Central vision is often preserved relative to the visual field loss. Macular edema in NAION patient is rare, and its occurrence may confuse to other disease and lead to unnecessary treatment.

Case Report: We identified a NAION patient presented with macular edema. The patient age was above 40 and had diabetes mellitus (DM). He had clinical findings consistent with NAION with poor visual acuity at the early presentation. Optical coherence tomography examination was performed, and the patient had prominent subretinal fluid. Intravitreal antiVEGF injection was done on our patient and he showed a significant improvement of macular edema.

Discussion: Macular edema is a rare clinical manifestation that may contribute a visual deterioration in NAION. The incidence of macular edema in NAION patients is difficult to measure since OCT of macula is not routinely performed. In our report, we encountered a case of NAION complicated by macular edema that underwent a different approach in therapy. Spontaneous regression of subretinal fluid was seen during observation without any treatment given. Our patient achieved a stable visual acuity and visual field defect. This finding is under the literature that spontaneous recovery will be observed during the natural course of acute NAION.

Conclusion: Macular edema is an unusual but self-limiting presentation of NAION. Therefore, a comprehensive examination is needed to prevent any unnecessary treatment.

Copy Right, IJAR, 2022., All rights reserved.

Introduction:-

Non-arteritic ischemic optic neuropathy (NAION) is a part of ischemic optic neuropathies that causes sudden painless monocular loss of vision. It is caused by ischemia of the optic disc due to vascular insufficiency. Typically, NAION occur in older patients, around fourth and fifth decades. The progression of the disease starts with optic disc edema which followed by optic atrophy in over 2-3 months with variable levels of visual field loss.¹ Risk of contralateral involvement is 15% in 5 years.² Structural crowding of the optic nerve head, DM, systemic hypertension, hyperlipidemia, sleep apnea are thought to be the common risk factors of NAION.

Corresponding Author:- P. Mahitha

Address:- Department of Ophthalmology, Santhiram Medical College, Nandyal.

Diagnosis of NAION can be made by history taking and careful examinations. The patients will notice a sudden vision loss upon awakening which may be explained by nocturnal hypotension theory. Vision loss is variable, but typically visual acuity noted to be 20/30 or better in 49% patients.³

We presented a NAION patient on acute phase with poor visual acuity at his first admission, we performed OCT and detected a significant macular edema that may explain its initial visual acuity. Macular edema is an unusual presentation of NAION. One recent study of macular evaluation in acute NAION showed some evidence that subretinal fluid may develop in 10% NAION patients.⁴ Subretinal fluid is best detected by OCT, even though it is currently not performed routinely in NAION cases. This phenomenon is considered rare and also have not received enough clinical attention. The finding of macular edema in NAION cases is also a challenge for ophthalmologists to be able to distinguish it with other diseases, and vice versa, which may relate to the following management.

Comprehensive history taking and examinations are required to obtain the correct diagnosis which may help us to decide which treatment is needed for each case. We have to be able to differentiate which macular edema that requires therapy or not, considering that this treatment may worsen the ischemic condition of NAION. The aim of this study is to improve knowledge that macular edema can occur in NAION cases, therefore it is important to know how to identify, diagnose, and choose the best Treatment.

Case Report

Case

A 50-year old man was referred to our vitreo-retina outpatient clinic on December 7th, 2021, with a chief complaint of blurry vision of his left eye since ten days ago. He also complained of metamorphopsia. There was no photopsia or floaters. There was no redness or pain, no history of trauma, surgery, or wearing eyeglasses. He had DM four years ago but did not consume any medications.

On the physical examination, patient had a high blood pressure (167/70). The best-corrected visual acuity of his right eye was 6/6, and his left eye was 0.5/60. The position of his eye was orthophoria, with normal intraocular pressure of both eyes. There were no abnormalities found on anterior segments, and the lens was slightly hazy on both eyes. Light reflex was positive, and RAPD was positive. The posterior segment of his left eye showed a diminished macular reflex. The optic nerve head of his left eye tends to be a bit blurry at the temporal edge, with cup-to-disc ratio was hard to be evaluated. There were no dot/blot hemorrhage, microaneurysms, exudates seen on his left eye. Posterior segment examination of his right eye was within normal limit. This patient has performed Optical Coherence Tomography (OCT)

Macula and found macular edema of his left eye, with the central macular thickness (CMT) of 421. His right eye was within the normal limit. He was diagnosed with macular edema of his left eye with edematous optic nerve head of his left eye suspicious of NAION and planned to give intravitreal anti-VEGF injections on the left eye and consult to neuro-ophthalmology division.

Due to administration problem with his national health insurance, intravitreal anti-VEGF injection was postponed and finally done on January 27th, 2021. Patient was given antibiotic eyedrop levofloxacin every 3 hours post injection. Patient then controlled 1 month later. He still complained blurry vision of his left eye, especially at his nasal side. His visual acuity was still the same with normal intraocular pressure of both eyes. Anterior segment examination was also at the same condition as before injection. RAPD examination was still positive. Posterior segment of his left eye showed a markedly pale optic nerve head with blurry edge, with cup-to-disc ratio was hard to be evaluated. Perimacular exudates noted on his left eye. On his right eye, the cup-to-disc ratio of his optic nerve head was 0.1-0.2. We repeated the OCT macula examination, and the result showed a significant improvement of CMT of his left eye from 421 to 203. (Fig. 1,2)

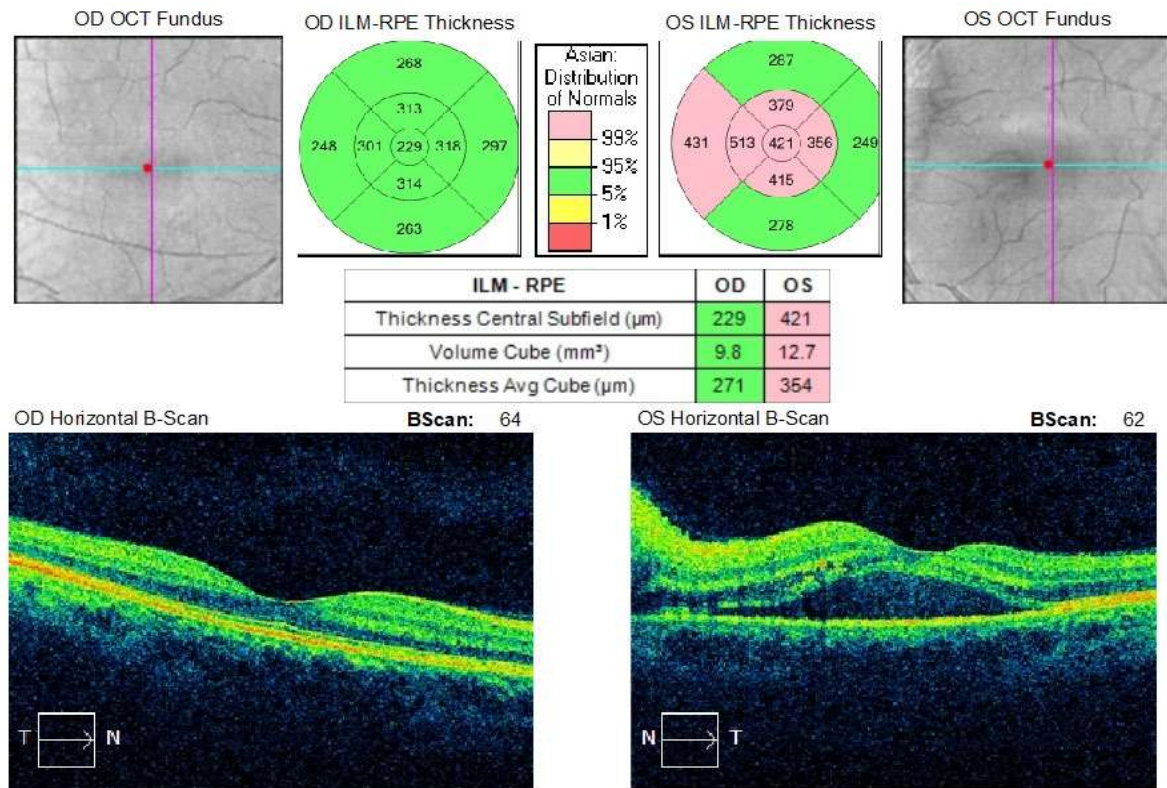


Figure 1:- OCT macula on December 7th, 2021 detected a high level of CMT and submacular fluid on the left eye.

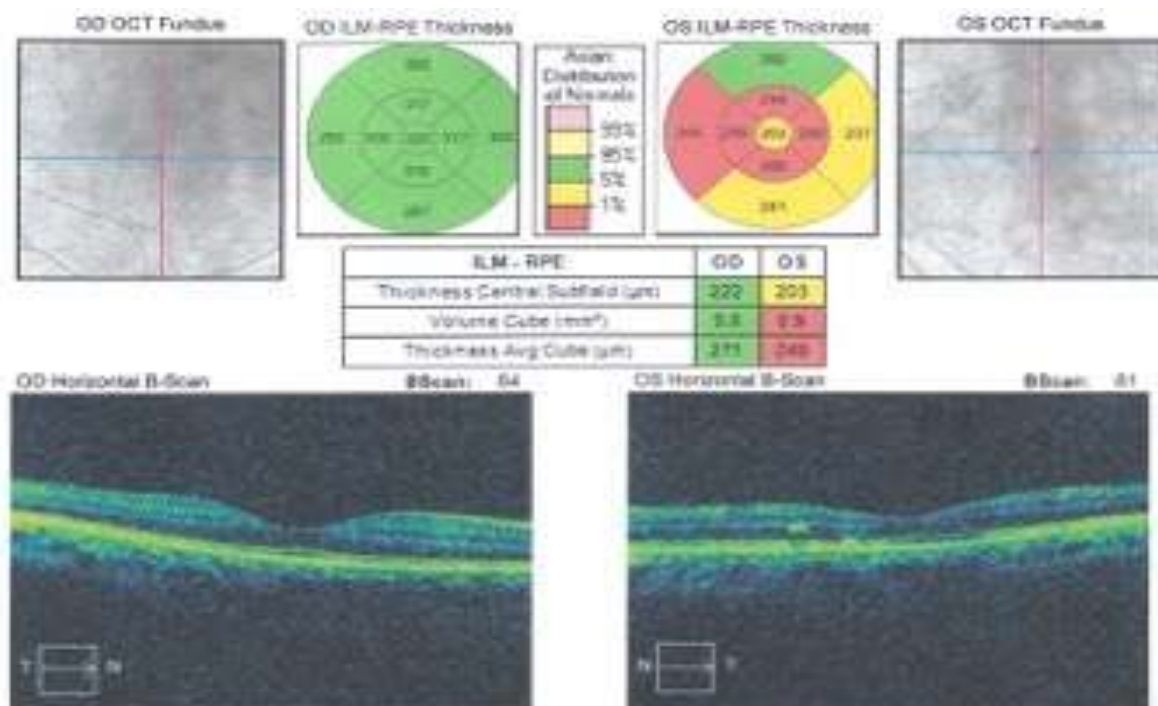


Figure 2:- OCT macula of both eyes post intravitreal anti-VEGF injection showed a significant decrease of CMT.

Patient then came to neuro-ophthalmology clinic on March 19th, 2022, and still complained of blurry vision of his left eye. He realized that blurry vision was worsening in the past 3 months, at first, he felt he was losing his visual field from nasal area then to central and inferior area. His visual acuity of right and left eye were 6/6 and 0.5/60,

respectively. Intraocular pressure was normal. Anterior segment examination was within normal limit. RAPD was still positive on his left eye. On posterior segment there was an atrophic optic nerve head on his left eye. Right eye found there was a small cup-disc-ratio. Patient was assessed with optic atrophy of left eye suspicious of NAION with disc at risk of his right eye and improvement of macular edema of left eye. Patient was planned to do visual field and also laboratory examinations. Visual field examinations showed VFI of 95% and MD -1.35 dB P<10% on his right eye. His left eye showed a false positive result with fixation losses of 9/13, then he asked to re-do the examination. (Fig.3) Laboratory examinations revealed high level of blood glucose (462mg/dL), total cholesterol (267 mg/dL), Triglyceride (262 mg/dL), and LDL (172 mg/dL)

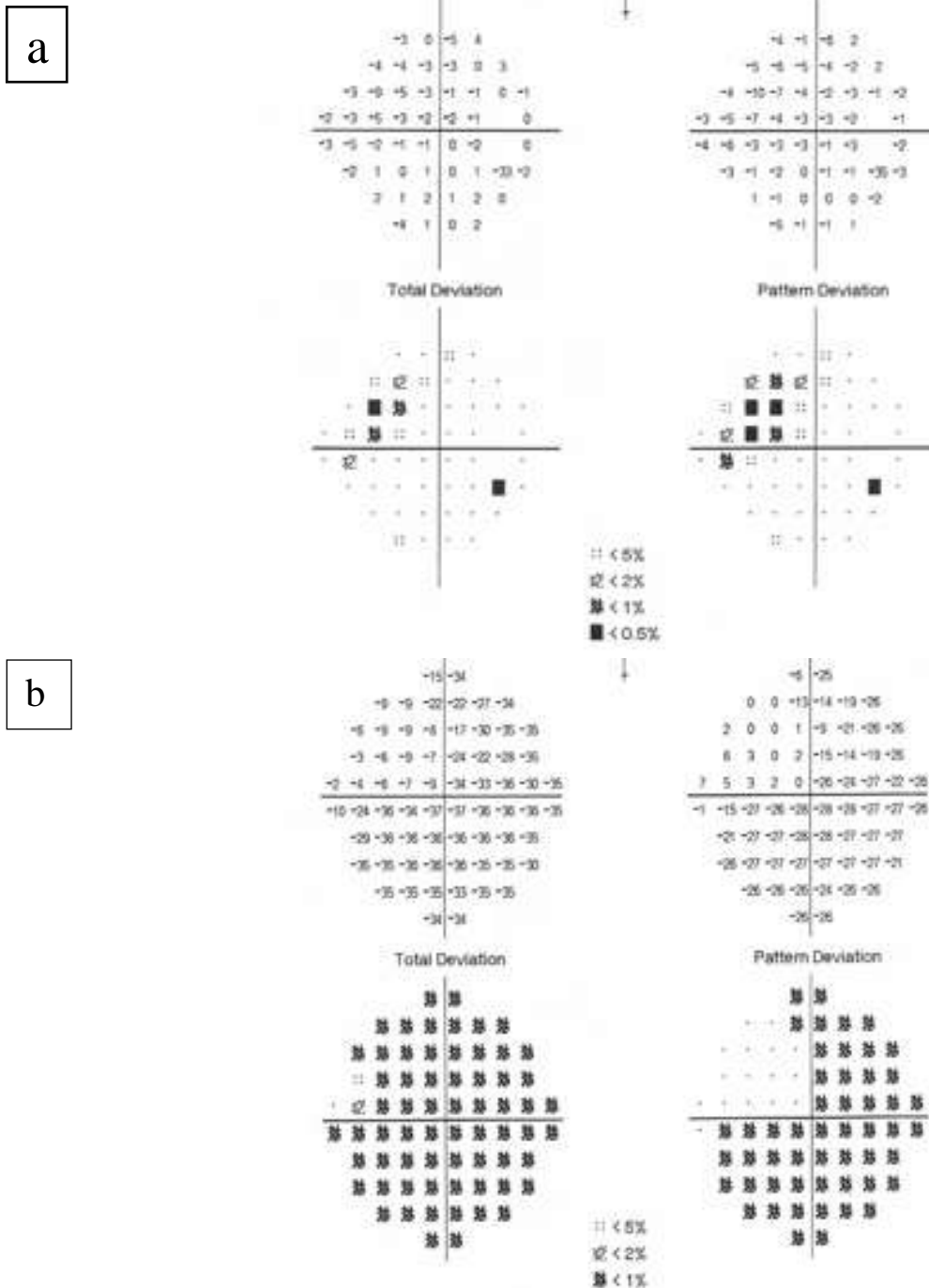


Figure 3:- Visual field examination on March 19th, 2021.

- (a) Slight arcuate visual field defect detected on the right eye, with VFI of 95%, MD of -1.35 dB $P < 10\%$, and PSD 2.51 dB $P < 2\%$.
 (b) Left eye showed of MD -27.06 dB $P < 1\%$ and PSD 12.02 dB $P < 1\%$, although low test reliability detected with fixation losses value of 9/13.

On April 28th, 2022, patient complained difficulty in reading since 5 days ago. Ophthalmology examinations was done on his right eye, the visual acuity was diminished into 3/60 and on posterior examination we found a hyperemic optic nerve head with blurry margin, cup-disc-ratio was also hard to be evaluated. Visual field examination was repeated, his right eye showed a significant deterioration of VFI (22%) with MD -23.45 dB $P < 0.5\%$, his left eye revealed a nearly total visual field loss. (Fig.4) Optical Coherence Tomography of macula was also reassessed (Fig. 5).

He was diagnosed as optic atrophy of right eye and edematous optic nerve head of right eye due to NAION and improvement of macular edema of the left eye. Patient was planned to be given methylprednisolone 8mg/kg and asked to control regularly. Unfortunately, our patient lost to follow up after given steroid treatment.

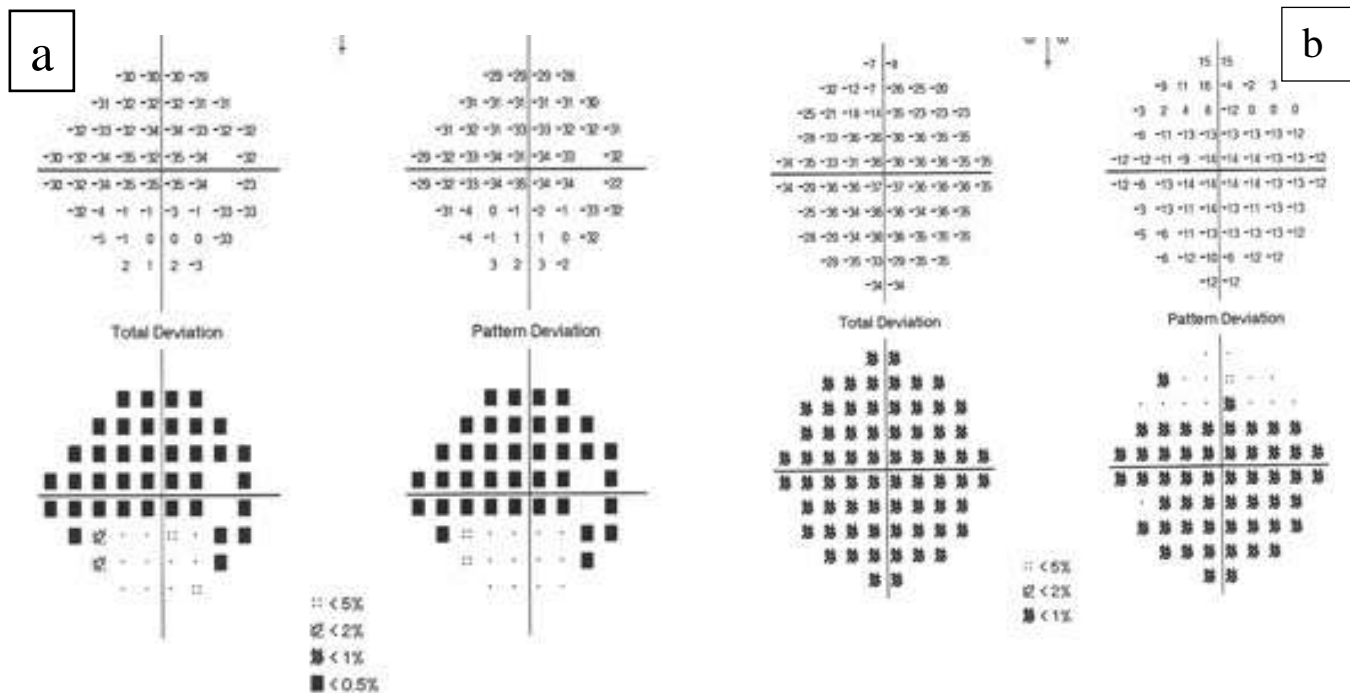


Figure 4:- Visual field examination was repeated on April 28th, 2021. Note a visual field defect on both eyes. (a). Visual field index

of the right eye was diminished into 22%, with MD of -23.45 dB $P < 0.5\%$, and PSD 15.14 dB $P < 0.5\%$. (b) The left eye showed total

visual field loss with MD -31.42 dB $P < 1\%$ and PSD of 7.37 dB $P < 1\%$.

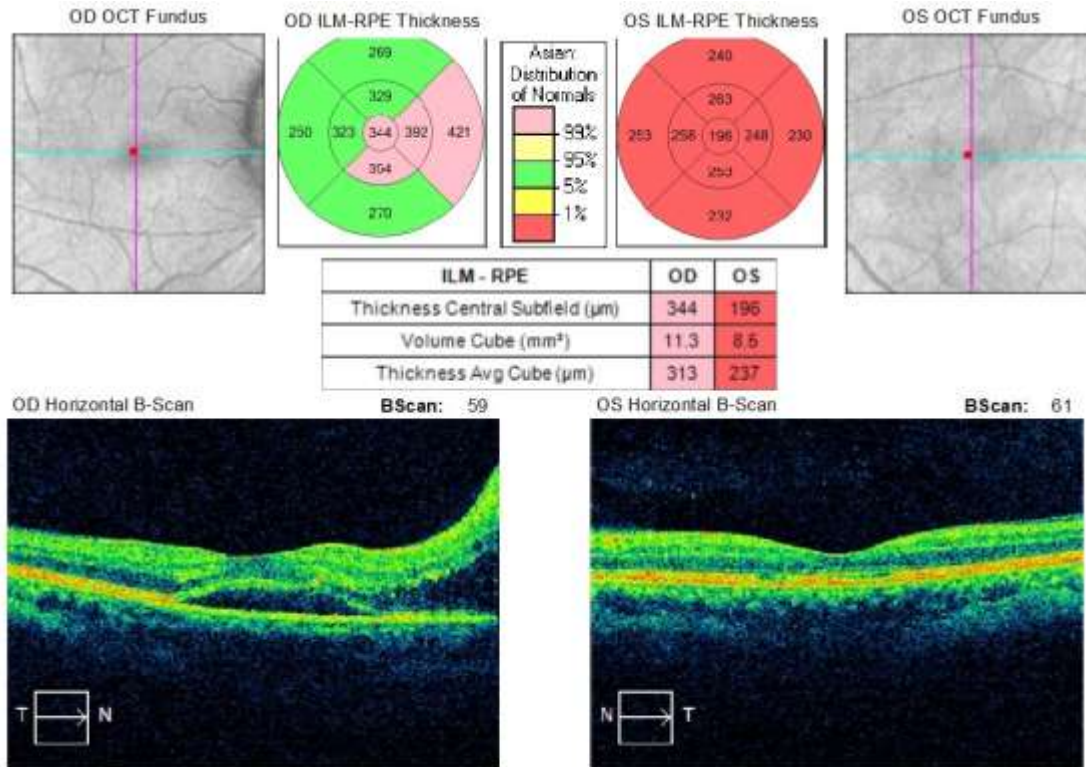


Figure 5:- OCT macula on April 28th, 2021. There was no macular edema left on the left eye. Submacular fluid has built on the right eye detected as a higher level of CMT.

Discussion:-

Non-arteritic optic neuropathy (NAION) is the most common type of ischemic optic neuropathy that generally occur over the age of 50 years. NAION is caused by an ischemia of short posterior ciliary artery that supply the optic nerve head. Vasculopathic risk factors, such as diabetes mellitus (DM), hypertension, dyslipidemia, hypercoagulable state play an important role in pathogenesis of NAION. The ischemia of optic nerve head leads to axonal edema and compartment syndrome that contribute to vision loss and visual field defects. In this acute phase, optic disc swelling is the important finding in NAION. The initial swelling of optic disc will soon resolves and leave a diffuse or sectoral atrophic optic disc typically within 6-11 weeks. Ipsilateral relative afferent pupillary defect or RAPD usually present in unilateral case. In addition, a small cup-to-disc ratio in the fellow eye is a sensitive sign for NAION, which may contribute to contralateral involvement later on in 15% of patients at 5 years. The most common visual field defect in NAION is altitudinal and arcuate defects, with respecting the horizontal meridian. Nearly half of NAION patients presented with 20/30 or better visual acuity within the first two weeks of presentation.^{5,6} Central vision is often preserved and relative to the visual field loss.³ Macular edema is a rare clinical manifestation that may contribute a visual deterioration in NAION.⁷ The incidence of macular edema in NAION patients is difficult to measure since OCT of macula is not routinely performed. However, previous studies noted a macular edema may occur in 10% of NAION cases, documented by OCT.⁸ Comprehensive history taking, ophthalmology examinations such as RAPD, color and contrast sensitivity tests, careful visual field and OCT interpretations are needed to avoid misdiagnosis in our patients.⁹

Patient in this case series was a senior patient with DM presented with acute unilateral onset and edema of the optic disc. Visual acuity of patients were poor on the first admission. From history taking and ophthalmological examination, we diagnosed the patient as NAION complicated by subretinal fluid in the macular area according to OCT examinations. According to the previous study of 500 consecutive NAION eyes showed an initial visual acuity of NAION was 20/20 in 33% patients, and better than 20/40 in 51% patients.¹⁰ Patients with subretinal fluid accumulation, detected by higher level of CMT more than 400 μm , tends to have more severely disturbed visual acuity.¹¹

Macular edema is a common clinical sign in various retinal diseases which develop if hydrostatic pressure gradient is increased between capillary and retinal tissue. In general, macular edema is may related to metabolic, ischemia, hydrostatic forces, inflammatory, toxic mechanism, or mechanical forces. Retina has two blood-retinal barriers (BRB), which is inner (vascular endothelium) and outer (retinal pigmented epithelium; RPE) BRB. Related to diabetics, diabetic macular edema is caused by chronic hyperglycemia state that led to accumulation of polyol pathway, increase advanced glycosylated end product, reactive oxygens, and activation of protein kinase C, that stimulates cytokines such as vascular endothelial growth factor (VEGF) to induce vascular dysfunction and increase vascular permeability of the BRB. Breakdown of the BRB in conditions of diabetes allows vascular leakage to retinal neuropile.^{12,13}

The pathogenesis of subretinal fluid in NAION is different from diabetic macular edema. We suspected that the cause of macular edema is produced by different hydrostatic pressure due to swelling of the optic disc in acute NAION.¹² Our NAION cases have a similar sign that subretinal fluid built up on the acute phase of NAION, which optic nerve edema may contribute to fluid accumulation on the macular area.

Studies mentioned some possible etiologies responsible for the development of submacular fluid and optic disc edema. The collection of this fluid is mostly multifactorial. The most possible explanation is due to axoplasmic flow stasis, and axonal swelling occurs in the pathogenesis of NAION. Optic disc swelling induces disruption of glial tissues which surrounds intermediary border tissue of Kuhnt, which acts as a barrier between optic nerve and retina.¹⁴ Disruption of the glial tissue, which also exacerbated by DM, may accumulate fluid in the peripapillary subretinal space, particularly if the infarct at the temporal portion of the optic disc, which may escape from the peripapillary choroid to subretinal space and streams to the macular region.^{4,15} In addition, the temporal sector of the optic nerve head proves the highest flow density in OCT-Angiography study on control study, and also the highest damage on acute NAION eyes.^{3,16} This study may give explanation the tendencies of fluid streams to macular area, not to the different part of the retina. Fluorescein angiography actually may further explain the mechanism of the accumulation of fluid in the macular area. Unfortunately, we did not perform this ancillary test. Previous fluorescein angiography study on acute NAION revealed early staining of the optic disc and patchy choroidal hypoperfusion extending off the optic disc, and in the late phase, intense optic disc hyperfluorescence was noted.¹⁷ Studies showed no dye accumulated in the macular region, which concludes that the fluid did not originally arise from retinal vessels or choroid directly.¹⁵ Animal study on experimental acute NAION also revealed intense staining of the optic disc and using quantitative analysis, 100% produce a significant amount of fluid, and no subretinal fluid seen on the day one and one week after NAION.¹⁷ Subretinal fluid will resolve along with the resolution of the edematous optic nerve, which suggests closely related to optic disc edema.¹⁸ The ischemic optic disc head and the surrounding retina, sometimes, become leaky with the breakdown of BRB, so the swelling disc may overwhelm the capacity of RPE to overcome the excess fluid, leading to fluid accumulation in subretinal space. This severe swelling of the optic nerve head also disturbs muller cell function and venous return. However, the fluid is reabsorbed as the resolution of optic nerve edema.¹⁷

The risk factor of macular edema in NAION is not well understood. In our series, our NAION patient presenting macular edema had the same underlying disease, which is DM. This raised a question of whether DM contributes an additional role to the mechanism of macular edema in NAION, or macular edema in NAION is a consequences of diabetic itself such as in diabetic retinopathy (DR), or is it has a separated mechanism with DR.

Some studies have mentioned that NAION exhibit unique characteristics related to DM, that the involvement or recurrence is more frequent in diabetics, detection of asymptomatic NAION is more common in diabetics, optic disc edema resolves longer in diabetics, and also associated with retinal hemorrhages and prominent telangiectasias. Moreover, one study also mentioned that some diabetics with NAION also concurrently have macular edema with poor visual acuity.^{19,20} We can conclude that diabetics may contribute an additional role to the mechanism of the macular edema in NAION.

The administration of intravitreal anti-VEGF agents in acute NAION with the presence of subretinal fluid is still debatable. Previous studies suggested that intravitreal anti-VEGF injection has positive effects on the course of the disease, the first one is to decrease vascular permeability, and the second is to reduce the concomitant subretinal fluid if present. Therefore, anti-VEGF is expected to alleviate the subretinal fluid and improve visual acuity.²¹ Intravitreal anti-VEGF injections also raise controversial aspects in treating NAION, whether the possible role of anti-VEGF is facilitating or inducing acute NAION. One study of intravitreal bevacizumab injections on acute

NAION showed another NAION episode two weeks after the injection. A survey of neovascular age-related macular degeneration treated with repeated intravitreal anti-VEGF injection showed that the higher number of injections also has a higher risk of developing ischemic optic neuropathy.²² Another report has documented an episode of NAION on patients with diabetic macular edema three weeks after intravitreal anti-VEGF injection. This may relate to an anti-VEGF activity or coincidental. A previous study had declared a potential mechanism that exacerbates ischemic state in NAION, include a vasoconstrictor effect of the anti-VEGF agents.²³ Some studies have demonstrated that intravitreal anti-VEGF can trigger NAION by transient IOP elevation following injection. Thus, a high IOP can precipitate visual loss in NAION patients.²³ Intravitreal anti-VEGF is also not only inhibit the neovascularization from the choroid, but also result in optic nerve head collateral vessel regression which aggravates the ischemia.²²

Our case was treated with intravitreal antiVEGF injection on his left eye due to macular edema. During one-month follow-up, resolution of subretinal fluid was seen. However, his visual field complaint was persisted, and no significant improvement in visual acuity and visual field defect. The recovery of subretinal fluid most likely was due to the progression of edematous to atrophic optic nerve head. In addition, this patient also leaves perimacular exudates on his left eye after the remission of edema. It occurred due to edematous optic nerve will also induce a certain amount of retinal venous engorgement, which in some eyes, along with the resolution of disc edema, lipid deposits may be seen in the macular or peripapillary region, especially in dyslipidemic patients, such as our patient. These lipid deposits are a suitable footprint for a history of an edematous disc in the past.¹⁰ Therefore, this event further indicates that the macular edema was related to optic disc edema.

His fellow eye also experienced an acute phase of NAION two months later accompanied by macular edema, which previously no macular involvement was detected. This simultaneous occurrence indicates that this phenomenon was related to optic disc edema. We decided not to treat them with antiVEGF injection and switch the treatment to steroid instead. Theoretically, the use of steroids in patients with NAION could decrease the optic nerve head capillaries compression, thus increasing blood flow and reducing optic nerve head edema. Currently, there is no literature which studied the effect of steroid and macular edema secondary to optic nerve head edema. In this patient, the steroid was aimed to accelerate the resolution of optic disc edema.²⁴

The importance of OCT in this case may help us observe the development of subretinal fluid, as implemented in our case.¹⁸

The prognosis of macular edema in NAION cases was demonstrated on the previous study, that 11 out of 13 eyes with NAION and macular edema have improvement in visual acuity when macular edema was resolved. The comorbidities in our patient, which are diabetes mellitus and hypertension, did not give different outcome in macular edema improvement. Our patient had resolved completely as the optic nerve edema subsided. Some cases showed that the reabsorption of this fluid may take account to the improvement in visual acuity in one-third patients with NAION. However, the natural course of NAION allow the deterioration of visual function over time, which may occur in 22-37% of cases, and it explains why the resolution of subretinal fluid in our patient do not affect the visual function.⁸

Conclusion:-

Macular edema is a rare but self-limiting phenomenon that may arise in patients with NAION and influence visual acuity. The pathogenesis of macular edema in NAION is more likely a spillover from optic disc edema, and spontaneous recovery of macular edema will be seen along the natural course of acute NAION. Advanced technology in recent times, such as OCT, has expanded further demonstrated the connection of NAION and macular edema, which will help us to confirm and closely monitor our findings.

References:-

1. Dave VP, Pappuru RR. An unusual presentation of nonarteritic ischemic optic neuropathy with subretinal fluid treated with intravitreal bevacizumab. *Indian J Ophthalmol.* 2016;64(1):87–8.
2. The patient with decreased vision: classification and management. In: *American Academy of Ophthalmology Basic and clinical science course section 5: Neuro-ophthalmology.* United States: American Academy of Ophthalmology; 2019.
3. Berry S, Lin W V, Lee AG. Nonarteritic anterior ischemic optic neuropathy : cause , effect , and management. 2017;23–8.

4. Donmez O, Kocaoglu G, Yaman A, Bajin MS, Saatci AO. Macular Evaluation with Spectral Domain Type Optic Coherence Tomography in Eyes with Acute Nonarteritic Ischemic Optic Neuropathy at the Presentation Visit. *Open Ophthalmol J.* 2017;11(1):17–23.
5. Huemer J, Khalid H, Ferraz D, Faes L, Korot E, Jurkute N, et al. Re-evaluating diabetic papillopathy using optical coherence tomography and inner retinal sublayer analysis. *Eye [Internet].* 2021;(March):1–10. Available from: <http://dx.doi.org/10.1038/s41433-021-01664-1>
6. Gaier ED, Torun N. The enigma of nonarteritic anterior ischemic optic neuropathy: An update for the comprehensive ophthalmologist. *Curr Opin Ophthalmol.* 2016;27(6):498–504.
7. Demirel S, Batioğlu F, Oguz YG, Özmert E. Macular involvement and response to steroid therapy demonstrated by optical coherence tomography in non-arteritic anterior ischaemic optic neuropathy. *Neuro-Ophthalmology.* 2013;37(4):161–4.
8. González-Martín-Moro J, FernándezHortelano A, Castro-Rebollo M, Pilo-de-la-Fuente B. Visual worsening despite resolution of subfoveal fluid in nonarteritic ischemic optic neuropathy. *Can J Ophthalmol [Internet].* 2017;52(6):e218–20. Available from: <http://dx.doi.org/10.1016/j.jcjo.2017.05.002>
9. Tsai MJ, Hsieh YT, Shen EP, Peng YJ. Systemic Associations with Residual Subretinal Fluid after Ranibizumab in Diabetic Macular Edema. *J Ophthalmol.* 2017;2017.
10. Hayreh SS. Ischemic optic neuropathies - Where are we now? *Graefes Arch Clin Exp Ophthalmol.* 2013;251(8):1873–84.
11. Takayama K, Kaneko H, Kachi S, Ra E, Ito Y, Terasaki H. High-dose intravenous pulse steroid therapy for optic disc swelling and subretinal fluid in non-arteritic anterior ischemic optic neuropathy. *Nagoya J Med Sci.* 2017;79(1):103–8.
12. Joussen AM, Stitt A, Lois N. Mechanisms of Macular Edema and Therapeutic Approaches. In: Schachat AP, editor. *Ryan's Retina.* 6th ed. USA: Elsevier; 2019. p. 1993.
13. Cantor LB, Rapuano CJ, McCannel CA. Retina and Vitreous. In: *Basic and Clinical Science Course.* San Francisco: American Academy of Ophthalmology; 2020.
14. Pan X, Fan N, Lie X. Easily Ignored Signs of Non-Arteritic Anterior Ischemic Optic Neuropathy: Secondary Serous Detachment in the Macula. In: Wang N, editor. *Optic Disorders and Visual Field.* Singapore: Springer; 2019. p. 369–76.
15. Tawse KL, Hedges TR, Gobuty M, MendozaSantiesteban C. Optical coherence tomography shows retinal abnormalities associated with optic nerve disease. *Br J Ophthalmol.* 2014;98(SUPPL. 2).
16. Sharma S, Ang M, Najjar RP, Sng C, Cheung CY, Rukmini A V, et al. Optical coherence tomography angiography in acute non-arteritic anterior ischaemic optic neuropathy. 2017;1045–51.
17. Yu C, Ho JK, Liao YJ. Subretinal fluid is common in experimental non-arteritic anterior ischemic optic neuropathy. *Eye.* 2014;28(12):1494–501.
18. Kanra AY, Uslu H. A preliminary diagnosis need to be considered as a differential diagnosis of submacular fluid: Non-arteritic ischemic optic neuropathy-case report. *Retina-Vitreus.* 2020;29(1):84–7.
19. Hayreh SS. *Ischemic Optic Neuropathies.* Springer; 2011.
20. Galvez-Ruiz A. Macular star formation in diabetic patients with non-arteritic anterior ischemic optic neuropathy (NA-AION). *Saudi J Ophthalmol [Internet].* 2015;29(1):71–5. Available from: <http://dx.doi.org/10.1016/j.sjopt.2014.09.002>
21. Ayhan Z, Kocaoğlu G, Yaman A, Bajin MS, Saatci AO. Single Intravitreal Aflibercept Injection for Unilateral Acute Nonarteritic Ischemic Optic Neuropathy. *Case Rep Ophthalmol Med.* 2015;2015:1–4.
22. Chen YY, Chou P, Huang YF, Chien HJ, Wu YC, Lee CC, et al. Repeated intravitreal injections of antivascular endothelial growth factor in patients with neovascular age-related macular degeneration may increase the risk of ischemic optic neuropathy. *BMC Ophthalmol.* 2019;19(1):1–7.
23. Mansour AM, Schwartz SG, Gregori NZ, Yehoshua Z. Insight Into 8 Patients With Nonarteritic Anterior. *J Neuro-ophthalmol.* 2012;32(2):189–93.
24. Chen J, Zhu J, Chen L, Hu C, Du Y. Steroids in the treatment of nonarteritic anterior ischemic optic neuropathy: A PRISMA-complaint meta-analysis. 2019;1–5.
25. Saatci AO, Taskin O, Selver OB, Yaman A, Bajin MS. Efficacy of Intravitreal Ranibizumab Injection in Acute Nonarteritic Ischemic Optic Neuropathy: A Long Term Follow Up. *Open Ophthalmol J.* 2013;7(1):58–62.