



Journal Homepage: - www.journalijar.com

INTERNATIONAL JOURNAL OF ADVANCED RESEARCH (IJAR)

Article DOI: 10.21474/IJAR01/16466

DOI URL: <http://dx.doi.org/10.21474/IJAR01/16466>



RESEARCH ARTICLE

A ANALYSIS OF FUNCTIONAL AND CLINICAL OUTCOME OF PILON FRACTURE TREATED WITH AN ANTEROLATERAL PLATE FIXATION IN A TERTIARY CARE CENTER: PROSPECTIVE STUDY

Dr. Lakkam Bhargavi¹, Dr. Kondareddy Harikrishna Reddy² and Dr. Aithagani Sandeep Kumar³

1. Post Graduate in Department of Orthopedics Narayana Medical College and Hospital Chinthareddy Palem Nellore -Pin Code 524003 Andhra Pradesh, India.
2. Professor in Department of Orthopedics Narayana Medical College and Hospital Chinthareddy Palem Nellore - Pin Code 524003 Andhra Pradesh, India.
3. Professor in Department of Orthopedics Narayana Medical College and Hospital Chinthareddy Palem Nellore - Pin Code 524003 Andhra Pradesh, India.

Manuscript Info

Manuscript History

Received: 19 January 2023

Final Accepted: 24 February 2023

Published: March 2023

Key words:-

Tibial Pilon Fracture, Anterolateral Approach For Pilon Fracture, Orif With Anterolateral Plate Fixation

Abstract

Introduction: This clinical study presents the short-term results of the Pilon fracture treated with open reduction and internal fixation through an anterolateral approach and further re-analyse the different complication rates and outcome percentages during surgical treatment through an anterolateral approach.

Materials And Methods: The present study is a prospective descriptive study involving 22 patients with Pilon fracture treated by ORIF through an anterolateral approach at the Department of Orthopaedics, Narayana Medical College and hospital, Nellore, Andhra Pradesh from June 2021 to May 2022.

Results: In our study, among 22 cases, the majority of patients were male (77%). The mean age group of our patients has been 40 -60 years. Right-sided injury and left-sided injury are almost equal. Functional outcome was measured using Mazur criteria. According to these, we found that 12 patients (54.54%) had excellent functional outcome, 8 patients (36.36%) had good functional outcome and 2 patients had fair functional outcome following ORIF with anterolateral plate for tibial pilon fractures and are comparable with other studies in the literature review.

Discussion: In our study functional outcome was measured using Mazur ankle score. According to these we found 12 patients (54.54%) had excellent functional outcome and 8 patients (36.36%) had good functional outcome and 2 patients (9.1%) had fair functional outcome following open reduction and internal fixation with anterolateral for tibial pilon fracture.

Copy Right, IJAR, 2023,. All rights reserved.

Introduction:-

Pilon fractures are amongst most serious fractures involving the ankle joint and persist to present a challenge to the orthopaedic surgeon. "Pilon fractures" involve the dome of the distal tibia articular surface, resulting from axial

Corresponding Author:- Dr. Lakkam Bhargavi

Address:- Post Graduate in Department of Orthopedics Narayana Medical College and Hospital Chinthareddy Palem Nellore -Pin Code 524003 Andhra Pradesh, India.

loading ranging from low to high energy, and a spectrum of articular and metaphyseal injuries where the fibula may or may not be intact.

These fractures account for approximately 7% of all lower limb fractures. The management of Pilon fractures remains challenging. Significant advancements in the management of Pilon fractures have taken place with the development of orthopaedic surgical techniques and materials, shifting from conservative management toward surgical intervention.

Management principles were originally outlined by Rüedi and Allgöwer and included reconstruction of the fibula as well as the articular surface of the tibia. A wide variety of treatment strategies, implants, and approaches have been utilised in order to manage this type of fractures with broad range of results.

Various modalities of internal fixation for tibial pilon by plating have been described. These include conventional AO medial plating using medial buttress plate, anterior plating using T plates, Cloverleaf plate or occasionally simple dynamic compression plates.

Locking compression plating (LCP) is the most widely used implant for tibial pilon fractures at present. For pilon fracture the gold standard was medial LCP, a low profile plate placed through medial approach. But Medial plating using LCP on the subcutaneous medial border of distal tibia still resulted in a significant rate of wound dehiscence and deep infection, although at a lower rate compared to standard AO plates.

Locking Compression Plating on the lateral surface of tibial plafond is a new entity and the anterolateral approach is gaining popularity for the fixation of tibial pilon fractures. Early studies have shown it offers the benefit of improved soft tissue coverage and the potential for a lower rate of wound healing complications. If it is so, then anterolateral plating for tibial pilon fractures could well be a milestone in the management of pilon fracture.

This clinical study presents the short term results of the Pilon fracture treated with open reduction and internal fixation through anterolateral approach and further re-analyze the different complication rates and outcome percentage during surgical treatment through anterolateral approach.

Materials And Methods:-

The present study is a prospective descriptive study involving 22 patients with Pilon fracture treated by ORIF through anterolateral approach at Department of Orthopaedics, Narayana Medical College and hospital , Nellore , Andhra Pradesh from June 2021 to may 2022.

Inclusion Criteria

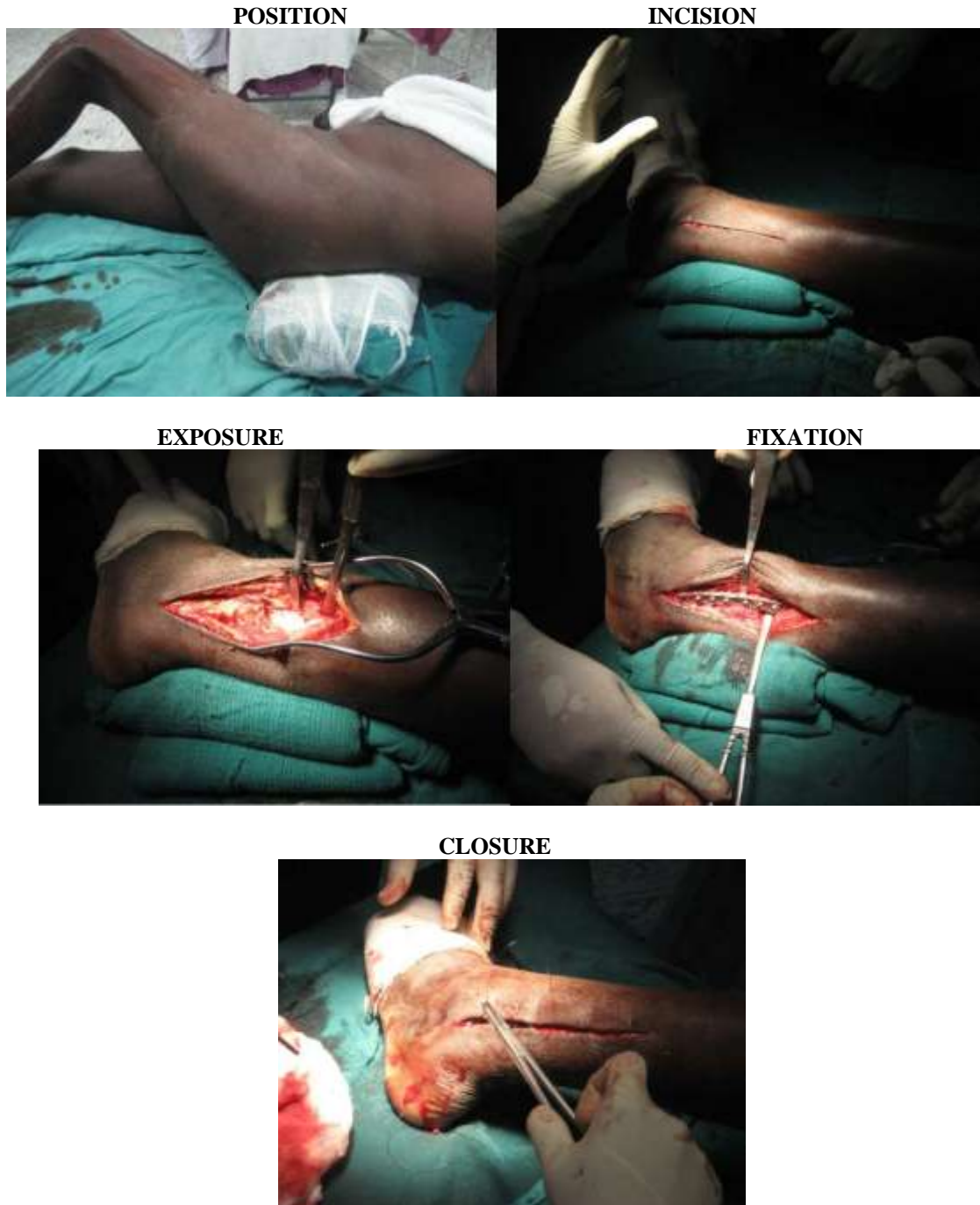
include Patients with tibial pilon fracture treated with anterolateral plate fixation in Narayana Medical College and hospital . Patients giving consent for the procedure. Skeletally mature patients. Ruedi and Allgower type – I, II, III fractures. AO/OTA type 43 A, B and C fractures. Closed fractures. Minimum follow up of 4 months.

Exclusion Criteria

Include Patients with pilon fracture treated with other treatment modalities. Patients not giving consent for the procedure. Age below 18 years and above 80 years. Compound fractures. Associated calcaneum fractures and talus fractures. Severely mangled extremity and associated spinal and abdominal injuries.

After proper history taking, clinical examination, radiological work up, pre-operative work up, pre anaesthetic check up and informed written consent, patients with tibial pilon fracture were taken up for treatment. All surgeries were performed on an elective basis using strict aseptic precaution under spinal or general anaesthesia.

All patients were operated using anterolateral approach of ankle and leg.



Post operatively intravenous antibiotic coverage given for three days followed by oral antibiotics. Suture removal done on tenth to twelfth post operative day and discharged from hospital.

Patients were followed at an interval of 6, 10 and 16 weeks and every month thereafter in cases of delayed union. Once signs of radiological union appear, partial weight bearing was allowed.

Full weight bearing was allowed after fracture consolidation. All cases were assessed using the Mazur ankle score.

Observations And Results:-

In our study, among 22 cases, majority of patients were male (77%). Mean age group of our patients has been 40 -60 years. Right sided injury and left sided injury are almost equal. Most of the injuries are due to RTA (63.6%).

In our study only AO/OTA classification type B and C are involved, Out of 22 cases, four patients are type B 2, two patients are type B 3, six patients are type C 1, ten patients are type C2. Type C1, C2 fractures can be effectively managed by anterolateral approach. Maximum no. of surgeries (64%) done between 15 to 21 days after admission.

Mean time taken for surgery was 1 hour 40 minutes. Average duration of hospital stay was found to be 24 -27 days. Three patients (13.63%) developed Superficial wound infection, two patients (9.1%) had deep wound infections, two patients had malunion (9.1%), three patients (13.63%) developed post traumatic arthritis and two patients (9.1%) had post traumatic stiffness. Functional outcome was measured using Mazur criteria.

According to these we found 12 patients (54.54%) had excellent functional outcome, 8 patients (36.36%) had good functional outcome and 2 patients had fair functional outcome following ORIF with anterolateral plate for tibial pilon fractures and are comparable with other studies in the literature review.

Discussion:-

In our study functional outcome was measured using Mazur ankle score. According to these we found 12 patients (54.54%) had excellent functional outcome and 8 patients (36.36%) had good functional outcome and 2 patients (9.1%) had fair functional outcome following open reduction and internal fixation with anterolateral for tibial pilon fracture.

Pierre Joveniaux et al and Xavier Ohi et al

in their study of distal tibia fracture: management and complication, they had a functional score of 76 % in their series. Their result had 20 cases of excellent, 15 cases of good, 9 cases of fair and 6 cases of poor in their series of 50 cases.

Mario Ronga MD et al and Nicola Maffulli MD et al

In their study of minimally invasive locked plating of distal tibia fractures, they had the following outcomes – of the 21 cases they achieved union in 20 cases and one case went in for non-union. They had 3 cases of angular deformities all less than 7° and no patient had a leg-length discrepancy.

Rakesh Gupta et al and Rajesh Kumar Rohilla et al

In their study of locking plate fixation in distal tibia fractures – series of 79 patients, had reported about 88% of healing without malunion, 2.5% of malunion and 3.7% of non-union. They used both MIPPO and ORIF for fixing these fractures. They found good and early union rate in the MIPPO group.

Pugh and colleague

Evaluated 60 patients, 25 of whom were treated with external fixators. They noted that they had more number of malunion in the external fixator group compared to that of internal fixation. They met most of their complication in the external fixator group.

Table 1:- Comparison of Functional outcome using MAZUR / AOFAS criteria.

SERIES	EXCELLENT	GOOD	FAIR	POOR
Rubin- Suarez et al	30.5%	46.5%	13.1%	9.7%
Carbonell-Escobar et al	30%	46%	14%	10%
Pierre Joveniaux et al	40%	30%	18%	12%
Kosalaraman P et al	16%	56%	12%	16%
Swarup-M Daniel et al	36.36%	54.54%	9.09%	
In our study	54.54%	36.36%	9.1%	0%

Conclusion:-

The following conclusions are drawn from this study: Tibia pilon fractures causes severe soft tissue swelling and damage, so operate after waiting for 10 to 20 days till edema to settle down and the wrinkle sign appears.

Respect the soft tissues: do not operate too early or through compromised skin, instead wait till the soft tissues are amenable for surgery.

Restoration of the articular surface and re-establishing its relationship to the tibial shaft is the primary goal of treatment. Good functional result depends on reasonable anatomic reduction of the articular surface either by direct or indirect methods.

Open reduction and internal fixation with anatomical restoration of the articular surface is to be done in all cases AO type C fractures otherwise it will lead to mal-alignment and secondary degenerative osteoarthritis.

Anatomic realignment of fibula indirectly reduces the talus beneath the anatomic of tibia. Restoration of fibular length, alignment and rotation has the substantial impact on the indirect realignment of anterolateral and posterolateral tibial plafond from their attachment to the anterior and posterior tibiofibular syndesmotic ligaments.

Hence fibula fixation is advocated wherever possible. The soft tissue condition and the fracture anatomy will decide the timing of surgery and the choice of approach and implant.

From our study, the anterolateral approach with anterolateral plate gives good result with low rate of complication. This approach can be used in most types of plafond fracture and is safe and effective.

References:-

1. Bucholz, Robert W.; Heckman, James D.; Court-Brown, Charles M.; Tornetta, Paul, Rockwood and Green's Fractures In Adults, 8th Edition
2. Michael S. Sirkin.; Plating of tibial pilon fractures; Am J Orthop. 2007;36(12 suppl):13- 17
3. S. Terry Canale, James H. Beaty ; Campbells operative orthopaedics 13th edition.
4. Warner et al. Surgical approach options for pilon fractures; Techniques in Foot & Ankle Surgery; volume 15; issue 4; Pages 169-174; 2016
5. Topliss CJ, Jackson M, Atkins RM. Anatomy of pilon fractures of the distal tibia. J Bone Joint Surg Br. 2005;87(5):692-697.
6. Aneja, Arun et al. Anterolateral distal tibia locking plate osteosynthesis and their ability to capture OTA C3 pilon fragments. Injury; volume 49; issue 2; pages 409-413; 2018
7. B D Crist et al. Anterolateral approach for pilon fractures: rate of wound complications in the early postoperative period; the JBJS-BRITISH; volume 92-B; p76; jan 2010
8. Hickerson et al. Anterolateral Approach to the Pilon. Journal of Orthopaedic Trauma. 30():S39-S40, AUG 2016.