

 <p>ISSN NO. 2320-5407</p>	<p>Journal Homepage: - www.journalijar.com</p> <h2>INTERNATIONAL JOURNAL OF ADVANCED RESEARCH (IJAR)</h2> <p>Article DOI: 10.21474/IJAR01/16762 DOI URL: http://dx.doi.org/10.21474/IJAR01/16762</p>	 <p>INTERNATIONAL JOURNAL OF ADVANCED RESEARCH (IJAR) ISSN 2320-5407 Journal Homepage: http://www.journalijar.com Journal DOI: 10.21474/IJAR01</p>
---	---	--

RESEARCH ARTICLE

AESTHETIC REHABILITATION OF SEVERE ANTERIOR ALVEOLAR RIDGE DEFECT WITH ANDREW'S BRIDGE-A CASE SERIES

Dr. Gopika K.K, Dr. Gayathri P.M, Dr. Ayana Shalimon and Dr. Harsha Kumar K.

Manuscript Info

Manuscript History

Received: 28 February 2023

Final Accepted: 31 March 2023

Published: April 2023

Key words: -

Andrew's Bridge, Fixed- Removable System, Anterior Ridge

Abstract

Loss of variable amount of soft and hard tissue is often an inevitable consequence of missing teeth. Prosthetic rehabilitation of large anterior alveolar ridge defects is often a challenge to the clinician.¹ Such defects require not just the replacement of teeth, but also closure of defective area so as to achieve proper speech and aesthetics. Fixed removable partial dentures are indicated for patients with extensive tissue loss and when the alignment of opposing arches creates difficulties for placement of conventional partial denture. Andrews's bridge is a type of fixed removable prosthesis indicated in patients with severe ridge defects. This type of prosthesis successfully replaces missing teeth along with complete closure of defect, restoring speech and aesthetics.²

Copy Right, IJAR, 2023, All rights reserved.

Introduction

Andrew's bridge is a fixed partial denture-removable partial denture system. It was introduced by Dr James Andrews of Amite, Louisiana, USA in 1965. Andrews bridge system incorporates a fixed component and a removable pontic component. Fixed component consists of porcelain fused to metal ceramic retainers on the abutment teeth joined by a bar.³ The removable pontic component consists of removable partial denture having attachments or sleeves to fit on the bar. Andrews bridge system is indicated in patients where a greater degree of the residual ridge has been lost due to trauma, congenital defects or other pathological process.

This functionally fixed prosthesis has the advantage of flexibility in arranging the removable partial denture teeth with minimum extension along with better retention and stability. The occlusal forces are directed more along the long axis of the abutment teeth. This technique successfully replaces the missing teeth along with complete closure of the defect and restores phonetics and aesthetics. The removable part of this system can be easily removed and reattached by the patient. Thus, it enables the patient to maintain hygiene around the abutments and under the bar.

This article describes three case reports having multiple missing anterior teeth along with ridge defects. These defects were restored successfully by using fixed-removable Andrew's bridge system.

Case Report-1

A 36-year-old male patient presented to the department of prosthodontics with a chief complaint of missing maxillary and mandibular anterior teeth (Figure:1). Patient had a history of road traffic accident 1 year back. Intra oral examination revealed missing teeth in relation to 12,21,22,31,32. Ellis class 2 fracture in relation to 21 and extrusion in relation to 11.

Patient had undergone root canal treatment irt 11,21 and alveoloplasty in relation to31,41 region. There was a bony defect irt mandibular anterior region (Siebert's class III defect) Personal history revealed chronic smoking and tobacco chewing habits. Treatment options for the maxillary arch included implant supported FDP, conventional FDP and conventional RPD.Treatment options for the mandibular arch included implant supported FDP with autogenous bone graft and a fixed-removable partial denture.

The patient was informed about the various treatment options. Implant supported fixed dental prosthesis treatment option was not considered because the patient is a chronic smoker. He also did not prefer surgical treatment for prosthetic rehabilitation of missing teeth. On further discussion with patient, he preferred a conventional fixed partial denture for the maxillary arch and a fixed-removable prosthesis for the mandibular arch.

Procedure

Diagnostic impressions were made with irreversible hydrocolloid impression material and poured in type iii dental stone. Tooth preparation was done on 11,13,21 to rehabilitate maxillary anterior region (figure:2) followed by provisionalisation with tooth coloured acrylicresin.Zirconia fixed dental prosthesis was cemented with glass ionomer luting cement. (Figure:3). Preparation done on 33,43 to receive PFM crowns for fabricating Andrew's bridge in relation to mandibular anterior region. Final impression was made with two stage putty wash technique using polyvinyl siloxane impression material and the impression has been sent to laboratory for fabrication of fixed component of Andrew's bridge system. Provisional acrylic crowns were cemented irt 33,43 with intermediate restorative material. In the laboratory, wax patterns were fabricated on the prepared abutment teeth (33,43) and were connected using prefabricated castable plastic bar attachment. To facilitate maintenance of oral hygiene by the patient, 2-3 mm clearance was made between the bar and the crest of the alveolar ridge. Then the entire assembly was casted in chrome cobalt alloy. The finished and polished metal framework was tried in the patient's mouth to verify proper fit and clearance between the bar and underlying soft tissues. Shade selection was done for the ceramic teeth. Ceramic layering was done on the retainers 33,43.

The next step was the fabrication of the removable part of Andrew's bridge system. The missing teeth 31,32,41,42 were arranged on the wax occlusal rim placed over the metal framework which was fabricated on to the edentulous area of the cast. Subsequently, try in of the removable partial denture (RPD) unit was done for aesthetic approval by the patient. The replacement teeth along with the wax base is flaked, dewaxed and cured using heat cure acrylic resin. The fixed part of the prosthetic assembly (retainers joined by the bar) was then cemented in the patient's mouth with type I GIC luting agent. The removable component of the Andrews bridge which is having a snug fit on the metallic component is placed in position. The patient was trained to insert and remove the RPD snugly fitting over the fixed component of Andrew's bridge. Proper oral hygiene (including the use of interdental brush) instructions were given to the patient. The patient was scheduled for follow-up visits after 1 week, 3and 6 months. On evaluation over 6 months, it was found that the patient very well adapted and was comfortable with the prosthesis. The patient was also satisfied with the restoration of function and aesthetics.



Figure 1: - Pre-operative extraoral view.

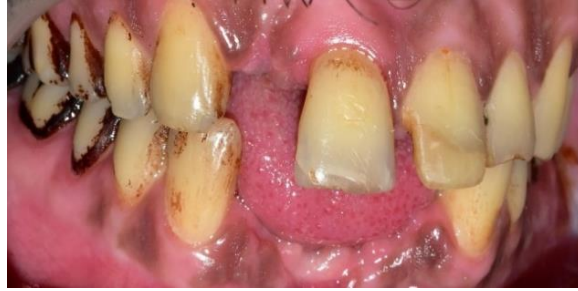

Figure 2: - Pre-operative intraoral view.

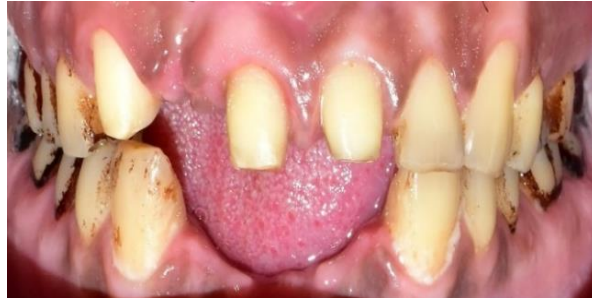

Figure 3: - Tooth preparation on 11,13,21.

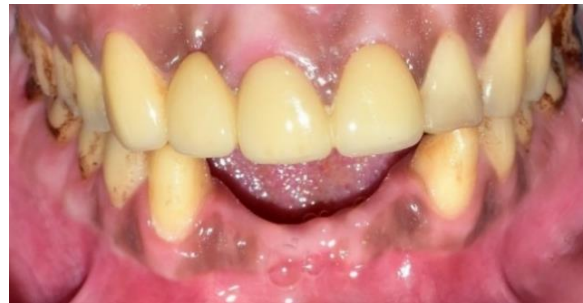

Figure 4: - Zirconia FPD in relation to 11,13,21.

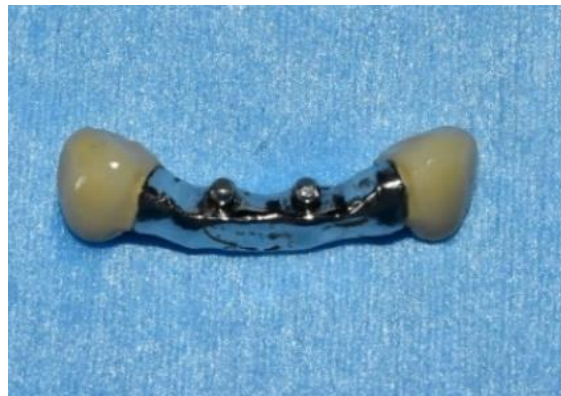

Figure 5: - Fixed component of Andrews bridge
Intraorview.

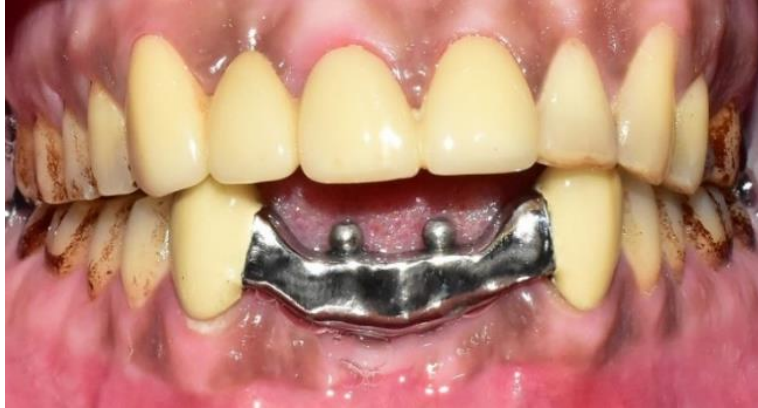

Figure 6: - Fixed component of Andrews bridge -Intra oral view.

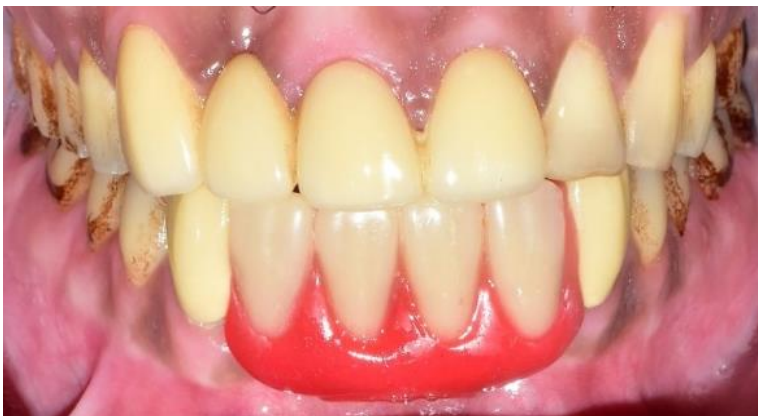

Figure 7: - Removable component of Andrew's bridge -wax trial.



Figure 8: - OT Cap in the intaglio surface of removable component of Andrew's bridge.

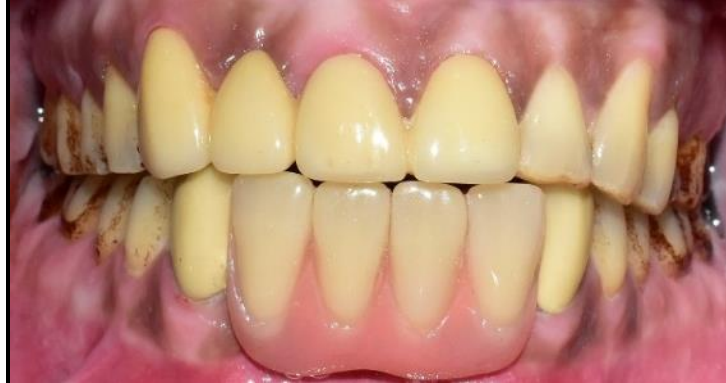

Figure 9: - Post-operative intraoral view.



Figure 10: - Post operative extra oral view.

Case report- 2

A 56-year-old male patient reported to the Department of Prosthodontics and Crown and Bridge, GDC, Trivandrum with the chief complaint of missing lower front teeth. (Figure: 11) The teeth were lost many years back due to trauma as reported by patient. Patient had an interim RPD but was not using it as he was not satisfied with the function. On examination, a large defect was present in the alveolar region extending from 33 to 43 which can be classified as Siebert's class III. (Figure: 12) The patient was provided various treatment options available like removable partial denture, fixed partial denture, implant with graft and fixed removable prosthesis. Patient was not very supportive regarding removable partial denture and implant prosthesis. Thus, the patient was explained about the advantages, disadvantages treatment duration and importance of oral hygiene measures while using Andrews Bridge prosthesis. Patient agreed to go with Andrews fixed removable prosthesis.

Procedure

Diagnostic impressions were made using alginate impression material. Mandibular left and right canines were used as abutments. Tooth preparation was done with 33 and 43 to receive PFM retainers and impression was made in Polyvinyl siloxane impression material. (Figure: 13). The bar was fabricated in the wax pattern and casted along with these copings. The finished and polished metal framework was tried in the patient's mouth for proper fit and clearance between the bar attachment and underlying soft tissues was checked. (Figure: 14). The missing teeth were arranged on wax occlusal rim fabricated on to the edentulous area of the cast and tried for aesthetic approval by the patient. (Figure: 15). The removable part of the Andrews Bridge was then fabricated using heat cured polymethylmethacrylate resin. Metal copings were then veneered with ceramic and the whole restoration was finished and polished.

The fixed component of the Andrews system was cemented over the prepared teeth. After one hour, a removable component was inserted and occlusal adjustments were carried out. (Figure: 16) Recall appointment was given after the first day and then after a week. The patient was happy with the aesthetics and functions of the prosthesis and was advised for regular recall visits.

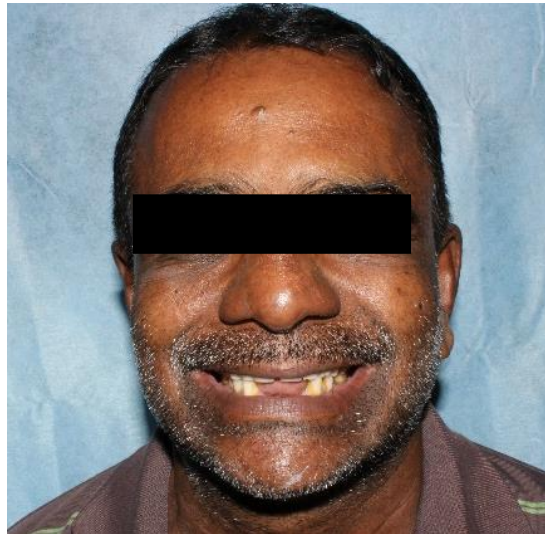


Figure 11: - Preoperative extra oral view.

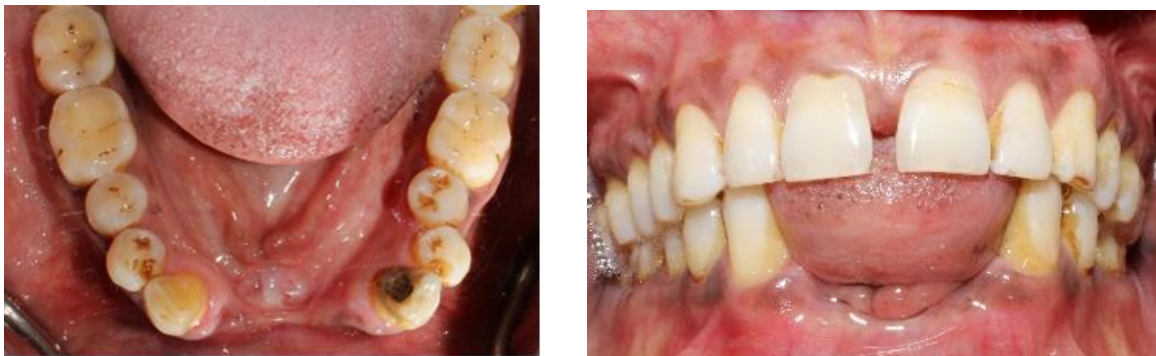

Figure 12: Intraoral pre-operative view

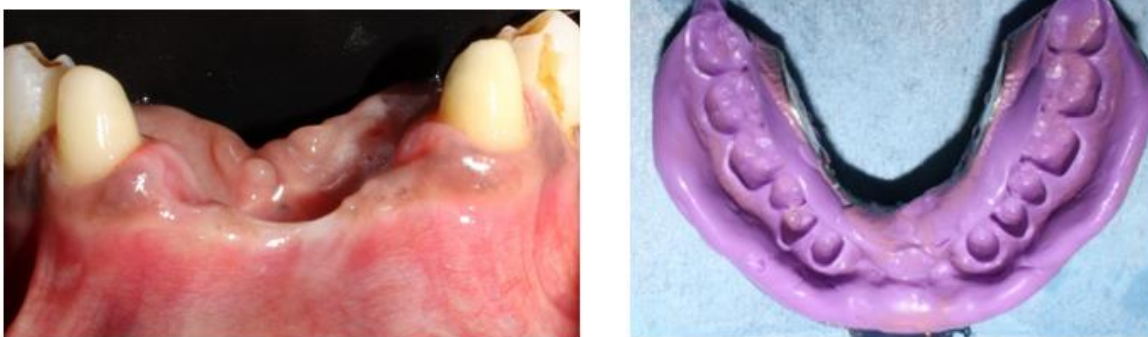

Figure 13: - Tooth preparation of 33 and 43 and Putty light body impression.

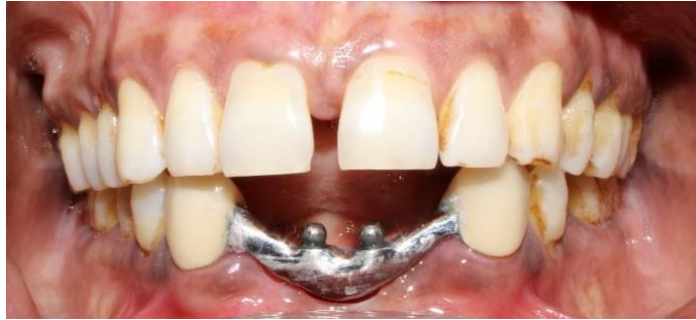

Figure 14: - Metal framework trial

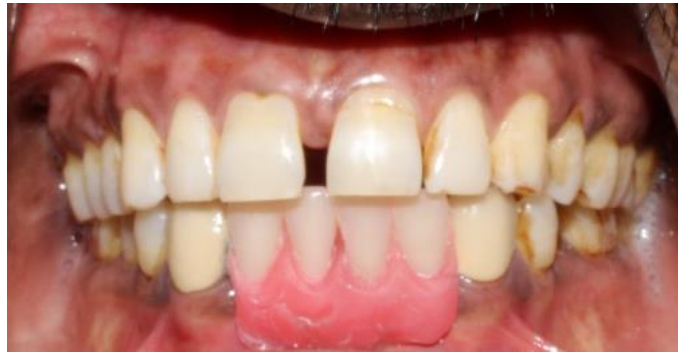

Figure 15:-Wax tryin of the removable component

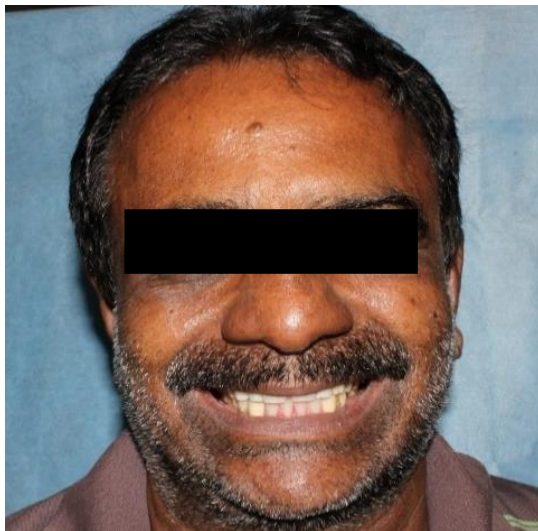


Figure 16: - Post operative extraoral view.

Case Report -3

A 40-year-old male patient reported to department of prosthodontics with a chief complaint of missing mandibular central and lateral incisors (31,32,41,42) which were extracted five years back due to mobility after a road traffic accident. On examination it was observed that mandibular canines were supraerupted and there was a Sieberts Class III defect of the edentulous region (Figure: 17). There was severe bone loss with loss of lower lip support. The defect required a prosthesis which could restore not only the missing teeth but also a large area of supporting structures. The case was planned for esthetic rehabilitation using Andrew's bridge with a bar retainer and a clip attachment for better esthetics and hygiene. A precision fit metal sleeve inserts retentively on the bar.

Both the mandibular left and right canines were endodontically treated and tooth preparation was done on canines to receive a metal ceramic crown and a bar connecting the two abutment crowns. A polyvinyl siloxane impression was made. This whole assembly was then cast into a chromium-cobalt alloy. The prepared and polished metal frame over the canines, attached to a ribbed metal bar, was tried in the patient's mouth to ensure proper fit and clearance between the bar attachment and the underlying soft tissue (Figure: 18, 19). Metal copings were then veneered with ceramic and the whole restoration was finished and polished. The missing teeth were arranged on the wax occlusal rim and aesthetics was evaluated in patient (Figure: 20). The removable part of Andrew's bridge was then made of heat cure polymethyl methacrylate resin. Plastic clip and metal housing were placed on to the cast bar and acrylic resin was packed (Figure: 21). The fixed component of the Andrews system was cemented to the prepared teeth. After 1 hour, the removable component was inserted and occlusal adjustment was performed (Figure: 22). The patient was instructed about the maintenance of the prosthesis and was trained to insert and remove the removable part of Andrews bridge. Patient was recalled after the first day and one week later of delivery. This ribbed bar with plastic clip incorporated in the metal sleeve increase the surface area of contact and ensures good friction fit between the walls of bar and sleeve which enhances the retention of prosthesis.

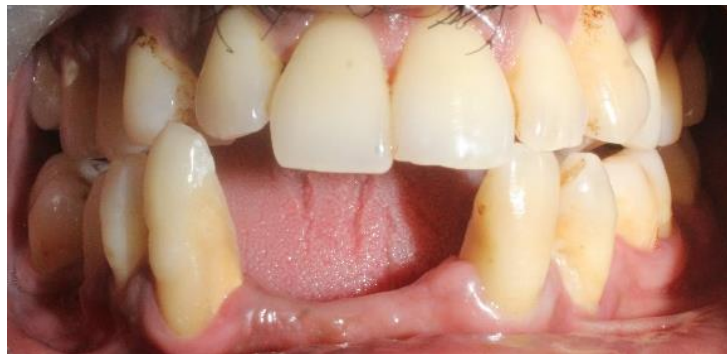

Figure 17: - Pre operative intra oral view

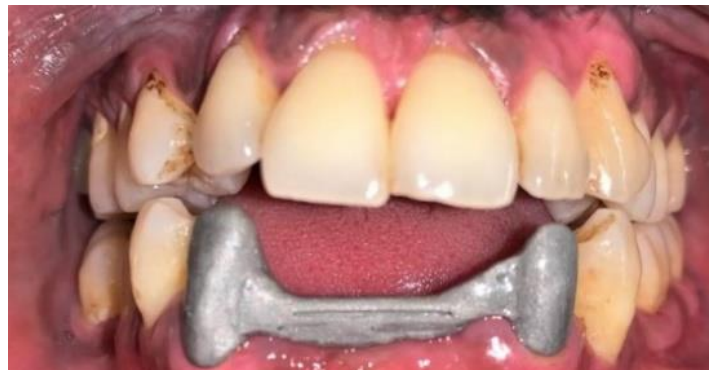

Figure 18: - Metal Try in of Andrews bridge framework after tooth preparation.

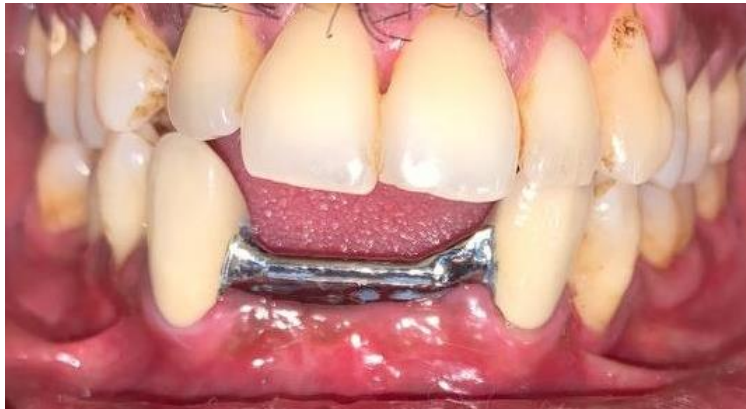

Figure 19: - Try in of fixed component.

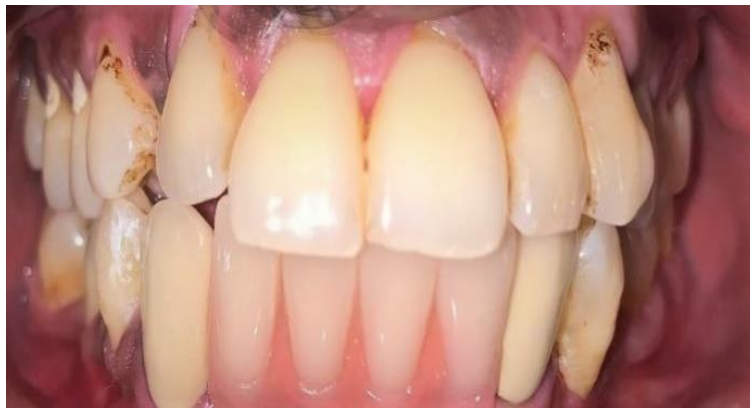

Figure 20: - Teeth setting trial.

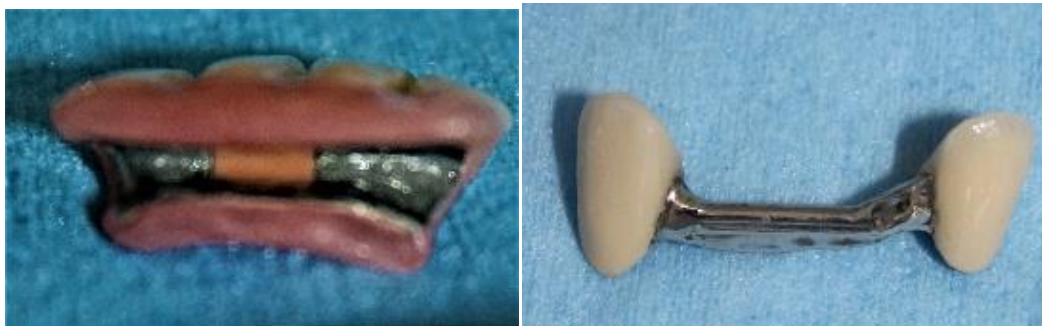

Figure 21: - Ribbed bar and intaglio surface of removable component with metal sleeve and nylon clip.

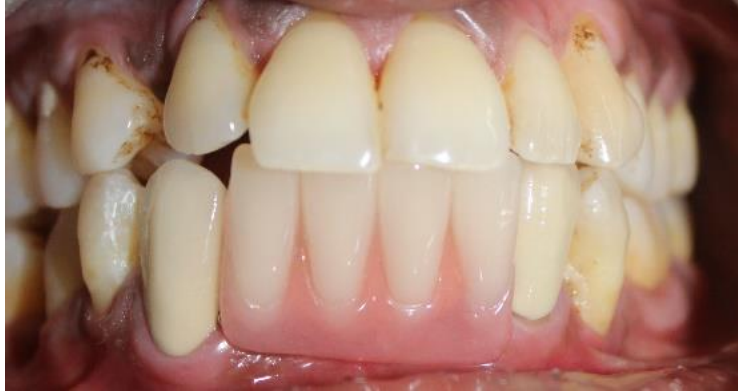

Figure 22: - Post-operative intraoral view.

Discussion

Restoration or rehabilitation of multiple missing teeth with severe bone loss is done on a routine basis with removable partial denture treatment. Mostly in Siebert's class III ridge defect presenting inadequate height and width, removable prosthesis can be used. But these removable prostheses are less retentive, less stable and have poor comfort as compared to fixed prosthesis. Due to this reason, patients prefer fixed prosthesis. But the treatment with fixed prosthesis will have poor long-term prognosis. In such situations, Andrews's bridge system is one of the preferred treatment modalities. Andrews's Bridge system incorporates a removable partial denture of gingival coloured acrylic resin and acrylic denture teeth for the missing dentition. This removable component clips over a bar which connects the Porcelain Fused to Metal (PFM) retainer over the abutment teeth.⁴There are various retentive systems used for Andrews's bridge like bar and sleeve attachment, magnets, ball attachment etc. In bar and sleeve attachment, two types of bars are used, a single bar to use anteriorly and a twin bar for posteriors. These bars are available in three lengths of three different curvatures. Each curve is a segment of a circle and the combinations allow adaptation to most clinical situations. Since the bar formed part of the arc of a circle, it simplifies reconstruction should a patient lose or damage the removable section.

For any given situation, Andrews recommended using the bar with the greatest possible curvature, thereby providing a maximum length and hence more frictional surface and greater wear resistance. It also resulted in a more critical path of insertion that reduced the chance of accidental dislodgement of the prosthesis. As with any bar retained prosthesis the design of the preparation must allow for adequate bulk of metal close to the gingival margin. All types of bar prostheses require a common path of insertion for the fixed section of the restoration, unless an auxiliary system has been incorporated. A shoulder or chamfer preparation adjacent to the bar is recommended, for this will contribute to the strength of the crown margins which are prone to damage under load. For the fabrication of this bar, wax patterns were made for all the prepared teeth and a wax custom bar running over edentulous deficit ridge was connected to this prepared wax patterns.⁵In two of the cases described here, ball type of extra coronal attachment was incorporated into the custom bar. This ball attachment was designed to engage the OT cap in the intaglio surface of the removable component of the fixed removable prostheses. In the third case, bar and sleeve system was used.

The advantages of the Andrews Bridge system are reported widely in literature such as improved aesthetics, better adaptability and phonetics. It is both comfortable and economical for patients. There is no lingual extension as in the case of removable partial dentures. Soft tissue response is also better due to less soft tissue impingement. This type of prosthesis is more retentive and stable with minimal extension. The system avoids unwanted leverage forces to the abutment teeth by acting as a stress breaker. Moreover, reconstruction is simpler if the patient loses or damages the removable section. The disadvantages of this system include the need to frequently remove the prosthesis for cleaning and associated loss of retention of the attachment.

Conclusion

A patient with several missing teeth along with ridge defect in the anterior aesthetic region poses a greater challenge for prosthodontic rehabilitation. Andrews Bridge is an effective and economical treatment modality for patients with pronounced ridge defects. It also possesses excellent properties of both fixed and removable prosthesis which can provide best aesthetic results. The patients treated with the Andrews bar system in this case series were routinely followed up and the patients were found to be comfortable with the prosthesis without any complaints.

Reference

1. Bhapkar. Andrew's Bridge System: An Esthetic Option.
2. Gopi A, Sahoo NK. Andrews Bridge: A fixed removable prosthesis. Journal of Pierre Fauchard Academy (India Section). 2016;30.
3. R C. Prosthodontic Rehabilitation of a Cleft Patient with Andrews Bridge: A Case Report.
4. Prosthodontic Rehabilitation of Anterior Bony Defect with Fixed Removable Bridge System: – A Claspless Approach. J Oral Biol 2016
5. Soni R, Yadav H, Kumar V. Andrew's bridge system: A boon for huge ridge defect in aesthetic zone. J Oral Biol Craniofac Res. 2020;10: 138–40.