



Journal Homepage: -www.journalijar.com

INTERNATIONAL JOURNAL OF ADVANCED RESEARCH (IJAR)

Article DOI:10.21474/IJAR01/19240
DOI URL: <http://dx.doi.org/10.21474/IJAR01/19240>



RESEARCH ARTICLE

UNVEILING VISUAL ACUITY AND INTRAOCULAR PRESSURE SHIFTS AFTER Nd:YAG LASER CAPSULOTOMY FOR POSTERIOR CAPSULE OPACIFICATION

Kamat Vikas V., Wartha Pramod and Paldiwal Shreya A.

Manuscript Info

Manuscript History

Received: 05 June 2024

Final Accepted: 08 July 2024

Published: August 2024

Key words:-

Visual Acuity, Intraocular Pressure,
Nd:YAG Laser Capsulotomy, Posterior
Capsule Opacification

Abstract

Introduction: Posterior capsule opacification (PCO) of the lens is a frequent complication following cataract surgery with intraocular lens implantation, leading to visual decline and symptoms like blurred vision, glare and halos around lights [1]. Nd:YAG laser capsulotomy is a common treatment for PCO, using a laser to create an opening in the opacified lens capsule to restore vision. Although effective, the procedure can cause a transient increase in intraocular pressure (IOP) [3].

Aim: To evaluate visual acuity outcomes and IOP changes following Nd:YAG laser capsulotomy for PCO.

Material and Methods: A prospective cohort study was carried out from December 2022 to June 2024 with 61 eyes of 61 patients posted for Nd:YAG laser capsulotomy, after receiving permission from the Institutional Ethics Committee (IEC) and taking informed written consent from the participating patients. The procedure was performed with standard techniques using Appa YAG Laser Machine Model 307, and patients were followed up at 1 hour, 4 hours, 7 days, 14 days, and 28 days after the procedure. Visual acuity and IOP were monitored, and statistical comparisons were made.

Statistical analysis used: Statistical tests to compare pre-procedure and post-procedure outcomes using paired t-tests and p-value.

Results: Visual acuity improved significantly (p -value < 0.05) from the pre-procedure mean value of 6/60 to 6/9 one month after the procedure. IOP increased transiently, peaking at 20 mmHg in 4 hours post-procedure but returning to baseline levels (15 mmHg) by 28 days. This pattern of transient IOP elevation is consistent with the inflammatory response following the procedure.

Conclusions: Nd:YAG laser capsulotomy improves visual acuity significantly with manageable transient IOP elevations. The procedure has a favorable safety profile, with IOP levels returning to baseline within a month. Ongoing monitoring is crucial to managing any potential complication, and further research with longer follow-up is recommended for a comprehensive understanding of long-term outcomes.

Copy Right, IJAR, 2024.. All rights reserved.

Corresponding Author:-Kamat Vikas V.

Introduction:-

Posterior capsule opacification (PCO) is one of the most common complications following cataract surgery with intraocular lens implantation [1]. The posterior lens capsule behind the Intraocular lens (IOL) may opacify due to proliferation of residual lens epithelial cells post-cataract surgery. This opacification is referred to as 'PCO' or 'secondary cataract' which results in gradual decline in visual acuity leading to symptoms such as blurred vision, glare, and halos around lights [1].

Nd:YAG laser capsulotomy is a minimally invasive technique employed to address PCO. This procedure uses a neodymium-doped yttrium aluminum garnet (Nd:YAG) laser to create an opening in the opacified lens capsule, thereby restoring clear vision. While Nd:YAG laser capsulotomy is highly effective in improving visual outcomes, it can be associated with transient changes in intraocular pressure (IOP), which may have implications for patient management and long-term outcomes [3].

Aims and Objectives:-

The objective is to evaluate the visual acuity outcomes and intraocular pressure changes following Nd:YAG laser capsulotomy for PCO. The study aims to provide a comprehensive understanding of how safe the procedure is and knowing its efficacy.

Material and Methods:-**Study Design:**

A prospective cohort study was conducted at a tertiary care center in the tribal area of Maharashtra from December 2022 to June 2024. The research was carried out after the approval of the Institutional Ethics Committee (IEC). Informed written consent documents were taken from all the participating patients before including them in the study.

Study Population:

The study consisted of 61 patients i.e. 61 eyes who were diagnosed with PCO and without any other complication of cataract surgery and with normal posterior segment, who were scheduled for Nd:YAG laser capsulotomy.

Procedure:

Nd:YAG laser capsulotomy procedure was performed with standard technique with Appa YAG Laser Machine Model 307. The procedure involved directing a laser beam through the dilated pupil to fragment and remove the opacified capsule.

Post-procedure follow-up: Patients were followed-up at 1 hour, 4 hours, 7 days, 14 days and 28 days post-procedure to assess the response to the procedure, including checking for any signs of inflammation, IOP changes, visual acuity changes, or any complications. IOP was measured with an Applanation tonometer. Visual acuity was measured as best-corrected visual acuity (BCVA) using the Snellen Chart.

Statistical Analysis:

Statistical tests to compare pre-procedure and post-procedure outcomes, using paired t-tests with a p-value of < 0.05 is taken as significant.

Results:-**Visual Acuity Outcomes:**

Visual acuity improved significantly (p-value<0.05) from a pre-procedure mean value of 6/60 to a post-procedure mean value of 6/9 one month after the procedure.

Pre-procedure IOP:

The mean pre-procedure intraocular pressure (IOP) was 15 mmHg, with a range from 10-18 mmHg. This baseline measurement helps contextualize the procedural impact on IOP.

Immediate Post-procedure IOP:

1 Hour Post-procedure IOP: In 1-hour post-procedure, the mean IOP was 18 mmHg. This early measurement reflects the immediate response of the eye to the laser procedure and is often higher due to the acute inflammatory reaction and laser-induced debris.

4 Hours Post-procedure IOP: The mean IOP at 4 hours was 20 mm Hg. The IOP tends to peak shortly after the procedure due to ongoing inflammatory responses and is generally monitored closely during this period.

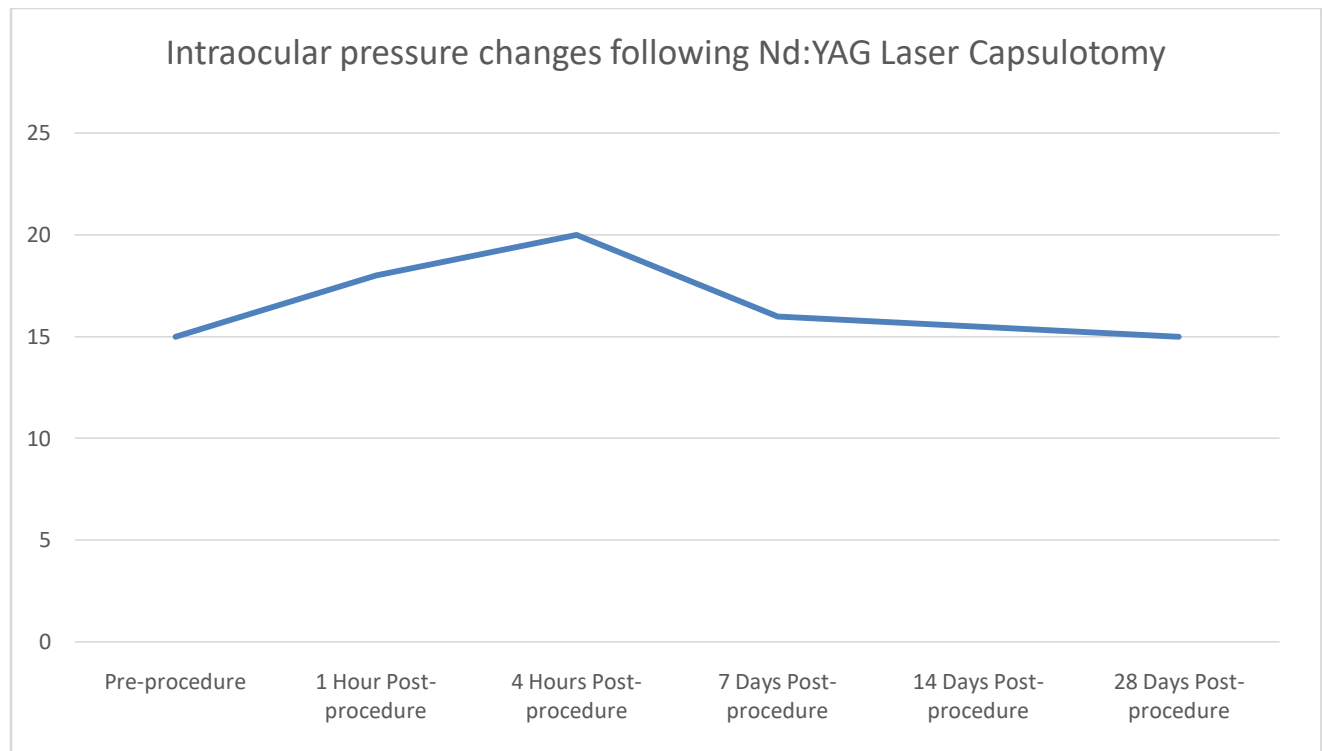
1 Day Post-procedure IOP: On 1-day post-procedure, the mean IOP returned to normal and was 17 mmHg.

7 Days Post-procedure IOP: On the 7-day follow-up, the mean IOP was 16 mm Hg. By this time, any acute inflammatory response starts to subside, and the IOP typically begins to stabilize.

14 Days Post-procedure IOP: The mean IOP at 14 days was 15.5 mm Hg. IOP levels usually start to return to baseline levels during this period, as inflammation continues to resolve and aqueous humor dynamics normalize.

28 Days Post-procedure IOP: On 28 days post-procedure, the mean IOP was 15 mmHg. By this time, IOP is generally stable and comparable to preoperative levels, indicating that the temporary elevation observed immediately after the procedure has been resolved.

Time Point	Mean IOP (mm Hg)
Pre-procedure	15
1 Hour Post-procedure	18
4 Hours Post-procedure	20
7 Days Post-procedure	16
14 Days Post-procedure	15.5
28 Days Post-procedure	15



Discussion:-

Visual Acuity Outcomes:

The significant improvement in visual acuity calculated as best-corrected visual acuity (BCVA) following Nd:YAG laser capsulotomy is consistent with numerous studies demonstrating the effectiveness of this procedure. The results showed marked enhancement in BCVA from a mean pre-procedure value of 6/60 to a post-procedure mean of 6/9 one month after the procedure. The study by Aron-Rosa et al. reported similar visual outcomes with a notable improvement in BCVA in the majority of the patients following Nd:YAG laser capsulotomy [4]. Their findings underscored that the procedure restores vision effectively, aligning with our results, which showed sustained improvements over the 1-month follow-up period.

In addition, the observed visual improvement is consistent with research by Bhargava et al. who highlighted that Nd:YAG laser capsulotomy provides a reliable method for visual rehabilitation, especially when PCO significantly

impairs vision [7]. The improvement in BCVA noted in our study is indicative of the procedure's success in addressing the opacified capsule, thus resolving the visual degradation caused by PCO.

Intraocular Pressure Changes:

Immediate Postoperative IOP Elevation:

The peak in IOP observed at 1 hour and 4 hours post-procedure is largely due to the inflammatory response induced by the laser procedure. The Nd:YAG laser capsulotomy causes localized tissue trauma, which can lead to increased aqueous humor production and decreased outflow, resulting in elevated IOP. Rathod et al. emphasize that this acute response is typical and generally self-limiting [3].

Short-Term Trends:

By 7 days post-procedure, the mean IOP begins to decrease as inflammation starts to subside. This is in line with findings from Keates et al. who noted a gradual return to baseline IOP levels as the postoperative inflammatory response resolves. This period is crucial for monitoring to ensure that IOP levels are stabilizing and not remaining elevated [2].

Medium to Long-Term IOP Stability:

The stabilization of IOP at 14 days and 28 days post-procedure reflects the resolution of transient inflammation and the normalization of aqueous humor dynamics. The IOP levels returning to baseline or near-baseline values by 28 days confirms that the Nd:YAG laser capsulotomy has a generally favorable impact on IOP, with transient increases that do not result in sustained elevation as quoted by Ge et al[5].

Clinical Implications:

The transient nature of IOP rise following Nd:YAG laser capsulotomy highlights the importance of close monitoring during the early postoperative period. Routine IOP measurements at 1 hour, 4 hours, 7 days, 14 days, and 28 days are essential to detect and manage any significant changes. This approach ensures that any postoperative complications, such as persistent IOP elevation are identified and treated promptly if required [6].

Complications:

The minor complications observed, such as transient inflammation and elevated IOP, are consistent with the safety profile reported in previous studies. Shah et al. conducted a comprehensive review of Nd:YAG laser capsulotomy and found that while the procedure is generally safe, minor complications such as mild inflammation and short-term IOP elevation are not uncommon [2]. These findings are corroborated by our study, which observed these effects in a small percentage of patients but did not encounter severe complications [2].

Our study's observation of manageable complications reinforces the safety profile of Nd:YAG laser capsulotomy as detailed in the literature. The incidence of such complications is generally low, and with proper post-procedural care, they can be effectively managed, supporting the procedure's overall safety and efficacy.

Limitations and Future Directions:

The limitations of the study include a relatively short period of follow-up and a single-center design, which may affect generalizability.

Further studies with extended follow-up and larger sample sizes could provide more comprehensive insights into the long-term effects of Nd:YAG laser capsulotomy on IOP and visual acuity outcomes.

Conclusion:-

The study concludes that the visual acuity increases significantly after the procedure. The transient rise in IOP following Nd:YAG laser capsulotomy is a well-recognized phenomenon that typically resolves within a month. The results of the study are seen to be aligned with existing literature, which indicates that while temporary IOP elevation is common, it generally does not lead to long-term complications if managed appropriately. Ongoing monitoring and management are essential to ensure that IOP levels normalize and to address any persistent elevations promptly. This approach helps to maintain the safety and efficacy of Nd:YAG laser capsulotomy, reinforcing its role as a valuable treatment option for posterior capsular opacification.

Acknowledgement:-

The authors would like to acknowledge the efforts of all the staff members of the Ophthalmology Department of the hospital and the patients involved in the study.

References:-

- 1) Vivekanandan, V. R.; Jezeela, K.; Odayappan, A.I. Recurrent posterior capsule opacification in an adult. Kerala Journal of Ophthalmology 36(1):p 59-61, Jan–Apr 2024. | DOI: 10.4103/kjo.kjo_8_21
- 2) Joshi, R. S., & Doble, P. (2023). The complication rate following Neodymium-doped Yttrium Aluminum Garnet laser posterior capsulotomy for posterior capsular opacification in patients with and without comorbidities. Indian journal of ophthalmology, 71(3), 791–796. https://doi.org/10.4103/ijo.IJO_1885_22
- 3) Rathod Darshana, Intraocular Pressure Variation After Nd:YAG Laser Posterior Capsulotomy IJSR 2016:5(12):43-7.
- 4) Karahan, E., Er, D., & Kaynak, S. (2014). An Overview of Nd:YAG Laser Capsulotomy. Medical hypothesis, discovery & innovation ophthalmology journal, 3(2), 45–50.
- 5) Parajuli, A., Joshi, P., Subedi, P., & Pradhan, C. (2019). Effect of Nd:YAG laser posterior capsulotomy on intraocular pressure, refraction, anterior chamber depth, and macular thickness. Clinical ophthalmology (Auckland, N.Z.), 13, 945–952. <https://doi.org/10.2147/OPHTH.S203677>
- 6) Shetty, N. K., & Sridhar, S. (2016). Study of Variation in Intraocular Pressure Spike (IOP) Following Nd- YAG Laser Capsulotomy. Journal of clinical and diagnostic research: JCDR, 10(12), NC09–NC12. <https://doi.org/10.7860/JCDR/2016/21981.9037>
- 7) Bhargava, R., Kumar, P., Prakash, A., & Chaudhary, K. (2012). Estimation of mean Nd:YAG laser capsulotomy energy levels for membranous and fibrous posterior capsular opacification. Nepalese Journal of Ophthalmology, 4(1), 108–113. <https://doi.org/10.3126/nepjoph.v4i1.5861>.