



Journal Homepage: -www.journalijar.com

INTERNATIONAL JOURNAL OF ADVANCED RESEARCH (IJAR)

Article DOI:10.21474/IJAR01/19244
DOI URL: <http://dx.doi.org/10.21474/IJAR01/19244>



RESEARCH ARTICLE

COMPARATIVE EVALUATION OF PREFORMED STAINLESS STEEL CROWNS AND PREFABRICATED ZIRCONIA CROWNS FOR RESTORING ENDODONTICALLY TREATED PRIMARY MOLARS

Dr. Divya Vyas¹, Dr. I.K. Pandit², Dr. Neeraj Gugnani³ and Dr. Monika Gupta⁴

1. Reader, Department of Pedodontics and Preventive Dentistry, Himachal Institute of Dental Sciences, Paonta Sahib, Himachal Pradesh.

2. Principal, Professor and HOD, Department of Pedodontics and Preventive Dentistry, D.A.V.(C) Dental College and Hospital, Yamunanagar, Haryana.

3. Professor, Department of Pedodontics and Preventive Dentistry, D.A.V.(C) Dental College and Hospital, Yamunanagar, Haryana.

4. Professor, Department of Pedodontics and Preventive Dentistry, D.A.V.(C) Dental College and Hospital, Yamunanagar, Haryana.

Manuscript Info

Manuscript History

Received: 05 June 2024

Final Accepted: 08 July 2024

Published: August 2024

Abstract

Objectives: This study was designed to evaluate preformed stainless steel crowns and prefabricated zirconia crowns for restoring endodontically treated primary molars.

Material and Methods: A total of 24 patients between the age group of 5-10 years having atleast a primary first or second maxillary or mandibular molars affected with caries requiring endodontic treatment followed by extracoronary restoration by preformed Stainless steel crown (group no. I consisting of 12 teeth) or Zirconia crowns (group II consisting of 12 teeth) for esthetics and function were included in the study. Following which, clinical photographs and intra oral periapical radiographs were taken and parents accompanying the patient were asked to score the satisfaction score. Patients were recalled after 1 week, 3 months and 6 months from the day on which the final crown placement was done.

Results: Considering the clinical and radiographic success rates at the end of 6 months, non-statistically significant differences were found between the two groups ($p=1.000$ and $p=1.000$ respectively) using Chi-square test.

Conclusion: It can be concluded from our study that both Zirconia crowns and Stainless steel crowns can be effectively used as extracoronary restorations in primary posterior endodontically treated teeth. In terms of retention, marginal adaptation, occlusion and gingival health both the crowns exhibited non-significant differences. However, zirconia crowns provided good esthetics and significantly better parental satisfaction scores. Thus, either of the crowns can be used for restoring such teeth, but whenever esthetic concerns surpass, zirconia crowns seem to be a preferred alternative.

Copy Right, IJAR, 2024.. All rights reserved.

Introduction:-

Caries is a biofilm (plaque)-induced acid demineralization of enamel or dentin, mediated by saliva. Worldwide, the contribution of dental caries to the burden of oral diseases is about 10 times higher than that of periodontal disease

Corresponding Author:-Dr. Divya Vyas

Address:-Department of Pedodontics and Preventive Dentistry, Himachal Institute of Dental Sciences, Paonta Sahib, Himachal Pradesh.

and the other common oral conditions.² Owing to its globally high prevalence, dental caries in children has been described as a 'pandemic' disease.³

Children in the age range of 12–30 months have a special caries pattern that differs from that in older children and is frequently called as "early childhood caries (ECC)", "bottle caries," "nursing caries," "baby bottle tooth decay," or "night bottle mouth".⁴

It is a complex disease, which involves maxillary primary incisors within a month after eruption and spreads rapidly to involve the other primary teeth.⁵

Patients with early childhood caries may also exhibit the involvement of various teeth at different stages of this disease process, that is, teeth may show signs ranging from small, chalky white de-mineralization (Stage 1) to deep cavitated lesions (Stage 2/3) or carious broken down teeth (Stage 4). Such patients should be managed in a comprehensive manner with the treatment being imparted according to the stage of the lesion. AAPD (American Academy of Pediatric Dentistry) (2011)⁶ guidelines stated that along with diet and behavior modification, small carious lesions shall be managed using interim therapeutic restorations (ITR) with material such as glass ionomers that release fluoride, while for large carious lesions appropriate endodontic treatment like pulpotomy or pulpectomy should be imparted.⁶

After appropriate pulp therapy, the primary tooth should be restored to the original dimensions using intracoronal and extracoronal restorative options. Common restorative materials used for restoring primary posterior teeth include amalgam, miracle mix, conventional glass ionomer cements (GICs), resin modified GIC, compomer, composites, open-faced stainless steel crowns, pre-veneered stainless steel crowns, strip crowns and stainless steel crowns.^{7,8} Among these, AAPD guidelines recommend the use of stainless steel crowns to restore the teeth with large carious lesions.⁹

A Stainless Steel crown is an extracoronal restoration that not only replaces the tooth to its original dimension but also has been reported to provide similar life span as that of an intact primary tooth besides providing protection to the residual tooth structure that may have been weakened after excessive caries removal.¹⁰ The Stainless Steel crowns (Chrome steel crowns) were introduced in 1947 by the Rocky Mountain Company and were popularized by Humphrey in 1950. They are mainly composed of about 18% chromium and 8% nickel as well as small amounts of other elements and are considered as 18-8 stainless steel.¹¹

Despite the favorable qualities mentioned, Stainless Steel Crowns have a major drawback of poor esthetic appearance. With the world becoming more and more esthetics conscious, there is a growing demand for tooth colored esthetic crowns.

In yester years, many esthetic alternatives to Stainless Steel Crowns have been developed which include namely open-faced crowns; bonded strip crowns; and pre-veneered SSCs etc.⁸

Recently, esthetically pleasing tooth colored Zirconia Crowns that have shown good results in adult dentistry have been introduced for restoration of primary teeth as the pediatric patient group has also become a part of the esthetically demanding patient group.

Zirconia crown exhibit a pleasing appearance like a natural tooth. They are biocompatible and have the highest strength than any of the pediatric crown types. Zirconia esthetic crowns for primary teeth were introduced by EZ Pedo (Loomis, California, USA.) in the year 2010, and are now commercially available through various manufacturers like EZ Pedo, Cheng Crowns, Kinder Crowns, Kids crowns and NuSmile Pediatric Crowns.¹²

Despite some disadvantages like the need to prepare the tooth to fit the crown rather than adjusting the crown to fit the preparation, inability to crimp the crowns for tight marginal seal, and high cost, Zirconia Crowns are likely to make a very popular restorative option for Primary teeth owing to their excellent esthetics and high strength.

There is a paucity of literature to show the clinical performance of Zirconia Crowns when used over endodontically treated primary posterior teeth. Few case reports have been published showing the success of zirconia crowns in

posterior teeth but to our knowledge there is no randomised control trial comparing the success of zirconia crowns with conventional stainless steel crowns.

With such limited knowledge, the present randomized clinical study was planned to evaluate the success of Zirconia crowns and Stainless steel crowns for restoring endodontically treated primary molars using various clinical and radiographic parameters.

Material and Methods:-

Ethical approval was sought from the Institutional Ethical Committee of J.N. Kapoor D.A.V. (C) Dental College, Yamunanagar and the Board of Studies, Pt. B.D. Sharma University of Health Sciences, Rohtak for conducting the study. This 2-arm parallel, randomized control trial was conducted to evaluate the clinical efficacy of Preformed Stainless Steel crowns and Prefabricated Zirconia crowns.

Post-operative evaluation was done in terms of crown retention, marginal adaptation, occlusion, proximal contact, crown adequacy, interproximal bone level, effect on gingival and periodontal health of the tooth, oral hygiene of patient, parent satisfaction and patient's comfort.

Inclusion Criteria:

Children in the age group of 5-10 years having pulpally involved teeth requiring endodontic treatment and an extracoronary restoration were included. Teeth showing signs and symptoms of pulpally involved (limited to coronal pulp) and indicated for pulpotomy, or extending to radicular pulp and indicated for pulpectomy) were included. Teeth with contralateral tooth free of caries or undergone proper restoration were included. Teeth with normal interproximal bone level (i.e. the distance between the crest of interdental bone and cementum-enamel junction should not be greater than 2 mm on radiographic evaluation) were included. Teeth with at least two third of the root present and children whose parents gave informed consent for participation in the study were included.

Exclusion Criteria:

Patients scoring definitely negative on Frankel's behavior rating scale, children with systemic diseases, allergy to any drug or material for e.g. Local anaesthetic agent, Nickel or any other restorative material to be used in the study, extremely poor oral hygiene, periodontal disease, severe malocclusion, submerged teeth, teeth with mobility, children with bruxism, any relevant medical history or long term medication that restricts dental treatment, children with special needs, pulpally involved teeth showing any signs and symptoms of furcal involvement / periapical radiolucency / swelling / associated sinus or fistula, teeth showing any sign/symptom of periapical pathology indicative of extraction, non-consent of the parents to participate in the study were included in the exclusion criteria.

A total of 24 patients were finally selected according to the calculation power of the study and who fulfilled all the above-mentioned criteria. The teeth included in this study were called as samples (n).

Preoperative Recording

Baseline data was recorded in the clinical record form and along with this the clinical photograph and pre-operative intraoral periapical radiographs were taken.

The selected teeth were then randomized into 2 equal groups treated with either of the following crown options:

Group 1 – Preformed Stainless steel crowns (number of patients=12)

Group 2 – Prefabricated Zirconia crowns (number of patients=12)

Randomization codes were generated using computer software. A Permuted block randomization scheme was used with a block size of 4 and allocation concealment was done by sealing the envelopes. Thus, a total of 24 selected teeth were divided into 2 groups with 12 teeth each.

Group 1

This group consisted of 12 samples which were restored using Preformed Stainless Steel Crowns.

Group 2

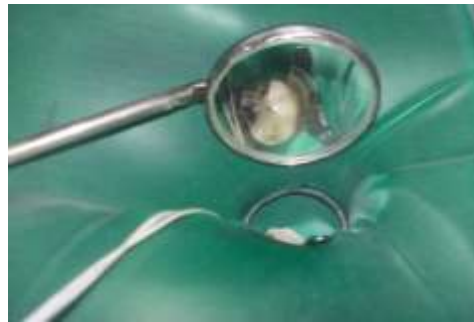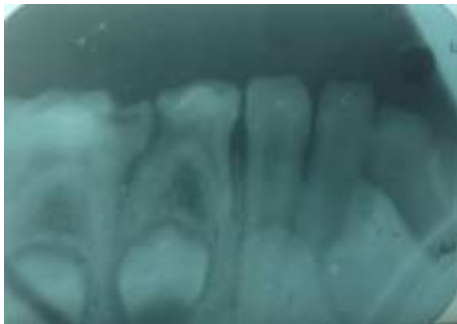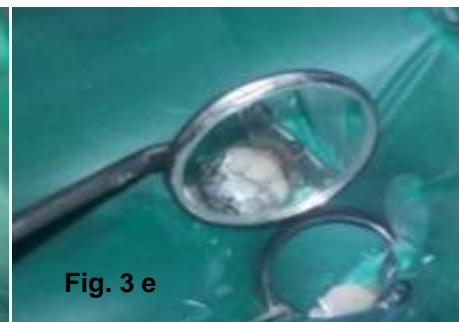This group consisted of 12 samples which were restored using Prefabricated Zirconia Crowns.

Clinical Procedure

After the selection of teeth, either pulpotomy or pulpectomy was performed as per the requirement of the particular tooth using standard protocol. The details of the clinical procedure are as below:

Pulpotomy

Topical anaesthesia was applied, followed by Local anaesthesia administration using 2% Lignocaine Hydrochloride with adrenaline (1:80000). Isolation of the cavity was done using rubber dam (Fig3a, 3b). The access opening was made with a round bur (Fig3c). Roof of the pulp chamber was removed and the necrotic coronal pulp tissue present in the chamber was removed using a sterile spoon excavator. The hemorrhage was controlled by placing a sterile, saline-wetted cotton wool pellet on the radicular pulp stumps with slight pressure. After primary hemostasis was achieved, removal of blood clot remnants and drying of the cavity with a cotton pellet was carried out. At this stage complete hemostasis was achieved.

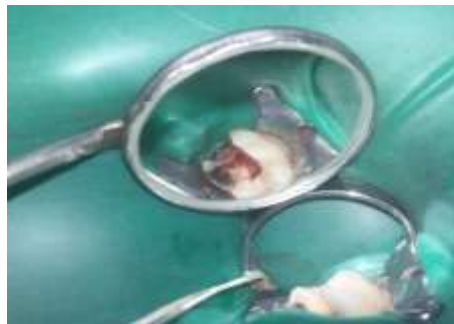
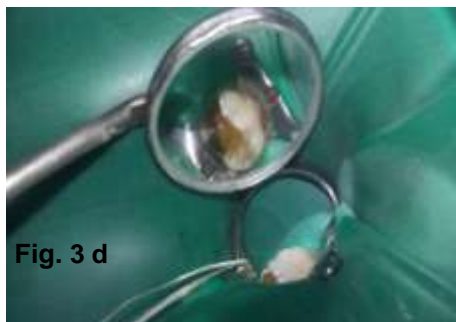
**Fig.3 a****Fig. 3 b****Fig. 3 c****Fig. 3 d****Fig. 3 e**

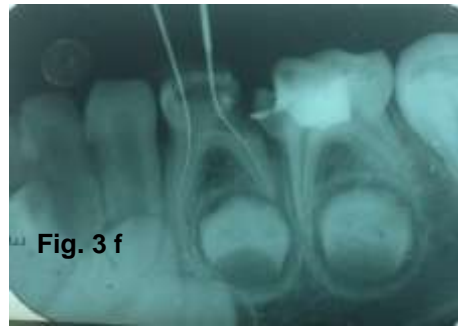

Fig. 3 f

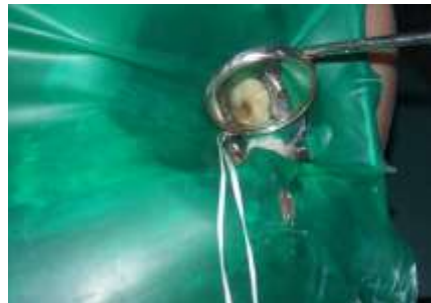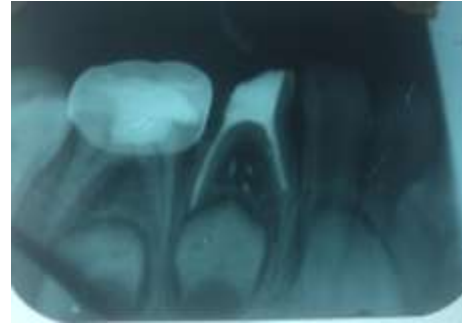

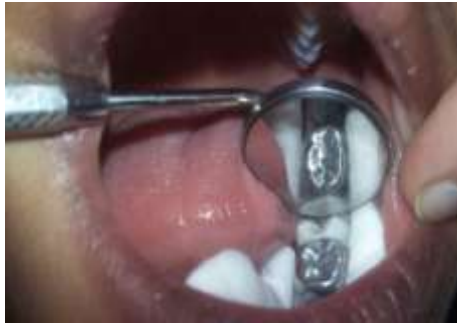
Fig. 4 a

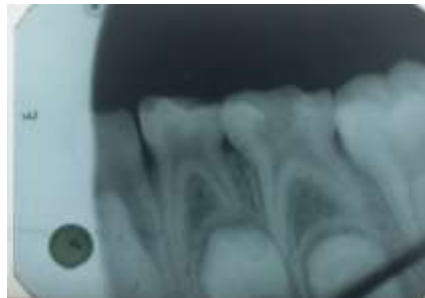

Fig. 4 b

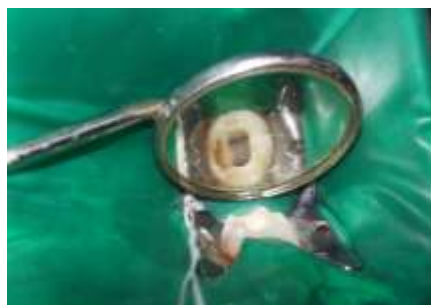

Fig. 4 c

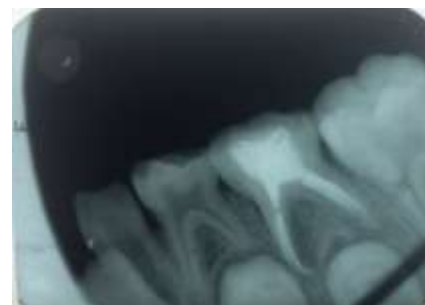

Fig. 4 d

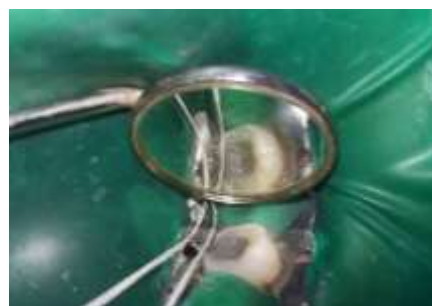

Fig. 4 e

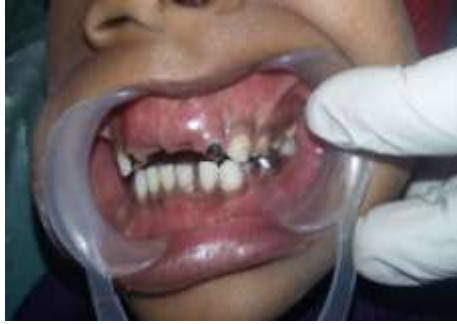

Fig. 5c

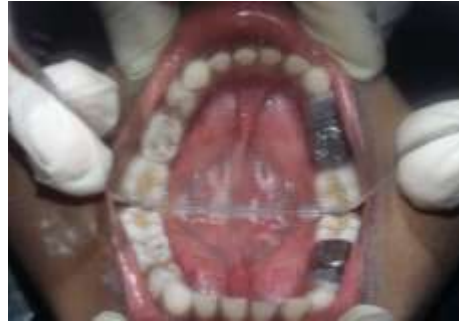

Fig. 5d

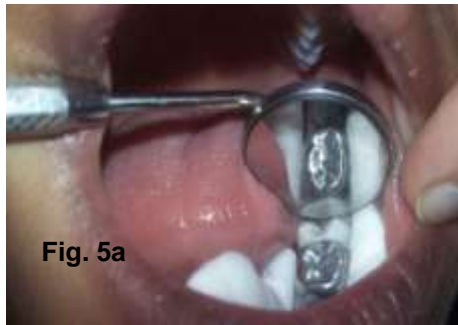

Fig. 5a

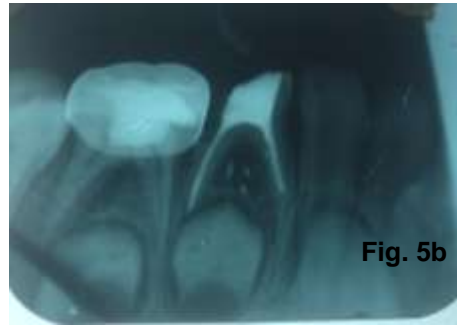


Fig. 5b

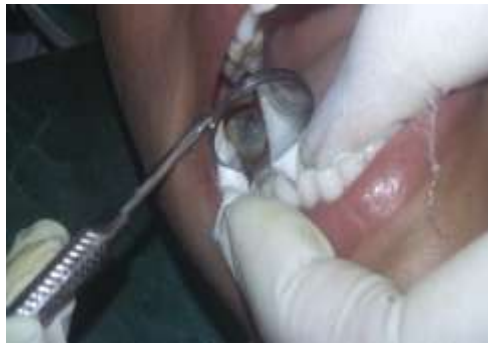

Fig. 6 a

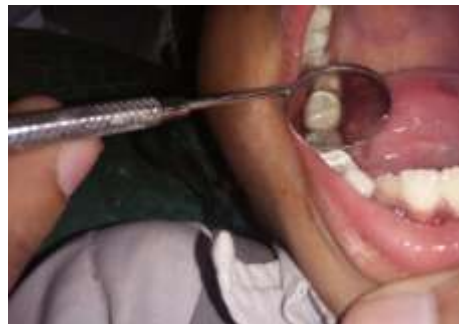

Fig. 6b

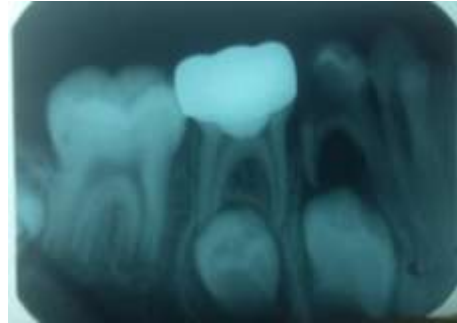


Fig. 6c

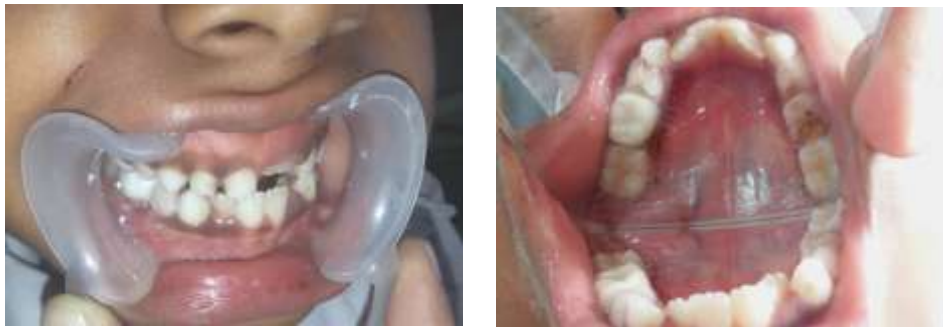

Fig. 6d:-Fig 6 e:-

A cotton pellet moistened with 15.5% Astringent ferric sulphate was placed in contact with the radicular pulp for 15 seconds. (Fig 3d) Then the pellet was removed and irrigation with normal saline was carried out which was followed by placement of temporary zinc oxide eugenol restoration. (Fig 3 e)

Recall

Patient was recalled after 1 week and if the patient was asymptomatic permanent restoration was placed with miracle mix. (Fig 3 f)

Pulpectomy

Topical anaesthesia was applied followed by local anaesthesia administration using 2% Lignocaine hydrochloride with adrenaline 1:80000. Isolation of the cavity was done by using rubber dam (Fig 4a, 4b). Access opening was done with a round bur (Fig 4c) mounted on a high speed handpiece with adequate cooling. After which the roof of the pulp chamber was removed and the necrotic pulp tissue present in the chamber was removed using sterile spoon excavator. Following which irrigation was done using normal saline. The chamber was then dried using cotton pellet. The cotton pellet was removed and the canal orifice were located. Root canals of the sample tooth were negotiated and all the radicular necrotic pulp tissue was removed using barbed broaches. The root length of the canals was determined using a diagnostic IOPA radiograph. A rubber stop was placed approximately 2-3 mm short of radiographically determined length on the first file that bind into the canal. Each canal was enlarged to two or three instrument sizes greater than the first file that bind the canal. Copious irrigation with normal saline was carried out between the use of each instrument in order to remove debris. After this the canal was dried with sterile paper points, followed by obturation with a biocompatible, resorbable, root canal filling material, keeping the obturation 2-3 mm short of the radiographic apex (Fig 4d). The pulp chamber was then filled with zinc oxide eugenol. Patient was recalled after 1 week and if found to be asymptomatic, permanent restoration was placed with miracle mix.

Extracoronary restoration of teeth included in various groups-

After one week, extracoronary restoration of the selected endodontically treated sample teeth was done in accordance to the group allotted after randomization.

For Group 1- Preformed Stainless Steel Crown

Preformed Stainless steel crown was placed on the endodontically treated tooth following the standard procedure. The steps are explained as below:

Preparation of the tooth:

Effective topical local anesthetic was administered. Occlusal reduction following the occlusal anatomy and the principles of tooth preparation was carried out to obtain the occlusal clearance of approximately 1.5 mm. The preparation was compared with the occlusal height of the neighboring teeth. The mesial and distal contact points were cleared and a smooth taper of <6 degrees from occlusal to gingival region was obtained that was free of ledges or shoulders. All caries was removed and the line angles were rounded off. The gingival finishing line was a feather edge with no detectable ledges or steps. Less preparation was needed on the buccal or lingual surfaces of primary teeth. The finishing line on all the surfaces was kept approximately 1 mm below the gingival margin.

Selection of proper crown size

The mesial-distal width between the contact points of the teeth adjacent to the sample tooth with calipers was recorded to aid in selecting the correct sized crown. Once the correct size was established, the external diameter of crowns in kit was measured to verify the dimensions so that they are equal to that of the original tooth. If teeth mesial or distal to the sample tooth were missing, the mesio-distal width of the same contralateral tooth was measured. The smallest crown that fitted was selected.

Seating and Trimming the crown

Initially the selected stainless steel crown was seated on the prepared tooth and the gingival margins were checked for any blanching. If any blanching was seen the excess crown margin from that area was trimmed. The occlusion was checked and the crown was removed with a crown remover. Trimming was done with crown scissors or with an abrasive wheel. After trimming, the crown had a larger cervical opening. Festooning of the crown was done which involves making a smile shape cervical margin on the buccal and lingual aspects and frown shaped in all the proximal aspects of all primary molars. Next step included crimping of the crown to regain its retentive contour, i.e. "snap fit". Once the adjustments were completed the crown margins were thinned slightly and smoothed with a large "heatless" stone. Final polishing was done with a rubber wheel.

Crown Cementation

Reinforced Glass Ionomer 3M™ ESPET™ RelyX™ Luting Cement was used for cementation of the crown. Powder and liquid were dispensed on a mixing pad using the standard powder/liquid ratio of 1.6:1 by weight by taking three level scoops of powder and 3 drops of liquid which provided an adequate amount of material to seat one typical crown. All the powder was mixed into the liquid in about 30 seconds using a cement spatula. Working time of the standard powder/liquid ratio was at least 2.5 minutes from the start of mix at a room temperature.

Crown placement:

The crown was loaded by spreading a layer of the cement over all the interior surfaces of the crown. For seating the crown on the prepared tooth, it was first placed lingually and rolled over the preparation to the buccal margin. The crown made an audible "click" as it spring into place over the gingival undercut area. Firm pressure was needed to seat the crown. The marginal gingiva blanched somewhat with a well-fitting crown as it seated. The crown margins were located approximately 1 mm sub-gingivally.(Fig 5a,5b)

Pressure was maintained on crown to maintain position during setting process. Excess material was removed with a scaler or explorer, and knotted dental floss was used interproximally to remove the excess cement when cement reached a waxy stage after a minimum of 3 minutes from placement in the mouth (37°C or 98°F). Following removal of excess cement final fit and occlusion was checked.(Fig 5c,5d)

For Group 2-Prefabricated Zirconia Crowns

Prefabricated Zirconia crown was placed on the endodontically treated tooth as per random allocation, following all the manufacturer's instructions. The steps are explained as below:

Selection of proper crown size

Effective topical local anesthetic was administered. The mesial-distal distance at the contact points of the teeth adjacent to the selected tooth were recorded using calipers. This helped to choose the crown size that looked most natural in the child's mouth.

Preparation of the Tooth crown(Fig 6 a)

1. Occlusal, proximal and supragingival reduction

The occlusal surface was reduced following the natural occlusal contours by approximately 1-1.5mm using a coarse football diamond bur. The interproximal contacts were opened using wedges as tooth separators to allow the selected crown to fit passively. Following which the tooth was reduced circumferentially by approximately 20-30%, or 0.5-1.25mm using coarse tapered diamond or carbide burs.

2.Subgingival reduction

The preparation margin was carefully extended and refined to a feather-edge approximately 1-2mm subgingivally on all surfaces using a thin, tapered diamond bur.

3.Completing the preparation

Line angles and point angles were rounded. The tooth was checked again for sufficient occlusal clearance with the opposing teeth.

Adjusting the Crown

Using the Adjustment Burs circumferential reduction was done and feather edge crown margins were prepared while shortening posterior ZR Crown wherever it was necessary. Crown polishers were used to restore a smooth surface to the crown. If occlusion was high, crown was trimmed according to the manufacturer's instructions. If the high occlusion did not get relieved even after crown trimming, the opposite tooth was adjusted as necessary.

Crown placement and Cementation

The same luting agent as used for stainless steel crowns was used for the purpose of cementation of the Zirconia crown. The mixing of the luting cement was done as per the manufacturer's instructions and crown was cemented in a similar manner as explained in Group I. (Fig 6 b,6 c)

Immediate Post-Operative Assessment

After the extra coronal restorations, clinical photographs and intra oral periapical radiograph were taken and parent accompanying the patient was asked to score the satisfaction as per the Likerts scale.

Post-Operative Assessment on Different Recalls

Patient was recalled after 1 week, 3 months and 6 months from the day, the final crown placement was completed. During these visits post operative clinical evaluation of the restored teeth was done in terms of crown retention, marginal adaptation, occlusion and whether the treated tooth got exfoliated or not. These parameters were recorded and the effect of crown placement on the gingival health of the sample teeth was recorded using Loe and Silness Gingival index at 1 week,3 months and 6 months. Radiographic evaluation of crown adaptation and interproximal bone level were recorded at 6 months using categorical scale.

Results:-

Twentyfour teeth, 12 in each group, were examined for 6 months. . All teeth of both groups were clinically checked at 1 week, 3 months and 6 monthstime interval. And they were radiographically checked at 6 months time interval. Postoperative clinical examinations are shown in Table 1 and post operative radiographic examinations are shown in Table 2.

Clinical Parameters (Table 1)

		Stainless steel	Zirconia	Stainless steel	Zirconia	Stainless steel	Zirconia
Crown retention	A	12	12	12	12	12	12
	B	0	0	0	0	0	0
P value		1.000		1.000		1.000	
Occlusion	A	10	1	10	11	10	1
	B	2	1	2	1	2	1
	C	0	0	0	0	0	0
PValue		0.537		0.537		0.537	
Marginal adaptation	A	11	10	11	10	10	11
	B	1	2	1	2	2	1

P value		0.307		0.307		0.307	
Gingival health	0	12	12	11	11	11	11
	1	0	0	1	1	1	1
	2	0	0	0	0	0	0
	3	0	0	0	0	0	0
P value		1.000		1.000		1.000	
Crown retention	A	0	0	0	0	0	0
	B	12	12	12	12	12	12
P value		1.000		1.000		1.000	

Radiographic Parameters(6 months)(Table 2)

		Stainless steel	Zirconia
Crown adaptation	A	12	12
	B	0	0
Pvalue		1.000	1.000
Interproximal bone level	A	12	12
	B	0	0
P value		1.000	1.000

Discussion:-

Caries is a biofilm (plaque)-induced acid demineralization of enamel or dentin, mediated by saliva.¹ Worldwide, the contribution of dental caries to the burden of oral diseases is about 10 times higher than that of periodontal disease and the other common oral condition.² Owing to its globally high prevalence, dental caries in children has been described as a 'pandemic' disease.³

Children in the age range of 12–30 months have a special caries pattern that differs from that in older children and is frequently called as "early childhood caries (ECC)", "bottle caries," "nursing caries," "baby bottle tooth decay," or "night bottle mouth".⁴

It is a complex disease, which involves maxillary primary incisors within a month after eruption and spreads rapidly to involve the other primary teeth.⁵

After appropriate pulp therapy, the primary tooth should be restored to the original dimensions using intracoronal and extracoronal restorative options. Common restorative materials used for restoring primary posterior teeth include amalgam, miracle mix, conventional glass ionomer cements(GICs), resin modified GIC, compomer, composites, open-faced stainless steel crowns, veneered stainless steel crowns, strip crowns and stainless steel crowns.^{7,8} Among these, AAPD guidelines recommend the use of stainless steel crowns to restore the teeth with large carious lesions.⁹

Stainless Steel crown is an extracoronal restoration that not only replaces the tooth to its original dimension but also has been reported to provide similar life span as that of an intact primary tooth besides providing protection to the residual tooth structure that may have been weakened after excessive caries removal.¹⁰

Despite the favorable qualities mentioned, Stainless Steel Crowns have a major drawback of poor esthetic appearance. With the world becoming more and more esthetics conscious, there is a growing demand for tooth colored esthetic crowns.

In yester years, many esthetic alternatives to Stainless Steel Crowns have been developed which include namely open-faced crowns; bonded strip crowns; and veneered SSCs etc.⁸

Recently, esthetically pleasing tooth colored Zirconia Crowns that have shown good results in adult dentistry have been introduced for restoration of primary teeth as the pediatric patient group has also become a part of the esthetically demanding patient group.

There is a paucity of literature to show the clinical performance of Zirconia Crowns when used over endodontically treated primary posterior teeth. Few case reports have been published showing the success of zirconia crowns in posterior region but to our knowledge there is no randomised control trial comparing the success of zirconia crowns with conventional stainless steel crowns.

With such limited knowledge, the present randomized clinical study was planned to evaluate the success of Zirconia crowns and Stainless steel crowns for restoring endodontically treated primary molars using various clinical and radiographic parameters.

Evidence suggests that both, children as well as their parents prefer white crowns over metallic fillings irrespective of age or sex (Ram D & Peretz B, 2000)¹³, (Fishman R et al. 2006)¹⁴, (Leith R & O'Connell AC, 2011)¹⁵. In our study immediate post-operative parental satisfaction was measured on Likert's scale which ranges from score 0 (very dissatisfied) to 4 (very satisfied). This scale was used in accordance with the study done by (Sharaf AA & Farsi NM, 2004)¹⁶. In stainless steel group immediate post-operative parental satisfaction was recorded as score '2' in 33.3% patients, score '3' in 16.7% patients and score '4' in 50% patients while score '4' was observed in all the patients in group 2 (Zirconia crown group). On inter-group comparisons the results were found to be statistically significant ($p = 0.018$).

Better immediate post-operative satisfaction in zirconia crown group was obvious owing to color matching property of zirconia crowns. Fuks AB et al. (1999)¹⁷ also emphasized that among all the metallic and esthetic restorative options, esthetic options are preferred over metallic restorations by parents.

In our study retention was recorded in accordance to the score given by (Maclean JK et al., 2007)⁸. In both the groups-1 and 2, at 1 week 100% of teeth presented with good retention and were recorded as 'A' score, 0.0% of teeth showed absence of retention (B score). No tooth in either of the groups showed poor retention. On inter group comparison non-significant difference was observed. ($p=1.000$). The same results were recorded at 3 and 6 month post-operative intervals respectively, exhibiting non-significant differences at all time intervals.

In our study occlusion was recorded in accordance to the score given by Fuks AB et al. (1999)¹⁷. In group-1, at 1 week 83.3% of teeth showed good occlusion and were recorded as 'A' score, 16.7% showed rotated occlusion (B score) while in group-2, 91.7% exhibited good occlusion (A score) and 8.3% of teeth exhibited rotated occlusion (B score). No tooth in either of the groups showed faulty occlusion. On inter group comparison non-significant difference was observed. ($p=0.537$). The same results were recorded at 3 and 6 month post-operative intervals respectively, exhibiting non-significant differences at all time intervals.

In group 1 at 1 week, 91.7 % teeth exhibited good marginal adaptation while 8.3% exhibited open margins while in group 2- 83.3% exhibited good margins while 16.7% exhibited open margins. The results were observed to be statistically non-significant ($p = 0.75$). Same scores were again observed at 3 month interval but at 6 month interval one extra tooth was observed to be having open margins in stainless steel crown group.

In our study gingival health was recorded using SilnessLoe index which is an acceptable index to record gingival health after pediatric restorative dentistry. (Kara BN & Yilmaz Y, 2014)¹⁰. In both the groups 100% of crowns showed good gingival health with no sign of inflammation at 1 week interval while at 3 months and 6 months post intervals 8.3% cases showed mild inflammation (score-1).The differences were recorded to be non-significant.

Conclusion:-

It can be concluded from our study that both Zirconia crowns and Stainless steel crowns can be effectively used as extra-coronal restorations in primary posterior endodontically treated teeth. In terms of retention, marginal adaptation, occlusion and gingival health both the crowns exhibited non-significant differences. However, zirconia crowns provided good esthetics and significantly better parental satisfaction scores. Thus, either of the crowns can be used for restoring such teeth, but whenever esthetic concerns surpass, zirconia crowns seem to be a preferred alternative.

References:-

1. American Academy of Pediatric Dentistry (AAPD). Definition of Early Childhood Caries (ECC). 2008:1.

2. Serhat Karaca, Gizem Ozbay, Betül Kargul. Primary Zirconia Crown Restorations for Children with Early Childhood Caries. *Actastomatol Croat.* 2013;47(1):64-71.
3. Saini S, Sharma D. Functional and Esthetic Rehabilitation during Deciduous Dentition Stage: A Case Report. *Dent Res J (Isfahan).* 2011 Spring;8(2):108-11.
4. Kawashita Y, Kitamura M, Saito T. Early Childhood caries: review article. *Int J Dent* 2011;2011:1-7.
5. Planells del Pozo P, Fuks AB. Zirconia crowns--an esthetic and resistant restorative alternative for ECC affected primary teeth. *J Clin Pediatr Dent.* 2014 Spring;38(3):193-5.
6. American Academy of Pediatric Dentistry (AAPD). Policy on Early Childhood caries(ECC):Unique Challenges and Treatment options. *REFERENCE MANUAL.*2014; 36(6):53-55.
7. Hickel R, Kaaden C, Paschos E, Buerkle V, García-Godoy F, Manhart J. Longevity of occlusally-stressed restorations in posterior primary teeth. *Am J Dent.* 2005 Jun;18(3):198-211. Review.
8. MacLean JK, Champagne CE, Waggoner WF, Ditmyer MM, Casamassimo P. Clinical outcomes for primary anterior teeth treated with veneered stainless steel crowns. *Pediatr Dent.* 2007 Sep-Oct;29(5):377-81.
9. Braff MH. A comparison between stainless steel crowns and multisurface amalgams in primary molars. *ASDC J Dent Child.* 1975 Nov-Dec;42(6):474-8.
10. Beldüz Kara N, Yılmaz Y. Assessment of oral hygiene and periodontal health around posterior primary molars after their restoration with various crown types. *Int J Paediatr Dent.* 2014 Jul;24(4):303-13. doi: 10.1111/ipd.12074. Epub 2013 Oct 28.
11. Salama FS, Myers DR. Stainless Steel Crowns in Pedodontics: A Review. *SaudiDentalJournal.*1992;4(2):70-74.
12. Kratunova E, O'Connell AC. A randomized clinical trial investigating the performance of two commercially available posterior pediatric veneered stainless steel crowns: a continuation study. *Pediatr Dent.* 2014 Nov-Dec;36(7):494-8.
13. Ram D, Peretz B. Composite crown-form crowns for severely decayed primary molars: a technique for restoring function and esthetics. *J Clin Pediatr Dent.*2000 Summer;24(4):257-60.
14. Fishman R, Guelmann M, Bimstein E. Children's selection of posterior restorative materials. *J Clin Pediatr Dent* 2006;31:1-4.
15. Leith R, O'Connell AC. A clinical study evaluating success of 2 commercially available veneered primary molar stainless steel crowns. *Pediatr Dent.* 2011 Jul-Aug;33(4):300-6.
16. Sharaf AA, Farsi NM. A clinical and radiographic evaluation of stainless steel crowns for primary molars. *J Dent.* 2004 Jan;32(1):27-33.
17. Fuks AB, Ram D, Eidelman E. Clinical performance of esthetic posterior crowns in primary molars: a pilot study. *Pediatr Dent.* 1999 Nov-Dec;21(7):445-8.