



Journal Homepage: - [www.journalijar.com](http://www.journalijar.com)

## INTERNATIONAL JOURNAL OF ADVANCED RESEARCH (IJAR)

Article DOI: 10.21474/IJAR01/19279

DOI URL: <http://dx.doi.org/10.21474/IJAR01/19279>



### RESEARCH ARTICLE

#### “CLINICAL, FUNCTIONAL AND RADIOLOGICAL OUTCOMES OF PROXIMAL FEMUR NAIL (PFN) IN COMPARISON WITH PROXIMAL FEMUR NAIL ANTIROTATION FOR ASIANS (PFNA2) IN THE TREATMENT OF INTERTROCHANTERIC FEMUR FRACTURE”

Dr. Pradeepa G.<sup>1</sup>, Dr. Vinay B. Patil<sup>2</sup> and Dr. Eshwar Masgal<sup>3</sup>

1. Post Graduate, Department of Orthopaedics, Basaveshwara Teaching and General Hospital, Attached Mahadevappa Rampure Medical College, Kalaburagi.
2. M.S.Orthopaedics, Professor, Department of Orthopaedics, Basaveshwara Teaching and General Hospital, Attached Mahadevappa Rampure Medical College, Kalaburagi.
3. M.S.Orthopaedics, Assistant Professor, Department of Orthopaedics, Basaveshwara Teaching and General Hospital, Attached Mahadevappa Rampure Medical College, Kalaburagi.

#### Manuscript Info

##### Manuscript History

Received: 12 June 2024

Final Accepted: 14 July 2024

Published: August 2024

##### Key words:-

Intertrochanteric Fractures, PFN A2, PFN

#### Abstract

**Introduction:** Intertrochanteric fractures management in elderly pose a serious challenge. The implants have evolved from extramedullary implants like dynamic hip screw to the intramedullary types of PFNA2 nail. Intramedullary implants have proven advantage over their counterpart in terms of stable anatomical fixation and better functional outcome. The main goal of fixation is early mobilization of patient in order to prevent complications of prolonged bed ridden status.

**Material And Methods:** A prospective, randomized, interventional, comparative study of 40 patients (PFN-20, PFN A2-20) who presented to us between 27 July 2022 to 27 January 2024 after applying inclusion and exclusion criteria. The details of the patients including gender, age, side of fracture, type of fracture, blood loss, time of union, operating time and complications were recorded. Patients were assessed clinically, functionally and radiographically at 6, 12, 24 weeks, 1 year postoperatively. Harris Hip Score was used to assess functional outcome.

**Results:** In this study, the mean ages of the PFN- 46.95 years, PFN A2 -53.45 years. Mean operative time for PFN was 111 minutes & PFNA2 had 76.75 minutes. The mean amount of blood loss for PFN is 112 ml & for PFNA2 is 98.75 ml. Mean radiological union time was 19.50 weeks for PFN & 17.05 weeks for PFNA2. Mean Harris hip score is 84 in PFN & 88 in PFNA2. The complications In the PFN A2 group were 1 experienced abduction lurch, 1 The complications In the PFN A2 group were 1 (5.0%) abduction lurch, 1 (5.0%) knee stiffness, 1 (5.0%) non-union, and 2 (10.0%) superficial infection. In the PFN group 2 (10.0%) abduction lurch, 2 (10.0%) knee stiffness, 2 (10.0%) non-union, 3 (15.0%) superficial infection, and 1 (5.0%) the Z effect.

**Conclusion:** From the study we concluded that the PFNA2 reduces the surgery time, blood loss and time of union as compared to PFN. As the union rate is more with PFNA2, the functional outcome is

**Corresponding Author:- Dr. Pradeepa G.**

Address:- Post Graduate, Department of Orthopaedics, Basaveshwara Teaching and General Hospital, Attached to Mahadevappa Rampure Medical College, Kalaburagi.

significantly better with Improved Harris hip score in PFNA2 than PFN. Implant related late complication is more with PFN which was markedly reduced with PFNA2.

Copyright, IJAR, 2024.. All rights reserved.

### Introduction:-

Intertrochanteric fractures are characterized as fractures of the upper femur, occurring between the trochanters, sometimes extending into the upper femoral shaft.<sup>1</sup>

Globally, the incidence of proximal femoral fractures is rising due to increasing life expectancy, higher rates of osteoporosis among the elderly, and more frequent road traffic accidents among younger individuals.<sup>2</sup>

The total number of trochanteric fractures is projected to reach 1.6 million by 2025 and 2.5 million by 2050. In 1990, Asia accounted for 26% of all intertrochanteric fractures, with this proportion expected to increase to 32% by 2025 and 38% by 2050.<sup>3</sup>

The primary objective in treating these injuries is to minimize displacement and stabilize the fracture with implants, allowing for early mobilization and weight-bearing during the healing process.<sup>4</sup>

Numerous studies have compared extramedullary and intramedullary implants, with intramedullary devices showing superior biomechanical properties and greater resistance to failure.<sup>5,6</sup>

The Proximal Femoral Nail Antirotation (PFNA) was introduced by the Arbeitsgemeinschaft für Osteosynthesefragen/Association for the Study of Internal Fixation (AO/ASIF) in 2003. It utilizes a helical neck blade to achieve high stability, preventing rotation and collapse.<sup>7</sup>

Both PFNA and PFNA2 are intramedullary devices with 6 degrees of proximal angulation. The helical blade in these devices compresses the cancellous bone in the femoral head during insertion, enhancing the strength of the femoral head and improving stability in the cervico-cephalic direction. The single helical blade in the PFNA2 is particularly suitable for smaller femurs, common in the Asian population, and biomechanically, the helical blade in PFNA2 offers better resistance to cut-out compared to screws.<sup>8</sup>

### Aims And Objectives:-

- 1.To study the Clinical, functional and radiological outcomes of proximal femur nail (PFN) in comparison with proximal femur nail antirotation for Asians (PFNA2) in the treatment of intertrochanteric femur fracture.
- 2.To study the potential complications associated with the procedure.

### Implant Discription:

#### Proximal Femoral Nail (PFN) :

- 1.Material: stainless steel or titanium alloy.
- 2.Length: standard size (250 mm ), length (340- 420mm).
- 3.Neck shaft angle range: 125, 130, 135 degree.
- 4.Nail proximal diameter : 14 mm.
- 5.Mediolateral valgus angle: 6 degree.
- 6.The distal diameter : 9, 10, 11, 12 mm.
- 7.Proximally it has 2 holes (distal one of 8 mm neck screw/sliding screw, the proximal one of 6.5 mm de-rotation screw).
- 8.Distally nail has 2 holes for 4.9 mm locking bolts (static and dynamic).

#### Proximal Femoral Nail antirotation for Asians (PFN A2) :

- 1.Material: stainless steel or titanium alloy.
- 2.Length: standard size (200mm ), length (260- 420mm).
- 3.Neck shaft angle range: 125, 130 degree.
- 4.Nail proximal diameter : 17 mm.

5. Mediolateral valgus angle: 5 degree.
6. The distal diameter : 9, 10, 11, 12 mm.
7. Proximally it has 1 hole for insertion of 11mm spiral blade.
8. Distally nail has 1 hole for 4.9 mm locking bolt (static or dynamic).

### Material And Methods:-

- Study setting: Basaveshwara Teaching and General Hospital, Attached Mahadevappa Rampure Medical College, Kalaburagi.
- Study design: Prospective interventional study.
- Sample size: 40.
- Sampling procedure: Subjects will be selected after applying inclusion and exclusion criteria. Information will be collected through prepared proforma. Written and informed Consent of each patient taken. Institutional ethical clearance had been obtained.
- Study duration: July 27, 2022–January 27, 2024.
- Statistical analysis: Data will be analysed using IBM SPSS software 20.0 version. If P value is <0.05 it is considered significant. Results will be depicted in the form of tables and graphs.

### Inclusion Criteria:

1. Patients above 18 years.
2. Radiologically confirmed cases of intertrochanteric femur fracture.
3. Medically fit and willing for surgery.

### Exclusion Criteria:

1. Patients with neurovascular injury.
2. Patients with associated injuries.
3. Patients with pathological fractures.
4. Patients who are medically unfit for surgery.

Patients will be reviewed at preoperative, postoperative 6 weeks, 3 months, 6 months, 1 year interval. Functional status was evaluated using Harris Hip Score.

### Physical Examination:

#### Clinical Presentation

##### • Symptoms

- \* acute onset of hip pain
- \* inability to ambulate

##### • Physical Examination

- \* Inspection: Shortened, externally rotated lower extremity
- \* Palpation: Tenderness over greater trochanter
- \* Motion: Pain with log roll and axial load, Unable to perform active straight leg raise
- \* Assess thigh compartments
- \* Neurovascular assessment

### Radiographic Studies:

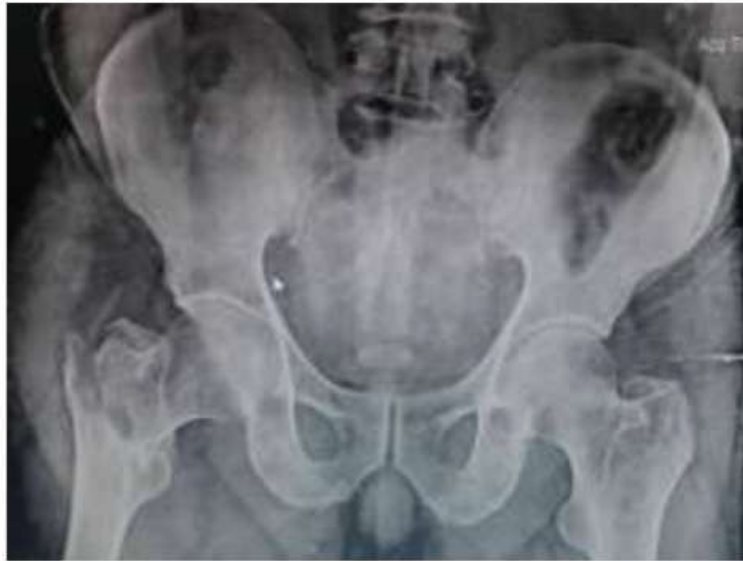**1. Recommended views :** AP pelvis, AP hip, Cross table lateral, Full length femur.

**2. Optional view :** Traction internal-rotation view (improve accuracy of fracture classification with direct impact on surgical planning).

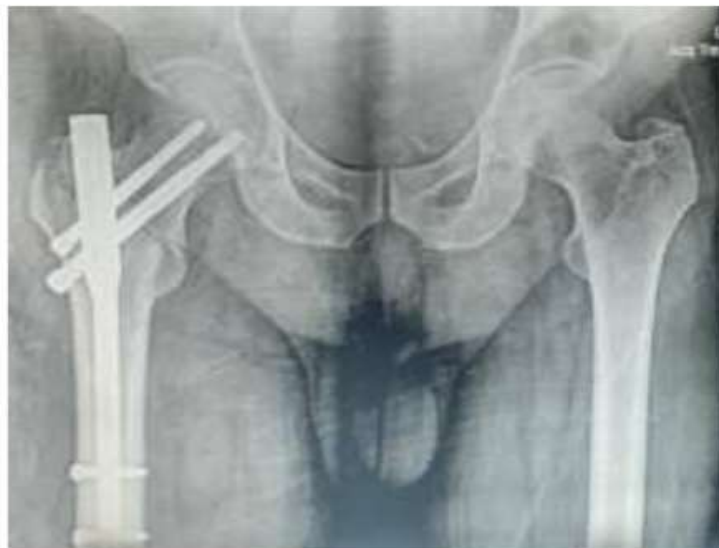#### 3. Findings :

- AP pelvis : compare to contralateral hip and assess neck shaft angle .
- AP hip : defines fracture pattern .
- Cross-table lateral : helps assess for posterior cortex comminution.
- Full length femur : assess subtrochanteric extension, possibility of pathological fracture, estimate length of intramedullary nail, assess femoral bowing, assess canal diameter.

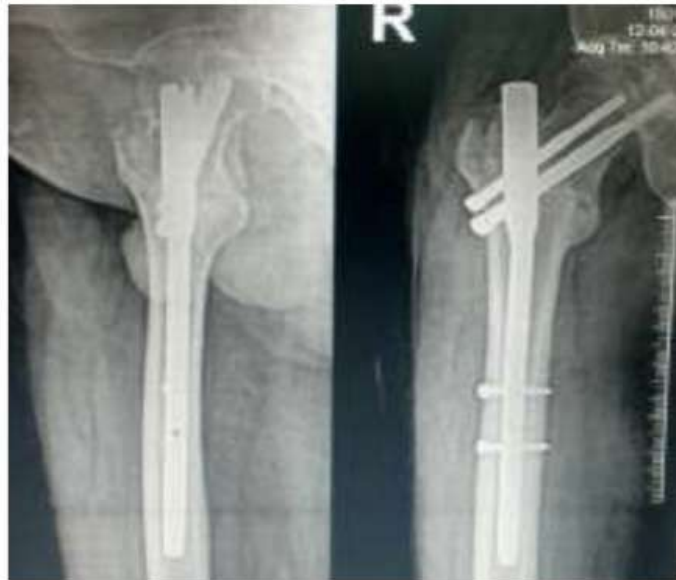**Preoperative And Postoperative Picture Of One Of The Patient In This Study:**



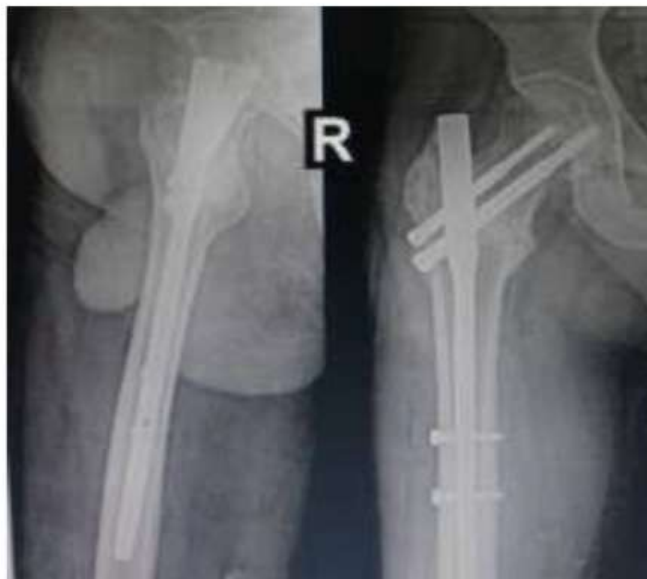Pre op x-ray



Immediate post op x-ray



3 months follow up



6 months follow up

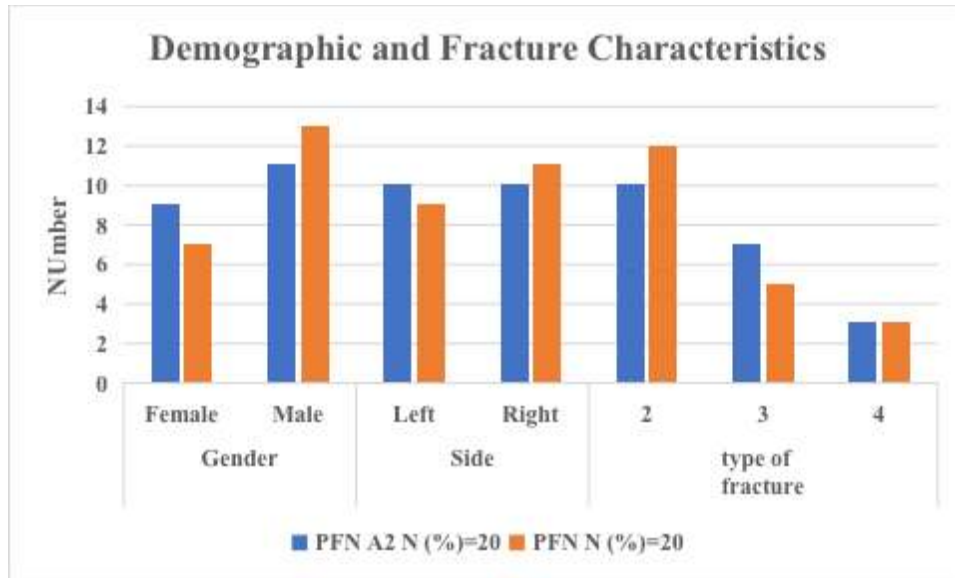
**Results:-**

**Mean Age Comparison:**

In this study, the mean ages of the PFN group 46.95 years , while the PFN A2 group is 53.45 years.

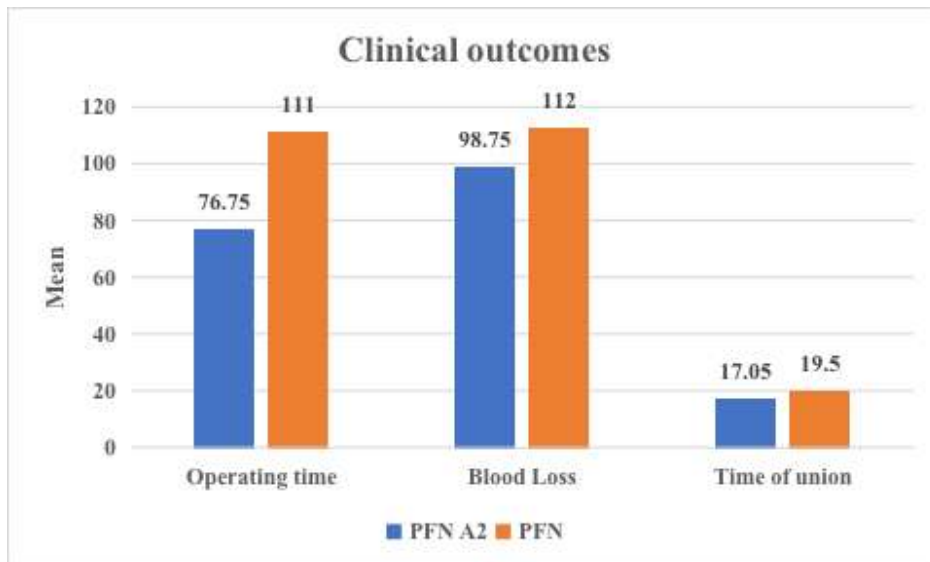
**Demographic and Fracture Characteristics:**

This graph provides a comparison of demographic and fracture characteristics



**Clinical Outcomes:**

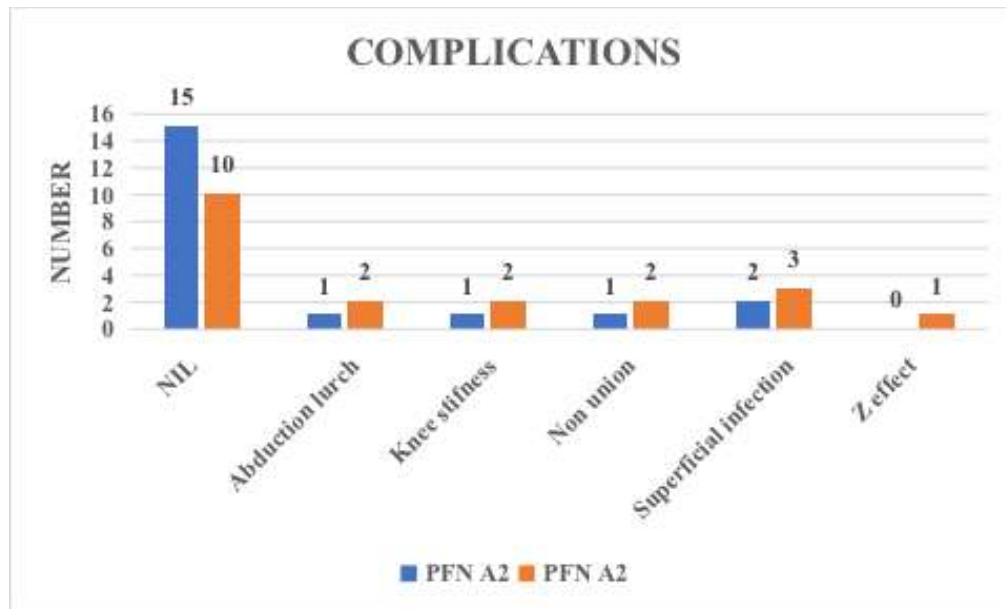
The mean operating time for the PFN A2 group was 76.75 minutes, whereas the PFN group had a significantly longer mean operating time of 111.00 minutes. The Blood loss during surgery with the PFN A2 group was 98.75 ml, compared to 112.00 ml in the PFN group. The time to union was significantly shorter in the PFN A2 group, with a mean of 17.05 weeks compared to 19.50 weeks in the PFN group.



**Complications:**

The complications In the PFN A2 group, 15 patients (75.0%) experienced no complications, 1 (5.0%) experienced abduction lurch, 1 (5.0%) experienced knee stiffness, 1 (5.0%) experienced non-union, and 2 (10.0%) experienced superficial infection. No patients in this group experienced the Z effect.

In the PFN group, 10 (50.0%) experienced no complications, 2 (10.0%) experienced abduction lurch, 2 (10.0%) experienced knee stiffness, 2 (10.0%) experienced non-union, 3 (15.0%) experienced superficial infection, and 1 (5.0%) experienced the Z effect.



#### Harris Hip Score:

The functional status according to Harris hip score was excellent in 7, good in 7, fair in 6 cases in PFN & excellent in 8, good in 9, fair in 3 cases in PFN A2.

#### Discussion:-

Currently, it is widely accepted that all intertrochanteric fractures should undergo internal fixation to reduce patient morbidity and mortality. However, the best method and the ideal implant for fixing intertrochanteric fractures remain a topic of debate, as each approach has its own advantages and disadvantages.

The proximal femoral nail (PFN) is considered particularly effective for unstable and reverse oblique fracture patterns because it offers better axial telescoping and rotational stability, functioning as a load-sharing device.<sup>9</sup>

It has been found to be biomechanically stronger than the dynamic hip screw, as it can withstand higher static loads and significantly more cyclical loading. This allows the fracture to heal even without the primary restoration of medial support. Additionally, the PFN acts as a buttress, preventing the medialization of the shaft. The AO/ASIF group further refined the PFN, creating the PFNA to enhance angular and rotational stability with a single element. This intramedullary device features a helical blade instead of a screw, providing better anchorage in the femoral head, as demonstrated in clinical studies.<sup>10</sup>

The Asia Proximal Femoral Nail Antirotation (PFNA-II) was specifically developed for Asian patients to address these challenges. It was designed with a mediolateral angle of 50 degrees and a proximal diameter of 16.5 mm, offering a significantly improved anatomical fit. This design effectively reduces hoop stress within the femoral shaft, which has led to a noticeable reduction in both intraoperative and postoperative diaphyseal fractures.<sup>11</sup>

In our study we came across mean age group of 53.45 years for PFNA2 and 46.95 years for PFN which are in line with Devadoss et al<sup>12</sup> with 69.1 and 69.9 years, Gadhe SS et al<sup>13</sup> with 67.56 years.

We came across mean operating time for PFNA2 76.75 and 111 minutes for PFN which are comparable Devadoss et al<sup>12</sup> and Shah A et al<sup>14</sup> which has 59.0, 71.9 minutes and 45, 56 minutes respectively.

We had blood loss for PFNA2 98.75 and 112 mL for PFN which aligns with Devadoss et al<sup>12</sup> and Shah A et al<sup>14</sup> which has 98.9, 123.1 mL and 90, 102 mL respectively.

In our study the time of union for PFNA2 17.05 and 19.50 weeks for PFN which are in line with the results of Devadoss et al<sup>12</sup> and Shah A et al<sup>14</sup> which has 15.3, 15.8 weeks and 12.23, 14.05 weeks respectively.

We came across the total complications for PFNA2 25% and 50% for PFN which are comparable to Devadoss et al<sup>12</sup> and Gadhe SS et al<sup>13</sup> with 13%,18% and 12%,20% respectively.

We had the functional outcome Harris hip score for PFNA2 88 and 84 for PFN which aligns with Devadoss et al<sup>12</sup> with 83.6% and 81.9% respectively.

**Source Of Funding:**

None.

**Conflict Of Interest:**

All the authors that have been listed above declared that they have no conflict of interest.

**Conclusion:-**

Our study concluded that PFNA2 offers several advantages over PFN, including reduced surgery time, less blood loss, and faster fracture union. Due to the higher union rate with PFNA2, the functional outcomes are also better, as reflected in the improved Harris hip scores compared to PFN. Additionally, implant-related late complications are more common with PFN but are significantly reduced with PFNA2. Based on these findings, the clinical, functional, and radiological outcomes of the Proximal Femur Nail Antirotation for Asians (PFNA2) are notably superior to those of the Proximal Femur Nail (PFN) in treating intertrochanteric femur fractures.

**References:-**

1. Kumar R, Singh RN, Singh BN. Comparative prospective study of proximal femoral nail and dynamic hip screw in treatment of intertrochanteric fracture femur. *J Clin Orthop Trauma*. 2012; 3(1):28-36.
2. Korkmaz MF. Outcomes of trochanteric femoral fractures treated with proximal femoral nail: an analysis of 100 consecutive cases. *Clinical Interventions in Aging* 569, 2014. doi:10.2147/cia.s59835.
3. Melton LJ. Secular trends in hip fracture incidence and recurrence. *Osteoporosis International*. 2009; 20:687-694.
4. Sheehan SE, Shyu JY, Weaver MJ, Sodickson AD, Khurana B. Proximal Femoral Fractures: What the Orthopedic Surgeon Wants to Know. *Radiographics*. 2015; 35:1563-1584.
5. Schipper IB, Marti RK, van der Werken C. Unstable trochanteric femoral fractures: extra medullary or intramedullary fixation. *Injury*. 2004; 35:142-151.
6. Parker MJ, Handoll HHG Gamma and other cephalocondylic intramedullary nails versus extra medullary implants for extra capsular hip fractures in adults. *Cochrane Database Syst. Rev*, CD000093, 2005.
7. Mereddy P, Kamath S, Ramakrishnan M, Malik H, Donnachie N. The AO/ASIF proximal femoral nail anti-rotation (PFNA): A new design for the treatment of unstable proximal femoral fractures. *Injury*. 2009;40(4):428-32.
8. Loo WL, Loh SYJ, Lee HC. Review of Proximal Nail Antirotation (PFNA) and PFNA-2—Our Local Experience. *Malaysian Orthopaedic Journal*. 2001; 5:1-5.
9. Williams WW, Parker BC. Complications associated with the use of the gamma nail. *Injury*. 1992; 23(5):291-2.
10. Kuderna H, Böhler N, Collon DJ. Treatment of intertrochanteric and subtrochanteric fractures of the hip by the Ender method. *J Bone Joint Surg Am* [Internet]. 1976; 58(5):604-611. Available from: <http://europepmc.org/abstract/MED/932059>.
11. Li M, Wu L, Liu Y, Wang C. Clinical evaluation of the Asian proximal femur intramedullary nail anti-rotation system (PFNA-II) for treatment of intertrochanteric fractures. *Journal of Orthopaedic Surgery and Research*. London; 2014, 9.
12. Devadoss A. Randomised comparative study in management of unstable intertrochanteric fracture with PFN V/S PFN A2-functional and radiological out-come. *International Journal of Orthopaedics*. 2018;4(4):866-74.
13. Gadhe SS, Bhor P, Ibad Patel DA, Vatkar DS, Kanade G. Comparative study of PFNA vs PFNA 2 in unstable intertrochanteric fractures: A randomised control study of 50 cases. *International Journal of Orthopaedics*. 2019;5(3):162-4.
14. Shah A, Badade K, Kadam R, Chhallani A, Sharma G, Pandey S. Clinical, functional and radiological outcomes of proximal femoral nail (PFN) with proximal femoral nail antirotation Asia (PFNA2) in the treatment of intertrochanteric and peritrochanteric femur fracture. *Int J Orthop Sci*. 2020;6:1156-60.