



Journal Homepage: -[www.journalijar.com](http://www.journalijar.com)

## INTERNATIONAL JOURNAL OF ADVANCED RESEARCH (IJAR)

Article DOI:10.21474/IJAR01/20059  
DOI URL: <http://dx.doi.org/10.21474/IJAR01/20059>



### RESEARCH ARTICLE

#### A CASE REPORT OF SEVERE FORM OF ASTEATOTIC ECZEMA WITH ALLERGIC CONSTITUTION TREATED SUCCESSFULLY USING HOMOEOPATHY

Kadam Kirti D. and Roy Sharmila A.

#### Manuscript Info

##### Manuscript History

Received: 13 October 2024

Final Accepted: 16 November 2024

Published: December 2024

#### Abstract

Asteatotic eczema is a common form of pruritic dermatitis (xerosis). It is commonly present in geriatric age group<sup>3</sup>. In geriatric age group 70% of population is affected with skin condition, among them common forms presented are dry, itchy skin<sup>2</sup>. Most of times, it is present in mild forms. It begins with dryness of skin. If it becomes severe in form, there occur fissures in skin. In geriatric age there is decreased activity of sebaceous glands and sweat glands. This leads to moisture depletion in skin of these people. To maintain this moisture, the keratin layer requires a significant water concentration. Excess water loss can cause fissures & splits in outer layer of skin (stratum corneum). These fissures are deep and can lead to damage of capillaries, which ultimately lead to bleeding. In this case Asteatotic eczema is present with allergic constitution which is a rare presentation. Allergy of detergent powder was the exciting factor in this case. In conventional mode of treatment is topical application of emollient containing creams & moisturizers<sup>4</sup>. Sometimes in severe forms corticosteroids are also prescribed<sup>5</sup>. Homoeopathy can completely cure even severe form of Asteatotic Dermatitis.

Copyright, IJAR, 2024,. All rights reserved.

#### Introduction:-

#### Objectives:-

1. To treat severe form of Asteatotic eczema.
2. To treat allergy of skin.

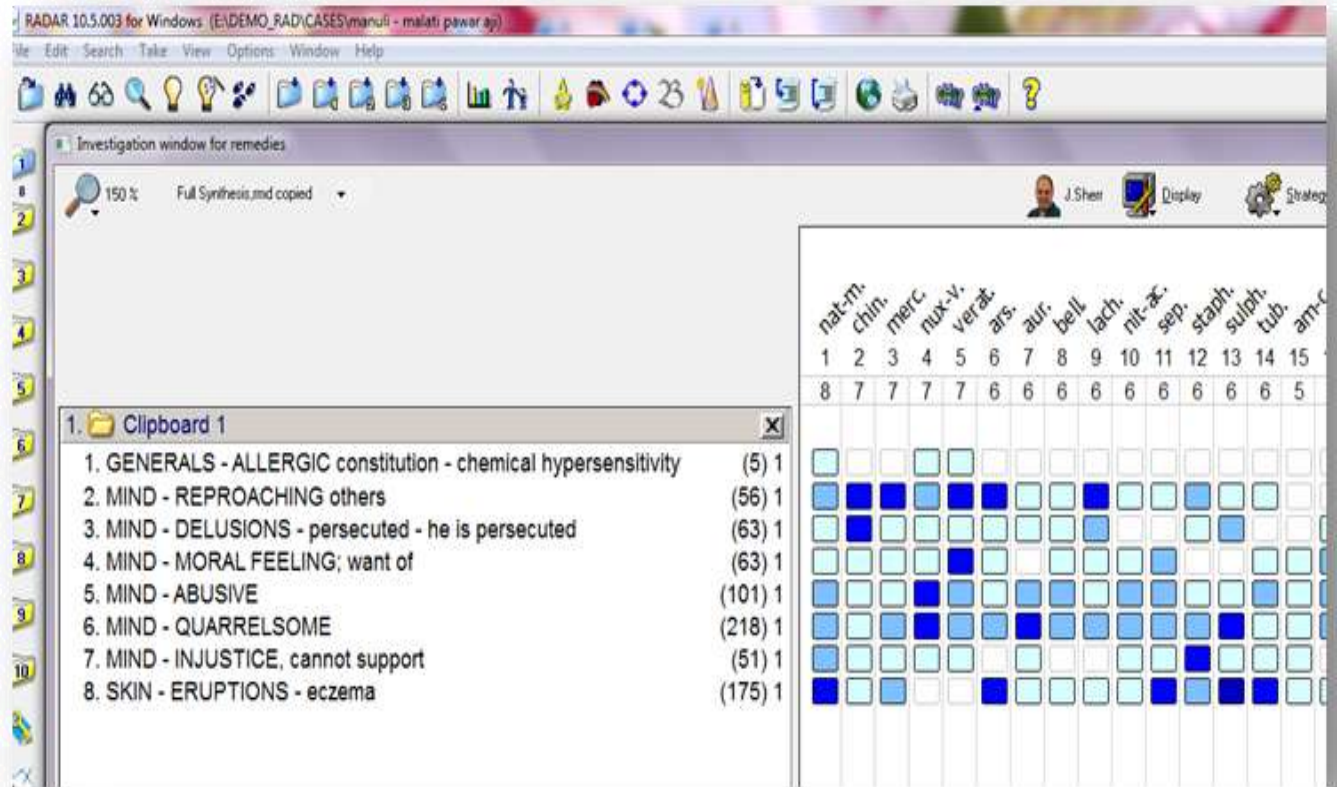
#### Case Description:

A 69 years old lady came in clinic on 15 October 2018 with presenting complaint of fissured skin with severe itching of both outer surfaces of hands. Fissures were deep and red, oozing a serous fluid, itching was very severe there was swelling of both hands as well. She also had an allergy from detergent powder. She was not able to wash her clothing and hence was persecuted because of this skin complaint. She also had allergy from Vermilion (Kumkum). (She was a known case of Diabetes mellitus, but with medication her sugar levels were stable.) Life Space Investigation: During her initial Stage of Life she had to struggle a lot because of low economic status. But she never took any financial help from her relatives to overcome this situation. Very independently she nurtured her children and made them self-sufficient. Her daughter in law now quarrels with her for this and that reason and sometimes she is abusive towards her. She reproaches her husband and his friends for their Sufferings (economical). If she faces any injustice situation, her skin complaints used to aggravates.

Corresponding Author:-Kadam Kirti D.

**Analysis of Case & Discussion:**

In initial Situation Tuberculinum 200 was prescribed to start the case.(In Synthesis 9.0 Rep. – Skin -Eruption-eczema- dry, fissured, deep= Tuberculinum) followed by little aggravation in itching followed by NatrumMuriaticum 200 (3 doses 8 hourly for one day). After which, itching was reduced in few days. It took 4 months to heal the deep ulcers. Swelling was reduced subsequently. She had allergic rhinitis before this complaint, which she again started in December 2018 but very soon she overcame it.The NatrumMuriaticum 200 was given in repetition for one year. After a year in 2019 winter there was no recurrence of any skin eruption. In 2020 also patient had no allergy from detergent and Vermilion (Kumkum). She was able to wash her clothing and could mark Vermilion (Kumkum) on her forehead without any allergy.

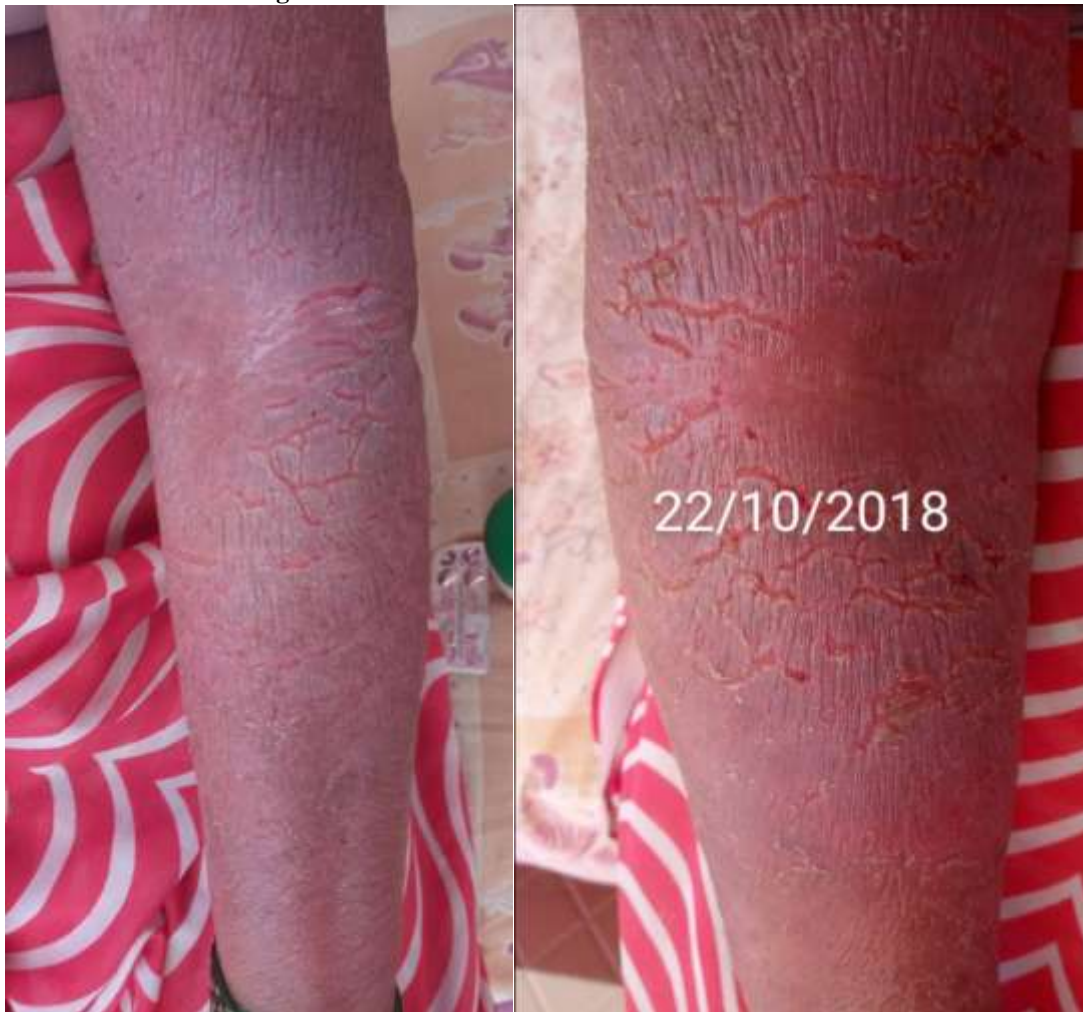

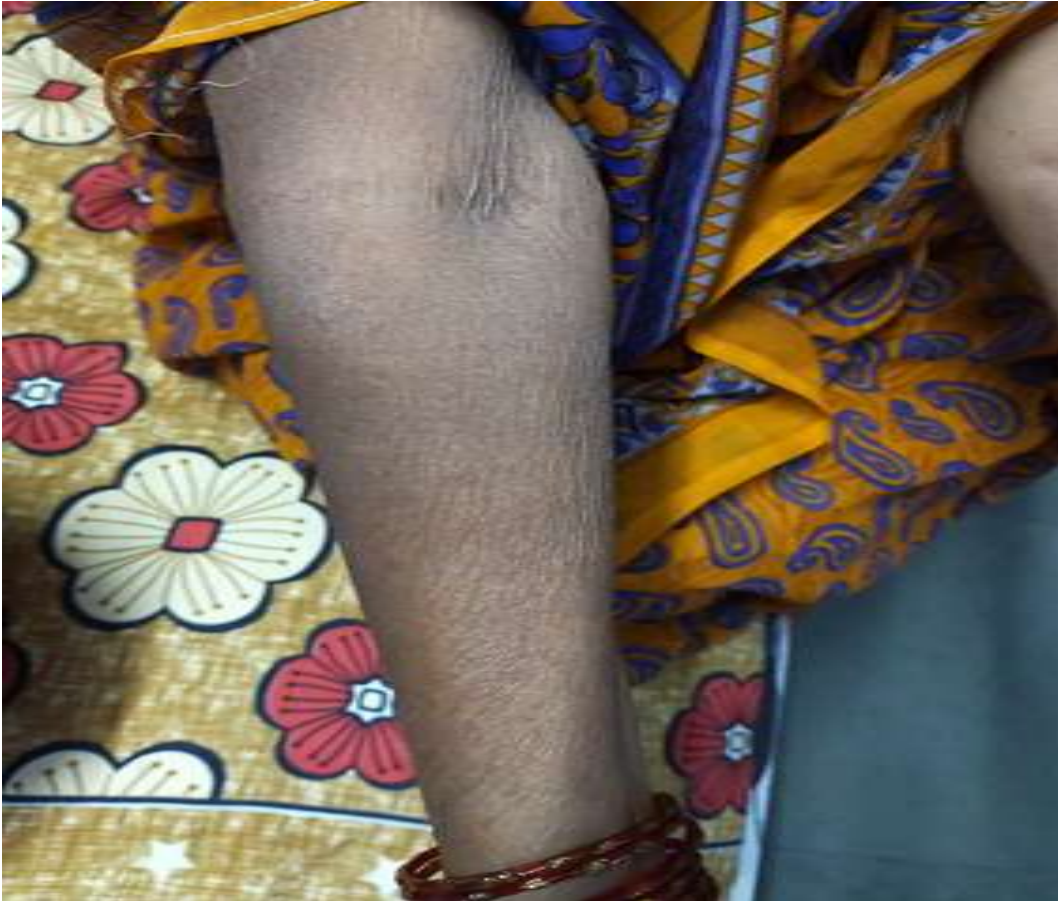**Table 1:-** Follow up Chart:

Complaints	Date	Prescription
Deep Fissured skin of hands, Allergy to detergent, kumkum, itching, oozing from fissures	15/10/2018	Tuberculinum 200 one dose.
Aggravation in itching of eczema, rest all complaints as it is	17/10/2018	NatrumMuriaticum 200 one dose.
Itching reduced, forehead eruption was reduced. (Kumkum allergy.) Fissures no change. Allergy no change	22/10/2018	SL 200 BD for a month
Itching completely relieved, redness and swelling reduced, oozing of serous fluid reduced. Fissures started healing.	20/11/2018	Natrum Mur. 200 one dose. SL 30 BD for One month.
Itching was completely reduced. Occasionally it itches. No oozing of fluid from skin. Fissures healed. No Change in Allergy.Her complaint of	28/12/2018	Natrum Mur. 1 M one dose HS. Natrum Mur 1M one dose was prescribed every month for a year till Dec 2019.

Allergic Rhinitis came back. Sneezing with watery discharge. (Overcame it within a week).		
No new Skin eruption & fissured skin of hands. Now she is able to wash clothing in detergent powder. No allergy from Kumkum. No complaint of Allergic Rhinitis.	18/12/2019	No medicine was prescribed.
No Any skin complaint and allergy noted in August & Winter 2020. No Recurrence.	18/08/2020	No Medicine was prescribed.

**Figure No. 02 and 03:-** Before Treatment 22/10/2018.



**Figure No.-04:-** After Treatment 18/08/2020.**Methods:-**

A case report evaluated using Modified Naranjo Criteria Score. If Score of Modified Naranjo Criteria is more than 6 we can say that case is improved. If score is below 6 Case is not Improved. (Maximum Score =13; minimum Score= 6).

**Table 2:-** Modified Naranjo Criteria for Homoeopathy (MONARCH)<sup>1</sup>

Domain	Yes	No	Not sure or N/A
1. Was there an improvement in the main symptom or condition for which the Homoeopathic medicine was prescribed?	+2	-1	0
2. Did the clinical improvement occur within a plausible timeframe relative to the drug intake?	+1	-2	0
3. Was there an initial aggravation of symptoms?	+1	0	0
4. Did the effect encompass more than the main symptom or condition (i.e. were other symptoms ultimately improved or changed)?	+1	0	0
5. Did overall well-being improve?	+1	0	0
6A. Direction of cure: did the symptoms improve in the opposite order of the development of symptoms of the disease?	+1	0	0
6B. Direction of cure: did at least two of the following aspects apply to the order of improvement of symptoms: - From organs of more importance to those of less importance? - From deeper to more superficial aspect of the individual. - From top to downwards.	+1	0	0
7. Did "old symptoms" (defined as non-seasonal and non-cyclical symptoms that were previously thought to have resolved) reappear temporarily during	+1	0	0

the course of improvement?			
8. Are there alternate Causes (other than the medicine) that- with a high probability- could have caused the improvement? (consider known course of disease, other forms of treatment, and other clinically relevant interventions)	-3	+1	0
9. Was the health improvement confirmed by any objective evidence (Laboratory test, Clinical Observation, etc.)	+2	0	0
10. Did the repeat dosing, if conducted, create similar clinical improvement?	+1	0	0

Thus the MONARCH score obtained is 9.

### Results:-

MONARCH score =9, this shows that, A case was treated with Homoeopathic medicine; follow up was taken after treatment for two years. There was no recurrence for life time.

### Conclusion:-

Homoeopathy can successfully treat a complicated severe form of Asteatotic Eczema and allergic condition.

### References:-

- 1) Chetna Deep Lamba: Evaluation of the Modified Naranjo Criteria for Assessing Causal Attribution of Clinical Outcome to Homeopathic Intervention as Presented in Case Reports- <https://www.thieme-connect.com/products/ejournals/pdf/10.1055/s-0040-1701251.pdf>
- 2) Ward S Eczema and Dry skin in older people: identification and management. Br. J Community Nurse 2005 Oct; 10(10);453-6 (Pub Med)
- 3) Polat M, Ilhan M N Dermatological Complications of elderly attending a dermatology outpatient clinic in Turkey; A Prospective study over a one year period. Actadermatovenerol Croat, 2015; 23(4); 277-81 (Pub Med)
- 4) ncbi.nlm.nih.gov/books/NBK549807/
- 5) Ng S Y Begum S; Chong S Y. Does order of application of Emollient & Topical Corticosteroids makes a difference in the severity of Atopic eczema in children? Pediatric Dermatol, 2016 Mar- April – 33(2); 160-4 (Pub Med).