



Journal Homepage: - www.journalijar.com

INTERNATIONAL JOURNAL OF ADVANCED RESEARCH (IJAR)

Article DOI: 10.21474/IJAR01/20180

DOI URL: <http://dx.doi.org/10.21474/IJAR01/20180>



RESEARCH ARTICLE

A RARE CAUSE OF MENORRHAGIA IN A YOUNG FEMALE : GLANZMANN THROMBASTHENIA(GT)

Souvik Bhandari¹, Ayan Thakur¹, Md Obidur Rahaman¹, Srijana Pradhan¹, Subhabrata Ray², Abhed Biswas² and Sumit Kumar Chakraborti³

1. PG Resident, Department of Medicine, North Bengal Medical College, Susrut Nagar, Silliguri- 70012, Dist - Darjeeling, West Bengal.
2. Assistant Professor, Department of Medicine, North Bengal Medical College, Susrut Nagar, Silliguri- 70012, Dist - Darjeeling, West Bengal.
3. Professor, Department of Medicine, North Bengal Medical College, Susrut Nagar, Silliguri- 70012, Dist - Darjeeling, West Bengal.

Manuscript Info

Manuscript History

Received: 06 November 2024

Final Accepted: 10 December 2024

Published: January 2025

Key words:-

Glanzmann Thrombasthenia (GT)
Autosomal Recessive Bleeding Disorder
Menorrhagia

Abstract

Glanzmann thrombasthenia(GT) is a rare inherited autosomal recessive bleeding disorder of platelet function caused by a defect in platelet membrane integrin α Ib β 3 (glycoprotein IIb/ IIIa).This integrin is the platelet fibrinogen receptor and essential for platelet aggregation and hemostasis. The lack of resultant platelet aggregation in GT leads to mucocutaneous bleeding whose manifestation may be clinically variable, ranging from easy bruising to severe and potentially life- threatening hemorrhages. Here we report a 16 year old girl presenting with history of menorrhagia since her menarche, who was diagnosed as Glanzmann thrombasthenia.

Copyright, IJAR, 2025,. All rights reserved.

Introduction:-

Glanzmann thrombasthenia (GT) is a congenital bleeding disorder causing lifelong bleeding episodes. This stems from a deficiency of the platelet integrin α Ib β III, which is the platelet fibrinogen receptor and is essential for platelet aggregation and hemostasis.^{1,2,3} The prevalence of GT is estimated to be about 1:1,000,000 in the general population.⁴ Glanzmann thrombasthenia is manifested by skin bleeds, epistaxis, gingival bleeding, gastrointestinal hemorrhage, hematuria, hemarthrosis, intracranial hemorrhage and visceral hematomas.⁵ Patients with this disorder have lifelong bleeding episodes that often involve the mucocutaneous membranes.⁴

Case Report :

A 16-year-old girl presented with history of persistent menorrhagia since her menarche, 3 years back. Her gynaecological assessment was non-contributory. She also gave history of easy bruisability and prolonged bleeding after any cut injury since birth. She had notable petechiae, purpura and ecchymosis specially on her limbs. There was no significant birth or developmental and family history. She was born out of a consanguineous marriage. Vital signs were unremarkable except tachycardia (PR 110/min), petechiae, purpura, ecchymosis. Cardiovascular, respiratory and other system examination were unremarkable.

Initial investigations showed microcytic hypochromic anemia (Figure 1) with normal leukocyte and platelet count (Table 1 and 2). Biochemical investigations also unremarkable (Table 3). Digital chest xray (PA view), 12 lead ECG

Corresponding Author:- Souvik Bhandari

Address:- PG Resident, Department of Medicine, North Bengal Medical College, Susrut Nagar, Silliguri- 70012, Dist - Darjeeling, West Bengal.

and 2D echocardiography were normal. Ultrasound of whole abdomen and pelvis could not detect any abnormalities. Thyroid profile, PT, INR, aPTT reports were within normal limit (Table 3). ANA hep 2 cell line report negative.

Prolonged bleeding time and normal clotting time(Table 3). On further evaluation we could document absence of platelet aggregation with ADP, epinephrine, arachidonic acid and collagen, as well as normal platelet aggregation in the presence of ristocetin (Figure 2 and 3). We consulted with Hematology colleagues and finally entertained a diagnosis of GT. The girl was managed conservatively with oral contraceptives, iron, tranexamic acid and advised to avoid contact sports or activities that are likely to cause trauma.

Discussion:-

GT has an autosomal recessive pattern and may arise from a number of mutations that affect GPIIb, GPIIIa, and/or the GPIIb/IIIa(CD41/CD61)complex.^{5,6,7} This protein complex is a member of the integrin family of adhesion.^{5,7} A defect in either GPIIb or GPIIIa causes the degradation of the other subunit and results in the same functional defect. Most of the encountered mutations are missense mutations or deletions in the GPIIb or GPIIIa gene.^{5,7} The frequency of consanguinity in affected families is noticeable, and GT has an increased incidence in populations in whom marriage among close relatives is an accepted custom.^{5,7,8} Affected patients exhibit a lifelong moderatetosevere bleeding tendency presenting as epistaxis (73%), gingival bleeding (55%) and menorrhagia (98%).^{2,5,7}

GT is characterized by normal platelet morphology, normal platelet count, prolonged bleeding time, absent or decreased clot retraction and normal platelet aggregation in the presence of ristocetin.^{6,7,8} Platelet aggregation is absent in the presence of epinephrine, collagen, arachidonic Acid, ADP, due to the dependence of these factors on fibrinogen attachment to the platelet for aggregation.^{2,7} Platelet aggregation occurs normally in response to ristocetin due to its independence from fibrinogen.⁷

There is no known cure for GT.^{2,8,9} The overall morbidity and mortality have been difficult to estimate due to its rarity, but in most studies, the prognosis has proven to be very good.^{8,9} Management is primarily supportive, including tranexamic acid, oral contraceptive pills, platelet transfusion or whole blood can be used for exchange transfusions before any invasive procedure or during heavy bleeding episodes and avoidance of offending drugs that predispose to bleeding.^{5,6,7,9}

Tables and figures :

Table 1:- Complete blood count.

Parameters	Results	Normal values
Hb	6.9 gm/ dl	12.0 -15.0 gm/ dl
MCV	76.9 fL	80 -100 fL
PCV	24.9 %	35.0-55.0 %
RDW	25.2	10.0 -16.0
TLC	8,700/ mm ³	4,000 -12,000/ mm ³
Platelet count	3,49,000/ mm ³	1,50,000 - 4,00,000/ mm ³
Reticulocyte production index	0.9 %	0.5 -2.5 %

Table 2:- Iron profile.

Parameters	Results	Normal values
Serum iron	34.8 µg/dL	50 -150 µg/dL
Ferritin	11.3 ng/mL	15 -300 ng/mL
Trabsferrin saturation	9 %	30 - 40 %
TIBC	409 µg/dL	310 -340 µg/dL

Table 3:- Biochemical parameters.

Parameters	Results	Normal values
Urea	25 mg/dL	15 -45 mg/dL
Creatinine	0.80 mg/dL	0.6 -1.2 mg/dL
Sodium	138 mEq/L	136- 146 mEq/L
Pottasium	4.2 mEq/L	3.5 -5.0 mEq/L
LDH	127.9 U/L	114 - 240 U/L

Total bilirubin	0.9 mg/dL	0.3 -1.3 mg/dl
Direct bilirubin	0.2 mg/dL	0.1 -0.4 mg/dL
SGOT	25 U/L	12 -38 U/L
SGPT	30 U/L	7 -41 U/L
Total protein	7.2 mg/dL	6.0 -8.3 mg/dL
Albumin	3.9 mg/dL	3.5 -5.5 mg/dL
PT	11.5 sec	13.5 sec
INR	1.06	0.8 -1.1
aPTT	29.2 sec	21.0 -35.0 sec
Clotting time	10 min	8.0 -15.0 min
Bleeding time	11 min	1.0 -9.0 min

Figure 1:- Peripheral blood smear showing microcytic, hypochromic anemia.

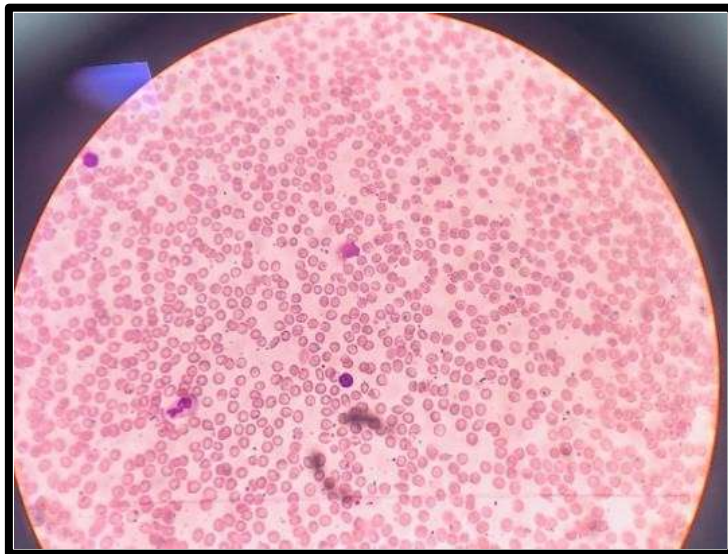
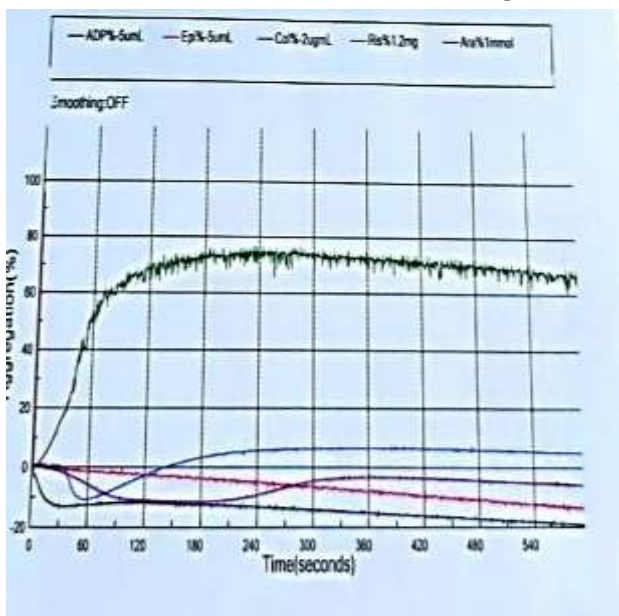


Figure 2 and 3:- Platelet function test.



Platelet Function Test	
Specimen :	Blood
Method	: Automated light transmission aggregometry by Sysmex CS-2400 analyzer
Observation	: -
ADP 5 µmol/L, 10 µmol/L	- No aggregation response.
Epinephrine 5µmol/L, 10 µmol/L	- No aggregation response.
Arachidonic acid 1 mmol/L, 1.5 mmol/L	- No aggregation response.
Collagen 2 µg/ml, 4 µg/ml	- No aggregation response.
Ristocetin 1.2 mg/ml	- Normal maximum and final aggregation.
Ristocetin 0.5 mg/ml	- No aggregation response.
Remarks	: Glanzmann thrombasthenia.
Enclosed	: Platelet aggregation curves of patient.

Conclusion:-

GT is a rare inherited bleeding disorder. However, unexplained bleeding predispositions on the background of normal platelet count, prolonged bleeding time and normal clotting time, should raise the suspicion of this diagnosis.

References:-

1. Doherty D, Singleton E, Byrne M, Ryan K, O'Connell NM, O'Donnell JS, et al. Missed at first Glanz: Glanzmann thrombasthenia initially misdiagnosed as Von Willebrand Disease. *J World Apher Assoc.* 2019;58(1):58–60.
2. Iqbal I, Farhan S, Ahmed N. Glanzmann Thrombasthenia: A Clinicopathological Profile. *J Coll Physicians Surg* 2016;26(8):647–650.
3. Poon MC, Di Minno G, d'Oiron R, Zotz R. New Insights Into the Treatment of Glanzmann Thrombasthenia. *Transfus Med Rev.* 2016;30(2):92–99.
4. Krause KA, Graham BC. Glanzmann Thrombasthenia. In: StatPearls [Internet]. Treasure Island (FL): StatPearls Publishing; 2024 [cited 2024 Jul 30]. Available from: <http://www.ncbi.nlm.nih.gov/books/NBK538270/>
5. Zenciroglu A, Bas AY, Demirel N, Yarali N. Glanzmann thrombasthenia in a neonate. *Indian Pediatr.* 2007;44(1):40–42.
6. Sebastiano C, Bromberg M, Breen K, Hurford MT. Glanzmann's thrombasthenia: report of a case and review of the literature. *Int J Clin Exp Pathol.* 2010;3(4):443–447.
7. Swathi J, Gowrishankar A, Jayakumar SA, Jain K. A rare case of bleeding disorder: Glanzmann's thrombasthenia. *Ann Afr Med.* 2017 Oct- Dec;16(4):196-198. doi: 10.4103/aam.aam_59_16. PMID: 29063905; PMCID: PMC5676411
8. Nurden AT. Glanzmann thrombasthenia. *Orphanet J Rare Dis.* 2006;1:10.
9. Seligsohn U. Glanzmann thrombasthenia: a model disease which paved the way to powerful therapeutic agents. *Pathophysiol Haemost Thromb.* 2002;32(5–6):216–217.