



Journal Homepage: - [www.journalijar.com](http://www.journalijar.com)

## INTERNATIONAL JOURNAL OF ADVANCED RESEARCH (IJAR)

Article DOI: 10.21474/IJAR01/20564

DOI URL: <http://dx.doi.org/10.21474/IJAR01/20564>



### RESEARCH ARTICLE

#### DENTIGEROUS CYST ENCOMPASSING THE HEMI-MAXILLA: A CASE REPORT

Shaju George Chammanam, Ranjith Jacob Kalliath, Jose Paul C.I, Stanley John Cheriyan, Leyons Augustine and Sruthy T.V

Department of Oral and Maxillofacial Surgery, Royal Dental College, Palakkad, Kerala.

#### Manuscript Info

##### Manuscript History

Received: 08 January 2025

Final Accepted: 12 February 2025

Published: March 2025

#### Abstract

Dentigerous cysts are the second most common odontogenic cysts after radicular cysts. Dentigerous cysts are benign odontogenic cysts associated with the crowns of permanent teeth. Cysts involve impacted, unerupted permanent teeth, supernumerary teeth, odontomas, and, rarely, deciduous teeth. The ectopic tooth embedded in a dentigerous cyst of the maxillary antrum is extremely rare in daily clinical practice. We are reporting a case of the ectopic left maxillary third molar tooth and the associated dentigerous cyst in the maxillary antrum.

"© 2025 by the Author(s). Published by IJAR under CC BY 4.0. Unrestricted use allowed with credit to the author."

#### Introduction:-

Displacement of the impacted tooth can occur due to a dentigerous cyst in an ectopic location like the mandibular condyle<sup>14</sup>, coronoid process<sup>14</sup>, nasal cavity, and maxillary antrum. There are possible etiological theories that explain the pathogenesis of ectopic teeth, including developmental abnormalities, trauma, infection, and pathological problems like dentigerous cysts. However, the exact mechanism remains unclear. Dentigerous cysts are usually not associated with pain. However, if they are associated with an infection, there is a painful swelling<sup>6</sup>.

#### Case Presentation.

A 40 year old female patient was referred to the oral and maxillofacial surgery department by a nearby dentist complaining of pain over the left infraorbital region. On primary evaluation tenderness over that region was noticed. Intraoral examination revealed the presence of distomolar and absence of third molar. On further evaluation with OPG (Fig 1) ectopically placed left upper third molar was noticed and CBCT was advised.

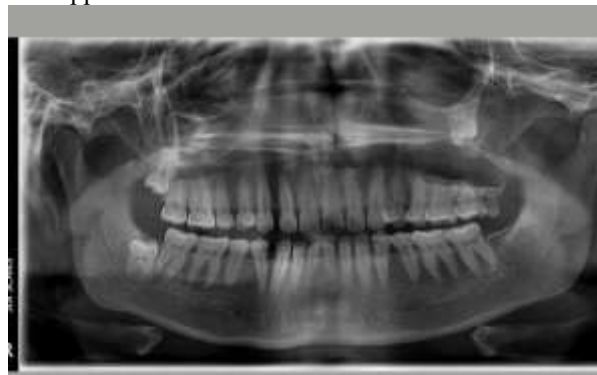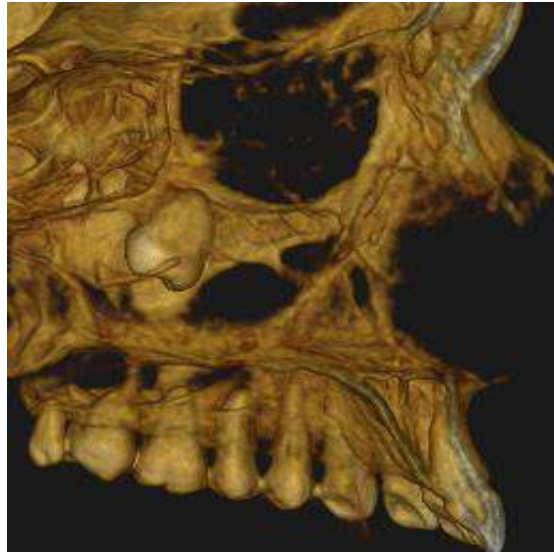


Fig. 1:- Pre-operative OPG.

Corresponding Author:- Shaju George Chammanam

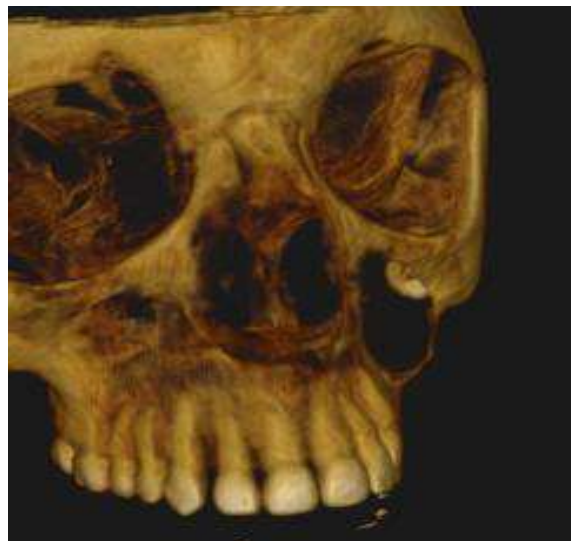Address:- Department of Oral and Maxillofacial Surgery, Royal Dental College, Palakkad, Kerala.

On Evaluation Single, unilateral, mostly well defined radiolucent lesion with variably corticated borders was noted in left body of maxilla Lesion extending antero – posteriorly from distal aspect of 25 to the pterygoid plates. Superiorly extending upto inferior border of orbit. Inferiorly lesion extends to 4 mm apical to the alveolar crest. Bucco- palatally causing buccal cortical plate expansion.



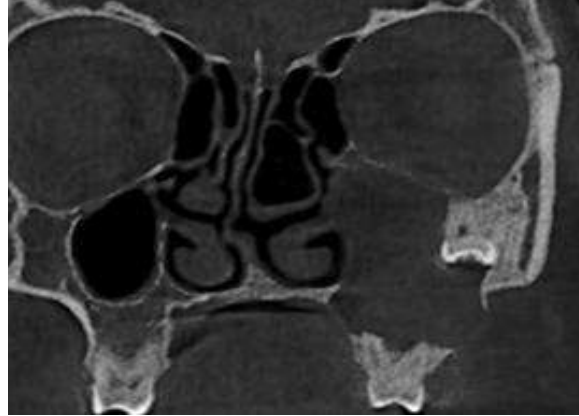
**Fig. 2:-** CBCT showing 28 in the medial wall of zygomatic bone.

The internal structure was radiolucent with mucosal thickening. Buccal cortical plate expansion with multiple areas of perforation and extreme thinning and mild erosion of palatal cortical plate noted suggestive of a highly expansile lesion. Posteriorly lesion was causing perforation of posterior border of maxilla, involving pterygopalatine fossa, greater palatine foramen and pterygoid plates.



**Fig. 3:-** Perforation of inferior border of orbit.

Complete obliteration of sinus noted with erosion of lateral wall of nasal cavity(fig 4), erosion of infraorbital canal and perforation of inferior border of orbit(fig 3). Vertically the impacted 28 was noted within sinus, in the medial border of zygoma.(Fig 2)

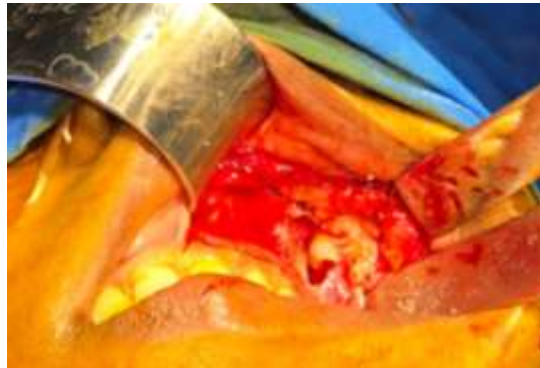

**Fig. 4:-**

A Single fused root was noted. Root apex was in contact with and causing perforation of inferior border of the orbit. Lesion inferiorly extended to the apical third level of roots of 25, 26 and 27 and causing external root resorption.

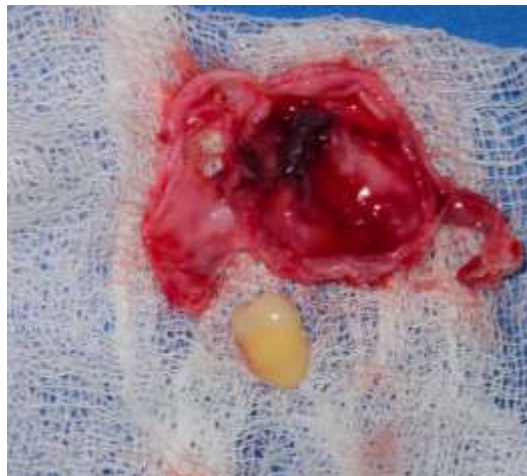Under GA a Caldwell-Luc incision was given over left posterior maxilla. Mucoperiosteal flap was raised. As the bone was too thin over the area, a natural window was opened into the maxillary sinus (fig 5)

**Fig. 5:-**



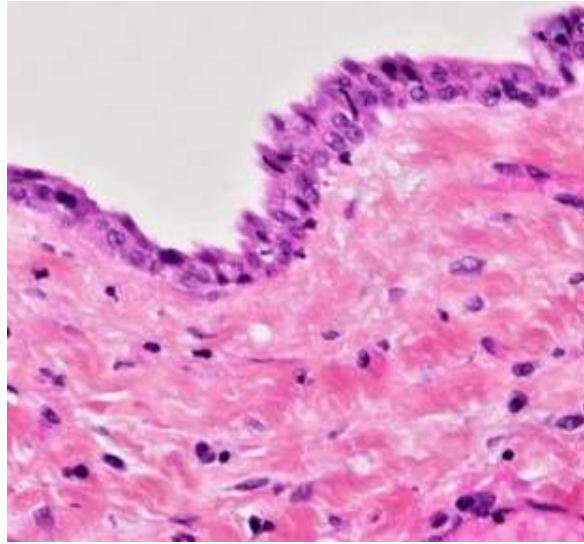
Complete removal of cyst along with the impacted 28 was done. (fig 6) Chemical cauterisation with Carnoy's solution was not done to prevent injury to orbital contents.

**Fig. 6:-**



Sinus was packed with ribbon gauze soaked in betadine, which was removed after 48 hours. Biopsy report was indicative of dentigerous cyst. (fig 7).

Fig 7.



The patient was given IV antibiotics, analgesics and steroids and discharged after 2 days as the postoperative period was uneventful.

Patient was reviewed after a week and satisfactory healing noticed .

After one month, healing was adequate with good function and patient satisfaction.

### Discussion:-

Dentigerous cysts, also known as follicular cysts, are the second most frequent odontogenic cysts after those associated with the roots of the teeth<sup>8</sup> (periapical cysts), originating from the weakened enamel epithelium during tooth crown development. They are most frequently found in the mandible (70%) than the maxilla (30%). The incidence is 14-20% and is slightly more prevalent among males (1.6:1) occurring in the second and third decades of life . Uncommon presentation of third molar in the lateral wall (medial border of zygoma) of left maxilla prompted us to publish this case.

Tooth development results from a complicated multistep interaction between the oral epithelium and the underlying mesenchymal tissue. A series of complex tissue interactions result in the formation of mature teeth. Abnormal tissue interactions during tooth development may potentially result in ectopic tooth development and eruption. Ectopic eruption of a tooth into the dental environment is common whereas ectopic eruption of a tooth in other sites is rare. One such site for ectopic tooth eruption in a nondental location is the maxillary sinus. Due to its rarity, there is a dearth of literature discussing this entity. Ectopic eruption may result due to one of the three processes: developmental disturbance, pathological process and iatrogenic activity<sup>8</sup>. Tooth eruption into the maxillary sinus may cause sinusitis, the treatment of which (if infected) is surgical removal. We present a case of an ectopic maxillary third molar, which presented in the left maxillary sinus and was removed via a Caldwell-Luc procedure.

The treatment of an ectopic tooth in the maxillary sinus is usually removal, as if left untreated, it has the tendency to form a cyst or tumor. The differential diagnosis of a dentigerous cyst includes other odontogenic cysts, such as radicular cysts, odontogenic keratocysts, and odontogenic tumors, such as ameloblastoma, odontoma, odontogenic fibroma, and cementomas<sup>12</sup>. However, mucoceles, retention cysts, and pseudocysts are also included in the differential diagnosis when a maxillary sinus cyst is visualized involving maxillary expansion. Histologically, dentigerous cysts are lined by a layer of nonkeratinized stratified squamous epithelium, with a surrounding wall of thin connective tissue containing odontogenic epithelial rests<sup>10</sup>.

The standard treatment for a dentigerous cyst is enucleation and extraction of the cyst-associated impacted or unerupted tooth. Dentigerous cysts of the maxillary sinus, and the impacted tooth within, are often easily removed via a Caldwell-Luc procedure<sup>5</sup>. Removal of the entire cyst with the impacted tooth is a main treatment to prevent recurrence of the cyst. Marsupialization is another advisable treatment to preserve the cyst-associated tooth and promote its eruption. Large cysts that involve serious loss of bone and that thin the bone dangerously are often treated via marsupialization<sup>13</sup>. It was successfully used to minimize the amount of maxillary destruction and surgical morbidity that might have resulted from the immediate enucleation of the lesion for dentigerous cysts within the maxillary antrum.

The major disadvantage of marsupialization is recurrence or persistence of the lesion<sup>15</sup>. Although the traditional Caldwell-Luc procedure provides a direct view into the maxillary sinus, it is associated with more morbidity than transnasal endoscopy. Transnasal extrusion of the tooth may be attempted if the tooth is small and sited near the maxillary ostium.

### Conclusion:-

The occurrence of an ectopic tooth in maxillary sinus and its association with dentigerous cyst is a rare phenomenon. Its presence is asymptomatic until it is infected. Routine X-rays and CBCT can confirm the diagnosis. The standard treatment for dentigerous cyst is enucleation and extraction of associated tooth via Caldwell-Luc approach. In large cyst, an initial marsupialization to diminish the size, followed by enucleation has been advocated.

### References:-

1. Mamatha NS, KriShNaMoorthy B, Savitha JK, Bhai P. Diagnostic CBCT in dentigerous cyst with ectopic third molar in the maxillary sinus—a case report. *Journal of Clinical and Diagnostic Research: JCDR*. 2014 Jun;8(6):ZD07.
2. John T, Shekhar MG, Koshy M. Dentigerous cyst associated with supernumerary teeth: A report of three cases. *J Clin Diagn Res*. 2010 Jun;4:2601-6.
3. Girish G, Kumar M, Umashankar D, Sharma R, Veeresh M, Bhandari A. Case report dentigerous cyst in maxillary sinus: A Rare Occurrence. *Int J Oral Maxillofac Pathol*. 2011;2:19-23.
4. Alhashim FY, Almarhoon FS, Alhashim HY, Moumen A. Endonasal endoscopic management of different cases of dentigerous cysts and ectopic teeth. *Journal of Surgical Case Reports*. 2021 Apr;2021(4):rjab099.
5. Marino MJ, Luong A, Yao WC, Citardi MJ. Management of odontogenic cysts by endonasal endoscopic techniques: a systematic review and case series. *American Journal of Rhinology & Allergy*. 2018 Jan;32(1):40-5.
6. Amin ZA, Amran M, Khairudin A. Removal of extensive maxillary dentigerous cyst via a Caldwell-Luc procedure. *Archives of Orofacial Sciences*. 2008;3(2):48-51.
7. Prasad TS, Sujatha G, Niazi TM, Rajesh P. Dentigerous cyst associated with an ectopic third molar in the maxillary sinus: a rare entity. *Indian journal of dental research*. 2007 Jul 1;18(3):141-3.
8. MacDonald-Jankowski D, Chan KC. Clinical presentation of dentigerous cysts: systematic review. *Asian Journal of Oral and Maxillofacial Surgery*. 2005 Jun 1;17(2):109-20.
9. Austin RP, Nelson BL. Sine qua non: dentigerous cyst. *Head and neck pathology*. 2021 Dec;15(4):1261-4.
10. Nahajowski M, Hnitecka S, Antoszevska-Smith J, Rumin K, Dubowik M, Sarul M. Factors influencing an eruption of teeth associated with a dentigerous cyst: A systematic review and meta-analysis. *BMC Oral Health*. 2021 Dec;21:1-1.
11. Assael LA. Surgical management of odontogenic cysts and tumors. *Principles of oral and maxillofacial surgery*. 1992;2:685-8.
12. Regezi JA. Cyst and cystlike lesions. Regezi JA, Sciubba J, Pogrel M A. *Atlas of Oral and Maxillofacial Pathology*. Philadelphia: WB Saunders. 2000.
13. Shear M. *Cysts of the oral regions*. Wright Oxford, England. 1992.
14. Yusuf H, Quayle AA. Intracondylar tooth. *International journal of oral and maxillofacial surgery*. 1989 Dec 1;18(6):323.
15. Kasat VO, Karjodkar FR, Laddha RS. Dentigerous cyst associated with an ectopic third molar in the maxillary sinus: A case report and review of literature. *Contemporary clinical dentistry*. 2012 Jul 1;3(3):373-6.