



Journal Homepage: [-www.journalijar.com](http://www.journalijar.com)

INTERNATIONAL JOURNAL OF ADVANCED RESEARCH (IJAR)

Article DOI:10.21474/IJAR01/20581
DOI URL: <http://dx.doi.org/10.21474/IJAR01/20581>



RESEARCH ARTICLE

DUODENAL TRICHOBEZOAR: AN EXCEPTIONAL LOCATION

Riyad A.¹, El Baroudi G.¹ and Gharbi K.²

1. Faculty of Medicine and Pharmacy of Laayoune, Ibnou Zohr University, Morocco.
2. Faculty of Medicine and Pharmacy of Marrakech, Cadi Ayyad University, Morocco.

Manuscript Info

Manuscript History

Received: 12 January 2025
Final Accepted: 15 February 2025
Published: March 2025

Key words:-

Trichobezoar, Duodenum, Endoscopic
Extraction, Surgery

Abstract

Trichobezoar is a rare condition characterized by the presence of a foreign body in the digestive tract, mainly the stomach, composed of hair or textile fibers. It primarily occurs in young women with specific psychological profiles, marked by a tendency to pull out their hair (trichotillomania) and eat it (trichophagia). The symptoms are varied, but the diagnosis is usually straightforward, guided by the patient's background and supported by tomography and endoscopy. Treatment can be endoscopic, but if this approach is not possible or fails, surgery remains the last resort, without neglecting psychological support. We report the case of a 19-year-old patient with trichobezoar, suspected based on epigastric pain associated with late postprandial vomiting and an abdominal mass found on clinical examination. Diagnosis was confirmed by abdominal CT scan, and treatment was performed through surgery after a duodenotomy following the failure of an endoscopic extraction attempt. In addition to the rarity of the condition, our observation is the first, to our knowledge, to report a case of an isolated trichobezoar in the duodenum.

"© 2025 by the Author(s). Published by IJAR under CC BY 4.0. Unrestricted use allowed with credit to the author."

Introduction:-

Bezoars are accumulations of indigestible substances that collect in the gastrointestinal tract, primarily in the stomach (1). They are formed by materials including dietary fibers, undigested food, hair, or medications (2).

Bezoars generally do not cause specific symptoms and can therefore mimic other conditions, such as tumors (3). They can increase in size and lead to complications such as digestive perforation, peritonitis, obstruction, pancreatitis, appendicitis, jaundice, and intestinal intussusception (4). Trichobezoar is a condition that occurs in adolescents with trichotillomania, characterized by repetitive hair pulling, often associated with obsessive thoughts, mood disorders, and anxiety (4). In this paper, we report the case of a young girl presenting with a trichobezoar located exclusively in the duodenum, a presentation possibly never documented in the literature.

Case Report:

We present the case of a 19-year-old girl with a history of trichophagia and a maternal history of severe geophagia. The patient presented with chronic epigastric pain, early postprandial vomiting, and minimal weight loss, which she considered insignificant. Clinical examination revealed a patient with preserved general health and the presence of a palpable epigastric mass.

Corresponding Author:- Riyad Abbas

Address:- Faculty of Medicine and Pharmacy of Laayoune, Ibnou Zohr University,
Morocco.

Biological workup showed anemia with a hemoglobin level of 10.7 g/dL.

Abdominal CT scan revealed an ovoid mass in the pyloroduodenal region, with well-defined contours and a lesion-like capsule. The mass displayed a mixed pseudo-fatty density with "fat density floating fibers," measuring 11 × 6 cm, strongly suggestive of a trichobezoar (Figure 1).

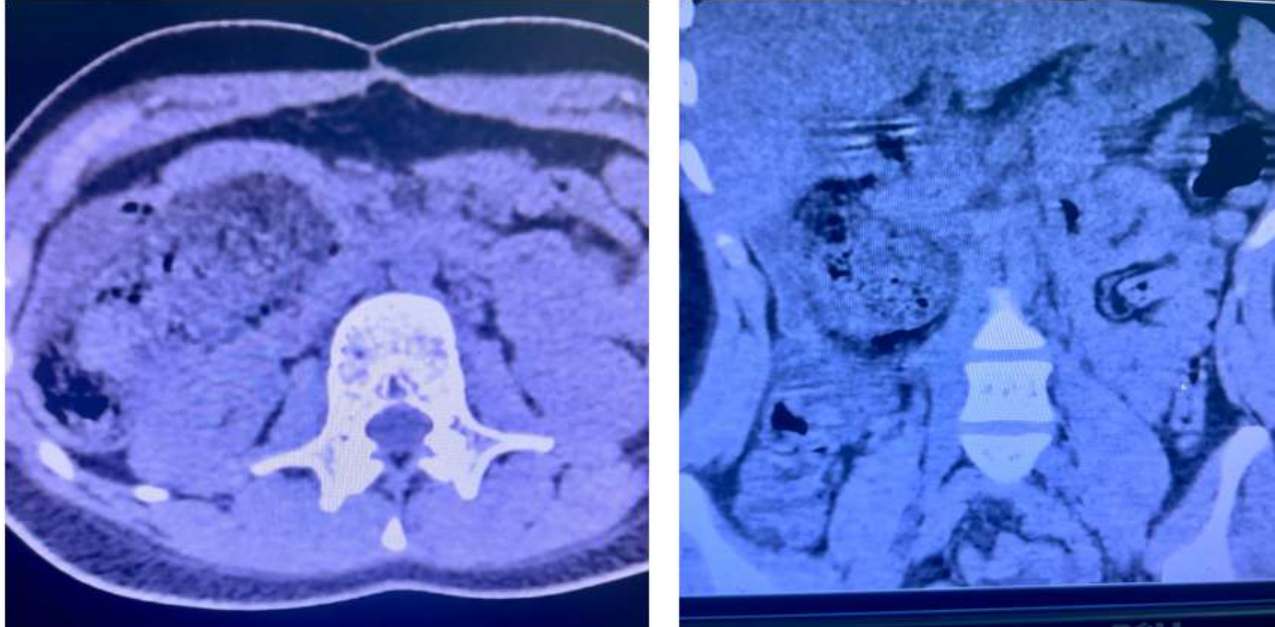


Figure 1:- Abdominal CT scan showing the trichobezoar.

The patient was admitted to the operating room for endoscopic extraction. During exploration, a trichobezoar was found to be confined exclusively to the duodenum, with a free pylorus. Endoscopic extraction was unsuccessful, leading to the decision to proceed with surgical management (Figure 2).

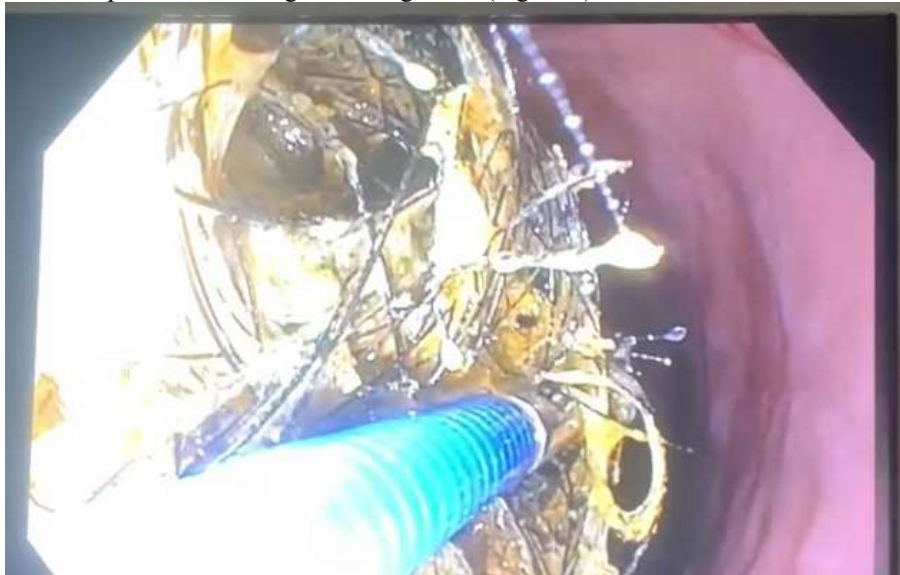

Figure 2:- Attempt at endoscopic extraction.

The surgical procedure was performed via a supraumbilical midline laparotomy. Exploration revealed a duodenal mass occupying the first three segments of the duodenum, which was distended. Attempts were made to push the trichobezoar into the stomach, but ultimately, a longitudinal duodenotomy was performed on the second segment of the duodenum (D2), through which the bezoar was successfully extracted.

Closure was achieved with separate stitches using 3/0 Vicryl with a round needle, and a Delbet drain was placed. Postoperative recovery was uneventful, with oral feeding resumed on the fourth postoperative day and discharge to home on the fifth day (Figures 3 and 4). Psychiatric care was initiated during the hospital stay.

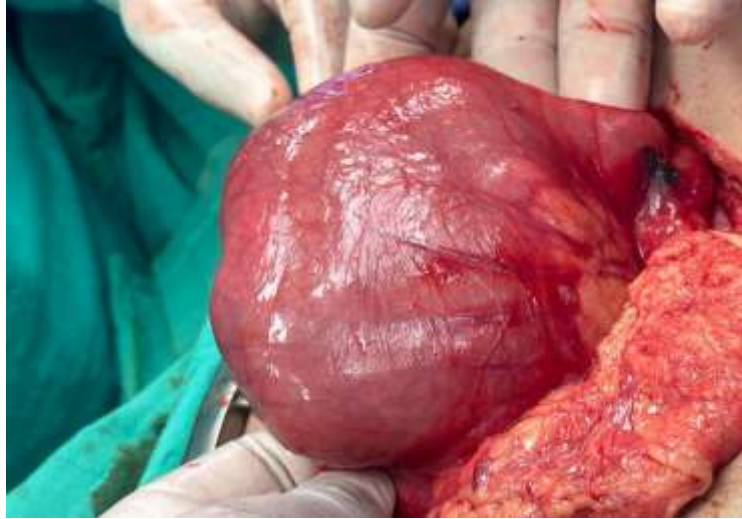


Figure 3:- Trichobezoar occupying the duodenum.

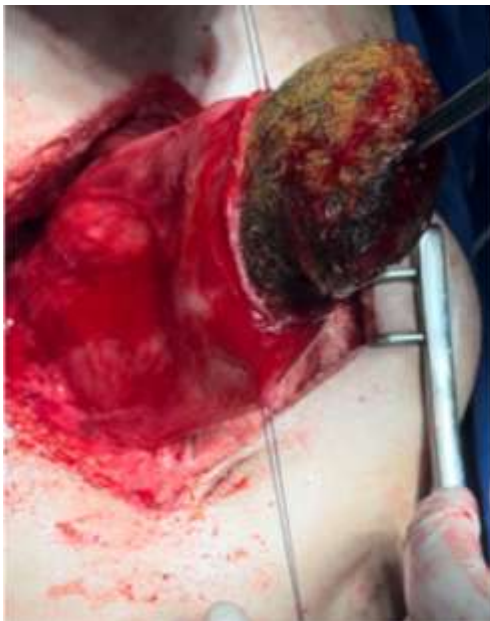


Figure 4:- Extraction of the trichobezoar.

Discussion:-

We present an original case of a trichobezoar located exclusively in the duodenum, a presentation that, to the best of our knowledge, has not been previously described. Through this case, we aim to shed light on this rare entity.

The incidence of the condition is poorly understood, but trichobezoar predominantly affects females (90% of cases), with 80% occurring in individuals under the age of 30 (5). Underlying mental health disorders, such as anxiety and post-traumatic stress disorder, are commonly associated and often lead to trichophagia and trichotillomania (6). Less than 1% of individuals with trichophagia will develop a trichobezoar (4).

The formation of the mass is facilitated by the indigestible and enzyme-resistant nature of hair, which continues to accumulate and form the trichobezoar (7). Bezoars can cause various symptoms and severe complications, including

obstruction, ulceration, subsequent gastrointestinal bleeding, pancreatitis, appendicitis, jaundice, and intestinal intussusception (4)(8). This underscores the importance of early diagnosis, with endoscopy remaining the gold standard (6).

Abdominal CT is the most accessible and least invasive diagnostic tool, revealing a heterogeneous intragastric lesion composed of trapped air bubbles, food debris, and concentric rings (9). The treatment approach depends on the size and location of the mass (10). Small trichobezoars can be managed with endoscopic extraction (8)(11), laser endoscopic fragmentation, gastric lavage, enzymatic treatment, or a combination of these methods (11).

Chemical dissolution is another option, which is cost-effective and minimally invasive, using substances that break down bezoars, including Coca-Cola® (12). However, these techniques carry a risk of iatrogenic complications, making surgery the most effective and safest management method. Surgical intervention typically involves laparotomy with opening of the affected digestive segment, which remains the standard approach. Laparoscopy has also been reported, offering satisfactory postoperative outcomes (13)(14).

Conclusion:-

Trichobezoar remains a rare condition, and our case is particularly noteworthy due to the unusual site of obstruction. We have highlighted the importance of an accurate diagnosis and prompt management to prevent potentially fatal complications.

Conflict Of Interest:

The authors have no potential competing interests or conflicts to report

Authors Contribution:

All authors have participated in the elaboration of this work from conception to final version

Bibliography:-

1. Revelation of Rapunzel syndrome : A rare case report of gastric trichobezoar-induced acute purulent peritonitis *Int J Surg Case Rep.* 2023 Sep 22;111:10886.
2. Risk factors, endoscopic findings, and treatments in upper gastrointestinal bezoars: multi-center experience in Iran. *Gastroenterol Hepatol Bed Bench.* 2021 Spring;14(2):160-164
3. Balawender K, Pliszka A, Możdżeń K, Kłos M, Ogorzałek A, Boroń D, et al. Trichopsychodermatology: trichotillomania and trichophagia leading to Rapunzel syndrome. *Postepy Dermatol Alergol.* 2022; 39: 739-743.
4. Gastric trichobezoar and Rapunzel syndrome: case report of a very rare condition. *Hippokratia.* 2023 Jan-Mar;27(1):25–27
5. The gastric trichobezoar: one case report. *J Clin Diagn Res.* 2016 Feb 1;10(2):PD10–PD11.
6. Schuler L, Hodel M, Stieger C. The Rapunzel syndrome: a hairy tale. *Surg Case Rep.* 2023; 9: 49.
7. Jackman J, Nana GR, Catton J, Christakis I. Gastric perforation secondary to Rapunzel syndrome. *BMJ Case Rep.* 2021; 14: e240100.
8. Minimally invasive treatment of duodenal obstruction with acute pancreatitis caused by two large bezoars. *J Minim Access Surg.* 2022 Jul 20;19(3):437–439.
9. Kwon HJ, Park J. Treatment of large gastric trichobezoar in children: Two case reports and literature review. *Medicine (Baltimore).* 2023; 102: e33589.
10. Delimpaltadaki DG, Gkionis IG, Flamourakis ME, Strehle AF, Bachlitzanakis EN, Giakoumakis MI, et al. A rare giant gastric trichobezoar in a young female patient: Case report and review of the literature. *Clin Case Rep.* 2021; 9: e05152.
11. Mazzei A, Centonze A, Aloï IP, Bertocchini A, Baldassarre E. Rapunzel Syndrome: Endoscopy, Laparotomy, or Laparoscopy? *J Indian Assoc Pediatr Surg.* 2021; 26: 66-67.
12. Systematic review: Coca-Cola can effectively dissolve gastric phytobezoars as a first-line treatment. *Aliment Pharmacol Ther.* 2013 Janv;37(2):169-73.
13. Haggui B, Hidouri S, Ksia A, Oumaya M, Mosbahi S, Messaoud M, et al. Management of trichobezoar: About 6 cases. *Afr J Paediatr Surg.* 2022; 19: 102-104.
14. Successful laparoscopic extraction of trichobezoar due to Rapunzel syndrome: first reported case in Kuwait. *J Surg Case Rep.* 2021 Dec 7;2021(12):rjab532.