



Journal Homepage: - www.journalijar.com

INTERNATIONAL JOURNAL OF ADVANCED RESEARCH (IJAR)

Article DOI: 10.21474/IJAR01/20619

DOI URL: <http://dx.doi.org/10.21474/IJAR01/20619>



RESEARCH ARTICLE

ADENOID CYSTIC CARCINOMA OF THE TRACHEA: A REPORT OF TWO CASES AND LITERATURE REVIEW

R. Amiali¹, Y. Afkar¹, L. Senhaji¹, M. Karhate¹, M. Serraj¹, M. Elbiaze¹, B. Alami², M. Smahi³, Mc. Benjelloun¹ and B. Amara¹

1. Department of Pneumology, University Hospital Center Hassan II, Fez, Morocco.
2. Department of Radiology, University Hospital Center Hassan II, Fez, Morocco.
3. Department of Thoracic Surgery, University Hospital Center Hassan II, Fez, Morocco.

Manuscript Info

Manuscript History

Received: 16 January 2025

Final Accepted: 19 February 2025

Published: March 2025

Key words:-

Adenoid Cystic Carcinoma, Trachea, Case Report

Abstract

Adenoid cystic carcinoma (ACC) is a rare neoplasm, with an estimated incidence ranging from 0.1 to 0.26 per 100,000 individuals. It constitutes the second most prevalent primary malignant tumor of the trachea. Therapeutic bronchoscopy plays a vital role in enhancing the clinical condition of the patient prior to surgical intervention, which remains the primary treatment modality. Conversely, radiotherapy has demonstrated efficacy, in contrast to conventional chemotherapy. This malignancy tends to exhibit slow progression but is frequently fatal in the absence of radical treatment. We present a novel case of adenoid cystic carcinoma in a 71-year-old female patient, identified during an episode of tracheal wheezing accompanied by dyspnea that had persisted for one year. Diagnosis was established through biopsy of the tumor located in the lateral wall of the trachea via mediastinoscopy. The second case features a 55-year-old male, a former smoker with a history of progressive dyspnea over five years, productive cough with intermittent blood streaks, wheezing, and chest tightness. Chest CT revealed a nearly stenosing intratracheal mass. Bronchoscopy confirmed a tumor obstructing the trachea by 90%. Biopsy indicated ACC. Mechanical debulking and placement of a silicone Y-stent were performed, followed by successful endoscopic follow-up. The patient was classified as T4N3M0 and referred for chemoradiotherapy.

"© 2025 by the Author(s). Published by IJAR under CC BY 4.0. Unrestricted use allowed with credit to the author."

Introduction:-

Adenoid cystic carcinoma (ACC) is an infrequent malignant tumor, accounting for less than 1% of all malignant neoplasms, with approximately 30% arising in the head and neck region, particularly within the salivary glands. Localization within the trachea is exceedingly rare, with an incidence of approximately 0.2 cases per 100,000 individuals annually, comprising nearly 10% of tracheal tumors. It ranks as the second leading cause of tracheal tumors, following squamous cell carcinoma (1)(2)(3).

The clinical manifestations associated with tracheal ACC are contingent upon the extent of airway obstruction. Consequently, this pathology may be entirely asymptomatic or may present with wheezing, stridor, dyspnea at rest or

Corresponding Author:- Rajae Amiali

Address:- Department of Pneumology, University Hospital Center Hassan II, Fez, Morocco.

during exertion, and hemoptysis. It is characterized by moderate malignancy, indolent growth, progressive clinical evolution, a propensity for local recurrence, and delayed metastasis (4).

The primary treatment approach is surgical resection, which may be supplemented by adjuvant radiotherapy. The prognosis is generally favorable when diagnosed and managed promptly (5). In this report, we describe a case of tracheal adenoid cystic carcinoma managed at our institution, emphasizing the effective integration of therapeutic bronchoscopy and surgical intervention in the treatment of adenoid cystic carcinoma, alongside a review of relevant literature.

Case 1:

A 71-year-old female patient, a non-smoker with no significant medical history, presented with inspiratory dyspnea accompanied by wheezing, which had progressively worsened over the past year, ultimately resulting in respiratory distress that necessitated her consultation.

Physical examination indicated that the patient had a World Health Organization (WHO) performance status of 0, with peripheral oxygen saturation measured at 70% in ambient air, alongside the presence of tracheal wheezing.

Imaging performed via computed tomography demonstrated thickening of the right tracheal wall, characterized by a lobulated formation protruding into the tracheal lumen, leading to an estimated 70% stenosis.

Bronchoscopy findings revealed a severe tracheal stenosis exceeding 80%, attributed to extrinsic compression. The mucosal surface appeared slightly infiltrated, with no evidence of protrusion; additionally, the tracheal wall exhibited fragility, showing slight bleeding upon contact. This stenosis was localized in the lower half of the trachea, extending nearly 4 cm, and was situated approximately 2 cm above the carina.

In light of these findings, a rigid bronchoscopy with biopsy was conducted; however, the results were inconclusive. A silicone tracheal stent measuring 16 mm by 60 mm was subsequently placed due to the significant stenosis. Positron emission tomography (PET) scan results indicated a mildly hypermetabolic tissue lesion in the right tracheal wall, measuring 20 x 26 x 45 mm, as well as a hypermetabolic lesion in the posterior wall of the left main bronchus located 9 cm from the carina. (figure 1 and 2)

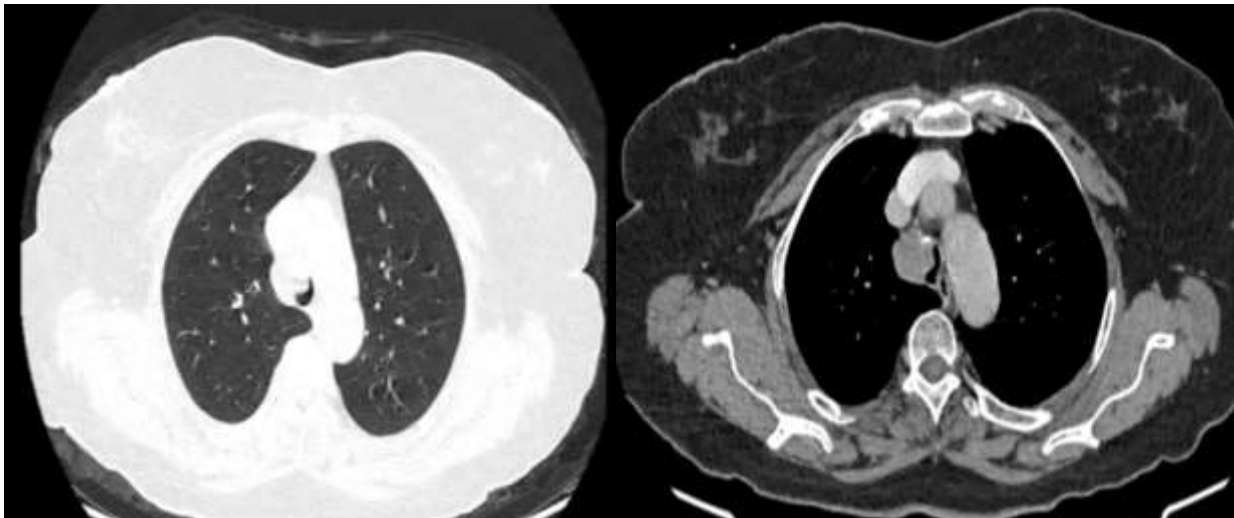


Figure 1:- (A, B): Chest CT Scans in parenchymal window A and mediastinal window B) showing thickening of the right lateral wall of the trachea responsible for stenosis.

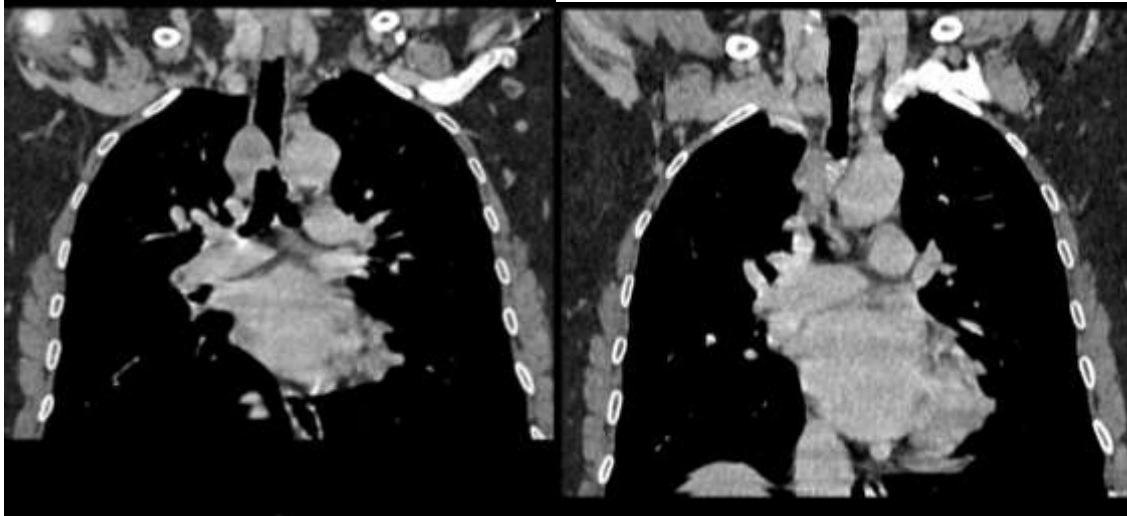


Figure 2(A, B):- Chest CT Scan in Mediastinal Window, Coronal Section showing thickening of the right lateral wall of the trachea responsible for stenosis.

A mediastinoscopy was conducted to achieve an etiological confirmation, as the bronchoscopy biopsy results were inconclusive. Histological analysis of the tumor fragments revealed the presence of fibro-hyaline stroma interspersed with rare epithelial structures, exhibiting morphological and immunohistochemical characteristics consistent with adenoid cystic carcinoma. (Figure 3)

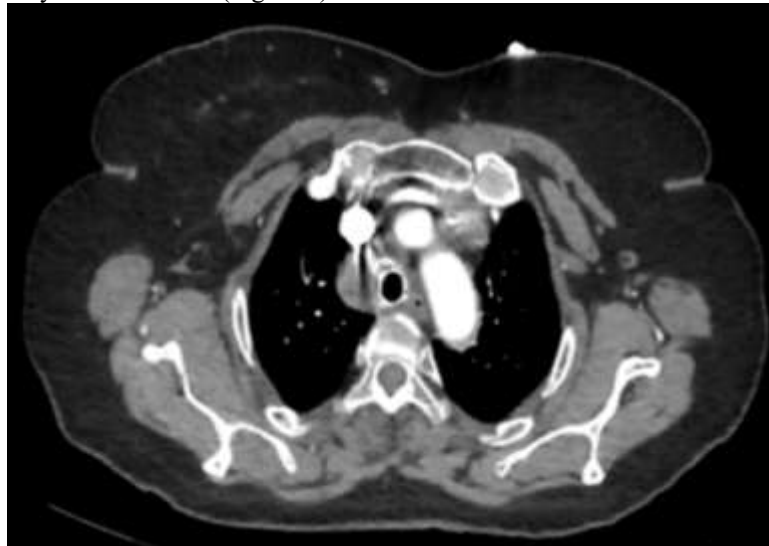


Figure 3:- CT Appearance After Placement of the Tracheal Stent.

The patient underwent surgical intervention for adenoid cystic carcinoma following staging, which indicated the absence of distant metastases. The surgical procedure involved the complete excision of the tumor, achieving negative surgical margins. No radiotherapy was administered post-operatively.

Monitoring over a two-year period demonstrated favorable progression of the patient's condition, with no evidence of recurrence or associated complications.

Case 2:

A 55-year-old patient, a former smoker who ceased smoking 30 years prior after an 8-year history, presented with progressive dyspnea over the past 5 years. This was accompanied by a productive cough with intermittent blood streaks, wheezing, and a sensation of chest tightness.

Physical examination indicated an ECOG performance status of 0, with peripheral oxygen saturation at 98% in ambient air, and tracheal wheezing noted upon auscultation.

Chest computed tomography revealed a nearly stenosing intratracheal mass lesion. (Figure 4)

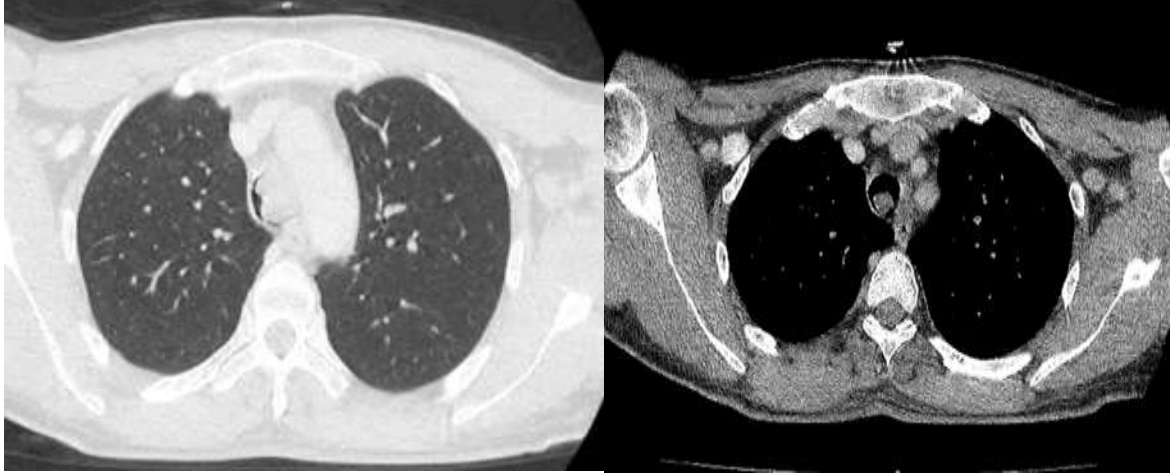


Figure 4 (A, B):- Thoracic CT scan in parenchymal window A and mediastinal window B showing an intratracheal, quasi-stenosing, budding tissue lesion process.

Bronchoscopy revealed a tumor mass located in the lower third of the trachea, obstructing the tracheal lumen by 90% and extending down to the level of the carina. (Figure 5)

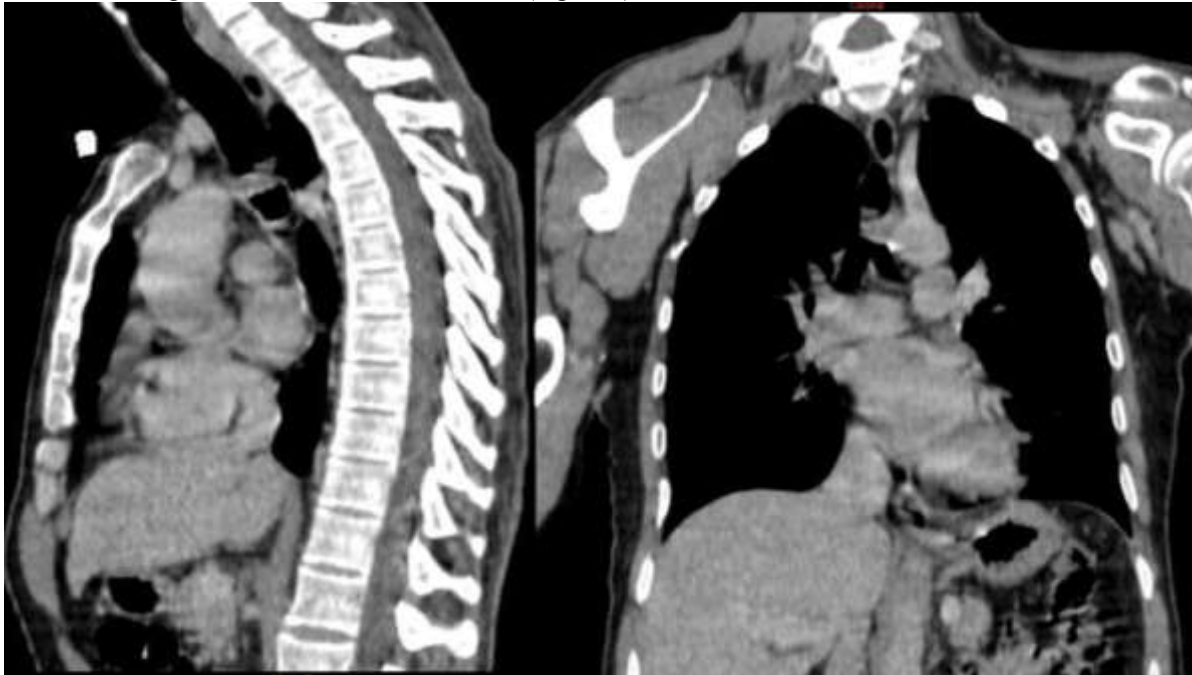

Figure 5 (A, B):- Chest CT in Mediastinal Window: Sagittal and Coronal Sections showing a nearly stenosing intratracheal mass lesion.

In light of this presentation, a rigid bronchoscopy with biopsy was performed, revealing morphological and immunohistochemical features consistent with adenoid cystic carcinoma.

Mechanical debulking was subsequently conducted using the bronchoscope, followed by the placement of a silicone Y-stent (caliber: 181414, length: 5.5T/1D/2G). Endoscopic follow-up showed satisfactory results, with a stable stent positioned such that the upper limit was located 3.5 cm from the vocal cords. (Figure 6 ,7 and8).

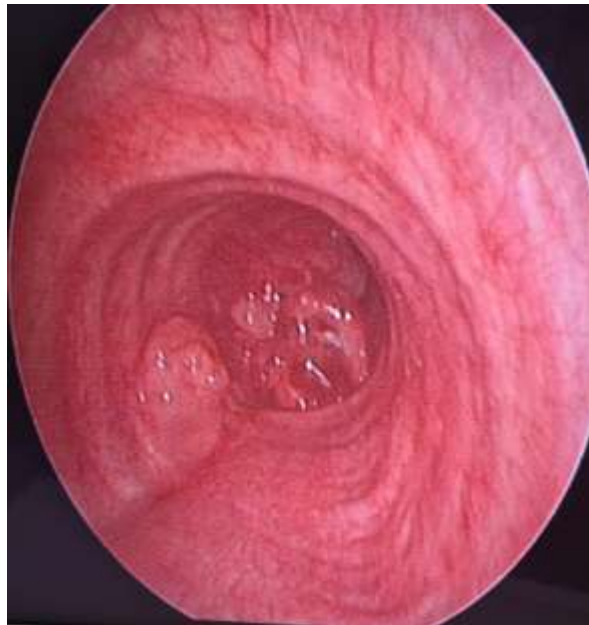

Figure 6:- Bronchoscopy Image showing a tumor mass in the lower third of the trachea, obstructing the tracheal lumen.

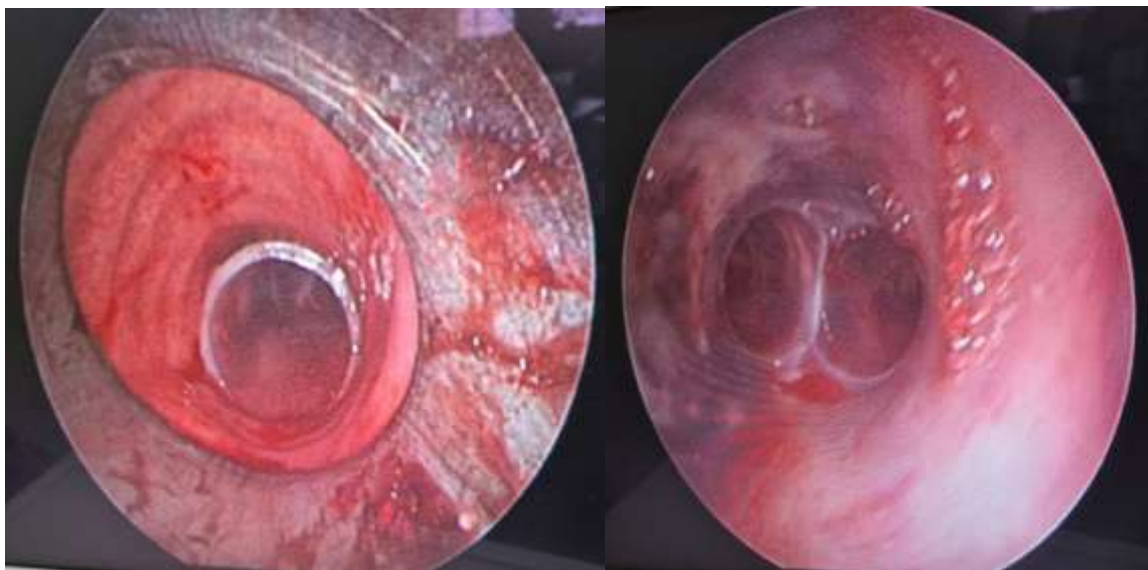


Figure 7:- Bronchoscopy Image showing the silicone Y-stent (caliber: 181414, length: 5.5T/1D/2G).

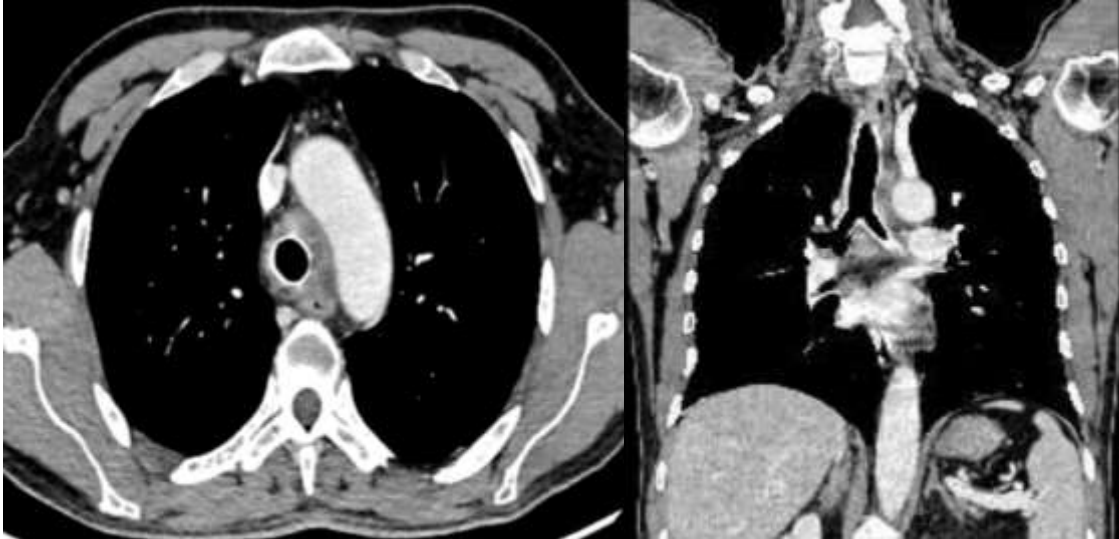


Figure 8 (A, B):- Chest CT in Mediastinal Window: Axial and Coronal Sections after the placement of the tracheal stent.

The extension evaluation revealed no signs of distant metastases, and the patient was classified as T4N3M0. The patient was then referred for chemoradiotherapy.

Discussion:-

Adenoid cystic carcinoma (ACC) is a rare malignancy, with an incidence of 0.2 cases per 100,000 people per year, accounting for approximately 10% of tracheal tumors. It is the second most common primary malignant tumor of the trachea. This carcinoma primarily arises from the secretory cells of salivary glands but can also affect central airway structures, including the trachea and main bronchi, representing about 10% of head and neck tumors.

Tracheal ACC is particularly uncommon, originating from the submucosal glands of the trachea, and typically occurs in the distal third. A study by Jiang et al. indicates that most cases are found in the upper part, while 14 of the 19 cases of squamous cell carcinoma occur in the distal segment. Tumors in the lower third generally exhibit less favorable survival outcomes compared to those in the upper third.

Notably, ACC is not linked to smoking and shows no sex predilection, affecting both men and women equally. Tracheal tumors tend to grow slowly and may remain asymptomatic until they obstruct 75% of the airway lumen. Symptoms include signs of upper airway obstruction, such as wheezing, stridor, or coughing, as well as hemoptysis due to mucosal irritation. Less than 25% of patients present with hemoptysis at an early stage.

Computed tomography (CT) is the standard imaging modality for evaluating intraluminal and extratracheal tumor extension, allowing visualization of tracheal wall thickening and the extraluminal extent of the mass. ACC often appears as a homogeneous mass surrounding the posterolateral wall of the trachea. While magnetic resonance imaging (MRI) is less frequently used, it offers better tissue characterization and can indicate the presence of an intraluminal mass or a tumor surrounding the trachea at 180° or more. Endoluminal ultrasound can also be beneficial for detecting compression and submucosal infiltration, aiding in achieving negative margins post-resection.

Tracheobronchial fibroscopy is essential for precise localization and confirmation of the diagnosis through biopsy, which can be challenging to interpret. Diagnosis of ACC is confirmed through histopathological examination, revealing histological features of cribriform, tubular, and solid types. The cribriform type is the most common, while tubular types, which are more differentiated, have a better prognosis. In contrast, solid types are associated with a poorer prognosis and an increased risk of metastases, particularly to the lungs. Immunohistochemical staining can support the diagnosis, showing positive expression for markers such as smooth muscle actin (SMA), p63, Ki-67, S100, and CD117.

Staging of tracheal cancer is crucial for guiding treatment and assessing prognosis. However, due to its rarity, there is no specific staging system. A recent study suggests the relevance of the TNM classification for tracheal cancer, given observed prognostic differences.

Treatment options include surgery, radiotherapy, or a combination of both. Surgical resection remains the primary approach for localized tracheal ACC, aiming for complete resection with negative margins. Radiotherapy has proven effective as a standalone treatment for inoperable ACCs, with neutron radiotherapy reporting a 5-year survival rate of 89% in a study involving 19 patients. Recent advancements in radiotherapy, such as intensity-modulated radiotherapy, have also shown effectiveness as adjuvant treatment.

The placement of endotracheal stents is considered for inoperable patients, primarily for palliative purposes or when radiotherapy is contraindicated, to mitigate obstructive recurrence. This procedure is usually preceded by endoscopic destruction of the lesion via rigid bronchoscopy. Tumor resection before surgery facilitates endotracheal intubation, essential for patient ventilation during the procedure.

Conventional chemotherapy has not demonstrated significant efficacy in treating ACC. However, ACCs express biomarkers such as Vascular Endothelial Growth Factor (VEGF) and c-kit mutations, which are associated with metastases and represent potential targets for targeted therapies, including tyrosine kinase inhibitors (TK). Although imatinib does not show efficacy as monotherapy for ACC, it demonstrates a partial response when combined with cisplatin in phase II trials. Similarly, cetuximab, an epidermal growth factor receptor (EGFR) inhibitor, shows a partial response when combined with cisplatin, with or without radiotherapy.

Conclusion:-

Adenoid cystic carcinoma is a rare tumor, and its low incidence underscores the importance of early diagnosis and a multidisciplinary approach involving thoracic surgeons, radiologists, and medical oncologists. This collaboration is essential for optimal treatment planning and improving patient outcomes.

Further research is crucial to enhance our understanding of the pathogenesis, molecular characteristics, and optimal management strategies for this rare malignant tracheal tumor. Early diagnosis is often overlooked, which can result in delays in treatment.

Several factors limit clinical trials on adenoid cystic carcinomas, including the small patient population, the prevalence of single-center studies, and the naturally slow progression of these tumors. These challenges highlight the necessity for multicentric trials, increased utilization of imaging analyses, and the identification of biomarkers specific to adenoid cystic carcinomas.

Conflict Of Interests

The authors declare no conflicts of interest.

References:-

1. Je HU, Song SY, Kim DK, Kim YH, Jeong SY, Back GM, et al. A 10-year clinical outcome of radiotherapy as an adjuvant or definitive treatment for primary tracheal adenoid cystic carcinoma. *Radiat Oncol Lond Engl*. 2017 Dec 4;12(1):196.DOI 10.1186/s13014-017-0933-6
2. Junker K. Pathology of tracheal tumors. *Thorac Surg Clin*. 2014 Feb;24(1):7–11.DOI: 10.1016/j.thorsurg.2013.09.008
3. Choi SG. Adenoid cystic carcinoma of distal trachea: A case report. *Clin Case Rep*. 2024;12(2):e8495.DOI: 10.1002/ccr3.8495
4. Thiam K, Carmassi M, Guinde J, Laroumagne S, Thomas P, Astoul P, et al. Medical-surgical management of tracheal adenoid cystic carcinoma: unity is strength. *Rev Mal Respir*. 2019 Jan 1;36(1):69–73.doi.org/10.1016/j.rmr.2018.03.005
5. Fei Q, Zhao H, Wang Y, Chen Y. Adenoid cystic carcinoma of trachea mimicking a thyroid follicular tumor: A case report and literature review. *Radiol Case Rep*. 2024 Dec 1;19(12):5653–7.doi.org/10.1016/j.radcr.2024.08.085

6. Shadmehr MB, Farzanegan R, Graili P, Javaherzadeh M, Arab M, Pejhan S, et al. Primary major airway tumors; management and results. *Eur J Cardio-Thorac Surg Off J Eur Assoc Cardio-Thorac Surg*. 2011 May;39(5):749–54. doi.org/10.1016/j.ejcts.2010.08.047
7. Analysis of clinical characteristics and prognosis of 57 patients with primary tracheal tumors - PubMed 2024 Dec 16.DOI: 10.21037/tcr.2019.11.55
8. Suemitsu R, Okamoto T, Maruyama R, Wataya H, Seto T, Ichinose Y. A long-term survivor after aggressive treatment for tracheal adenoid cystic carcinoma: a case report. *Ann Thorac Cardiovasc Surg Off J Assoc Thorac Cardiovasc Surg Asia*. 2007 Oct;13(5):335–7.
9. Zhu S, Schuerch C, Hunt J. Review and updates of immunohistochemistry in selected salivary gland and head and neck tumors. *Arch Pathol Lab Med*. 2015 Jan;139(1):55–66.doi: 10.5858/arpa.2014-0167-RA
10. Piórek: Do we need TNM for tracheal cancers? Analysis... - Google Scholar 2024 Dec 16.doi.org/10.3390/cancers14071665
11. Brand-Saberi BEM, Schäfer T. Trachea: anatomy and physiology. *Thorac Surg Clin*. 2014 Feb;24(1):1–5.DOI: 10.1016/j.thorsurg.2013.09.004
12. Silicone stents, the rigid bronchoscope, and the standard of care in central airway stenosis | Current Pulmonology Reports 2024 Dec 16.doi.org/10.1007/s13665-011-0003-8
13. Laurie SA, Ho AL, Fury MG, Sherman E, Pfister DG. Systemic therapy in the management of metastatic or locally recurrent adenoid cystic carcinoma of the salivary glands: a systematic review. *Lancet Oncol*. 2011 Aug;12(8):815–24.DOI : 10.1016/S1470-2045(10)70245-X
14. Bell D, Hanna EY. Head and neck adenoid cystic carcinoma: what is new in biological markers and treatment? *Curr OpinOtolaryngol Head Neck Surg*. 2013 Apr;21(2):124–9.DOI : 10.1097/MOO.0b013e32835c05fd.