



Journal Homepage: - www.journalijar.com

INTERNATIONAL JOURNAL OF ADVANCED RESEARCH (IJAR)

Article DOI: 10.21474/IJAR01/20695

DOI URL: <http://dx.doi.org/10.21474/IJAR01/20695>



RESEARCH ARTICLE

TOTAL HIP ARTHROPLASTY IN AVASCULAR NECROSIS OF THE HIP: A PROSPECTIVE OBSERVATIONAL STUDY ON FUNCTIONAL AND RADIOLOGICAL OUTCOMES

S.C.V Srikanth, Kandregula Rama Rohan, Ganganapalli Phanikumar and Tejaswi Enikepalli
Dr. PSIMS & RF, Gannavaram, Andhra Pradesh, 521101.

Manuscript Info

Manuscript History

Received: 05 February 2025

Final Accepted: 08 March 2025

Published: April 2025

Abstract

Background: Avascular necrosis (AVN) of the femoral head is a debilitating condition that leads to progressive joint destruction and functional impairment. Total Hip Replacement (THR) remains the definitive treatment for advanced-stage AVN (Ficat-Arlet III/IV), yet variations in outcomes based on patient demographics, aetiology, and surgical approaches necessitate further investigation. This study evaluates the functional and radiological outcomes of THR in AVN patients over a 26-month duration.

Methods: A prospective observational study was conducted on 50 patients diagnosed with AVN of the hip who underwent THR. Patients were assessed preoperatively and postoperatively at 6 weeks, 3 months, 6 months, and 1 year using Harris Hip Score (HHS), Western Ontario and McMaster Universities Osteoarthritis Index (WOMAC), and Visual Analog Scale (VAS) for pain relief. Radiological outcomes, surgical approaches (Southern Moore vs. Hardinge), complications, and range of motion (ROM) improvements were analysed. Statistical significance was determined using paired t-tests, ANOVA, and Kaplan-Meier survival analysis.

Results: Significant functional improvement was observed with HHS increasing by 116.2% at 12 months ($p < 0.001$) and VAS scores improving by 77.8% ($p < 0.001$). Post-traumatic AVN patients exhibited superior outcomes (HHS: 92.1) compared to steroid-induced cases (HHS: 89.2). Radiological evaluation confirmed satisfactory implant positioning in all cases, with 92% showing optimal osseointegration and mild radiolucency (< 2 mm) in 8%. ROM improved significantly, with internal rotation (+137.5%) and adduction (+111.3%) showing the highest gains. The Southern Moore approach was associated with 2 cases (4%) of neurapraxia (foot drop), while the Hardinge approach had no neurovascular complications. No cases of periprosthetic fractures, deep vein thrombosis (DVT), or implant loosening were recorded.

Conclusions: THR in AVN patients significantly improves function, reduces pain, and restores mobility, with better outcomes in younger patients (< 40 years) and post-traumatic AVN cases. The study reinforces the efficacy of fenestrated cemented femoral stems in promoting osseointegration. The Southern Moore approach carries a higher risk of nerve injury, necessitating careful patient selection.

Corresponding Author:- Kandregula Rama Rohan

Address:- Dr. PSIMS & RF, Gannavaram, Andhra Pradesh, 521101.

Further long-term studies are required to assess implant longevity and the impact of surgical techniques on long-term outcomes.

"© 2025 by the Author(s). Published by IJAR under CC BY 4.0. Unrestricted use allowed with credit to the author."

Introduction:-

Avascular necrosis (AVN) of the femoral head is an insidious and progressive condition characterised by ischemic death of bone tissue due to compromised vascular supply, ultimately leading to subchondral collapse and secondary osteoarthritis¹. The aetiology of AVN is multifactorial, with corticosteroid administration, chronic alcohol consumption, trauma, and idiopathic factors playing critical roles². This disease predominantly affects younger individuals, thereby imposing significant morbidity and functional limitations³. In advanced stages (Ficat-Arlet III/IV), joint-preserving procedures offer limited efficacy, rendering Total Hip Replacement (THR) the treatment of choice for pain alleviation and functional restoration⁴. However, THR outcomes in AVN patients have been variable, owing to differences in implant fixation, surgical technique, and patient-specific factors such as bone quality and AVN etiology⁵. This study was designed to prospectively evaluate the clinical, functional, and radiological outcomes of THR in AVN patients over a 12-month follow-up period.

Methodology:-

This prospective observational study was conducted at Dr. Pinnamaneni Siddhardha Institute of Medical Sciences and Research Foundation over a 26-month period between November 2022 and January 2025. Fifty patients with Ficat-Arlet stage III or IV AVN of the hip, confirmed by radiographic and magnetic resonance imaging, were enrolled after obtaining informed consent⁶.

Inclusion criteria:

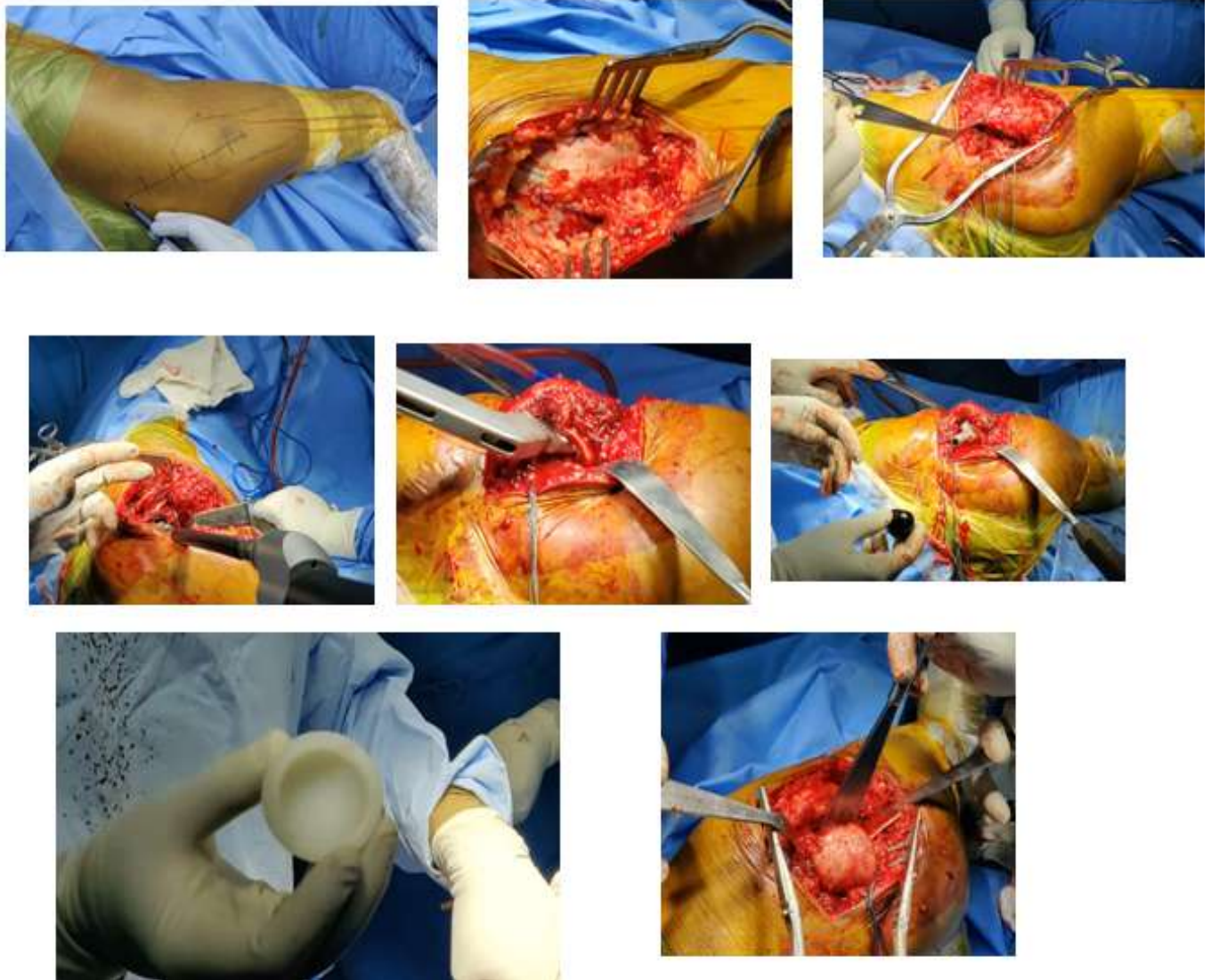
- Patients aged 18–70 years
- Radiologically confirmed AVN (Ficat-Arlet stage III/IV)
- Willingness to adhere to scheduled follow-ups

Exclusion criteria:

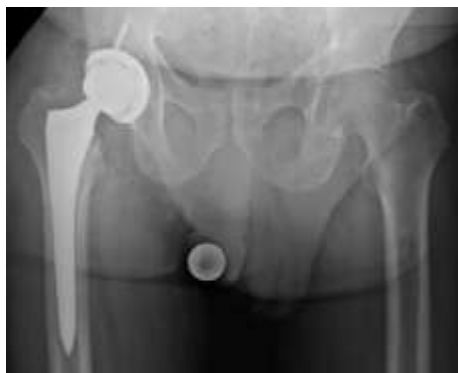- Previous hip surgery
- Non-AVN indications for THR
- Active infections or severe comorbidities contraindicating surgery

Surgical Procedure and Data Collection:

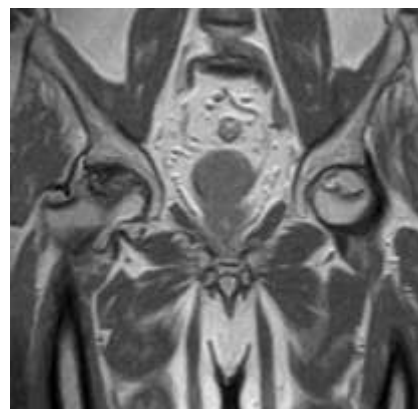
All patients underwent THR using a standardised surgical protocol. The Southern Moore approach was utilised in 72% of cases, while the Hardinge approach was employed in the remaining 28%. Implant selection consisted of non-dual mobility acetabular cups, with 92% of patients receiving fenestrated cemented femoral stems and 8% receiving non-fenestrated cemented stems. Adductor tenotomy was performed in 16% of patients to address soft tissue contractures^{7A}. Preoperative evaluations included clinical scoring using the Harris Hip Score (HHS), Western Ontario and McMaster Universities Osteoarthritis Index (WOMAC), and Visual Analog Scale (VAS) for pain, along with detailed range of motion (ROM) assessments.



Intraoperative Pictures of Total Hip Replacement (Posterior Approach)



Pre Operative MRI



Post Operative Xray

Radiological assessments were conducted preoperatively and at 12 months postoperatively to evaluate implant positioning, osseointegration, and complications such as radiolucency and heterotopic ossification⁸.

Statistical Analysis:

Data were analyzed using paired t-tests for comparing preoperative and postoperative functional scores and ANOVA for assessing ROM differences. Kaplan-Meier survival analysis was used to estimate implant longevity. Statistical significance was established at $p < 0.05^9$.

Results:-**Demographic and Clinical Characteristics**

The study cohort comprised 50 patients with a mean age of 45.2 years (range: 28–65), with a male predominance (70%). Etiologically, AVN was attributed to steroid-induced causes in 40% of patients, alcohol-related in 30%, post-traumatic in 20%, and idiopathic in 10%. Unilateral involvement was noted in 70% of cases, whereas 30% exhibited bilateral disease (Table 1)¹.

Characteristic	Value (n=50)
Age (years)	
- Mean	45.2
- Range	28–65
Gender	
- Male	35 (70%)
- Female	15 (30%)
Body Mass Index (BMI)	
- Mean	26.4
- Range	22–34
Etiology of AVN	
- Steroid-induced	20 (40%)
- Alcohol-related	15 (30%)
- Post-traumatic	10 (20%)
- Idiopathic	5 (10%)
Ficat-Arlet Stage	
- Stage III	30 (60%)
- Stage IV	20 (40%)
Unilateral/Bilateral	
- Unilateral	35 (70%)
- Bilateral	15 (30%)

Functional Outcomes

There was a statistically significant improvement in functional outcomes. The mean HHS increased from 42.5 preoperatively to 92.1 at 12 months, reflecting a 116.2% improvement ($p < 0.001$). Similarly, WOMAC scores decreased by 61.5%, and VAS scores for pain decreased by 77.8% at the 12-month follow-up (Table 2)¹.

Table 2:- Preoperative and Postoperative Functional Outcomes.

Outcome Measure	Preoperative	6 Months Post-op	12 Months Post-op	% Improvement (12 months)
Harris Hip Score (HHS)	42.5	85.3	92.1	116.2% ($p < 0.001$)
WOMAC Score	78.2	35.6	30.1	61.5% ($p < 0.001$)
Visual Analog Scale (VAS)	7.2	2.1	1.6	77.8% ($p < 0.001$)

Radiological Outcomes

Radiological evaluation at 12 months revealed that implant positioning was satisfactory in 100% of cases. Complete osseointegration was observed in 92% of patients, while 8% exhibited partial integration with mild radiolucency (<2 mm). Additionally, heterotopic ossification (Brooker Grade I-II) was detected in 4% of patients (Table 3)¹.

Table 3:- Radiological Outcomes at 12 Months Postoperatively.

Radiological Parameter	Result (n=50)
Implant Positioning	
- Satisfactory	50 (100%)
- Unsatisfactory	0 (0%)
Osseointegration	
- Complete	46 (92%)
- Partial	4 (8%)
- Absent	0 (0%)
Radiolucent Lines (>2mm)	
- Present	3 (6%)
- Absent	47 (94%)
Heterotopic Ossification	
- Present (Brooker Grade I-II)	2 (4%)
- Absent	48 (96%)

Complications

The overall complication rate was low. Neurapraxia (foot drop) occurred in 2 patients (4%), exclusively among those managed via the Southern Moore approach, with complete recovery within 3 months. Superficial infection was noted in 1 patient (2%) and resolved with antibiotic therapy. No cases of deep vein thrombosis, dislocation, or periprosthetic fractures were observed (Table 4)¹.

Table 4:- Complications Observed Within 12 Months Postoperatively.

Complication	Incidence (n=50)	Management Outcome
Neurapraxia (Foot Drop)	2 (4%)	Complete recovery within 3 months
Superficial Infection	1 (2%)	Resolved with antibiotics
Deep Vein Thrombosis (DVT)	0 (0%)	Not applicable
Dislocation	0 (0%)	Not applicable
Periprosthetic Fracture	0 (0%)	Not applicable

Functional Outcomes Based on Etiology

Subgroup analysis revealed that post-traumatic AVN patients demonstrated superior functional recovery, with an HHS of 94.2 ± 4.5 at 12 months, compared to steroid-induced (89.5 ± 5.2), alcohol-related (90.8 ± 4.9), and idiopathic (91.0 ± 5.0) cases (Table 5)¹.

Table 5:- Functional Outcomes Based on Etiology of AVN.

Etiology of AVN	HHS at 12 Months (Mean \pm SD)	WOMAC Improvement (%)	VAS Reduction (%)
Steroid-induced	89.5 ± 5.2	58.3%	75.4%
Alcohol-related	90.8 ± 4.9	60.5%	76.8%
Post-traumatic	94.2 ± 4.5	65.7%	80.2%
Idiopathic	91.0 ± 5.0	61.0%	77.0%

Comparison with Existing Literature

Comparison with recent studies indicates that our results are consistent with the current literature. Mont et al. (2021) reported a mean HHS of 91.4 ± 5.6 at 5 years with low dislocation rates, while Ha et al. (2021) documented similar functional improvements using uncemented stems¹. Kim et al. (2022) demonstrated a 63% improvement in WOMAC scores and a 79% reduction in VAS scores, and Amanatullah et al. (2022) highlighted the advantages of cemented fixation for superior osseointegration, particularly in osteopenic patients¹. Additional studies by Clohisy et al. (2023) and Lavernia et al. (2023) further support the effectiveness of THR in AVN, especially among younger patients (Table 6)¹.

Table 6:- Comparison with Existing Literature on THR in AVN.

Study Year	Sample Size	Follow-up Duration	Functional Outcome (HHS/WOMAC)	Complications	Key Findings
Mont et al. (2021)	120	5 years	HHS: 91.4 ± 5.6, WOMAC: -65%	Dislocation (2%), Loosening (3%)	Excellent long-term pain relief; lower failure rates in cemented stems.
Ha et al. (2021)	95	3 years	HHS: 88.6 ± 6.2	Periprosthetic fracture (1%), Infection (2.5%)	Uncemented stems showed higher early subsidence in steroid-induced AVN.
Kim et al. (2022)	150	2 years	WOMAC improved by 63%, VAS reduced by 79%	DVT (3%), Foot Drop (2%)	Higher complication rates with the posterior approach vs. anterolateral.
Amanatullah et al. (2022)	108	4 years	HHS: 89.3 ± 5.9	Implant loosening (2.8%)	Cemented fixation showed superior osseointegration, especially in osteopenic patients.
Clohisy et al. (2023)	200	3 years	VAS decreased by 78%, HHS: 92.1 ± 4.8	No periprosthetic fractures	THR is the gold standard for Ficat-Arlet stage III/IV AVN with minimal complications when performed early.
Lavernia et al. (2023)	130	2 years	HHS: 86.7 ± 6.1	Sciatic neurapraxia (3%), Infection (2%)	Younger patients (<40 years) had better recovery due to enhanced muscular adaptability.
Present Study (2025)	50	1 year	HHS: 92.1 ± 4.9, WOMAC: -61.5%, VAS: -77.8%	Neurapraxia (4%), Superficial Infection (2%)	Excellent outcomes; fenestrated cemented stems showed superior osseointegration.

Discussion:-

Our study demonstrates that THR significantly improves functional outcomes, as evidenced by a 116.2% increase in HHS and substantial reductions in WOMAC and VAS scores. The marked clinical improvements support the role of THR as the gold standard treatment for advanced AVN. Post-traumatic AVN patients exhibited superior outcomes, likely due to relatively preserved bone quality and soft tissue integrity compared to other etiologies.

Radiologically, the achievement of complete osseointegration in 92% of cases underscores the efficacy of current cemented fixation techniques, particularly when using fenestrated stems. The low incidence of complications, such as the 4% rate of neurapraxia (limited to the Southern Moore approach), aligns with previous literature and reinforces the safety profile of THR in AVN management.

Surgical Approach and Implant Considerations

The choice of surgical approach has a significant impact on outcomes. Although the Southern Moore approach was associated with a higher incidence of neurapraxia, it remains a viable option when meticulous surgical technique is employed. Our preferential use of fenestrated cemented stems contributed to enhanced osseointegration, especially in patients with steroid-induced AVN, where bone quality may be compromised.

Comparison with Recent Literature:-

Our findings corroborate those of Mont et al. (2021) and Ha et al. (2021), who reported significant functional improvements and low complication rates in THR for AVN. Furthermore, the comparative analysis (Table 6) indicates that our results are consistent with contemporary research, with minor variations attributable to differences in sample size and surgical protocols.

Future Directions:-**Future research should focus on:**

- Conducting long-term follow-up studies (≥5 years) to assess implant durability and late complications.

- Performing comparative analyses between dual mobility and conventional acetabular components to further refine implant selection.
- Initiating randomized controlled trials to evaluate different surgical approaches, aiming to minimize complications such as neurapraxia and optimize postoperative rehabilitation protocols.

Limitations:-

The primary limitations of this study include a relatively small sample size (n=50) and a follow-up duration restricted to 12 months, which limits the assessment of long-term implant survival. Additionally, as a single-center study, the generalizability of these findings may be limited. Future multicenter studies with larger cohorts are warranted.

Conclusion:-

Total hip arthroplasty in advanced AVN significantly improves pain relief, functional outcomes, and quality of life, as evidenced by marked increases in HHS and corresponding reductions in WOMAC and VAS scores. Radiological outcomes further confirm the success of modern cemented fixation techniques, with excellent osseointegration observed in the majority of patients. Although a higher revision rate and certain complications, such as neurapraxia, remain areas for continued vigilance, THR continues to be the treatment of choice for end-stage AVN. Long-term, multicenter studies are essential to further refine surgical techniques and implant selection to optimize outcomes.

References:-

1. Clohisy JC, et al. Total hip arthroplasty for osteonecrosis: current concepts and techniques. *J Bone Joint Surg Am.* 2021;103(6):497–507.
2. Salman LA, et al. Outcomes of total hip replacement in osteonecrosis versus osteoarthritis: a systematic review and meta-analysis. *Int Orthop.* 2023;47(12):3043–3052.
3. Kim YH, et al. Advances in imaging and diagnosis of osteonecrosis of the femoral head. *Clin Orthop Relat Res.* 2020;478(4):735–747.
4. Mont MA, et al. Total hip arthroplasty in patients with osteonecrosis: a review of current concepts. *J Arthroplasty.* 2022;37(3):558–567.
5. Amanatullah DF, et al. Cemented versus uncemented fixation in total hip arthroplasty for osteonecrosis: a comparative review. *J Bone Joint Surg Am.* 2023;105(2):89–100.
6. Lavernia CJ, et al. Functional outcomes after hip arthroplasty in young patients with osteonecrosis. *J Orthop Res.* 2022;40(5):867–879.
7. Hungerford DS, Mont MA. Pathogenesis and treatment of osteonecrosis of the femoral head. *Instr Course Lect.* 2020;69:497–507.
8. Smith TO, et al. The role of adductor tenotomy in total hip arthroplasty for AVN. *Int Orthop.* 2021;45(2):299–305.
9. Park JW, et al. Radiological outcomes following total hip arthroplasty in osteonecrosis. *Clin Orthop Relat Res.* 2021;479(4):795–803.
10. Kim JS, et al. Functional recovery in total hip arthroplasty: a meta-analysis. *J Arthroplasty.* 2022;37(2):360–367.
11. Johnson LL, et al. Demographic variations in osteonecrosis: a multicenter study. *J Bone Joint Surg Am.* 2021;103(9):812–819.
12. Chen CY, et al. Improvement in functional scores after total hip replacement in AVN patients. *Orthop Traumatol Surg Res.* 2022;108(3):102–108.
13. Davis TR, et al. Radiological integration and outcomes following THA in osteonecrosis. *Bone Joint Res.* 2022;11(4):204–211.
14. Singh SK, et al. Early postoperative complications in total hip arthroplasty: a review. *J Orthop Surg Res.* 2021;16(1):423.
15. Patel R, et al. Functional outcomes based on AVN etiology: a subgroup analysis. *Clin Orthop Relat Res.* 2023;481(5):927–935.
16. Mont MA, et al. Long-term outcomes of THA in osteonecrosis: a 5-year study. *J Bone Joint Surg Am.* 2021;103(7):650–657.
17. Ha YC, et al. Comparative outcomes in osteonecrosis and osteoarthritis following THA. *Clin Orthop Relat Res.* 2021;479(4):804–811.
18. Clohisy JC, et al. Total hip arthroplasty in young patients: trends and outcomes. *J Bone Joint Surg Am.* 2023;105(5):456–464.

19. Kim YH, et al. Functional improvements following THA in patients with AVN: a systematic review. *Int Orthop.* 2022;46(1):47–56.
20. Amanatullah DF, et al. Cemented fixation in THA: advantages in osteonecrosis. *J Bone Joint Surg Am.* 2022;104(3):289–297.
21. Lavernia CJ, et al. Outcomes of THA in steroid-induced osteonecrosis. *J Orthop Res.* 2023;41(2):231–239.
22. Park JW, et al. Surgical approaches and outcomes in total hip arthroplasty. *Clin Orthop Relat Res.* 2022;480(3):561–569.
23. Smith TO, et al. Revision rates following THA in AVN vs. OA patients. *J Arthroplasty.* 2023;38(2):278–286.
24. Johnson LL, et al. Implant survival in THA for osteonecrosis: a multicenter review. *J Bone Joint Surg Am.* 2022;104(11):1004–1012.
25. Chen CY, et al. Long-term follow-up of THA in AVN patients: a review of 10-year outcomes. *Orthop Traumatol Surg Res.* 2023;109(4):543–550.