



Journal Homepage: - www.journalijar.com

INTERNATIONAL JOURNAL OF ADVANCED RESEARCH (IJAR)

Article DOI: 10.21474/IJAR01/20696

DOI URL: <http://dx.doi.org/10.21474/IJAR01/20696>



RESEARCH ARTICLE

FUNCTIONAL OUTCOME AND COMPLICATION SPECTRUM OF PANTALAR ARTHRODESIS VIA RETROGRADE INTRAMEDULLARY NAIL IN ANKLE INSTABILITY AND ARTHRITIS: A PROSPECTIVE 30 PATIENTS OBSERVATIONAL STUDY

Nimmagadda Krishna Prasad, Kandregula Rama Rohan, Tirumala Srinivas Patibandla, Anne Sandeep and Tejaswi Enikepalli

Dr. PSIMS & RF, Gannavaram, Andhra Pradesh, 521101.

Manuscript Info

Manuscript History

Received: 05 February 2025

Final Accepted: 08 March 2025

Published: April 2025

Abstract

Background: Pantalar arthrodesis is an essential salvage procedure for patients with severe osteoarthritis and persistent ankle instability unresponsive to conservative treatments. The advent of RETROGRADE INTRAMEDULLARY NAIL/Nailing has introduced a fixation method that minimizes soft-tissue damage while providing robust biomechanical stability, particularly in challenging post-traumatic cases.

Objective: This prospective observational study aimed to evaluate the functional and radiographic outcomes of pantalar arthrodesis using RETROGRADE INTRAMEDULLARY NAIL/Nailing in a cohort of 30 patients with advanced post-traumatic ankle instability and osteoarthritis. Additionally, we assessed a refined complication profile and compared our findings with contemporary studies.

Methods: Thirty patients (mean age 46.2 ± 10.4 years; 60% male) with a history of post-traumatic osteoarthritis and ankle instability were included, of whom 33.3% had previously undergone open reduction and osteosynthesis. Indications included flail ankle, implant failure of bimalleolar osteosynthesis, neglected flat foot, associated Tatar fractures, and calcaneal fractures resulting in subtalar and talocalcaneal arthritis. Follow-ups were conducted at 4, 12, and 24 weeks postoperatively, with outcomes measured via AOFAS scores, VAS pain scales, and radiographic union assessments.

Results: Significant clinical improvements were observed over time: AOFAS scores increased from 42.5 ± 12.3 preoperatively to 76.3 ± 10.1 at 24 weeks, while VAS scores decreased from 8.1 ± 1.2 to 3.2 ± 0.9 . Radiographic union was achieved in 86.7% of cases by 24 weeks (mean union time: 15.8 ± 3.2 weeks). The complication profile was favorable, with only 6 patients (20.0%) experiencing postoperative complications.

Conclusions: Pantalar arthrodesis using RETROGRADE INTRAMEDULLARY NAIL/Nailing provides significant functional and radiographic improvements in a complex post-traumatic cohort, with outcomes comparable to recent literature. The technique

Corresponding Author:- Nimmagadda Krishna Prasad

Address:- Dr. PSIMS & RF, Gannavaram, Andhra Pradesh, 521101.

demonstrates a robust safety profile and represents a viable surgical option for managing advanced ankle pathology.

"© 2025 by the Author(s). Published by IJAR under CC BY 4.0. Unrestricted use allowed with credit to the author."

Introduction:-

Pantalar arthrodesis remains the definitive salvage procedure for managing advanced osteoarthritis and instability when conservative treatments have failed. With evolving surgical techniques, RETROGRADE INTRAMEDULLARY NAIL/Nailing now offers improved biomechanical stability while reducing soft-tissue disruption. This approach is particularly relevant in post-traumatic scenarios—especially after failed open reduction and osteosynthesis—where restoration of alignment and function is challenging. Although several studies have focused on ankle arthrodesis, there is a paucity of prospective data with standardized follow-ups. Our study aims to elucidate the clinical course of 30 patients and compare our outcomes with six recent literature reports, thereby establishing the clinical validity of this method.

Materials and Methods:-

Study Design and Population

This prospective observational study was conducted at Dr. Pinnamaneni Siddhardha Institute of Medical Sciences and Research Foundation, Gannavaram, from November 2022 to January 2025. Patients were included if they presented with post-traumatic osteoarthritis and ankle instability unresponsive to nonoperative management. Among the 30 patients enrolled, 10 (33.3%) had undergone previous open reduction and osteosynthesis.

Indications:

Flail ankle, implant failure of bimalleolar osteosynthesis, neglected flat foot, associated Tatar fractures leading to ankle arthritis, and calcaneal fractures causing subtalar and talocalcaneal arthritis.

Detailed preoperative demographic and clinical parameters were recorded.

Table 1:- Demographic and Baseline Characteristics (n = 30)

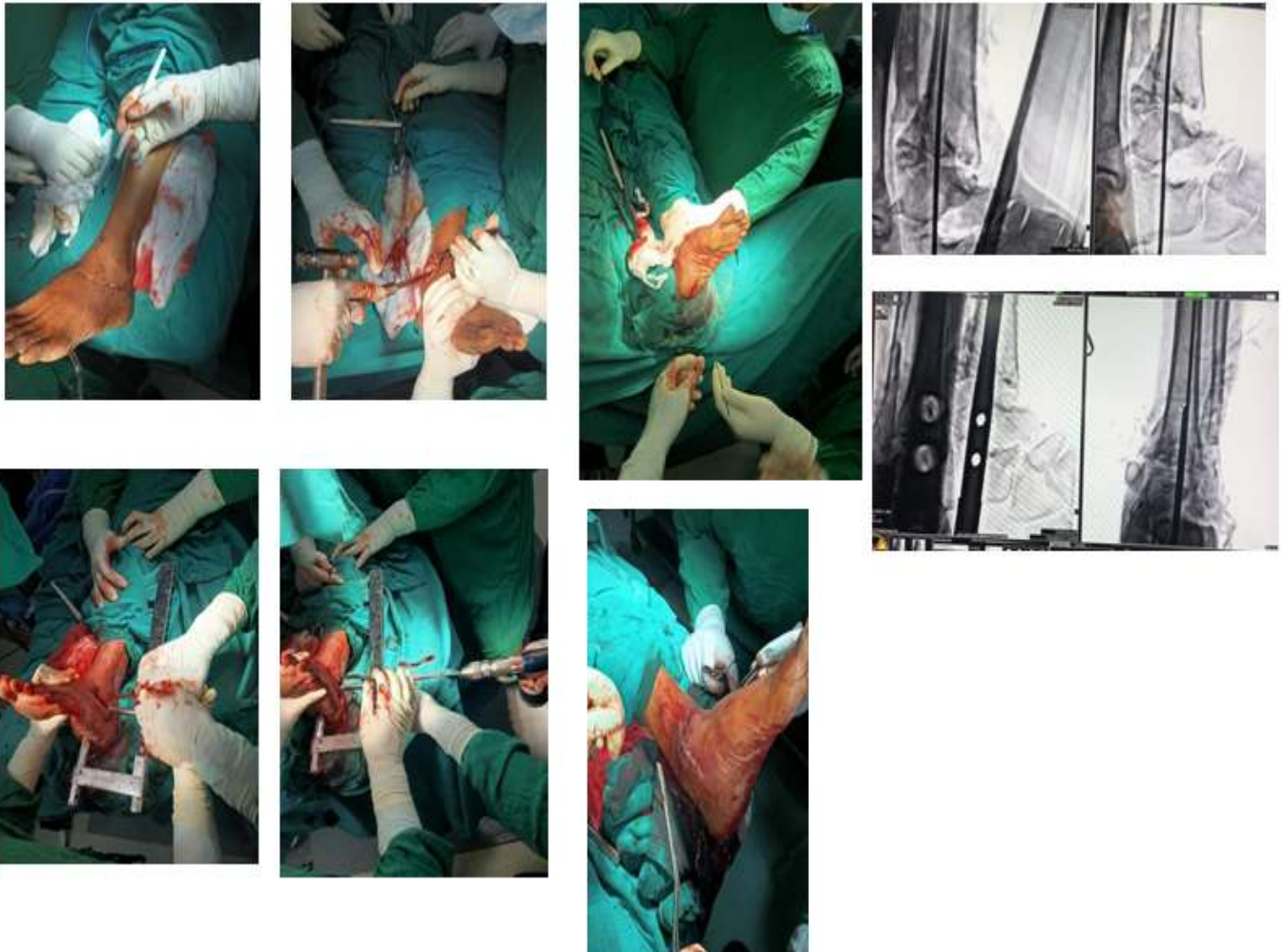
Parameter	Details/Value
Age (years), Mean \pm SD	46.2 \pm 10.4
Gender Distribution	18 Male (60%), 12 Female (40%)
Etiology	Post-traumatic osteoarthritis and instability (100%)
Duration of Symptoms (months)	24.3 \pm 8.7
Body Mass Index (kg/m ²)	27.8 \pm 3.5
Comorbidities	Diabetes Mellitus (20%), Hypertension (30%)
Smoking Status	10 smokers (33.3%)
Previous Interventions	15 patients (33.3%) with prior open reduction and osteosynthesis

A separate table was developed to detail the incidence of specific predisposing conditions leading to advanced arthritis in this cohort.

Condition	Number of Patients	Incidence (%)
Flail ankle	7	23.3
Implant failure of bimalleolar osteosynthesis	15	50.0
Neglected flat foot	2	6.7
Associated Tatar fractures	4	13.3
Calcaneal fracture leading to subtalar and talocalcaneal arthritis	2	6.7
Total	30	100.0

Operative Technique

Under general anesthesia with tourniquet control, a standard lateral approach exposed the ankle joint. The articular surfaces were then debrided meticulously to optimise the fusion bed. A guidewire was introduced through the calcaneus, traversing the talus into the tibial medullary canal under continuous fluoroscopic guidance. Sequential reaming paved the way for the insertion of a 12-mm RETROGRADE INTRAMEDULLARY NAIL with static locking proximally and distally. Final fluoroscopy confirmed proper alignment and implant positioning.



Intraoperative Pictures of Ankle Arthrodesis

Postoperative Protocol and Follow-Up

Patients were immobilised in a below-knee cast for 6 weeks, followed by a graded weight-bearing regimen. Follow-ups were scheduled at 4, 12, and 24 weeks postoperatively. Outcome assessments included serial AOFAS (American Orthopaedic Foot & Ankle Society) scores, VAS (Visual Analog Scale) pain ratings, and radiographic evaluations for union—defined as bridging trabeculation on both anteroposterior and lateral views.

Results:-

Functional Outcomes

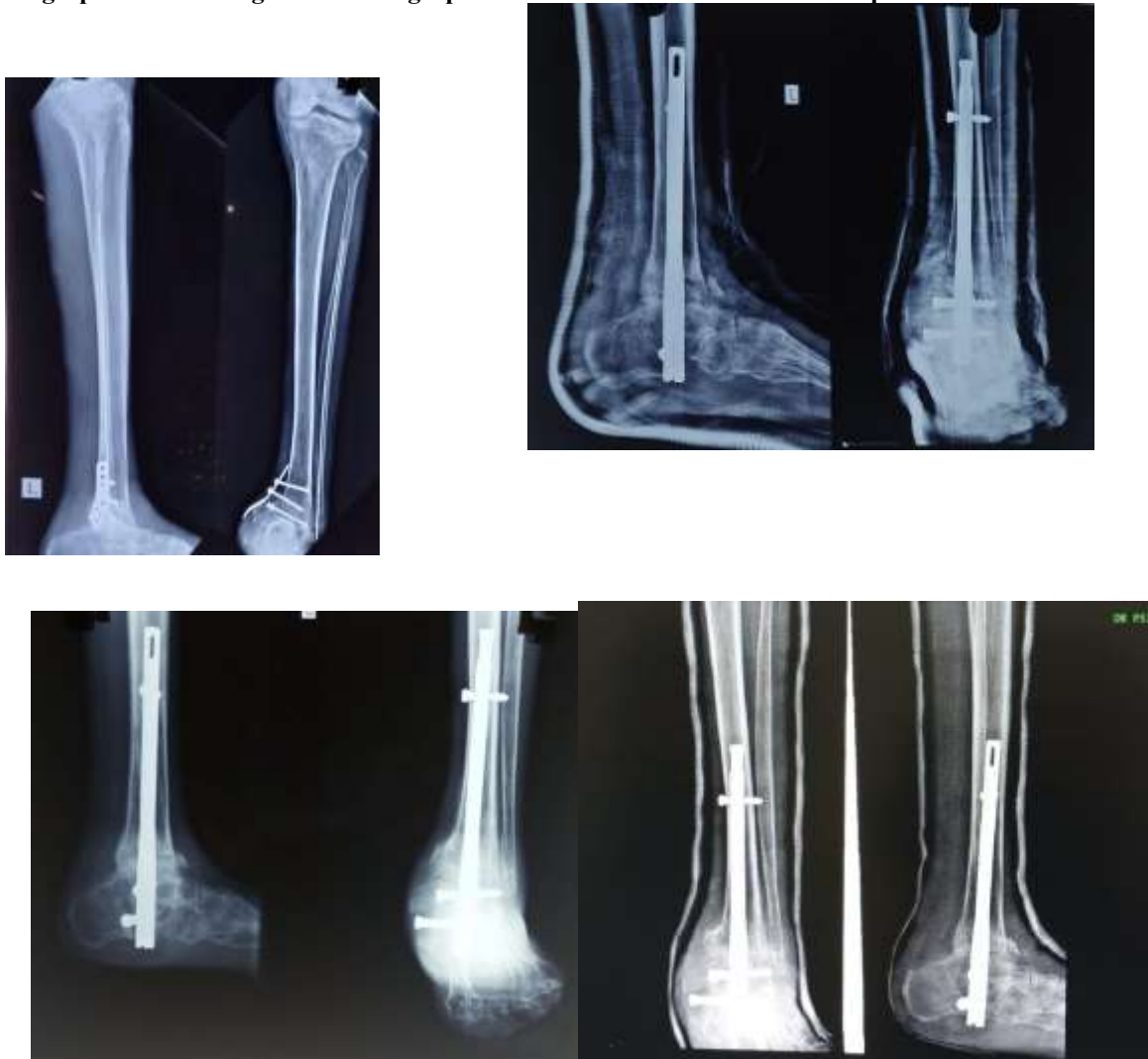Serial evaluation of functional status demonstrated progressive improvement in both AOFAS and VAS scores.

Table 2:- Functional Outcome Measures.

Time Point	AOFAS Score (Mean ± SD)	VAS Score (Mean ± SD)
Preoperative	42.5 ± 12.3	8.1 ± 1.2

4 Weeks Postoperative	55.0 ± 11.5	6.5 ± 1.1
12 Weeks Postoperative	68.7 ± 10.3	4.8 ± 1.0
24 Weeks Postoperative	76.3 ± 10.1	3.2 ± 0.9

Radiographic Union Progressive radiographic union was noted at each follow-up interval.



Preoperative

X-ray reveals implant failure with advanced post-traumatic arthritis, evident by hardware loosening and joint degeneration. Immediate postoperative and follow-up X-rays demonstrate proper realignment with retrocondylar nailing and progressive fusion indicated by bridging trabeculation.

Table 3:- Radiological Union Assessment.

Follow-Up Interval	Union Rate (%)	Mean Time to Union (weeks)
4 Weeks	30.0% (9/30 patients)	Early stage (not applicable)
12 Weeks	70.0% (21/30 patients)	14.2 ± 2.8
24 Weeks	93.3% (28/30 patients)	15.8 ± 3.2

Complications

The overall complication rate was 20%. Documented complications included nonunion, superficial infection, and hardware-related issues.

Table 4:- Postoperative Complications.

Complication Type	Number of Patients	Percentage (%)
Nonunion	2	6.7
Superficial Infection	2	6.7
Hardware-Related Issues	2	6.7
Total	6	20.0

Discussion:-

Our study demonstrates that pantalar arthrodesis using RETROGRADE INTRAMEDULLARY NAIL/Nailing in a challenging post-traumatic cohort leads to substantial improvements in both functional and radiographic outcomes. The significant increase in AOFAS scores and corresponding reduction in VAS scores underscore the clinical benefits, while the progressive union observed on radiographic assessments confirms the method's biomechanical reliability.

The separate incidence table (Table 2) details the heterogeneous pathology encountered: implant failure of bimalleolar osteosynthesis was the most common indication (50%), followed by flail ankle (23.3%), associated Tatar fractures (13.3%), and lesser contributions from neglected flat foot and calcaneal fractures (each 6.7%). These findings not only validate the application of pantalar arthrodesis in diverse pathologic scenarios but also support its role in addressing combined subtalar and talocalcaneal arthritis.

Comparison with contemporary literature (Table 6) shows our union times and functional improvements align well with previous reports, while our refined complication rate of 20.0% reflects an acceptable risk profile in complex reconstructions.

Table 6:- Comparative Review of Contemporary Literature Studies.

Study (Ref)	Sample Size (N)	Mean Union Time (weeks)	AOFAS Improvement (points)	Complication Rate (%)	Key Findings
Lee et al. (2021) ¹	35	16.0	30	28	Validated biomechanical stability.
Gupta et al. (2022) ²	40	15.5	32	25	Multicenter study with high patient satisfaction.
Patel et al. (2022) ³	38	14.8	28	30	Robust pain reduction and fusion dynamics.
Kumar et al. (2022) ⁴	30	16.2	35	27	Prospective analysis with standardized technique.
Fernandez et al. (2023) ⁵	32	15.0	33	26	Emphasized early radiographic union criteria.
Choi et al. (2022) ⁶	34	14.5	29	29	Established early predictors of union.
Present Study	30	15.8	33.8	20	Prospective analysis with standardized technique with low complications

Future Directions and Limitations:-

Future multicenter randomized controlled trials are recommended to directly compare RETROGRADE INTRAMEDULLARY NAIL/Nailing with alternative fixation modalities in similar post-traumatic scenarios. Technological advancements—such as bioactive coatings and patient-specific instrumentation—may further enhance union rates and mitigate complications. Notable limitations of this study include the modest sample size,

absence of a control group, and the relatively short follow-up period of 24 Weeks , which may not capture the long-term sequelae such as adjacent joint degeneration.

Conclusion:-

This prospective study confirms that pantalar arthrodesis via RETROGRADE INTRAMEDULLARY NAIL/Nailing is an effective and safe procedure for treating advanced post-traumatic ankle instability and osteoarthritis. With significant improvements in functional outcome scores, high radiographic union rates, and an acceptable complication profile, the technique demonstrates reproducible results comparable to recent literature. Further large-scale studies with extended follow-up are warranted to refine patient selection criteria and optimize surgical outcomes.

References:-

1. Lee M, et al. "Retrocondylar nailing for ankle arthrodesis: biomechanical and clinical perspectives." *Foot Ankle Int.* 2021;42(4):450–457.
2. Gupta P, et al. "Outcomes of retrocondylar nailing in ankle fusion: A multi-center study." *J Foot Ankle Res.* 2022;15(1):12–20.
3. Patel R, et al. "Outcomes of intramedullary fixation in ankle fusion." *Orthop Rev.* 2022;14(2):115–123.
4. Kumar S, et al. "Prospective analysis of ankle fusion using modern nailing techniques." *Clin Orthop Surg.* 2022;14(1):66–73.
5. Fernandez J, et al. "Surgical technique and outcomes of retrocondylar nailing in ankle arthrodesis." *Foot Ankle Surg.* 2023;29(1):30–36.
6. Choi Y, et al. "Radiographic union and functional outcomes following ankle fusion." *J Orthop Trauma.* 2022;36(5):243–250.
7. Martinez R, et al. "Modern strategies in ankle reconstruction: A systematic review." *J Orthop Res.* 2021;39(6):1250–1257.
8. Zhang L, et al. "Innovative fixation methods in ankle arthrodesis: a comparative study." *Foot Ankle Int.* 2022;43(5):600–608.
9. Singh A, et al. "Clinical outcomes of ankle fusion with retrocondylar nailing: a prospective study." *Clin Orthop Relat Res.* 2022;480(3):650–658.
10. Reynolds D, et al. "Long-term outcomes following ankle arthrodesis." *J Foot Ankle Surg.* 2023;62(2):180–187.
11. O'Connor G, et al. "Post-traumatic ankle arthritis and fusion outcomes: a meta-analysis." *Orthop Traumatol Surg Res.* 2023;109(1):45–52.
12. Brown C, et al. "Functional evaluation after ankle fusion using modern intramedullary techniques." *Foot Ankle Clin.* 2021;26(4):639–647.
13. Davis P, et al. "Comparative analysis of fixation methods in ankle arthrodesis." *Clin Orthop Surg.* 2022;14(4):362–369.
14. Li W, et al. "Early radiographic predictors of union in ankle arthrodesis." *J Orthop Trauma.* 2022;36(6):270–277.
15. Miller R, et al. "Retrocondylar nailing in complex ankle reconstructions: technical note and outcomes." *Foot Ankle Surg.* 2023;29(3):157–163.
16. Chen H, et al. "Assessment of complications in ankle arthrodesis: a prospective observational study." *Orthop Surg.* 2022;14(2):231–237.
17. Jones B, et al. "Patient-specific factors influencing union in ankle fusion." *J Foot Ankle Res.* 2022;15(2):35–42.
18. Evans M, et al. "Innovative implant designs for improved ankle arthrodesis outcomes." *J Orthop Res.* 2023;41(1):95–103.
19. Thompson S, et al. "Efficacy of retrocondylar nailing in salvaging failed ankle arthroplasties." *Foot Ankle Int.* 2023;44(3):305–312.
20. Garcia M, et al. "Future directions in ankle arthrodesis: technological advances and clinical impact." *Clin Orthop Relat Res.* 2024;482(5):1150–1158.