



### RESEARCH ARTICLE

## A CASE REPORT OF CALCINEURIN INHIBITOR RENAL TUBULOPATHY

Renu K Regi<sup>1</sup>, Meeta Thomas<sup>2</sup> and Lillykutty Pothan<sup>3</sup>

1. PG resident Department of pathology, Pushpagiri institute of medical sciences and research centre, Thiruvalla, Kerala, India.
2. Associate professor Department of pathology, Pushpagiri institute of medical sciences and research centre, Thiruvalla, Kerala, India.
3. Professor Department of pathology, Pushpagiri institute of medical sciences and research centre, Thiruvalla, Kerala, India.

### Manuscript Info

#### Manuscript History

Received: 22 February 2025  
Final Accepted: 25 March 2025  
Published: April 2025

#### Key words:-

Calcineurin inhibitor  
tubulopathy, kidney, transplant

### Abstract

Calcineurin Inhibitor tubulopathy refers to kidney damage caused by the use of calcineurin inhibitors, a type of immunosuppressive medication commonly used to prevent rejection in organ transplant patients. Kidney biopsy is often necessary to diagnose CNI tubulopathy. Adjusting the dose of CNI medications or switching to alternative immunosuppressive medications may help alleviate kidney damage. Here presenting a case of CNI tubulopathy in a renal transplant patient with delayed graft dysfunction.

"© 2025 by the Author(s). Published by IJAR under CC BY 4.0. Unrestricted use allowed with credit to the author."

### Introduction:-

Calcineurin Inhibitors (CNI) Improve Allograft Survival In Transplant Patients Of Which Routinely Used Are Cyclosporine And Tacrolimus. Cyclosporine Is Isolated From Fungus Tolypocladium Inflatum Gams And Tacrolimus Is Isolated From Fungus Streptomyces Tsukubaensis. Cnis Have Nephrotoxic Side Effects Which Occurs Early In The Post-Transplantation Phase. It Can Be Acute And Chronic Involving Tubular, Vascular And Glomerular Compartments. Acute Toxicity Is Reversible.

### CASE PRESENTATION

A 31 year old male with history of cadaveric renal transplant presented with delayed graft dysfunction after 2 months. Patient was on triple immunosuppression therapy-Tacrolimus, Mycophenolate mofetil and Wysolone.

Urine output: 1.8L

Lab investigations:

LDH: 1840 U/L, urea: 156 mg%, creatinine: 3.57 mg%

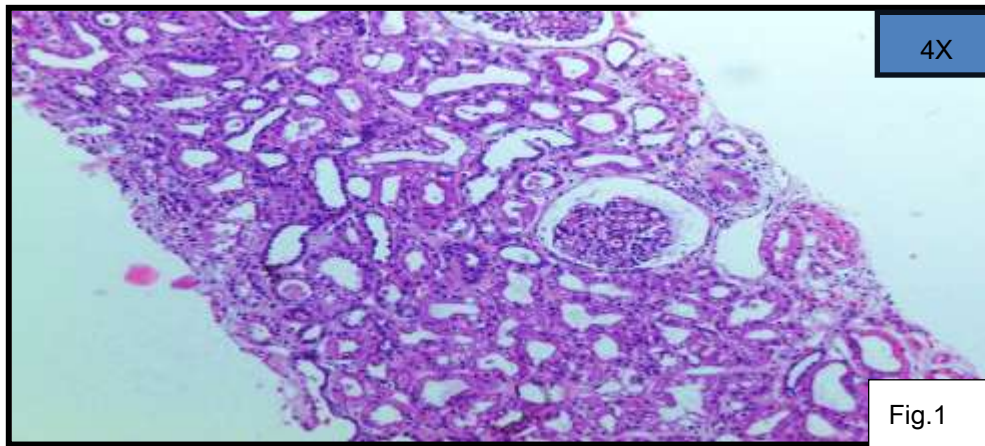
Ultrasonogram shows graft kidney with normal echogenicity and normal corticomedullary differentiation.

**MACROSCOPY**-Received 2 linear soft tissue cores in formalin measuring 0.8cm and 0.3cm and one in normal saline measuring 0.5cm in length.

**MICROSCOPY**- Shows 2 linear cores of renal cortical tissue with 12 glomeruli. 2 were globally sclerosed [Fig.1]

**Corresponding Author:-** Renu K Regi

**Address:-** PG resident Department of pathology, Pushpagiri institute of medical sciences and research centre, Thiruvalla, Kerala, India.



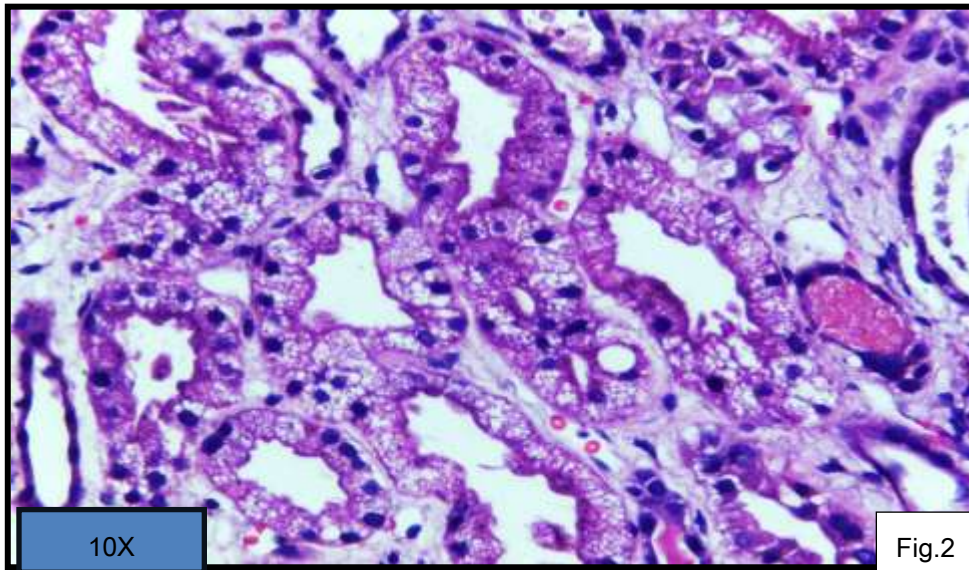
Glomeruli showed mild intercapillary matrix expansion and focal congestion of capillary loops.No glomerulitis(g-0).

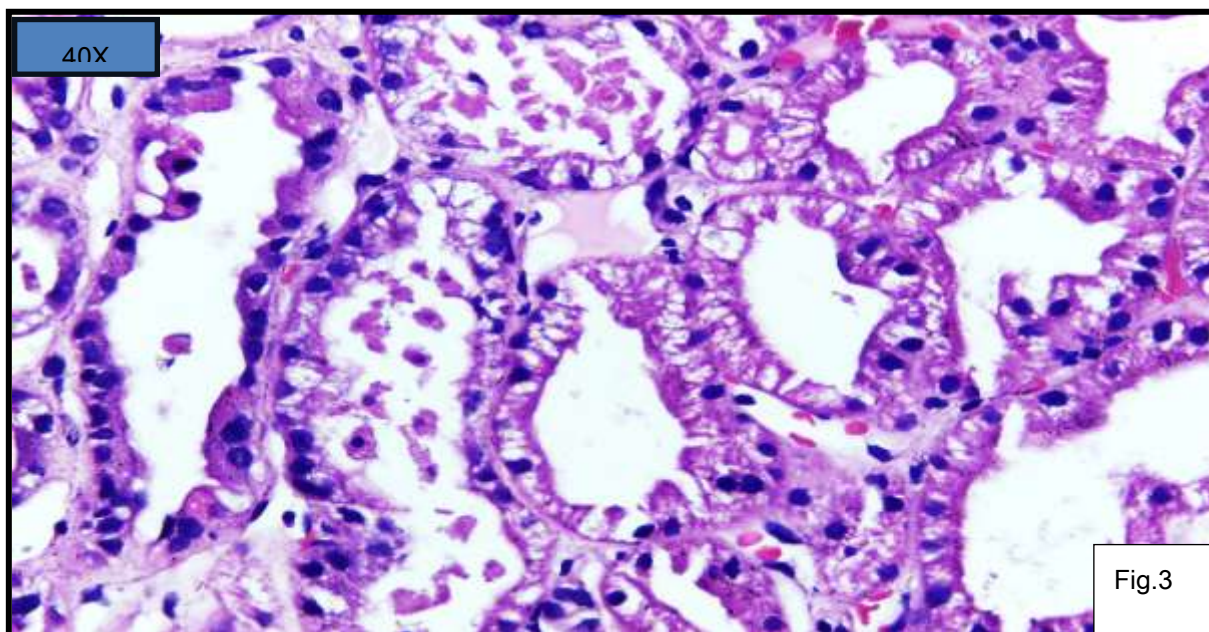
Interstitial edema and focal mild interstitial infiltrates of mononuclear inflammatory cells(<10%)(i-0) noted.

Tubules dilated and showed ballooning with diffuse isometric cytoplasmic vacuolization of lining epithelial cells[Fig.2],simplification of lining epithelium and sloughing of cells with intraluminal debris[Fig.3] noted.

Peritubular capillaries :opened out with occasional inflammatory cells(pte-0).

Vascular compartment showed mild hyaline change and mucoid deposits.





Immunofluorescence-

Negative for IgA,IgG,IgM,C3,kappa and lambda

Immunohistochemistry:

C4d showed negative staining (C4d-0,0-ptc)

**DIAGNOSIS**-Diffuse isometric vacuolar tubulopathy with focal acute tubular necrosis.

Correlation with serum Tacrolimus level were suggested.

Tacrolimus level was 4ng/ml and the dose was reduced.

### Discussion:

Calcineurin inhibitors (cyclosporin and tacrolimus) are potent immunosuppressants that improve graft survival, but can cause acute and chronic nephrotoxicity. Renal biopsy is a reliable tool to diagnose calcineurin inhibitor induced nephrotoxicity. Acute toxicity is characterised by necrosis, hyalinosis and vacuolation of proximal tubules. Chronic toxicity shows fibrosis of interstitium and tubular atrophy.

### DIFFERENTIAL DIAGNOSIS:

Acute toxicity:

Osmotic nephrosis have a history of mannitol or IV immunoglobulin infusion.

Chronic toxicity:

- Hypertensive arteriosclerosis shows atrophy of media.
- In diabetic arteriolar hyalinosis insudative lesions of glomerular capsular drops and fibrin caps seen.
- Transplant glomerulopathy shows circumferential duplication of GBM and C4d positivity.

**PROGNOSIS:** Acute CNI induced injury cause vasculopathy and tubulopathy which is reversible with dose reduction or discontinuation of the drug. Chronic CNI nephropathy is a progressive disease leading to irreversible tubulointerstitial damage and glomerulosclerosis. Proper management by regular monitoring of kidney function and biopsy is required. Adjusting the dose of CNI medications or switching to alternative immunosuppressive medications may help alleviate kidney damage.

### References:

1. Liptak P, Ivanyi B. Primer: histopathology of calcineurin-inhibitor toxicity in renal allografts. Nat Clin Pract Nephrol. 2006;2:398-404
2. Renal biopsy interpretation – Anila Korula: 203-205<sup>th</sup>
3. Heptinstall's Pathology of the kidney-7 Edition: 1391-1402