

	<p>Journal Homepage: - www.journalijar.com</p> <p>INTERNATIONAL JOURNAL OF ADVANCED RESEARCH (IJAR)</p> <p>Article DOI: 10.21474/IJAR01/20945 DOI URL: http://dx.doi.org/10.21474/IJAR01/20945</p>	
---	--	---

RESEARCH ARTICLE

PLEURAL EFFUSION: A RATIONALE APPROACH TO DIAGNOSIS AND MANAGEMENT.

Poonam Gupta, Meet Bhanushali, Swapnil jain, Anil Badal, Arti Julka and JC Agrawat.

1. RD Gardi Medical College, Surasa, Ujjain MP, India

Manuscript Info

Manuscript History

Received: 25 March 2025

Final Accepted: 28 April 2025

Published: May 2025

Key words:-

Adenosine deaminase (ADA), Close pleural biopsy (CPB), Malignant pleural effusion (MPE), Medical thoracoscopy (MT), pleurodesis, Tubercular pleural effusion (TPE), fiberoptic bronchoscopy (FOB)

Abstract

Background: Pleural effusion is a most common pleural disorder which can be due to multiple underlying pulmonary or systemic causes. The management of pleural effusion is based on history, clinical, radiologic and then analysis of pleural fluid with complete biochemical, cytologic, microbiological, histopathological examination. As a protocol the Lights criteria was applied to distinguish transudate and exudate effusion. The management also depends upon underlying disease for that acquisition of histopathological biopsy sample is required with use of precise and selective diagnostic tool.

Results: Study included 103 cases of pleural effusions, predominantly middle aged individuals with a mean age of 45.6 years. Males constituted the majority at 74.8%, reflecting a male predominance in the affected population. Cough (75.7%), breathlessness (73.8%), and chest pain (65.0%), were the main symptoms. The predominant etiology in the study population was TB (49%), followed by malignant effusions (19%) and Syn-pneumonic effusions in 17% accounted 17% of cases. Diagnostic and therapeutic procedures such as pleurocentesis (96%), intercostal drain (ICD) insertion (32%), and the therapeutic procedures i.e. fibrinolytic, adhesion and septation removal, and pleurodesis (24%) were also performed. The diagnostic yield improved with the use of simirigid thoracoscope and fiberptic bronchoscopy by 13% and 12% respectively.

Have become more acceptable and popular tool since past decade.

Discussion: The clinical examination and chest x-ray (CXR) are the simplest way to detect PLEF. Apart from the examination of PLEF for bio/ cyto/ microbes, the acquisition/ procurement of tissue for histological analysis becomes mandatory especially for undiagnosed cases. There are two known options for tissue biopsy: 1) a blind/ or closed pleural biopsy (CPB) with Abrams or Tru-cut needle and 2) a 'gold standard' surgical biopsy. However the USG guided pleural interventions are safe, cost effective, least invasive, radiation free and can be performed bed site with a comparable yield, where ever the computed tomography and thoracoscopy facilities are lacking.

"© 2025 by the Author(s). Published by IJAR under CC BY 4.0. Unrestricted use allowed with credit to the author."

An image-guided Tru-cut biopsies and the medical thoracoscopy (pleuroscopy) to directly visualize disease site under local anesthesia have become more acceptable and popular tool since past decade. Conclusion: The pleural effusion is most common ailment with underlying local, focal and generalized or systemic causes. The presentation of PLEF is wide and variable thus for the selection of diagnostic and therapeutic tool the patients comfort, consent, cost effectiveness, least complication, easy availability and feasibility should be considered. The mis or undiagnosed cases of PLEF should be again considered for a complete repeat examination after a suitable interval

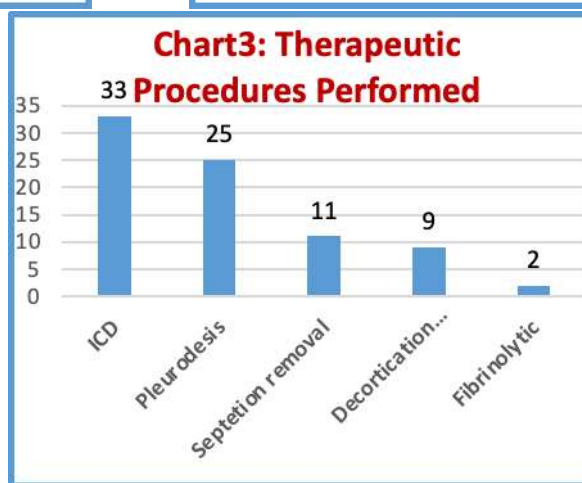
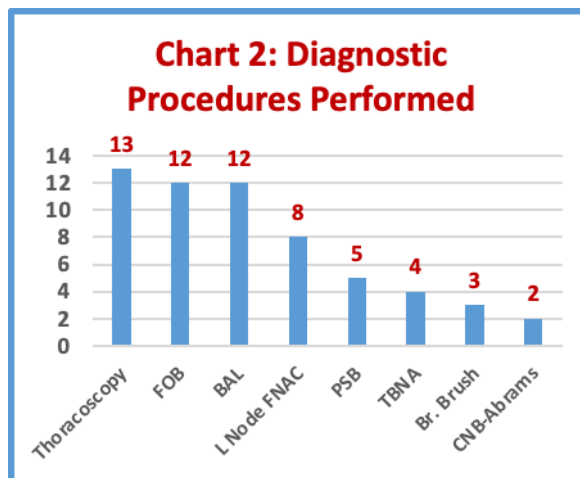
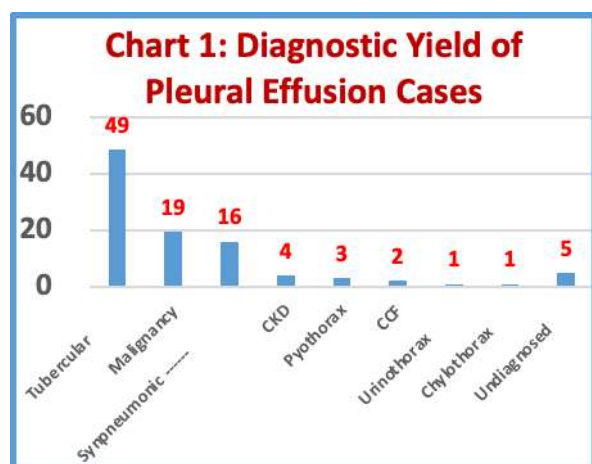
Introduction:-

Pleural effusion is the collection of fluid in the pleural space. The causes of pleural effusion varies by geographical areas and the local pattern of incident and prevalent of diseases. In developed countries the common causes of pleural effusions in adults which varies around 320/ Lac of population ⁽¹⁾ includes; cardiac failure, malignancy, and pneumonia, conversely in developing countries, tuberculosis is an important cause, para pneumonic effusions as is malignancy (lung or metastatic) being more prevalent. The accumulation of effusion is associated with various medical conditions that predispose to fluid buildup through various mechanisms (isolated or in combined) like increased pulmonary capillary pressure, decreased oncotic pressure, increased pleural membrane permeability, and lymphatic obstruction ⁽²⁾.

There is no need to emphasize that a meticulously taken history of the patient with thorough clinical examination plays a pivotal role in differential diagnosis of PLEF. A patient with pleural effusions typically present with dyspnea because of compressed and displaced lung and mediastinum with reduced vital capacity. They may also have cough, sharp pleuritic chest pain (radiating/ nonradiating), there may accompanying fever (denotes underlying infection/inflammation), expectoration (Parenchymal disease), haemoptysis (Pulmonary thromboembolism) and clinical findings suggestive of collapse or consolidation are some of the examples. Apart from the diseases of the pleura itself (e.g. mesothelioma) and the lung, there are wide spectrum of systemic diseases including the co-morbidities i.e. cardiac, renal, liver, pancreatic, thyroid (myxedema), drug induced, post radiotherapy, ovarian hyperstimulation syndrome and connective tissue or autoimmune disorders (like rheumatoid arthritis or lupus) etc. are some of the other rarer causes of PLEF. The pleural fluid has to be carefully drained, with under perfect aseptic precautions to investigate the etiology. The physical appearance of drained PLEF may provides a clue toward diagnosis e.g. odor, color, transparent or opaque/ turbid etc and it could be further classified according to the Light's criteria as exudative or transudative. These two type of fluids enable to narrow the differential diagnosis; however PLEF could be serosanguinous (watery and pinkish-red due to blood mixed with serum), haemorrhagic (haemocrate value >50%), turbid to frank pus (empyema), and or milky (Chylous) etc that may also contribute to underlying etiology. Apart from the clinical, biochemical, microscopy and bacteriologic examination of PLEF, a chest x-ray (PA/ Lateral and decubitus position) prior and after the aspiration is desirable, however USG and or CT thorax may require to further precisely delineate the site and size of underlying ailment and enable to optimized interventions. The histopathology and or immuno-histochemistry is the ultimate to establish diagnosis and that required to procure pathological biopsy tissue samples from pleura, lung, or lymph nodes (intra or extra thoracic) and from the primary sites which may be variable in each case. The optimal use of available modalities and procedures are the key to success e.g. FNAC, Abrams or Tru-cut needle closed pleural biopsy (CPB), thorascopic or bronchoscopic biopsies are some of the examples. The present study is carried out at a rural based Medical college to understand the diagnostic yield with optimal use of various tools.

Results:

A total of 103 admitted cases of pleural effusion were considered for a prospective observational study in the department of respiratory medicine. The mean age of participant was 46 yrs and among them more than 57 % cases were above the age 40 years with nearly three times male predominance ie 77 males and 26 females. Pleurocentesis was carried out in all the cases after taking complete history and clinical examination, followed by chest x-ray/ USG thorax, and were investigated for biochemical, pathological, microbiological etc to establish the diagnosis and management. However 4 cases showed dry tap and later on diagnosed as tuberculosis. The diabetes, COPD, HIV and hypertension as a systemic diseases were detected as comorbidities in 8%, 8%, 5% and 4% patients respectively. Similarly less common



diseases known to cause PLEF were also detected as CKD (4%), CCF (2%), and 1% each with urinothorax, CAD and CLD. However the case of urinothorax was due to per cutaneous nephro-lithotomy and was also managed successfully which resolved spontaneously after an aspiration. Pleuroscopy was done with the video assisted semi rigid thoracoscope in 13% cases and fibreoptic bronchoscopy was performed in 12% cases and their results displayed on bar **Chart: 1&2**. A close needle biopsy (CNB) yielded 100% with Abrams in 2 cases with having ample of pleural fluid and finally diagnosed as of TB origin. A fine needle aspiration cytology (FNAC) in 8% cases with cervical lymphadenopathy had revealed TB in 2 and Malignancy in 6 cases.

Some of the therapeutic procedures were also performed i.e. insertion of intercostal tube drainage (ICD) with under water seal (in 32% cases), pleurodesis (in 25%), pleuroscopy with adhesion/ septations removal during pleuroscopy (in 13%), fibrinolysis (in 2% cases), and 9% chronic recalcitrant cases referred to thoracic surgical unit for decortications **Chart: 3**.

Discussion:

The parietal pleura is richly supplied with sensory nerve and the inflamed or diseased pleura become painful due to friction with visceral part, however the pain may later disappear with the collection of reactionary fluid or again reappear after pleurocentesis due to direct contact of both pleura and inflammation in the pleural space. The dyspnea is the most common presentation with a filling of more than a half of the hemithorax with fluid. The clinical examination and chest x-ray (CXR) are the simplest way to detect PLEF in the free form (meniscus), loculated (D

sign) or subpulmonic and even a small amount of free fluid can be diagnosed with chest radiograph taken in decubitus position. However in a tedious situation the radiation free USG guided pleurocentesis remained the best choice.

In the present study the drained PLEF samples (99 cases) were examined for biochemical, bacteriologic and cell cytology and was classified as exudative (92%) and transudative (8%) according to the Light's criteria. The exudative PLEF was in majority and among them 49%, 19% and 17% cases were of TB, malignancy and synpneumonic effusion respectively. In the Indian context upfront molecular testing with or without ADA (value >40 unit) test may have higher yield in diagnosing tuberculosis along with rifampin resistance, nevertheless the bacillary population is sparse/ paucibacilli in PLEF. In the absence of mycobacterium the sensitive individuals may develop TPE that could be due to delayed type hypersensitivity⁽³⁾. The present study observed 20% (10/50 cases) as bacteriologically positive by CBNAAT and among them 2/50 (4%) rifampin resistant cases were also detected that remained creditable. Similarity Damanjit Duggal et al had reported that in majority of their patients 77 (86%) MTB could not be detected by the GENEXPERT test and concluded insufficient tool for TPE⁽³⁾. Rahul Gupta et al mentioned that TPE is second most common extrapulmonary TB while the positivity of CBNAAT was higher in lymph node TB (TBLN) patients (57.8%) as compared to TPE (23.7%) patients⁽⁴⁾. A microbiol culture and sensitivity test was performed for turbid or frank pus (empyema) to initiate appropriate chemotherapy. The synpneumonic PLEF (pneumonia or infected lung with PLEF) as usually responded, very well with the same antibiotic treatment, thus intervention is usually not required as happened with our 17 (17%) cases, however 3 cases of pyothorax were managed with intercostal tube drainage.

A predominant lymphocytes and the value of ADA (>40 IU) with the ratio of LDH/ADR may help to distinguish TB from synpneumonic and malignancy effusion e.g. a lower ratio around <10 favor tubercular etiology against >14 or >45 suggests parapneumonic and malignant origin respectively⁽⁵⁾. The intercostal tube drainage (ICD) with an under water seal should invariably be placed to manage pleural fluid whenever the pH is <7.2 or found to be turbid/ frank pus (empyema) without considering the underlying etiology. In the present small series of 103 cases the ICD was placed in 33 (32%) cases after the therapeutic or post diagnostic procedures.

In the present study 8 cases were clinically detected with additional finding of cervical lymphadenopathy, and among them a simple FNAC revealed TB (in 2 cases) and malignancy (in 6 cases), had contributed to the ultimate diagnosis. A pleural fluid cell block should invariably be examined for exfoliative cytology but none of the cases in our study reported any abnormality i.e. malignant or fungal hyphae etc in the sputum or pleural fluid. In 4 (4%) cases the PLEF sample could not be collected due to minimal amount nevertheless the clinical, radiologic and pathological findings had supported in making a diagnosis of TB in these cases. The co morbidities may also play a pivotal role in management e.g. eight cases of our study group had transudative effusion due to cardiac and renal disease which resolved with diuretic, dialysis, and supportive management etc, and did not require further evaluation. Similarly among them a case of urinothorax followed by PCNL (percutaneous nephrolithotomy) also resolved spontaneously.

Apart from the examination of PLEF for bio/ cyto/ microbes, the acquisition/ procurement of tissue for histological analysis becomes mandatory especially for undiagnosed cases. There are two known options for tissue biopsy: 1) a blind/ or closed pleural biopsy (CPB) with Abrams or Tru-cut needle and 2) a 'gold standard' surgical biopsy. The biopsy could also be performed under image (USG or CT) guided is much safer procedure especially for pleural or peripheral lung lesions. Yuqing Wei et al in their meta-analysis study of exudative effusion had mentioned that the closed pleural biopsy (CPB) yielded comparable to medical thoracoscopy (MT) 69% and 68% respectively in non malignant cases, so they concluded that the CPB may be considered as first choice⁽⁶⁾. However they further mentioned that CPB could not properly visualise the diaphragmatic, apical and mediastinal pleura and they also stated that the diagnostic yield in malignant PLEF remained higher with MT (92%) vs. CPB (72%). The most common complication associated with CPB includes pneumothorax, pain, haemothorax, hematoma, vasovagal reaction and transient fever etc reported to be 8- 18%⁽⁷⁾. Boy DP et.al. has stated that USG guided pleural interventions are safe, cost effective, least invasive, radiation free and can be performed bedside with a comparable yield, wherever the facilities of computed tomography and medical thoracoscopy facilities are not available⁽⁸⁾. He further mentioned and added a recommendation that the US-guided procedures should be encouraged and adopted as an integral part of the respiratory physician curriculum^(8,9).

Giles Dixon et al had mentioned that since last more than a decade an image-guided Tru-cut biopsies and medical thoracoscopy (pleuroscopy) under local anesthesia have become more acceptable and popular tool⁽¹⁰⁾. We too preferred and adopted a minimal invasive video-assisted semi-rigid thoracoscope in 13% cases with diagnostic

dilemma to visualize the pleural space and surrounding structure and enable biopsy under direct vision. Similarly the fiberoptic bronchoscopy was performed in 12 cases with suspected lung malignancy and biopsy, bronchial brushing and BAL fluid were collected and TBNA was also carried out in 2 cases with enlarged sub carinal lymph nodes detected on CECT thorax. Along with FOB a protected sample biopsy (PCB) were also performed in 3 cases of delayed resolving synpneumonic effusion for culture and sensitivity test however, ICD was also placed in them. The MT may also ease therapeutic procedures like Fibrinolytic (2% cases), removing fluid and adhesions in loculated/ complex effusions (found in 12% cases) to allow lung expansion and also help in deciding a candidate for decortication with pleural peel or trapped lung. 9% cases referred to thoracic surgeon for decortication. The present study also performed pleurodesis in 24% (24cases) with doxycycline after full expansion of the lung nevertheless with a failure rate of 16% (4/24). Our study reported 4% undiagnosed cases as against Wei et al. mentioned 15-20 % PLEF cases may remain undiagnosed ⁽⁶⁾. In India the medical thorascopies are performed more frequently than ever before yet most the general practionars are still managing PLEF empirically which leads to mised or delayed diagnosis and untoward complications due to improper treatment ⁽¹¹⁾.

The prognosis of PLEF depends upon the underlying etiology with complete cure to disastrous end of life, as in malignant pleural effusion (MPE) which has the worst (TNM-stage 4) prognosis and it also depends on the amount i.e. massive effusion irrespective of histological type of lung cancer, which may require prolonged indwelling ICD and palliative management ⁽¹¹⁻¹⁴⁾.

Conclusion:

The pleural effusion is most common ailment with underlying local and generalized or systemic causes. The PLEF may presents with a certain variable clinical and radiological features that themselves will incline us to choose/ opt a particular procedure. Thus a definite algorithm cannot be implanted while the minimal invasive with least complication and maximum yielded procedures should be planned for each individual case. Patient comfort, consent are all component of a patient's centric care to ensure full cooperation in removing fluid and preventing its reaccumulation. The CPB may be more suitable in exudative and lymphocytic predominant with diffuse pleural involvement cases when USG/ CT facilities are unavailable or when patient cannot tolerate medical thoracoscopy. The misdiagnosed cases of PLEF should be followed up regularly and should be again considered for a complete repeat examination after an interval.

References:

1. Deschuyteneer EP, De Keukeleire T. Diagnostic value and safety of thorascopic pleural biopsies in pleural exudative effusions of unknown origin, including follow-up. *BMJ Open Res* 2022;**9**:e001161. doi:10.1136/ bmjresp-2021-001161
2. Christopher DJ, Gupta R, Thangakunam B, Daniel J, Jindal SK, Kant S, *et al.* Pleural effusion guidelines from ICS and NCCP Section 1: Basic principles, laboratory tests and pleural procedures. *Lung India* 2024;**41**:230-48.
3. Damanjit Duggal, Karan Deshmukh, Gopinath Shengole, Pleural Fluid Genexpert/CBNAAT In The Diagnosis Of Tubercular Pleural Effusion; *Int J Acad Med Pharm* 2023; **5** (3); 1575-1579
4. Rahul Gupta et al. Role of CBNAAT in the diagnosis of extrapulmonary tuberculosis: a prospective cross-sectional study; *The Egyptian Journal of Bronchology* (2025) 19:10 <https://doi.org/10.1186/s43168-025-00369-3>
5. Ho CY, Tsai YH, Chang CC, Huang HL, Tan NC, Chen WC, *et al.* The role of pleural fluid lactate dehydrogenase-to-adenosine deaminase ratio in differentiating the etiology of pleural effusions. *Chin J Physiol* 2022;**65**:105-8.
6. Wei Y, Shen K, Lv T, Liu H, Wang Z, Wu J, Zhang H, Colella S, Wu FZ, Milano MT, Zhan P, Song Y, Lu Z; written. Comparison between closed pleural biopsy and medical thoracoscopy for the diagnosis of undiagnosed exudative pleural effusions: a systematic review and meta-analysis. *Transl Lung Cancer Res*. 2020 Jun;**9**(3):446-458. doi: 10.21037/tlcr.2020.03.28. PMID: 32676309; PMCID: PMC7354159.
7. Gouda A M et al. A comparison between Cope and Abrams needle in the diagnosis of pleural effusion; *Annals of Thoracic Medicine* -Vol 1, Issue 1, June 2006 <https://impactfactor.org/PDF/IJPCR/16/IJPCR,Vol16,Issue1,Article177.pdf>
8. Boy DP, Shaw JA, Koegelenberg CFN. Ultrasound-guided pleural biopsy. *Eurasian J Pulmonol* 2023;**25**:1-11.
9. Federico Mei et al. Diagnostic Yield and Safety of Image- Guided Pleural Biopsy: A Systematic Review and Meta-Analysis; *Respiration* 2021;**100**:77-87 <https://sci-hub.se/downloads/2021-08-16/89/mei2020.pdf>

10. sChristopher DJ, Gupta R, Thangakunam B, Daniel J, Jindal SK, Kant S, *et al.* Pleural effusion guidelines from ICS and NCCP Section 1: Basic principles, laboratory tests and pleural procedures. *Lung India* 2024;41:230-48.
11. Yang Y, Du J, Wang YS, Kang HY, Zhai K, Shi HZ. Prognostic impact of pleural effusion in patients with malignancy: A systematic review and meta-analysis. *Clin Transl Sci.* 2022 Jun;15(6):1340-1354. doi: 10.1111/cts.13260. Epub 2022 Mar 21. PMID: 35212454; PMCID: PMC9199884.
12. Roberts ME, Rahman NM, Maskell NA, et al. *Thorax* 2023;78:1143–1156.
<https://thorax.bmj.com/content/thoraxjnl/78/11/1143.full.pdf>
13. David J. Feller-Kopman et al, Management of Malignant Pleural Effusions An Official ATS/STS/STR Clinical Practice Guideline, *Am J Respir Crit Care Med* Vol 198, Iss 7, pp 839–849, Oct 1, 2018
<https://www.atsjournals.org/doi/epdf/10.1164/rccm.201807-1415ST?role=tab>