



ISSN NO. 2320-5407

Journal homepage: <http://www.journalijar.com>

**INTERNATIONAL JOURNAL
OF ADVANCED RESEARCH**

RESEARCH ARTICLE

A clinical study of pediatric patients with intussusception

Omar Bin Hasan¹, Tahera Arif¹, Azadh Chandrashekar uppari²

Assistant professor, Department of General Surgery, Deccan college of medical sciences, Hyderabad. ²Senior resident in General surgery, Osmania General Hospital.

Manuscript Info

Manuscript History:

Received: 12 October 2015

Final Accepted: 25 November 2015

Published Online: December 2015

Key words:

Intussusception, Mesenteric lymph nodes, Lead point, Ileo-colic.

*Corresponding Author

Omar Bin Hasan

Abstract

BACKGROUND

Intussusception is one of the classic subjects of paediatric surgery. It is defined as telescoping of one segment of bowel into other. It is one of the most common paediatric emergencies, and an important cause of small bowel obstruction in children: if left untreated leads to fatal complications.

AIM

To study the clinical profile of paediatric patients with intussusception in a tertiary care hospital.

PATIENTS AND METHODS

A prospective case series study of 50 children admitted to a tertiary care Hospital, Hyderabad with a diagnosis of acute intussusception between May 2012 to April 2014 were included in the study. All children clinically suspected of having intussusception were evaluated by real time ultrasonography and those with positive findings were entered into the study.

RESULTS

Male preponderance was observed in our study with predominant symptoms being excessive crying/Abdominal pain 100% (50 cases), followed by vomiting and mass per abdomen 80% (40). Most of the cases were idiopathic type and 22% (11) cases were secondary to lead points most common lead points being mesenteric lymph nodes 54.5% (6) cases followed by Meckel's diverticulum and gut associated lymphoma seen in 18.1% (2) cases. The most common type of intussusception was found to be ileo-colic with 62% (32) cases being reported.

Copy Right, IJAR, 2015,. All rights reserved

INTRODUCTION

Intussusception is defined as the telescoping of one segment of bowel (Intussusceptum) into another (Intussusciens), usually proximal segment into the distal segment of bowel [1]. As the mesentery of the proximal bowel is drawn into the distal bowel, it is compressed, which results in venous obstruction and edema of bowel wall. If reduction of the intussusception does not occur, arterial insufficiency and bowel wall necrosis follows progressing to strangulation, transmural gangrene, perforation and peritonitis, which in turn will lead to morbidity and death of patient. Diagnosis and treatment of intussusception is a combined effort among the paediatrician, the pediatric radiologist and pediatric surgeon. In the past due to lack of diagnostic modalities, the morbidity and mortality of intussusception was very high [2]. Hence to determine the clinical profile of patients with

intussusception and to delineate the role of ultrasonography in early diagnosis of this condition the present study was initiated.

PATIENTS AND METHODS

This is a prospective case series study where in 50 children who were admitted in Owasis Hospital and Research centre, Hyderabad with a diagnosis of acute intussusception from May'2012 to April 2014 were included in the study.

Inclusion criteria

1. Ultrasonographically diagnosed case of intussusception.
2. Age below 12 years.

Exclusion criteria

1. Child presenting with signs of peritonitis.
2. Child with X-ray findings of bowel perforation.
3. Child presenting with features of shock.

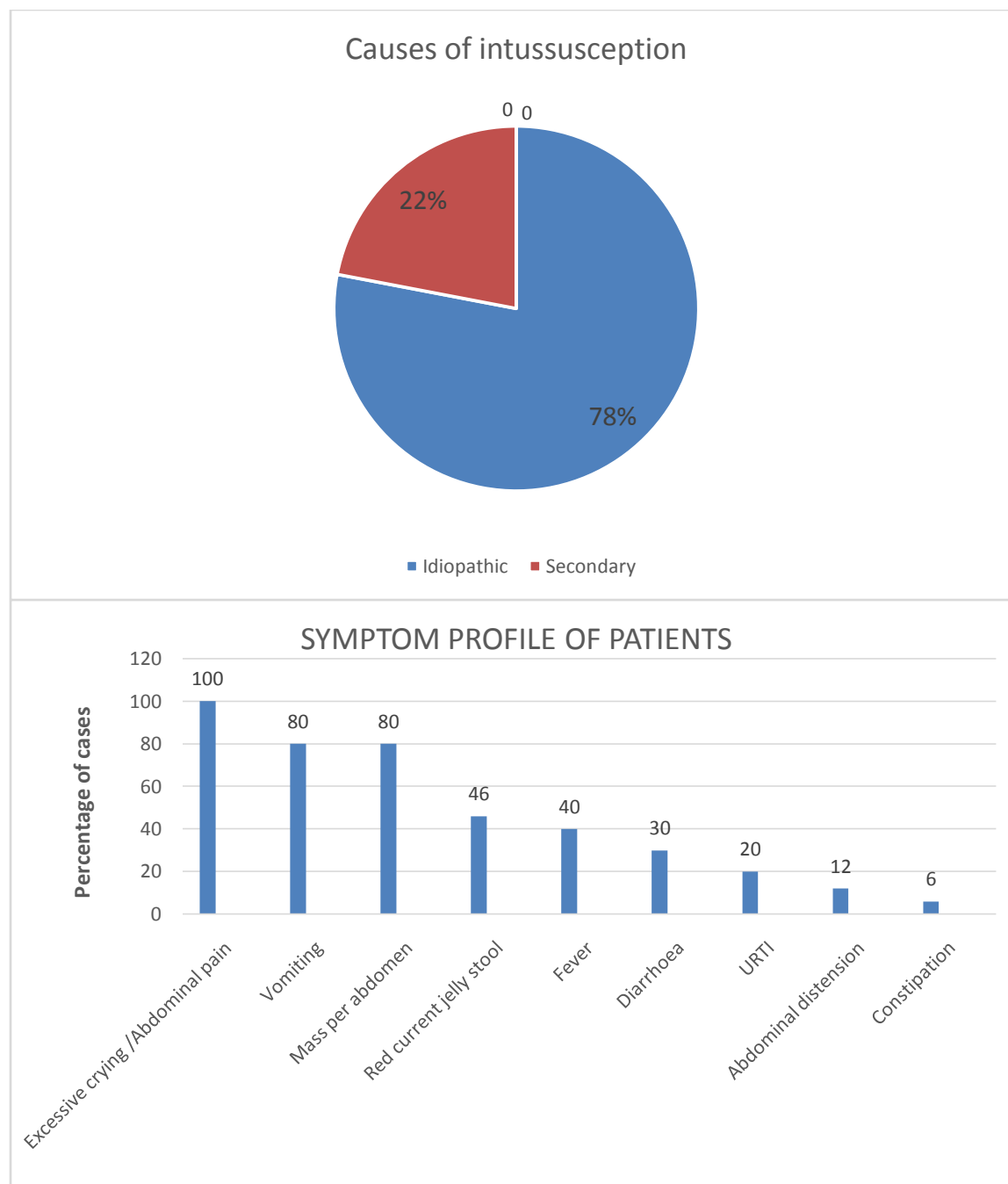
Ultrasound criteria

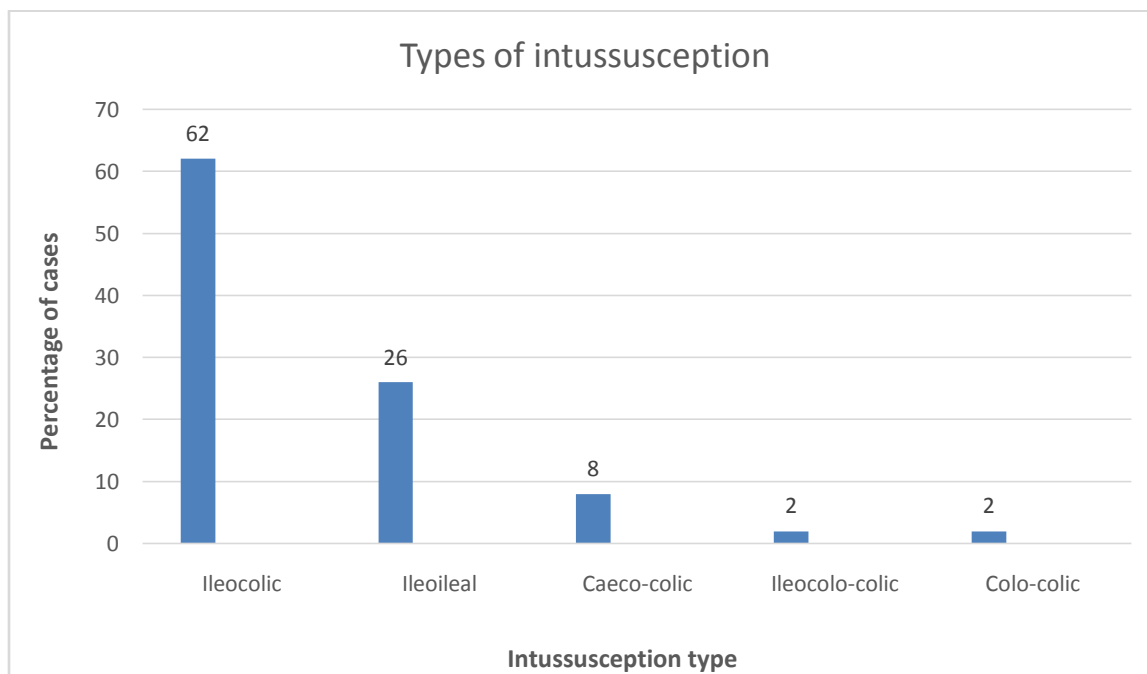
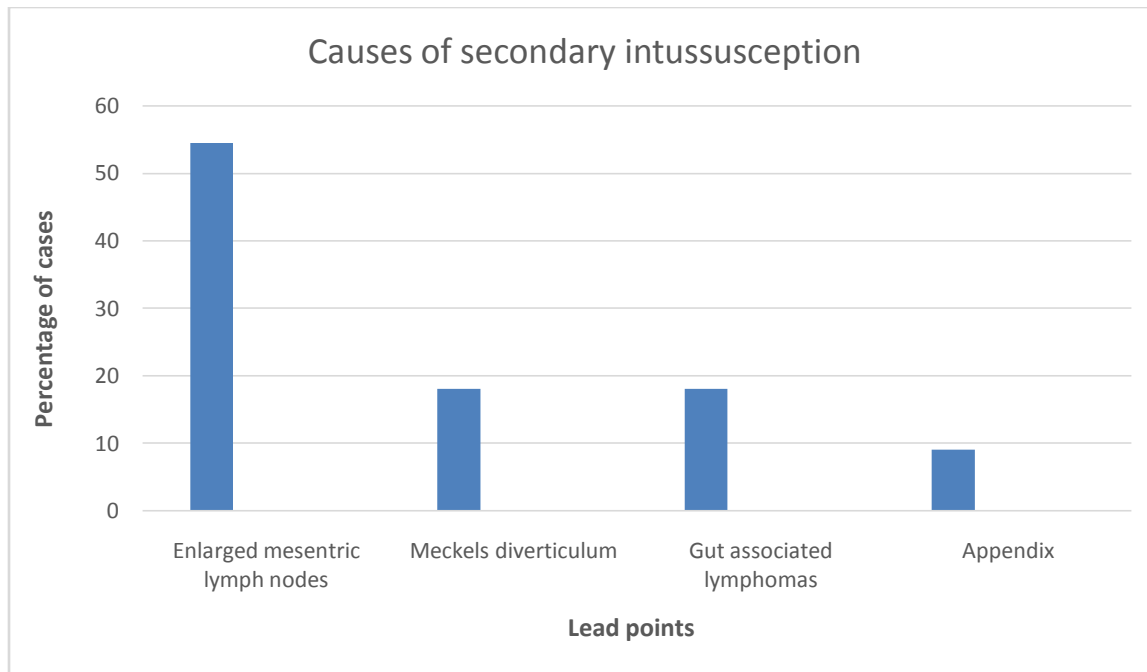
1. Visualization of intussusceptum, seen as a doughnut shaped or target shaped configuration on transverse images with hypo-echoic edematous bowel surrounding a central area of increased echogenicity.
2. Pseudo-kidney appearance on longitudinal image.
3. The single concentric ring representing the swollen terminal ileum instead of the multiple concentric rings (TARGET SIGN) of intussusception.
4. The abrupt transition of bowel wall thickness between the swollen terminal ileum and the proximal normal ileum when scanned along the long axis of the ileum.
5. Additional ultrasonographic criteria were a double or multiple or concentric ring sign and an atypical target sign with fluid filled centre.

After thorough history taking and physical examination including per rectal examination, all children clinically suspected of having acute intussusception were evaluated by real time ultrasonography and those with positive findings on sonography confirming intussusception were entered into the study.

RESULTS

Out of 50 patients 36(72%) were males and 14(28%) were females. Thus a high male preponderance was observed in the study. High proportion of cases 34(68%) were seen in age group of 0-1 year. Two peaks of seasonal variation were observed in our study with 22(44%) of cases occurring in winter and 17(14%) cases in summer. The predominant symptom in most of the cases were excessive crying/abdominal pain(100%), followed by vomiting and mass per abdomen(80%), Red current jelly stools (46%) and fever seen in 40% of the patients. Majority of cases were idiopathic 78%(39) and 22%(11) were secondary to lead points. Among the causes of secondary intussusception most common lead points were Mesenteric lymph nodes followed by Meckel's diverticulum and gut associated lymphoma seen in 2(18.1%) cases. Appendix as a lead point was seen in 1 case (9.09%). The most common type of intussusception was found to be ileo-colic with 31(62%) reported cases, followed by ileo-ileal type with 13(26%) cases.





DISCUSSION

A higher male preponderance along with most common age group being 0-1 year was observed in our study which is consistent with most of the studies including Stringer MD et al[3,4]. The characteristic two peaks of seasonal variation were observed in our study with 22(44%) of cases occurring in winter and 17(14%) cases in summer, in accordance to a study by Ravitch M.M., where two peaks of incidence of intussusception one in spring and summer, possibly the season of gastroenteritis and another in the mid-winter, during the time of maximal incidence of respiratory illnesses [6]. Probably these two peaks are associated with viremia, which leads to generalized lymphoid proliferation causing hypertrophy of Peyer's patches which in turn leads to hyperperistalsis causing intussusception.

The ileo-caecal variety being commonest and associated with mesenteric lymphadenopathy substantiates this theory.[4,6]. In India an increased incidence of intussusception was reported in summer months. Another study reported an increase in intussusception admissions in April and May associated with the peak incidence of gastroenteritis [5,7].

CONCLUSION

Intussusception is one of the most common paediatric emergencies. Our study showed a higher male preponderance, with highest number of cases seen in the age group of 0-1 years. Two peaks of seasonal variation were observed in our study one in winter and other in summer. Most of the clinical symptoms were overlapping the predominant symptoms being excessive crying/Abdominal pain, Vomiting and mass per abdomen. Majority of cases were idiopathic and are of ileo-colic type. Secondary intussusception occurs due to lead points. Most common lead points in our study are mesenteric lymph nodes, Meckels diverticulum, gut associated lymphomas and appendix.

REFERENCES

1. Welch K.J., Randolph J.S, Ravitch M.M,et al, Paediatric surgery: Intussusception, 4th Ed. Vol.2, Chap.88, 868-881pp.
2. Swenson's pediatric surgery. 5th Ed., Chapter 27, 221-229 pp.
3. Stringer MD, Pablot SM, Brereton RJ: Paediatric intussusception. British Journal of Surg. 79:867-876, 1992.
4. Hamby L.S., Fowler C.L., Pokorny W.J.: Intussusception. In: Donnellan W.L., ed. Abdominal surgery of Infancy and childhood, Australia: Harwood; 1996: 1
5. WHO/V&B/02.19 (www.WHO.int/vaccines.documents/)
6. Ravitch M.M, MuCune R.M. Jr: Intussusception in infants and children. J Pediatr 37:153, 1950.
7. Davis C.F, McCabe A.J., and Raine P.A.M., The ins and outs of intussusceptions : history and management over the past fifty years. J. pediatr Surg: May 2003.