



### RESEARCH ARTICLE

## SIGNIFICANCE OF TIMELY MANAGEMENT OF LARYNGOTRACHEAL STENOSIS: A CASE REPORT

Satish Chandra Tripuraneni, Anusha Akkineni, Sameera Gera, Poola Lavanya and Arni Swetha

### Manuscript Info

#### Manuscript History

Received: 04 April 2025

Final Accepted: 07 May 2025

Published: June 2025

#### Key words:-

Laryngotracheal Stenosis, T Tube, Rib Cartilage Graft, Airway Reconstruction

### Abstract

Laryngotracheal stenosis is a rare but serious life-threatening condition. With the recent advances in critical and terminal care the incidence of acquired laryngotracheal stenosis is on the rise. Previously, Trauma used to be the most common cause of laryngotracheal stenosis but now iatrogenic is almost competing with that. Early diagnosis of laryngotracheal stenosis and proper decision making regarding the management is vital in treating the patients with laryngotracheal stenosis. The site of the lesion, type and extent of the stenosis influence the decision regarding the treatment options. In this article, we want to highlight the importance of decision making in treatment of laryngotracheal stenosis. A diagnosed case of subglottic stenosis previously treated with a T Tube, presenting with persistent disease was managed by laryngotracheal reconstruction with laryngo-fissure and stenting leading to successful clinical outcome.

"© 2025 by the Author(s). Published by IJAR under CC BY 4.0. Unrestricted use allowed with credit to the author."

### Introduction:-

Laryngotracheal stenosis can be congenital or acquired<sup>(7)</sup>. Acquired laryngotracheal stenosis may be due to various reasons like endotracheal intubation, high tracheostomy, polytrauma or idiopathic. But, due to advancement of the critical care in terminally ill patients, incidence of iatrogenic stenosis is increasing. The factors that contribute to the development of stenosis in terminally ill patients are prolonged intubation, improper cuff pressure monitoring, poor tracheostomy care and patient factors.

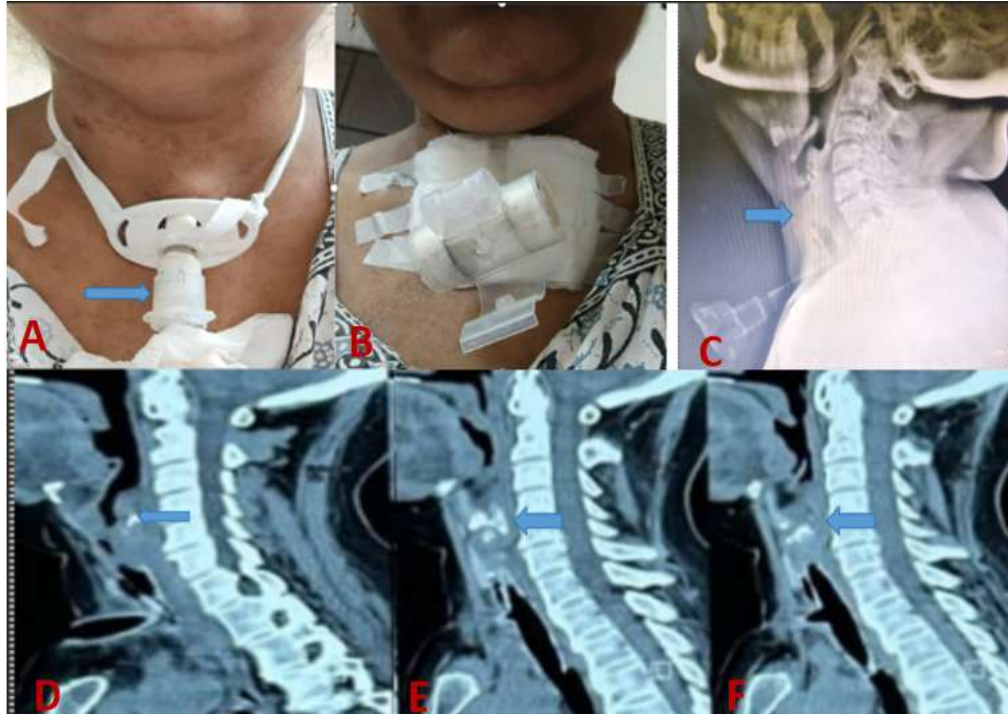
The treatment should be planned individually for every patient depending on the location of the lesion, type of stenosis, whether the stenosis is involving only the sub glottis or extending to trachea or glottis and the timing of patient's presentation with symptoms to the clinic. In isolated tracheal stenosis either endoscopic dilatation, T-Tube insertion or resection and anastomosis can be opted. But, in patients with subglottic stenosis due to circumferential lesion involving the cricoid cartilage, reconstruction procedures are better suited<sup>(6)</sup>. Hence, timely diagnosis with individualized treatment plan plays a crucial role to prevent recurrence.

### Case Report:

A 53-year-old female patient presented to the department of otorhinolaryngology, head and neck in our institute for treatment of persistent subglottic stenosis who underwent multiple tracheal dilatations with T-tube insertion at an outside hospital.

Patient developed breathlessness 4 months ago following an episode of intubation and mechanical ventilation 2 month prior. Patient had an episode of pneumonia with septicemia and multi-organ dysfunction for which she was on mechanical ventilator for 3 days and was extubated on 4<sup>th</sup> day.

She developed sudden onset of breathlessness after 2 months and was diagnosed as sub-glottic stenosis. Patient underwent tracheostomy with T-tube insertion. But even after the procedure and multiple attempts of tracheal dilatation, patient symptoms were not relieved and hence she was referred to higher center. So, she came to our hospital for second opinion with T-tube in situ. She was breathing through the humidifier when she presented to us (fig 1-a). On examination patient had biphasic stridor. Video laryngoscopy showed edema of glottic region with narrowed subglottic region. Bilateral vocal cords were moving.



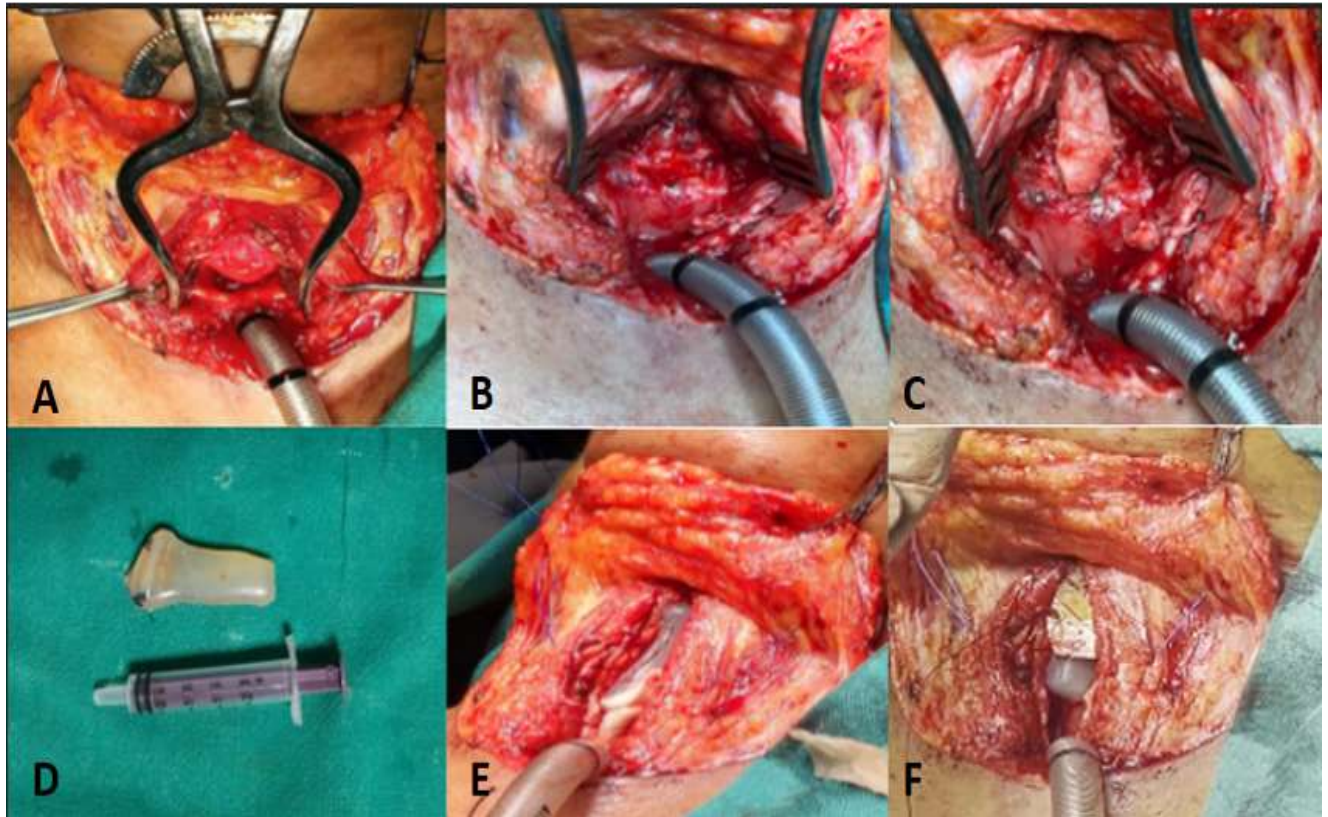
Pre-operative X-ray neck lateral view revealed T-tube in-situ with soft tissue density noted above the level of the T-tube, indicating complete obstruction of the lumen. (fig.1-b)

CT scan of neck revealed T-tube in-situ with grade-3 subglottic stenosis according to Mc Caffrey classification with the stenotic segment extending from the sub-glottic region to upper trachea but not involving the glottis with necrosis of the cricoid cartilage (fig 1-c).

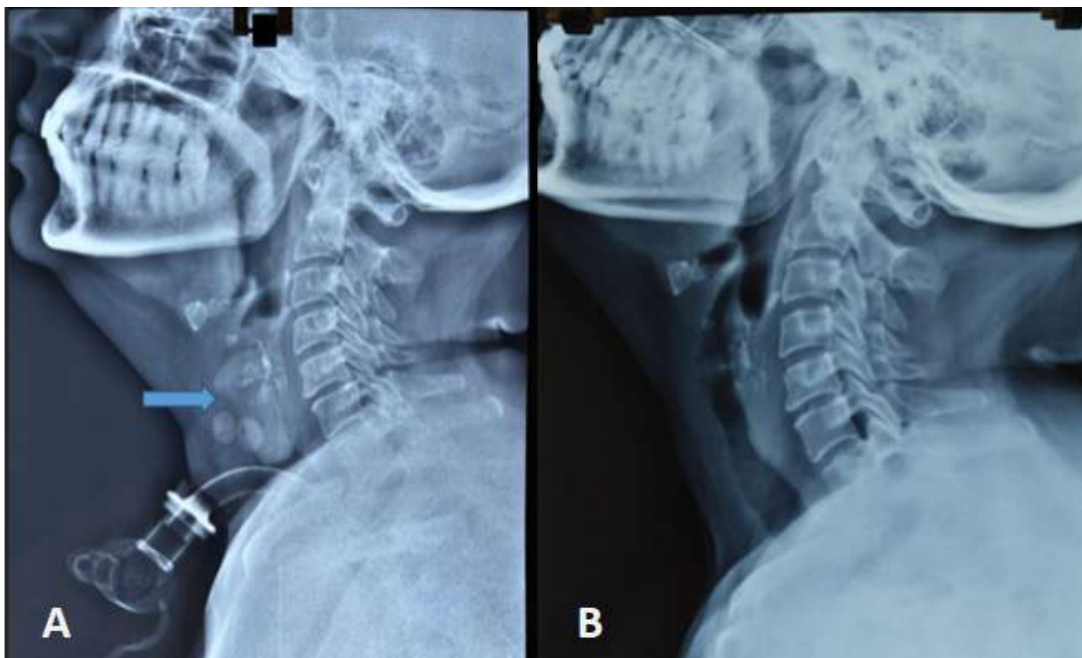
We planned for laryngotracheal reconstruction with rib cartilage grafting. A horizontal incision was given as extension on either side of the previous tracheostomy stoma site and sub-platysmal flaps are elevated exposing the cricoid cartilage, thyroid cartilage and trachea. Granulation tissue (fig.2-a) around the tracheostomy stoma site was excised. An anterior midline laryngo-fissure was performed and granulations in the tracheal lumen was excised and removed along with the fibrotic tissue. Necrosed bits of the cricoid cartilage were also removed (fig.2-b). Posterior cricoid split was done and rib cartilage (fig.2-c) was placed over it to augment and provide adequate support. Montgomery solid Laryngeal stent (fig.2-d,e) was placed over the rib cartilage. Another piece of rib cartilage (fig.2-f) was placed over the laryngeal stent and larynx approximated.

7.5mm portex cuffed tracheostomy tube was placed and incision closed.

Patient was followed up on regular basis and laryngeal stent (fig.3-a) was removed after 6 weeks. Tracheostomy tube was removed. Check X-ray after stent removal showed normal tracheal lumen. (fig.3-b)



**Fig. 2:-** a- intra-operative image showing granulation tissue in the sub-glottic region after laryngofissure approach.  
 b- image after removal of the granulation tissue and necrotic cricoid cartilage.  
 c – image showing rib cartilage placed over the cricoid region  
 d,e- image showing the laryngeal stent which is placed over the rib cartilage  
 f- image showing another piece of rib cartilage placed anteriorly over the laryngeal stent.



**Fig. 3-a:-** Post-operative x-ray neck lateral view showing the laryngeal stent insitu  
**Fig.3-b:-** x-ray neck lateral view after stent removal, showing normal tracheal lumen.



**Discussion:-**

Laryngotracheal stenosis is a complex entity with various treatment options<sup>(1)</sup>. The decision regarding the management of laryngotracheal stenosis depends on various factors including site of lesion, whether involving a part of trachea or larynx or a lesion involving both, type of lesion like either mucosal granulation, circumferential fibrosis, granulations secondary to the underlying cartilage infection<sup>(3)</sup>. Another factor that decides the treatment is length of the involved segment.

Isolated thin membranous stenosis secondary to circumferential scarring or stenosis due to granulations are amenable to endoscopic dilatation and stenting. Hard or fibrotic stenosis with long segments and cartilage involvement need open approaches. The necrotic cartilage may act as infective foci for granulations. So treating these cases without removing the infected focus may lead to obvious recurrences.

In our case, investigations showed chondronecrosis of the cricoid cartilage with underlying infective foci and stenotic segment involving the trachea. Multiple attempts of endoscopic dilatations with T-tube insertion was done elsewhere without removal of the underlying pathology thereby causing persistence. We proceeded with laryngofissure approach resecting the necrosed cartilage, granulation tissue and augmented with autologous rib graft<sup>(4)</sup>. Laryngeal reconstruction was done to widen and maintain the airway patency. The decision regarding the management should be focused in clearing the underlying pathology based on the site, type and extent of the lesion.

Iatrogenic laryngotracheal stenosis itself is a complication due to manipulation at laryngotracheal region for airway management. The management of the cases should aim at relieving the stenosis but not worsen the patient condition. The main aim in treating should be resect the necrotic cartilage, disease pathology with reconstruction and widening of the laryngeal lumen.

**Declarations****Funding:**

There was no source of funding for the study.

**Conflict of interest:**

The authors declare no conflict of interest.

**Compliance with Ethical standards:**

The Ethics Committee at our institute has confirmed that no ethical approval is required.

**Financial interest:**

Authors certify that they have no affiliations with or involvement in any organization or entity with any financial interest or non-financial interest in the subject matter or materials discussed in this manuscript.

**References:-**

1. Puri HV, Bansal M, Asaf BB, Pulle MV, Bishnoi S, Kumar A. Cricoid Augmentation by Costal Cartilage Graft in the Treatment of Complex Crico-Tracheal Stenosis in Adults. *Indian J Otolaryngol Head Neck Surg.* 2023 Mar;75(1):200-207. doi: 10.1007/s12070-022-03437-y. Epub 2023 Jan 17. PMID: 37007901; PMCID: PMC10050644.
2. Pandya A, Sreevidya SR, Chaudhari N, Prajapati BJ, Gupta N. Laryngotracheal Stenosis: Our Experience in a Tertiary Care Hospital. *Indian J Otolaryngol Head Neck Surg.* 2023 Mar;75(1):39-44. doi: 10.1007/s12070-022-03445-y. Epub 2022 Dec 31. PMID: 37007876; PMCID: PMC10050668.
3. Monnier P, Dikkers FG, Eckel H, Sittel C, Piazza C, Campos G, Remacle M, Peretti G. Preoperative assessment and classification of benign laryngotracheal stenosis: a consensus paper of the European Laryngological Society. *Eur Arch Otorhinolaryngol.* 2015 Oct;272(10):2885-96. doi: 10.1007/s00405-015-3635-4. Epub 2015 May 8. PMID: 25951790.
4. Terra RM, Minamoto H, Carneiro F, Pego-Fernandes PM, Jatene FB. Laryngeal split and rib cartilage interpositional grafting: treatment option for glottic/subglottic stenosis in adults. *J Thorac Cardiovasc Surg.* 2009 Apr;137(4):818-23. doi: 10.1016/j.jtcvs.2008.08.035. Epub 2009 Jan 18. PMID: 19327502.
5. Lorenz RR. Adult laryngotracheal stenosis: etiology and surgical management. *Curr Opin Otolaryngol Head Neck Surg.* 2003 Dec;11(6):467-72. doi: 10.1097/00020840-200312000-00011. PMID: 14631181.

6. Zhi L, Wenli W, Pengfei G, Pengcheng C, Wenxian C, Jiasheng L, Yongzhu S. Laryngotracheal reconstruction with autogenous rib cartilage graft for complex laryngotracheal stenosis and/or anterior neck defect. *Eur Arch Otorhinolaryngol.* 2014 Feb;271(2):317-22. doi: 10.1007/s00405-012-2256-4. Epub 2013 Jul 2. PMID: 23818115.
7. Saravanam PK, Manimaran V. Role of Primary Aetiology of Intubation in Acquired Laryngotracheal Stenosis: An Institutional Audit and Review of Literature. *Indian J Otolaryngol Head Neck Surg.* 2022 Oct;74(Suppl 2):2241-2246. doi: 10.1007/s12070-020-02102-6. Epub 2020 Sep 2. PMID: 36452704; PMCID: PMC9702272.