



Journal Homepage: [-www.journalijar.com](http://www.journalijar.com)

INTERNATIONAL JOURNAL OF ADVANCED RESEARCH (IJAR)

DOI:10.21474/IJAR01/21106

DOI URL: <http://dx.doi.org/10.21474/IJAR01/21106>



RESEARCH ARTICLE

EVALUATION OF SOFT TISSUE AND SKELETAL CHANGES FOLLOWING BILATERAL SAGITTAL SPLIT SETBACK SURGERY A RETROSPECTIVE STUDY

Josepaul C.I¹, Varghese Mani², Sankar Vinod³, Arun George⁴, Atic Thomas⁵ and Bright E.C⁶

1. Senior Lecturer, Department of Oral and Maxillofacial Surgery, Royal Dental College, Palakkad.
2. Professor Emeritus. Department of Oral and Maxillofacial Surgery. Mar Baselios Dental College, Kothamangalam, Kochi, Consultant Oral and Maxillofacial Surgeon, Trichur Institute of Head and Neck Surgery (TIHANS), Saroja Multispecialty Hospital Thrissur.
3. Professor and Head of Department, Department of Oral and Maxillofacial Surgery. Mar Baselios Dental College, Kothamangalam.
4. Professor, Department of Oral and Maxillofacial Surgery. Mar Baselios Dental College, Kothamangalam.
5. Reader, Department of Oral and Maxillofacial Surgery. KMCT Dental College, Kozhikode.
6. Reader, Department of Oral and Maxillofacial Surgery St. Gregorius Dental College, Kochi.

Manuscript Info

Manuscript History

Received: 04 April 2025

Final Accepted: 07 May 2025

Published: June 2025

Abstract

Purpose: To evaluate the stability of Bilateral Sagittal Split Osteotomy setback surgery with rigid internal fixation for participants with skeletal class III malocclusion.

Patients and Methods: The sample comprised of 30 participants who underwent BSSO setback surgery for correction of mandibular prognathism at Department of Oral and Maxillofacial Surgery, Mar Baselios Dental College. Lateral cephalograms at three different time intervals - Pre operative (T0), Immediate post operative (T1) and Late Post operative (T2) were collected, traced, evaluated and analyzed for soft and hard tissue changes by certain vertical, angular and horizontal parameters.

Results: The average setback obtained at the pogonion (Pg) was 10.40 mm with relapse after 6 months of 1.87 mm (17.98 %). The horizontal setback obtained at the point B(B) was 9.77 mm with a relapse of 1.37 mm (14.02 %). The relapse at the menton (Me) was 24.55 %. The horizontal setback obtained at the soft tissue points Pg', B' and lower lip were 6.77mm, 8.27mm and 8.07mm respectively and the relapse rate after 6 months were 4.43%, 10.52% and 3.35% respectively. The ratio of change of soft tissue pogonion and B' relative to the Pg and B were 75.90 % and 88.10 % respectively.

Conclusion: The Bilateral Sagittal Split Setback Surgery for the surgical correction of the prognathic mandible in our centre is found to be a stable procedure. The relapse rate at the pogonion (Pg) is about 18 % and this over correction should be done in the future cases to improve the results.

"© 2025 by the Author(s). Published by IJAR under CC BY 4.0. Unrestricted use allowed with credit to the author."

Corresponding Author:-Josepaul C.I

Address:-Senior Lecturer, Department of Oral and Maxillofacial Surgery, Royal Dental College, Palakkad.

Introduction:-

Aesthetic factor is one of the most dominant factors for surgical correction of facial deformities. The aesthetico-physiological studies of Secard and Backman reveals that the “Impressions of Personality” is related to occlusion and soft tissue profile. The protruding and receding chin were negatively assessed from the aesthetic point of view.

The better way to understand the success of orthognathic surgery is to re-evaluate the aftermath of surgery using a standardised criteria. Hence the evaluation of hard and soft tissue profile after surgery is essential to determine the aesthetic outcome of the patient and also to create a database for predicting the results in future

The beauty of SSRO lies in the curvilinear osteotomy in the anteroposterior direction of mandible and the distinct condylar and dental segment separated by it with the neurovascular bundle on the dental segment and it can be pitched rolled and yawed. The modification of SSRO by Dalpont, Hunsunk and Epker made it more popular nowadays.

There may be differences in the Bilateral Sagittal Split Osteotomy surgical technique that is used in various centres, so it is essential for each surgeon to understand the soft tissue and skeletal changes following Bilateral Sagittal Split Osteotomy setback surgery. This retrospective study intends to evaluate the soft tissue and skeletal changes following Bilateral Sagittal Split setback Osteotomy using certain specified cephalometric landmarks on lateral cephalometric radiographs..

This will help us to create a database of soft tissue versus hard tissue changes following BSSO. This will help us to predict the results of BSSO setback procedure better and will eventually benefit our patients in long.

Patients and Methods:-

Patients:-

All patients had undergone Bilateral sagittal split osteotomy for correction of compromised esthetics due to their skeletal class III condition in our institute, under same surgeon. All of them underwent an average 4 months of presurgical orthodontics phase.

Inclusion Criteria.

All participants were nongrowing adults treated by Bilateral Sagittal Split Osteotomy setback with rigid internal fixation for skeletal class III cases and whose preoperative and postoperative radiographs with a follow up of 6 months. Participants who had undergone upper jaw surgeries, genioplasty, and subjects with Craniofacial anomalies and cleft lip or cleft palate were excluded from this study.

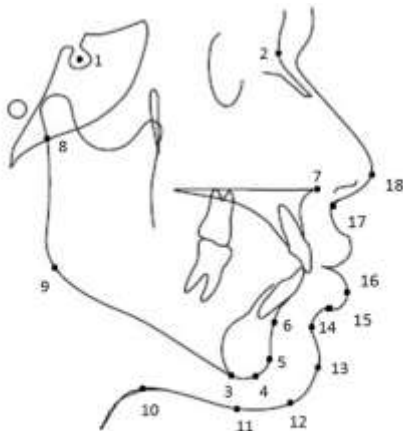
Procedure:-

Pre and post surgical lateral cephalographs of 30 participants with skeletal class III malocclusion who received combined orthodontic-surgical treatment With Bilateral Sagittal Split Osteotomy setback surgery were collected from the department records of the participant. Participant information will not be revealed. No facial details of the participant will be revealed. Informed consent from the participants and Ethical Committee approval was acquired prior to the study

Research Methodology:-

The cephalometric landmarks were identified and tracings were measured according to different hard and soft tissue landmarks (Fig 1). Angular (Table A) and linear measurements were taken to the nearest 0.05° or 0.05mm on lead acetate sheets with extra smooth finish HB pencil with diameter of 0.3mm

Paired t test were used for comparison of changes in the parameters at different time intervals. The statistical calculation were performed using the software SPSS for windows (Statistical Presentation System Software, SPSS Inc. 1999, New York) version 17

Fig 1:-Soft Tissue And Hard Tissue Landmarks.

1.Sella (S) 2.Nasion (N) 3. Menton (Me) 4. Gnathion (Gn) 5. Pogonion (Pg)

6. Point B (B) 7. Anterior Nasal Spine(ANS) 8. Articulare (Ar) 9. Gonion (Go)

10. Cervical point (C) 11. Soft tissue menton (Me') 12. Soft tissue gnathion (Gn') 13.soft tissue pogonion (Pg) 14. Mentolabial sulcus or soft tissue point B (B')

15 . Labraleinferius (Li) 16. Inferior lip anterior point (Ila) . 17. Subnasale (Sn)

18 . Pronasale (Pn

Table A**ANGULAR CHANGES.**

1. Mandibular plane angle(MPA) The angle formed between the line from Go – Gn and the HP
2. SNB Angle(SNB).
3. Lip- chin- throat- angle(LCTA) The angle formed by intersection of lines Li- Pog' and C – Gn'
4. Mentolabial angle(MLA) - The angle formed by the intersection of point Li and Pog' at B'

Results:-

In our study the vertical hard tissue changes and vertical soft tissue changes are also evaluated. But, of the 15 pair of vertical hard tissue parameters studied only 3 pair are significant. Similarly , of the 9 pairs of vertical soft tissue parameters studied only 1 pair is significant statistically. On the other hand the 12 of the 15 hard tissue horizontal parameters and 8 of the 12 soft tissue horizontal parameters were significant.

Hard Tissue Changes.

Hard tissue point	SETBACK(mm)	RELAPSE (mm)	RELAPSE RATE (%)
pogonion	10.40	1.87	17.98
Point B	9.77	1.37	14.02
Menton	9.90	2.43	24.55

Soft Tissue Changes.

SOFT TISSUE POINT	HORIZONTAL SETBACK (mm)	RELAPSE (mm)	RELAPSE RATE (%)
Soft tissue pogonion –Pg'	6.77	0.30	4.43
Soft tissue Point B - B'	8.27	0.87	10.52
Inferior lip anterior point (Ila)	8.07	0.27	3.35

Angular Changes.

ANGLES	PRE OP (degree)	IMM POST(degree)	LATE POST(degree)	RELAPSE (degree)
MANDIBULAR PLANE ANGLE(MPA)	25.90	27.83	26.50	- 1.33
SNB	87.43	81.73	82.23	0.50
LIP CHIN THROAT ANGLE(LCTA)	115.90	130.57	119.33	- 11.23
MENTOLABIAL ANGLE(MLA)	128.27	115.73	117.00	1.27

Ricketts E Line.

	RICKETTS E LINE - LOWER LIP
preoperative	2.27
Immediate post operative	2.53
Late post operative	0.40

Hard And Soft Tissue Relationship

VARIABLES	CORRELATION COEFFICIENT (HORIZONTAL)	RATIO OF SOFT TISSUE TO HARD TISSUE CHANGE
Pg' - Pg	0.99	75.90
B' - B	1	88.10
ILa - Pg	0.99	91.7

Discussion:-

The evaluation of skeletal and soft tissue changes after BSSO setback seen in the literature cannot be considered universal as it depends on the surgeons technique and the studying population. In our study the average setback obtained at the pogonion (Pg) and Point B(B) were 10.40 mm and 9.77 mm respectively with relapse after 6 months of 1.87 mm (17.98 %) and of 1.37 mm (14.02 %), which were statistically significant. The group of patients studied shows significant soft and hard tissue changes changes in horizontal direction but not in vertical direction.

The horizontal setback obtained at the soft tissue points Pg' , B' and lower lip(ILa) were 6.77mm , 8.27mm and 8.07mm respectively and the relapse rate after 6 months were 4.43% , 10.52% and 3.35% respectively.

The comparison of soft and skeletal tissue is an essential part of this study as this will provide an idea of the relative soft tissue movement that is to be done in predicting the final profile of the patient. In this study the ratio of change of soft tissue pogonion(Pg') and B' relative to the Pg and B were 75.90 % and 88.10 % respectively. The Pearson correlation coefficient for the pair of Pg'- Pg and B' – B were 0.9 and 1 respectively.

In our study the ratio between the lower lip (ILa) and the Pg was 91 % which is statistically significant. Hence for a setback of 10 mm at Pg there is a setback of lower lip of 9 mm which can be applied in the presurgical planning (1: 0.9)

The Ricketts E line (E) is used to determine the lower lip position. The mean presurgical position of lower lip was 2.27 mm ahead of E-line which got reduced to 0.4 mm in the 6 month follow up period.

The angle included in this study are mandibular plane angle (MPA), SNB, lip chin throat angle (LCTA) and mentolabial angle (MLA).

Also in this study it can be seen that the longer the mandibular body length more will be the setback obtained. Among the 30 patients studied 18 patients show anterior relapse, 9 patients shown further posterior movement and 3 patients with no relapse tendency.

Relapse

In orthognathic surgery any deviation from the acceptable surgical results can be called as relapse.

Proper seating of the condyles or the control of the proximal segment, condylar growth and altered mandibular posture were important factors producing relapse. The condylar growth factor can be minimised by delaying operation until towards the end of the growth period and the tendency for the patient to protrude the mandible might be lessened by detaching the medial pterygoid muscle and the speno-mandibular ligament.

The essential impetus for relapse comes from a proprioceptive drive to re-establish the preoperative dento-oro-facial environment, and that the site of most active proprioceptive stimulus is within the condylo-ramus-masticatory muscle complex, that under the influence of the proprioceptive drive, bone can be remodel.

The tongue and other musculature can respond to the proprioceptive demands by assuming functions and taking positions to reapproximate the preoperative alignment of the teeth.

Immaturity of the bony callous at the osteotomy site, stretching of the pterygomasseteric sling beyond its normal resting length and failure of the masticatory muscles to adapt to alterations in their length are also implicated in relapse.

Relapse has been linked to instability at the osteotomy site, distal rotation of the proximal segment, postsurgical pull of the pterygomasseteric sling, and failure of other masticatory muscles to adapt to the new environment. Presurgical orthodontics allows good intercuspation after surgery, and hence is also an important factor in the prevention of relapse.

Positioning of condyle also plays a role in stability of BSSO. It is believed that positioning of condyle back into fossa is easier in setback surgeries as soft tissues around the proximal segment of mandible get compressed and not stretched. The position of the condyle is mainly determined by muscle tone and rigidity of capsule. During anesthesia, capsule and muscles around condyle may be hypotonic but when they return to normal tone post-operatively, there may be change in the position of condyle which can lead to relapse and visible malocclusion.

Hence from the surgeons point of view profile correction is given more importance than giving textbook occlusion. Regular follow up by the operating surgeon in the immediate postoperative period and proper use of guiding elastics play an important role in achieving stable occlusion.

Summary

This retrospective study intends to evaluate the soft tissue and skeletal changes Following Bilateral Sagittal Split Osteotomy setback using certain specified landmarks on cephalometric radiographs.

The mean setback obtained at pogonion (Pg) was 10.40 mm with a relapse of 1.87 mm or 17.98 %. The Menton (Me) expressed more relapse among the hard tissue points. Among the soft tissue points the relapse rate is more for the inferior labial sulcus (ILs)

The more the setback, the more will be the relapse as can be seen in this study. Also more the length of mandibular body the more will be the setback and vice versa.

The Mentolabial angle (MLA) and the lip – chin –throat angle (LCTA) tends to reduce on longer post operative period and thus enhances the esthetics. The Ricketts E-Line (E) seems to be reaching near the lower lip after the surgery which again improves the esthetics.

There is a statistically significant relationship between the skeletal and soft tissue points. In this study the soft tissue pogonion (Pg) is changing at a rate of 76 % of the pogonion (Pg). Similarly the lower lip (ILa) is changing at a rate

of 91 % of the pogonion(Pg). This relative information can be used in the presurgical evaluation and also to predict the outcome of surgery to the patient.

The controversies can be seen in the literature about the treatment plan of skeletal class III. Most centres prefer only the BSSO procedure than operating the both jaws where as it is a bijaw procedure in some centres. The stability of this double-jaw procedure should be evaluated on larger samples and for long term basis. The other controversy is between the surgery first approach and the conventional surgery. The difference in the stability of both approach will be a debatable topic in future.

References:-

1. Mani V. Surgical correction of facial deformities. JP Medical Ltd; 2010 Feb 28.
2. Naini FB, Cobourne MT, Garagiola U, McDonald F, Wertheim D. Mentolabial angle and aesthetics: a quantitative investigation of idealized and normative values. *Maxillofacial plastic and reconstructive surgery*. 2017 Dec 1;39(1).
3. Joe I, Chou C, Fong HJ, Kuang SH, Gi LY, Hwang FY, Lai YC, Chang RC, Kao SY. A retrospective analysis of the stability and relapse of soft and hard tissue change after bilateral sagittal split osteotomy for mandibular setback of 64 Taiwanese patients. *Journal of oral and maxillofacial surgery*. 2005 Mar 1;63(3):355-61.
4. Joss CU, Vassalli IM. Stability after bilateral sagittal split osteotomy advancement surgery with rigid internal fixation: a systematic review. *Journal of oral and maxillofacial surgery*. 2009 Feb 1;67(2):301-13..
5. Joss CU, Joss-Vassalli IM, Bergé SJ, Kuijpers-Jagtman AM. Soft tissue profile changes after bilateral sagittal split osteotomy for mandibular setback: a systematic review. *Journal of oral and maxillofacial surgery*. 2010 Nov 1;68(11):2792-801..
6. Ghassemi M, Hilgers RD, Jamilian A, Hölzle F, Fritz U, Gerressen M, Ghassemi A. Consideration of effect of the amount of mandibular setback on the submental region in the planning of orthodontic–orthognathic treatment. *British Journal of Oral and Maxillofacial Surgery*. 2014 Apr 1;52(4):334-9.
7. Lee JY, Kim YK, Yun PY, Lee NK, Kim JW, Choi JH. Evaluation of stability after orthognathic surgery with minimal orthodontic preparation: comparison according to 3 types of fixation. *Journal of Craniofacial Surgery*. 2014 May 1;25(3):911-5.
8. Kaklamanos EG, Kolokitha OE. Relation between soft tissue and skeletal changes after mandibular setback surgery: a systematic review and meta-analysis. *Journal of Cranio-Maxillofacial Surgery*. 2016 Apr 1;44(4):427-35.
9. Kwon YW, Bayome M, Park JU. Stability after bilateral sagittal split osteotomy with rigid internal fixation in surgery-first approach. *Journal of Oral and Maxillofacial Surgery*. 2016 Apr 1;74(4):828-e1.
10. Kwon YW, Bayome M, Park JU. Stability after bilateral sagittal split osteotomy with rigid internal fixation in surgery-first approach. *Journal of Oral and Maxillofacial Surgery*. 2016 Apr 1;74(4):828-e1.
11. Al-Moraissi EA, Ellis E. Stability of bicortical screw versus plate fixation after mandibular setback with the bilateral sagittal split osteotomy: a systematic review and meta-analysis. *International journal of oral and maxillofacial surgery*. 2016 Jan 1;45(1):1-7.
12. Park KH, Sandor GK, Kim YD. Skeletal stability of surgery-first bimaxillary orthognathic surgery for skeletal class III malocclusion, using standardized criteria. *International journal of oral and maxillofacial surgery*. 2016 Jan 1;45(1):35-40.
13. Tabrizi R, Pourdanesh F, Sadeghi HM, Shahidi S, Poorian B. Does Fixation Method Affect Stability of Sagittal Split Osteotomy and Condylar Position?. *Journal of Oral and Maxillofacial Surgery*. 2017 Dec 1;75(12):2668-e1
14. Jeong JH, Choi SH, Kim KD, Hwang CJ, Lee SH, Yu HS. Long-Term Stability of Pre-Orthodontic Orthognathic Bimaxillary Surgery Using Intraoral Vertical Ramus Osteotomy Versus Conventional Surgery. *Journal of Oral and Maxillofacial Surgery*. 2018 Feb 20.
15. Merta M, Kiukkonen A, Leikola J, Stoor P, Suojanen J. Skeletal stability after mandible bilateral sagittal split osteotomy—comparison of patient-specific implant and mini-plate fixation: A retrospective study. *Journal of Cranio-Maxillofacial Surgery*. 2024 Jan 1;52(1):93-100.
16. Li DT, Wang R, Wong NS, Leung YY. Postoperative stability of two common ramus osteotomy procedures for the correction of mandibular prognathism: A randomized controlled trial. *Journal of Cranio-Maxillofacial Surgery*. 2022 Jan 1;50(1):32-9.