



RESEARCH ARTICLE

POST TRAUMATIC PSEUDOANEURYSM OF RIGHT SUBCLAVIAN ARTERY ABOUT ONE CASE: REPORT

Afif Yasser, Zerhouni Amine, Yaseen Ahmad, Chabbar Sara, Faoji Fatimazahra, Mounir Anass, El Kettani Chafik and Bouhouri Mohamed Aziz

Manuscript Info

Manuscript History

Received: 10 April 2025
Final Accepted: 13 May 2025
Published: June 2025

Key words:-

Subclavian Artery Pseudoaneurysm,
Blunt Chest Trauma, Endovascular
Treatment, Computed Tomography
Angiography, Cervical Spine Injury,
Vascular Surgery, Case Report

Abstract

Background: Pseudoaneurysms of the subclavian artery are uncommon and typically result from penetrating or blunt trauma. Early diagnosis and prompt management are essential to prevent life-threatening complications.

Case Presentation: We present the case of a 30-year-old male involved in a motor vehicle accident, resulting in multiple severe injuries, including a rare traumatic pseudoaneurysm of the proximal right subclavian artery. Initial computed tomography angiography (CTA) revealed a 12×12 mm pseudoaneurysm which increased to 17×12 mm within 48 hours despite supportive care. Due to rapid deterioration and progression of intracranial hemorrhage, surgical repair could not be performed, and the patient succumbed on the fourth day of admission.

Conclusion: Subclavian artery pseudoaneurysms should be suspected in high-energy chest trauma, especially when cervical vertebral injuries coexist. CTA remains the diagnostic modality of choice. Endovascular management is increasingly favored for its minimally invasive nature and favorable outcomes.

"© 2025 by the Author(s). Published by IJAR under CC BY 4.0. Unrestricted use allowed with credit to the author."

Introduction:-

Pseudoaneurysm develops when there is a lack of integral arterial wall structure, resulting in blood leakage through the wall, and then wrapped by perivascular tissue. Subclavian artery pseudoaneurysm is rare, and the reported incidence is about 1 to 2%. Treatment is required to prevent rupture, embolization, or tracheal compression [1,2]

Case Report:

A 30-year-old man was involved in a motor vehicle accident, causing polytrauma.

The inspection found a patient in the attitude of a traumatized lower limb, with a right cervical and thoracic ecchymosis.

The physical examination found an unconscious patient with a Glasgow score of 8/15, symmetrical and reactive pupils, blood pressure: 77/55 mmHg, heart rate: 156 beat per minute, respiratory rate: 20 cycles per minute, O₂ saturation: 80%. Cardiovascular auscultation was without abnormality and pleuropulmonary auscultation found auscultatory silence of the right hemithorax.

The abdomen was supple and the vascular examination was without abnormality (preserved cubital and radial pulse).

After monitoring and conditioning, a body computed tomographic showed:

At the cerebral level (figure1):

1. A right frontal intraparenchymal hematoma
2. A meningeal hemorrhage at the supratentorial level
3. Intraventricular hemorrhage

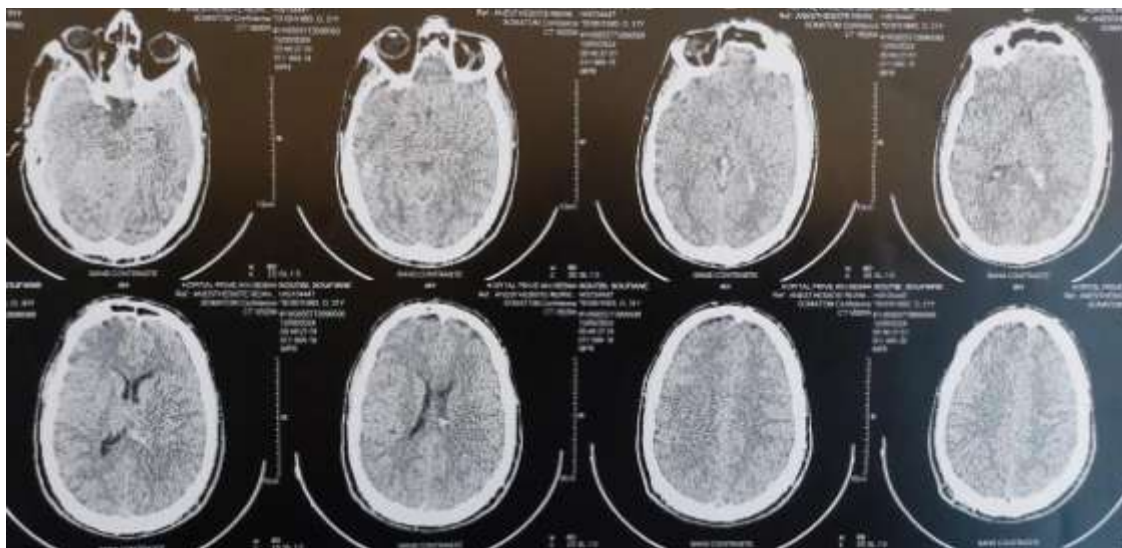


Figure 1:- Cerebral CT scan shows a right frontal intraparenchymal hematoma.

At the cervical level:

A C1C2 dislocation without posterior wall displacement

- At the thoracic level:
1. Large right lateral tracheal hematoma compressing the right internal jugular vein, the right brachiocephalic vein trunk, the superior vena cava, and deviating the heart to the left
2. Moderate hemopericardium
3. Extravasation of contrast product from the right brachiocephalic arterial trunk and the origin of the subclavian artery
4. Large left hemopneumothorax (figure 2)
5. Moderate right hemothorax (figure 2)
6. Contusion and alveolar hemorrhage of the right lung

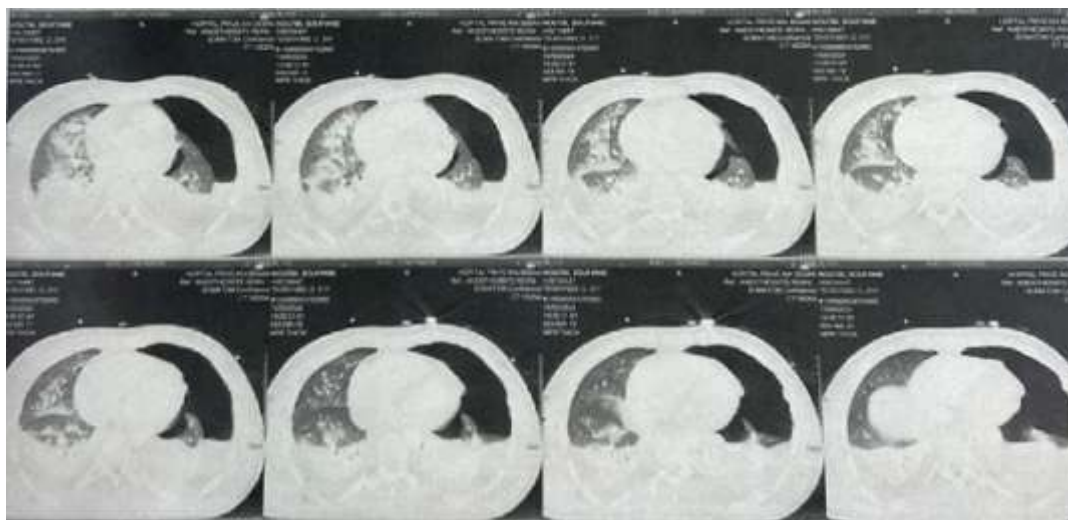


Figure 2:- CT scan chest demonstrate Large left hemopneumothorax, moderate right hemothorax, contusion and alveolar hemorrhage of the right lung

In the lower limbs:

Displaced fracture of the right femoral diaphysis

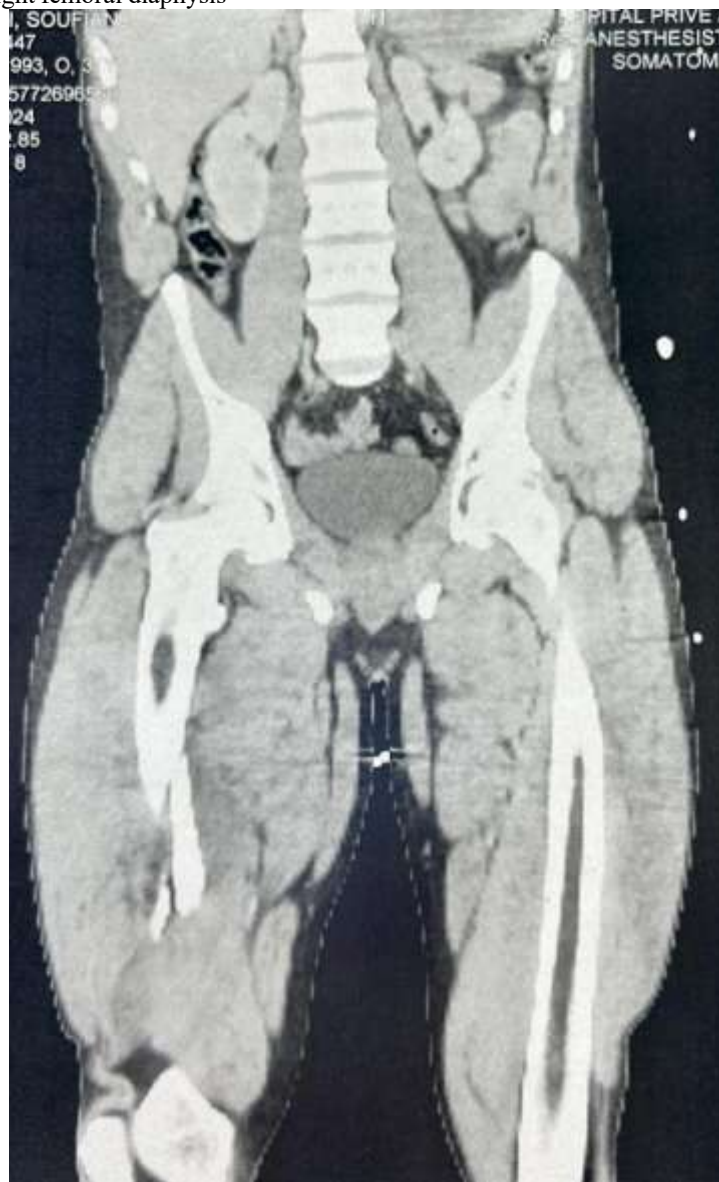

Figure 3:- Displaced fracture of the right femur.

A CT angiogram of the supra-aortic trunk objectified:

a pseudoaneurysm of 12*12mm in diameter of the proximal portion of the right subclavian artery (Figure 4)

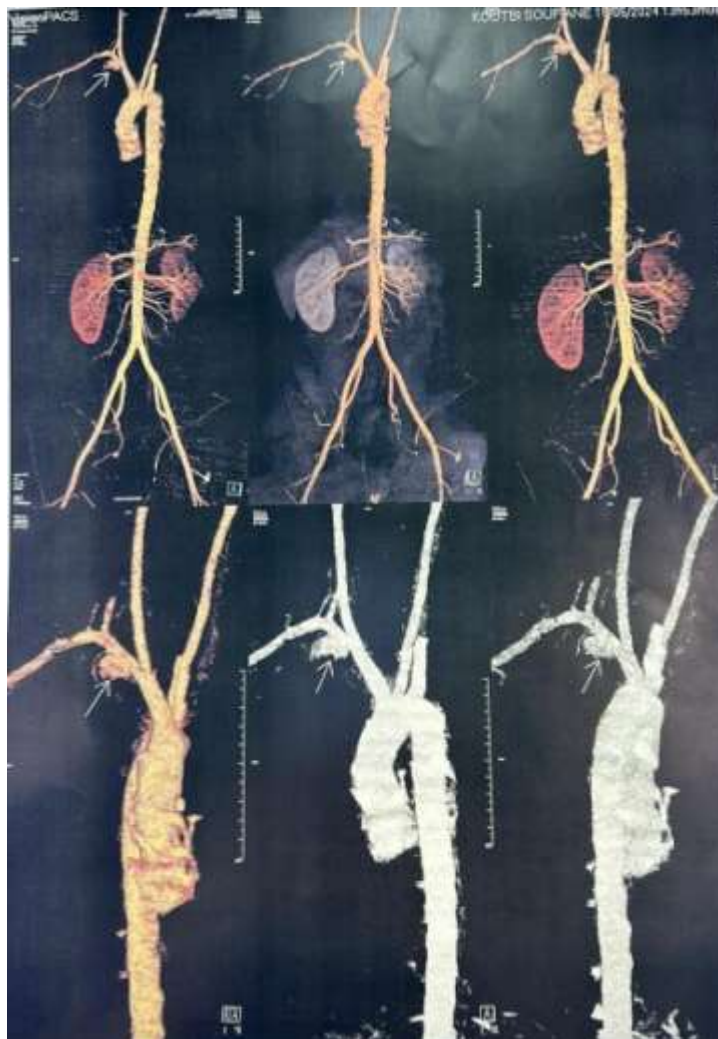

Figure 4:- A CT angiography objectified a pseudoaneurysm of 12*12mm in diameter of the proximal portion of the right subclavian artery.

During his hospitalization, the patient was intubated, ventilated, and sedated. He has benefited from bilateral thoracic drainage, fixation of his femoral fracture with intramedullary nailing and Cervical immobilization of C1C2 subluxation with a rigidus neck brace.

The evolution was marked on the 2nd day by the increase in the size of the right frontal intraparenchymal hematoma, the lateral tracheal hematoma and the pseudoaneurysm 17*12 mm vs 12*12mm.

The patient was scheduled for surgical treatment of his aneurysm but he died on day 4 of his hospitalization.

Discussion:-

Post traumatic pseudoaneurysm of subclavian artery is rare and generally arises from trauma to the upper part of the chest and the thoracic outlet [3,4]. Is often associated with fractures of surrounding bony structures, primarily the clavicle and first rib; which is not the case with us.

In rare cases, it can be associated with fractures and/or luxation of cervical vertebrae, as in our case. The site of the arterial lesion is frequently located within the scalene muscles, but the origin of the vertebral artery can sometimes be affected as in our case (figure 4). Symptoms of subclavian artery pseudoaneurysm vary depending on its location and size. In some cases, it is found by chance without symptoms or as a simple palpable mass on the neck. Local compression may cause dysphagia, hoarseness, dyspnea or Horner's syndrome. It can also appear with ischemia of the upper limb or cerebral infarction due to embolism caused by internal thrombus.

Brachial plexus palsy can be found, it is often secondary to direct compression by the pseudoaneurysm [5,6,7]. The arterial examination is necessary because the arterial injuries can be masked by the excellent collateral circulation.

surrounding the scapula [8]. In our patient, the arterial examination was normal. Pseudoaneurysm of subclavian artery can be diagnosed depending on the patient's history, clinical manifestations, and imaging examination [9]. Arterial Doppler ultrasound generally allows to establish a positive diagnosis, but it depends significantly on the operator's experience, some lesions are affected by poor image quality due to the interference of the clavicle [7,9,10]. CT scan can present the size and surrounding structure of the mass, but there are also cases of misdiagnosis. CT Angiogram provides much more morphological and topographical details, can show the lesions from multiple angles, which present the relationship between mass and the surrounding tissues more accurately and contribute to the judgment of the origin of the lesion [9,11].

The angiography can have a diagnostic and therapeutic purpose. The indications for angiography are currently limited, because of the high sensitivity and specificities offered by computed tomography angiogram [7]. Arteriography is used in cases where an endovascular procedure is considered from the outset. In this observation, the diagnosis of the pseudoaneurysm of the subclavian artery was confirmed on the data of the computed tomographic angiogram [9,12].

If proper treatment is not provided, rupture can occur, and cause life-threatening massive hemorrhage [9,10].

Surgery is the traditional therapeutic method, but it is sometimes difficult to expose the pseudoaneurysm completely, and the risk of nerve injury and massive hemorrhage are high because of the complex anatomical conditions of the subclavian artery [13].

In recent years, endovascular treatment using covered stenting has been recommended by many experts due to its advantages such as less invasiveness and lower complication rate. And it has given vascular surgeons the ability to manage vascular lesions that otherwise would be extremely difficult to treat with standard surgical therapy [2-14].

Conclusion:-

Post traumatic pseudoaneurysms of Subclavian artery are rare. The Symptoms are vary depending on its location and size. CT Angiogram is the most sensitive and specific radiological examination used in emergency. The endovascular approach is considered to be the first line treatment, given that open surgery is a complex procedure due to anatomical features, being associated with significant morbidity and mortality.

References:-

1. Mudoni A, Cornacchiari M, Gallieni M, et al. Aneurysms and pseudoaneurysms in dialysis access. Clin Kidney J 2015; 8:363e7.
2. Van der Weijde E, Vos JA, Heijmen RH. Hybrid repair of a large pseudoaneurysm of the proximal right subclavian artery in a Marfan patient. J Vasc Surg Cases Innov Tech 2017; 3:215e7.
3. Graham JM, Feliciano DV, Mattox KL, et al. Management of subclavian vascular injuries. J Trauma. 1980; 20:537–545.
4. Watelet J, Testart J, Biga N, et al. A propos d'un cas de rupture
5. traumatique de l'artère sous clavière. J Chir. 1976; 112:37–45.
6. Evans T, Roy S, Rocker M. Subclavian Artery Pseudoaneurysm Formation 3 Months after a Game of Rugby Union. Case Rep Emerg Med. 2015; 2015(1):1–3
7. Serrano JA, Rodríguez P, Castro L, Serrano P, Carpintero P. Acute subclavian artery pseudoaneurysm after closed fracture of the clavicle. Acta Orthop Belg. 2003 Dec;69(6):555-7
8. Elouakili, M. Bouayad, M. Kharmaz, F. Ismael, M.R. Moustaine. Faux anévrisme de l'artère sous-clavière compliquant une fracture de la clavicule. Journal de Traumatologie du Sport 28 (2011) 185–188.
9. Tsutsumi K, Saito H, Ohkura M. Traumatic pseudoaneurysm of the subclavian artery following anterior dislocation of the shoulder: report of a surgical case. Ann Thorac Cardiovasc Surg. 2006; 12:74–76.
10. Wang Y, Dong X, Liang H, Mkangala A, Su Y, Liu D. Endovascular Treatment of Subclavian Artery Pseudoaneurysm. Ann Vasc Surg. 2020 May; 65:284. e1-284.e6
11. Alawneh K, Raffee L, Hamouri S. Delayed endovascular stenting of right subclavian artery pseudoaneurysm caused by gunshot accident in a Syrian Refugee: a case report. Vasc Endovascular Surg 2017; 51:386e9
12. Van der Weijde E, Vos JA, Heijmen RH. Hybrid repair of a large pseudoaneurysm of the proximal right subclavian artery in a Marfan patient. J Vasc Surg Cases Innov Tech 2017; 3:215e7
13. Jaiswal D. Management of Subclavian Artery Pseudoaneurysm: Case Series World J Vasc Surg. 2022; 5(1): 1032
14. Francis D, Kumar M, Singh M, Okafor TL, Reddy MMRK, Inban P, Singh P. Endovascular management of traumatic pseudoaneurysm of left subclavian artery: A case report. Radiol Case Rep. 2023 Sep 5; 18(11):4066-4070.
15. J. Malvaux, A.Belhaj, P. Eucher. Traitement chirurgical d'un pseudo-anévrisme post-traumatique de l'artère subclavière droite. Louvain Med 2021 Septembre : 140 : 373-378.