

 <p>ISSN NO. 2320-5407</p>	<p>Journal Homepage: -www.journalijar.com</p> <h2 style="text-align: center;">INTERNATIONAL JOURNAL OF ADVANCED RESEARCH (IJAR)</h2> <p style="text-align: center;">Article DOI: 10.21474/IJAR01/21162 DOI URL: http://dx.doi.org/10.21474/IJAR01/21162</p>	
---	--	---

RESEARCH ARTICLE

ANOTHER REASON TO BAN SUBCLAVIAN CATHETERS: A CASE REPORT AND LITERATURE REVIEW

**Khaoula Tanafaat, Harlow Mouele, Larios Ahlonson, Mohammed Hallak, D.El Kabbaj
and D. Ibrahim Montasser**

1. Department of Nephrology in Military Training Hospital Mohammed V, Medicine and Pharmacology University of Rabat CP 10000.

Manuscript Info

Manuscript History

Received: 12 April 2025
Final Accepted: 15 May 2025
Published: June 2025

Abstract

The high incidence of catheter colonization and associated infections, with or without bacteremia, remains a significant factor in morbidity and mortality. The microbial organisms colonizing the catheter can be influenced by various factors, including the type of central venous catheter, insertion and maintenance techniques, and whether guidewire replacement is permitted. This publication reports, in addition to infectious and thrombotic risks, an unusual but potentially serious complication in a patient with a subclavian dialysis catheter. This complication was discovered incidentally during her hospitalization for an infectious syndrome.

"© 2025 by the Author(s). Published by IJAR under CC BY 4.0. Unrestricted use allowed with credit to the author."

Introduction:-

Subclavian catheters for hemodialysis were first used by Erben et al. in 1969 (1), but their widespread acceptance only occurred after the introduction of the modified single-needle dialysis cannula in 1979 by Uldall et al. (2). Due to their ease of insertion and immediate usability, they were widely employed to achieve vascular access in patients with acute kidney failure or chronic hemodialysis patients experiencing arteriovenous (A-V) fistula failure.

However, the high incidence of catheter colonization and associated infections, with or without bacteremia, remains a significant factor in morbidity and mortality. The microbial organisms colonizing the catheter can be influenced by various factors, including the type of central venous catheter, insertion and maintenance techniques, and whether guidewire replacement is permitted.

This publication reports, in addition to infectious and thrombotic risks, an unusual but potentially serious complication in a patient with a subclavian dialysis catheter. This complication was discovered incidentally during her hospitalization for an infectious syndrome.

Case Report:

Patient History

The patient was a 56-year-old woman with the following medical history:

- Ischemic heart disease treated with stenting in 2020, with a left ventricular ejection fraction (LVEF) of 25-30%.
- Hyperthyroidisme.

Corresponding Author:-Khaoula Taanafat

Address:-Department of Nephrology in Military Training Hospital Mohammed V, Medecin and Pharmacology University of Rabat CP 10000.

- Former chronic smoker, abstinent for three years.
- Chronic hemodialysis since 2020 due to hereditary polycystic hepatorenal disease, with two previously created arteriovenous fistulas (left radial and basilic) that had thrombosed.

Clinical Presentation

She was admitted for the investigation of a febrile syndrome while undergoing dialysis through a subclavian tunneled catheter that had been in place for three months. The catheter had thrombosed multiple times and had been manipulated with guidewires to clear thrombi.

On admission, the examination revealed an altered general condition, a fever of 39°C, hypotension, and a systolic heart murmur at the aortic valve area.

Diagnostic Workup

Laboratory findings :

C-reactive protein (CRP) of 300 and a procalcitonin of 16. Central and peripheral blood cultures revealed methicillin-sensitive *Staphylococcus aureus* (MSSA).

In the context of normochromic normocytic anemia at 4 g/dL (compared to 11 g/dL three weeks prior) without externalized bleeding and with a history of anticoagulation therapy (vitamin K antagonists), a

An urgent transthoracic echocardiography (TTE) revealed thickened valvular structures with good opening, as well as thickening at the tip of the aortic valve, highly suggestive of infectious endocarditis.

A transesophageal echocardiography (TEE) was attempted but was not tolerated by the patient, leaving the diagnosis unconfirmed.

Contrast-enhanced thoraco-abdominal-pelvic CT scan (figure1) was performed to search for internal bleeding. It revealed multiple excavated masses with an infectious appearance, likely due to tuberculosis or staphylococcal pneumonia, with no signs of bleeding.

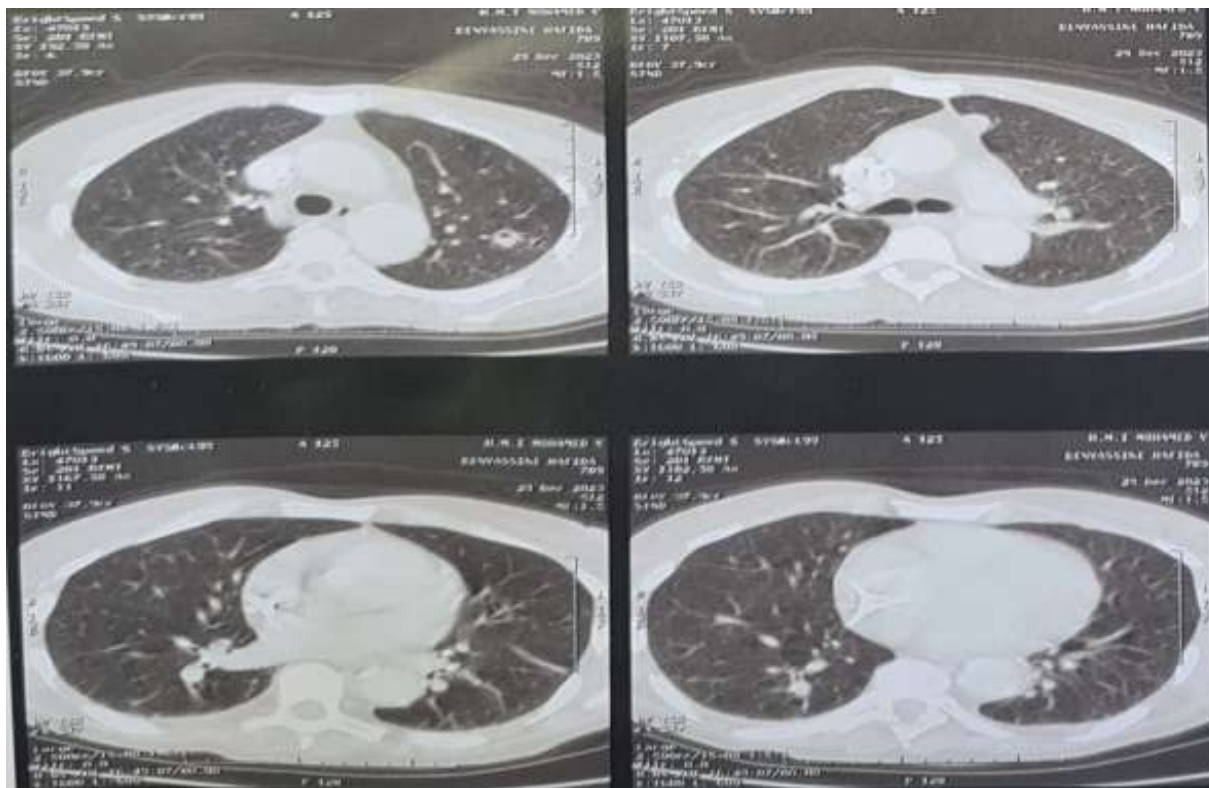


Figure 1:- Multiple excavated masses with an infectious appearance.

Chest X-ray (Figure 2) showed an alveolar syndrome more pronounced in the lower right lobe. Bronchoscopy was normal, and GeneXpert tests on sputum and bronchial aspirates were negative.

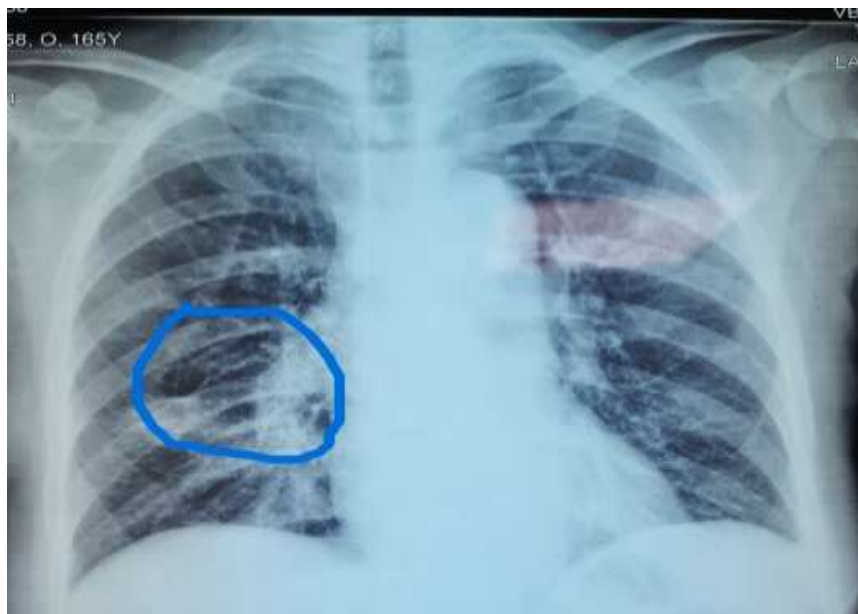
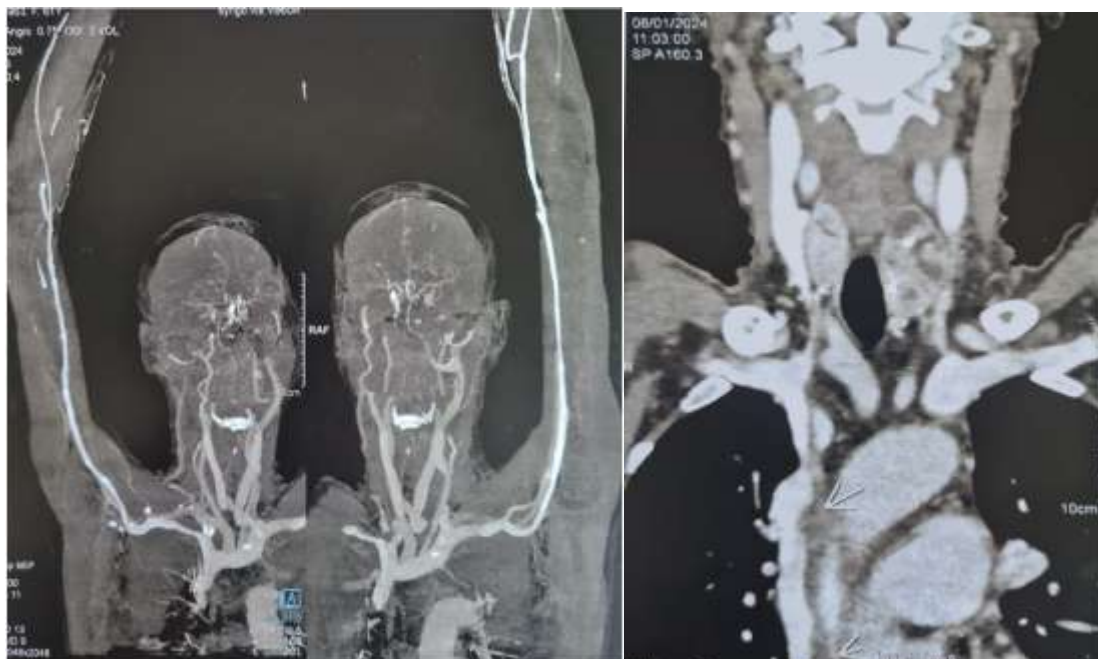

Figure 2:- Alveolar syndrome in the right lobe.

venous phleboscans Figures, to explore the deep venous system, a of the upper limbs, ordered by the vascular surgeon, revealed a thrombus affecting the superior vena cava over 20% of its surface and extending to the right atrium. **3 (A,B)**



Figures 3:- Venous phleboscans of the upper limbs revealed a thrombus affecting the superior vena cava over 20% of its surface and extending to the right atrium.

Additionally, a foreign body from the central venous line, likely a guidewire, was identified in the right lower lobar pulmonary artery **Figure 4**.

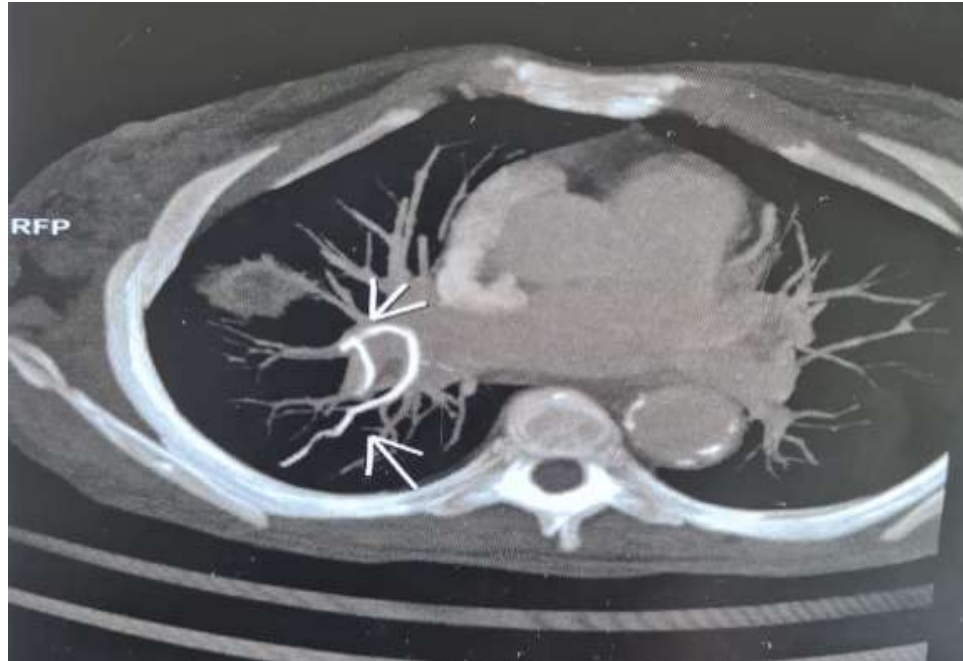

Figure 4:- The same phleboscans identified a foreign body likely a guidewire, in the right lower lobar pulmonary artery.

Management & Outcome

- **Vascular surgeons:** Reported difficulty in removing the intravascular material due to its distal location.
- **Thoracic surgeons:** Stated that removal would require a highly invasive procedure, possibly a lower lobectomy or right pneumonectomy.
- **Decision:** Conservative approach with targeted antibiotic therapy for infectious endocarditis.
- **Outcome:** Despite these challenges, the patient's clinical course was favorable, characterized by
 - Radiological resolution of pulmonary lesions.
 - Decrease in infectious markers.
 - Negative follow-up blood cultures.

Discussion:-

Catheter-Related Bloodstream Infections (CRBSIs)

Hemodialysis catheters are known to be a major risk factor for bacteremia, especially when compared to synthetic or native A-V fistulas (3).. The prolonged use of tunneled dialysis catheters significantly increases the risk of bacteremia.

The incidence of catheter-related bloodstream infections (CRBSIs) varies widely in the literature. CRBSI is defined as the presence of fever or systemic signs of infection in a patient with a tunneled catheter, without another evident infectious source, and with the same microorganism identified in blood cultures obtained from both the catheter and a peripheral vein. Differential time to positivity (DTP) has been used to confirm the diagnosis of CRBSI. A DTP of ≥ 120 minutes between blood cultures obtained from the catheter and peripheral vein is considered diagnostic of CRBSI (4)

Early bacteremia is defined as occurring within the first 90 days after catheter implantation. Secondary outcomes include the time to first CRBSI, causative organisms, and potential influencing factors.

The risk of bacteremia depends on several factors, including:

- The type of catheter.
- Catheter survival rates: In one study, Dittmer et al. (5) reported that 68% of catheters were colonized after an average of 27 days (range: 5–115 days), and 35% developed bacteremia with the same organism, with tunneling being utilized after an average of 15 days.

- The central vein used: A retrospective study (6) covering 14 years (2005–2019) involving 406 tunneled catheters implanted in 325 patients reported 85 cases of CRBSI, with an incidence of 0.40 per 1,000 catheter-days (81.1% occurring after six months of implantation). The study highlighted that catheter placement in the internal jugular vein was associated with a lower risk of infection compared to the femoral site or subclavian vein (7),(8) Other identified risk factors include:
- Nasal carriage of **Staphylococcus aureus** (SA): Nasal carriage was observed in 35% of patients, and 80% of these carriers experienced at least one episode of bacteremia compared to 12% of non-carriers. (9)
- Methicillin-resistant organisms: In the same study, 83.4% of CRBSIs were caused by Gram-positive organisms, particularly **Staphylococcus epidermidis** (48.4%) and **Staphylococcus aureus** (28.0%), with 12.5% of the **S. aureus** isolates being methicillin-resistant (10)

Central Vein Obstruction:

This condition frequently involves the subclavian and innominate veins, leading to venous hypertension, massive arm edema, and fistula failure. Repeated central catheterizations and chronic intimal changes caused by high-flow turbulence can predispose patients to the development of central obstructions.

In a situation similar to classical venous thoracic outlet syndrome (TOS), the subclavian vein becomes vulnerable due to its proximity to the junction of the clavicle and the first rib. Enlargement of the anterior scalene muscle (located posterior to the subclavian vein), the subclavius muscle, and the costoclavicular ligament can all contribute to narrowing the thoracic outlet's anterior space, promoting blood stasis and subsequently thrombus formation.

Based on decades of experience with this situation in venous TOS, it is widely recognized that such stenoses generally do not respond well to endovascular treatment. Physical bony decompression, often through first-rib resection or clavicle resection, is frequently necessary to salvage the fistula or create a homolateral AVF to ensure long-term patency. (11).

Guidewire Migration

The migration of a central venous catheter guidewire is a serious yet rare complication of indwelling intravenous catheters.

The incidence rate is estimated at 0.1% of central venous catheter insertions (12).

Particularities of J-Wire Construction

The J-wire features a rigid internal structure surrounded by a coiled wire for flexibility. The "J" tip is flexible, reducing the risk of vascular perforation, while the straight portion facilitates catheter introduction.

With proper handling, complications should be minimal. The J-wire should glide smoothly through the catheter introducer and be easily removed after catheter placement. Unexpected resistance during these steps should alert the clinician to possible complications. In this case, resistance during wire removal likely led to its shearing. Without preserving the wire, the exact nature of the embolized fragment remains unclear. Observations of the J-tip coiling around the internal wire have been made repeatedly, suggesting that the coiled J-tip was sheared off.

Site of Embolization

The site of embolization depends on the entry point and size of the fragment(13). Larger fragments introduced via venous access may remain with the proximal end in the vena cava and the distal end in the right atrium, ventricle, or pulmonary artery. Smaller fragments often reach the pulmonary arteries. Similarly, smaller fragments on the arterial side tend to lodge in peripheral vessels.

Techniques and Instrumentation

The decision to remove foreign bodies is controversial due to the risks associated with both extraction and leaving the fragments in situ. However, literature tends to favor the prompt removal of foreign bodies. Fisher and Ferreyro (14) found that only 29% of patients with retained foreign bodies survived without significant complications during long-term follow-up, with a 71% mortality rate associated with retained fragments.

Potential complications include myocardial perforation, pulmonary embolism, arrhythmia, sepsis, endocarditis, and even cardiac arrest. This unpredictability underscores the importance of immediate removal of foreign bodies.

Various techniques and instruments have been described for the extraction of intravascular foreign bodies. The most commonly used methods involve a snare or grasping device, such as helical baskets or bronchoscopy forceps (13) (15)

Current endovascular treatment options for a dislodged "peripherally inserted central catheter" CVPC include the use of a loop snare, basket retriever, balloon catheter, and grasping forceps (16) (17) The loop snare method, recognized as a standard endovascular approach for retrieving a dislodged CVPC, has demonstrated high success rates (16) (17)

For pulmonary arteries and cardiac chambers, soft loops made of stranded stainless-steel cable (1.5 cm outer diameter) are used. The size and angulation of the loop should be modified according to the foreign body's location.

The snare technique has a high success rate, with rare complications, and no deaths have been reported **figure 6** (14)

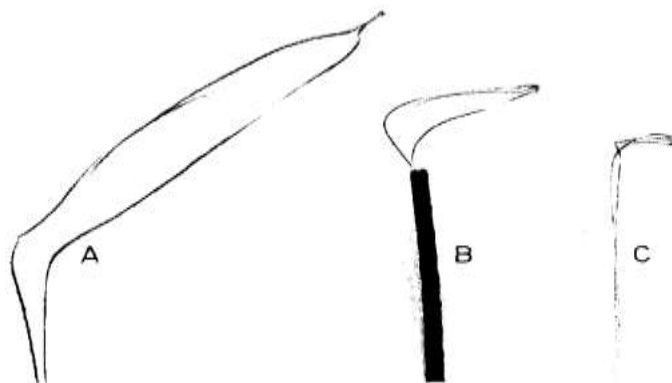


Figure 6:-Note that the loops vary in size and angle. Loop A was used for adult patients, while loops B and C were used for children (*<https://doi.org/10.1055/s-0029-1231337>*).

It was thus concluded that rapid, percutaneous, and non-surgical removal of intravascular fragments should be attempted in all cases before resorting to major surgical intervention (18).

Conclusion:-

This case highlights the rare but serious complication of guidewire shearing and migration into the pulmonary artery. Although rare, such events warrant meticulous inspection of the guidewire upon removal and post-procedure imaging to rule out retained foreign bodies. Prompt consultation with interventional radiologists or vascular surgeons is recommended for cases where the fragment's location is proximal and retrievable.

References:-

1. Erben, J.; Kvasnicka, J.; Bastecky, J.: Vortel, V.: Experience with routine use of subclavian vein cannulation in hemodialysis. *Proc. Eur. Dial. Transplant. Ass.* 6:59-64 (1969)
2. Uldall, P.R.; Dijck, R.F.: Woods, F.; Merchant, N.: Martin, G.S.; Cardella, C.J.: Sutton, D.; De Verber, G.A.: A subclavian cannula for temporary vascular access for hemodialysis or plasmapheresis. *Dial. Transplant.* 8:963-968 (1979).
3. Hoen B, Kessler M, Hestin D, Mayeux D: Risk factors for bacterial infections in chronic haemodialysis adult patients: A multicentre prospective survey. *Nephrol Dial Transplant* 1995;10:377-381
4. Blot F, Schmidt E, Nitenberg G, Tancrede C, Leclercq B, et al. Earlier positivity of central-venous versus peripheral-blood cultures is highly predictive of catheter-related sepsis. *J Clin Microbiol.* 1998;36(1):10.
5. Dittmer ID, Sharp D, McNulty CA, Williams AJ, Banks RA: A prospective study of central venous hemodialysis catheter colonization and peripheral bacteremia. *Clin Nephrol* 1999;51: 34-39
6. Tunneled catheter-related bacteremia in hemodialysis patients: incidence, risk factors and outcomes. A 14-year observational study Marina Almenara-Tejedera¹, María A Rodríguez-Pérez², María J Moyano-Franco², Marina de Cueto-López³, Jesús Rodríguez-Baño^{#345}, Mercedes Salgueira-Lazo^{#246}
7. Catheter-Related Bloodstream Infections and Catheter Colonization among Haemodialysis Patients: Prevalence, Risk Factors, and Outcomes Shamira Shahar¹, Ruslinda Mustafar¹, Lydia Kamaruzaman¹, Petrick Periyasamy¹, Kiew Bing Pau², Ramliza Ramli³

8. Vanegas JM, Salazar-Ospina L, Roncancio GE, Jimenez JN. Staphylococcus aureus colonization increases the risk of bacteremia in hemodialysis patients: a molecular epidemiology approach with time-dependent analysis. *Am J Infect Control*. 2021;49(2):215–222. doi: 10.1016/j.ajic.2020.05.031. [PubMed] [CrossRef] [Google Scholar].
9. Risk Factor Analysis for Long-Term Tunneled Dialysis Catheter-Related Bacteremias G. Jean B. Charra C. Chazot T. Vanel J.C. Terrat J.M. Hurot G. Laurent Centre du Rein Artificiel de Tassin, Tassin la Demi-Lune, France
10. Tunneled catheter-related bacteremia in hemodialysis patients: incidence, risk factors and outcomes. A 14-year observational study Marina Almenara-Tejederas ^{1,✉}, María A Rodríguez-Pérez ¹, María J Moyano-Franco ¹, Marina de Cueto-López ², Jesús Rodríguez-Baño ^{2,3,4,#}, Mercedes Salgueira-Lazo ^{1,3,5,#}
11. Décompression costo-claviculaire veineuse chez les patients avec accès artério-veineux pour hémodialyse menacé, 2010. panel Carolyn Glass, Michelle Dugan, David Gillespie, Adam Doyle, Karl Illig
12. Intravascular migration of fragments of central venous catheters. 3 cases*, O. Marie, G. Leverger, M.C. Douard, et al.).
13. Dondelinger RF, Rossi P, Kurdziez JL, et al: *Interventional Radiology*. New York, Thieme Medical Publishers, 1990, pp 717-728*
14. Fisher and Ferreo Evaluation of current techniques for nonsurgical removal of intravascular iatrogenic foreign bodies. *AJR* 1979; 130:541, <https://doi.org/10.2214/ajr.130.3.541>*)
15. *Bloomfield DA: Techniques for nonsurgical retrieval of iatrogenic foreign bodies from the heart. *Am J Cardiol* 1971; 27:538*).
16. Cheng CC, Tsai TN, Yang CC, Han CL. Percutaneous retrieval of dislodged totally implantable central venous access system in 92 cases: experience in a single hospital. *Eur J Radiol*. 2009;69:346–350. doi: 10.1016/j.ejrad.2007.09.034. [DOI] [PubMed] [Google Scholar]
17. Wang PC, Liang HL, Wu TH, Huang JS, Lin YH, Huang YL. Percutaneous retrieval of dislodged central venous port catheter: experience of 25 patients in a single institute. *Acta Radiol*. 2009;50:15–20. doi: 10.1080/02841850802524493. [DOI] [PubMed] [Google Scholar].
18. Nonsurgical removal of intravascular foreign bodies C Zollkofer, P H Nath, W R Castaneda-Zuniga, P Probst, A Barreto, S M Tadavathy, K Amplatz.