



### RESEARCH ARTICLE

## TREATMENT OF A SINGLE TOOTH WITH MILLERS CLASS I GINGIVAL RECESSION DEFECT BY CORONALLY ADVANCED FLAP (CAF) IN CONJUNCTION WITH CONNECTIVE TISSUE GRAFT (CTG)- A CASE REPORT

Sabyasachi Bhowal<sup>1</sup>, Argha Rudra<sup>2</sup>, Prakhar Bhardwaj<sup>1</sup>, Preeti Sodhani<sup>1</sup> and Hanaa A P<sup>1</sup>

1. PGT, Dept of Periodontics, Dr. R. Ahmed Dental College and Hospital, Kolkata.
2. Professor & Head of the Department, Dept of Periodontics, Dr. R. Ahmed Dental College and Hospital, Kolkata.

### Manuscript Info

#### Manuscript History

Received: 16 April 2025

Final Accepted: 19 May 2025

Published: June 2025

#### Key words:-

Connective Tissue Graft(s), Gingival Recession, Periodontal Plastic Surgery, Root Coverage

### Abstract

Due to cosmetic concerns or sensitivity of root, treating buccal gingival recession is often necessary. Complete coverage of the recession defect with a pleasant colour and tissue integration between the treated area and neighbouring tissue should be the ultimate goal of root coverage techniques, thereby attaining success in terms of both biology and appearance. Patient with recession in upper left canine tooth had undergone recession coverage surgery by Coronally Advanced Flap (CAF) with Connective Tissue Graft (CTG) harvested from palate. The patient was reviewed for a period of 8 months. The recession coverage was complete and aesthetically pleasing. A diverse array of surgical procedures have been presented over the decades for the treatment of gingival recessions. The adjunctive use of CTG under CAF enhanced the likelihood of attaining complete root coverage in Miller Class I recession situation.

"© 2025 by the Author(s). Published by IJAR under CC BY 4.0. Unrestricted use allowed with credit to the author."

### Introduction :-

Gingival recession or soft tissue recession is defined as the displacement of the gingival margin apical to the cemento-enamel junction (CEJ) of a tooth.(1) Untreated gingival recession tends to exhibit progressive apical displacement over time.(2)(3) Gingival recession, which exposes the root surface, is commonly associated with dentin hypersensitivity, root caries, non-carious cervical lesions (NCCLs), compromised plaque control and unaesthetic appearance.(4)The ultimate goal of a root coverage procedure is the complete coverage of the recession defect with good appearance related to adjacent soft tissues and minimal probing depth (PD) (5)

The aetiology of gingival recession are multifactorial and complex, with its exact mechanism not fully understood yet. It intertwines predisposing anatomic risk factors-such as bone dehiscence, gingival width and thickness insufficiency, tooth malposition, aberrant attachment of the labial frenulum with precipitating factors such as inflammation related to plaque, improper tooth brushing habit, smoking, chronic trauma because of traumatic incisor relationship and iatrogenic factors related to improper restorative, prosthetic, orthodontic and periodontal procedures.

One popular method for root coverage is the coronally advanced flap (CAF) surgical procedure. The coronal displacement of the soft tissues on the exposed root surface serves as the basis for this process. This approach may be used alone or in combination with subepithelial connective tissue graft (6), barrier membrane (BM) (7), enamel matrix derivative (EMD) (Rasperini et al. 2000), acellular dermal matrix (ADM) (8), platelet-rich plasma (PRP) (Marx et al. 1998) and living tissue-engineered human fibroblast derived dermal substitute (HF-DDS) (9).

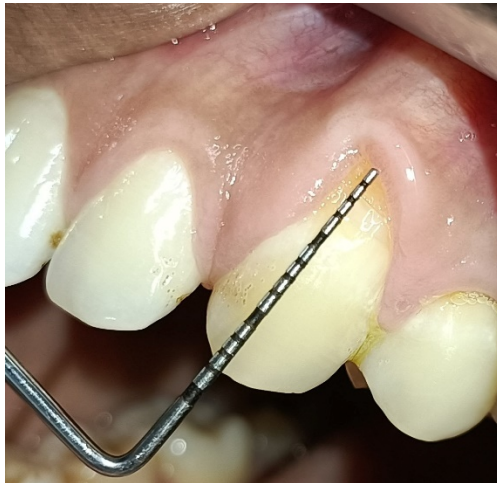When choosing a treatment plan, physicians should take patient and tooth-related aspects into account.

The purpose of this case report is to present successful management of a single tooth with Miller's Class I gingival recession by CAF with CTG.

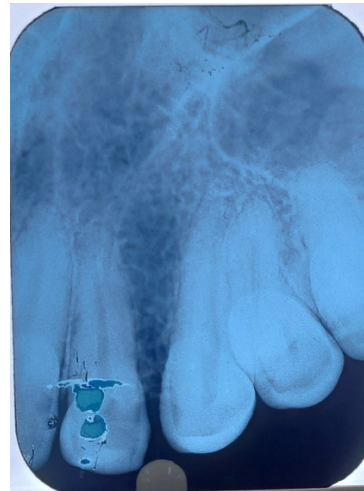
### Case Report

A 27 years old male came to the outdoor of Department of Periodontics, Dr. R. Ahmed Dental college and Hospital, Kolkata with chief complain of gingival displacement away from the tooth margin of upper left canine (#23) along with sensitivity on taking cold. He also complained about unaesthetic look due to mismatch of gingival position with adjacent tooth.

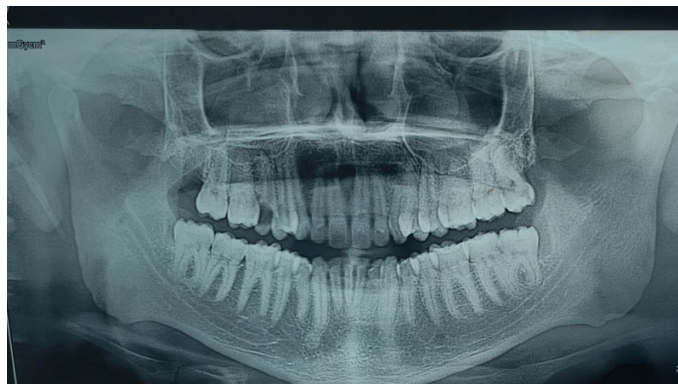On intra oral examination it was seen as Miller's class I gingival recession of 3 mm on tooth #23. Clinical attachment loss (CAL) was 4 mm. Probing pocket depth (PPD) was found to be 1 mm. The gingival biotype was thin, with keratinized tissue width of 2 mm.



**Figure 1:-** Pre Operative View



**Figure 2(a):-**Pre operative IOPAR.



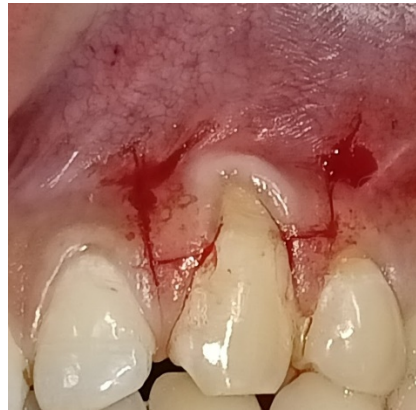**Figure 2(b):-** Pre operative OPG.

### Treatment plan:

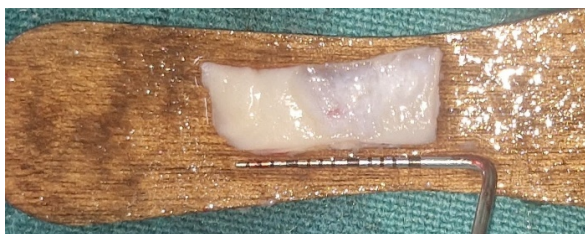Root coverage utilizing a coronally advanced flap (CAF) alongside a connective tissue graft (CTG) harvested from the palate.

The patient was clinically healthy. Informed consent was obtained before the procedure, detailing the advantages, disadvantages, and any difficulties connected with the treatment.

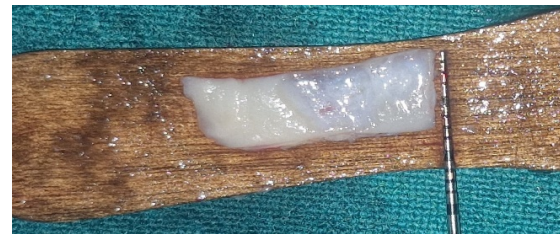The surgical method for addressing gingival recession involved a trapezoidal-type flap (Figure 3), which completely enveloped a connective tissue graft (CTG) derived from the de-epithelialization of a free gingival graft (FGG) (Figure 4)



**Figure 3 :-** Primary incision.



(a)



(b)

**Figure 4 :-** FGG harvested from palate and de epithelialization done.

A trapezoidal flap of varied thickness (split–full–split) was prepared at the recipient site using a #15C blade under local anaesthesia. Both the horizontal incisions were 3 mm long made at a distance from anatomical papilla tip equals to recession depth plus 1 mm and two slightly diverging vertical releasing incisions extended as far as the alveolar mucosa.

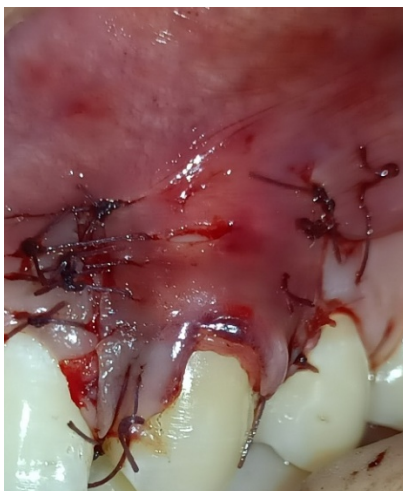The anatomical papilla was de-epithelialized using #15 C blade and microsurgical scissors.

Using a mini five Gracey curette, the exposed root surface was mechanically debrided. Then irrigation was done with normal saline.

The fully de-epithelialized connective tissue graft was 6 mm wider mesio distally than the recession's width at the prosthetic collar and 1 mm more in height than the depth of root exposure. Two interrupted suture with 5-0 resorbable suture (Vicryl®) was placed at the base of the papillae attaching the grafted tissue to the facial keratinized tissue of the neighbouring teeth secure the graft 1 mm coronally to the prosthetic collar.

For the full coverage of the connective tissue graft, the flap was advanced coronally. Beginning at the most apical extension of the mesial releasing incision, a series of simple interrupted sutures using 5-0 resorbable suture (Vicryl®) were applied along the releasing incision, progressing in an apico-coronal direction. Same procedure was followed to close distal releasing incision. To snugly fit the coronal flap border over the prosthetic crown convexity, the final sling suture had compressed the surgical papillae against the corresponding de-epithelialized anatomical papillae. (Figure 5)



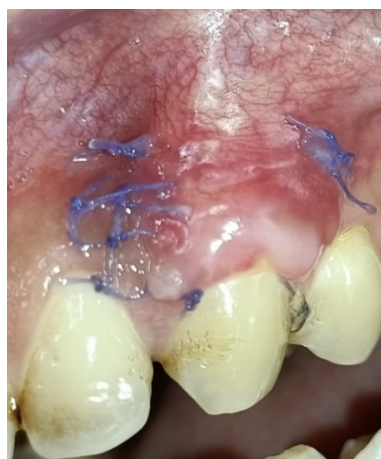

**Figure 5 :-** Immediate post surgical situation.

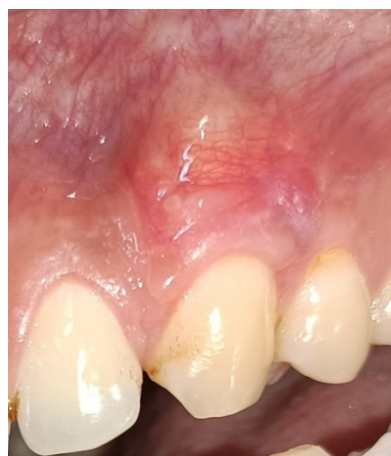Following Surgery,

- 1.For 5 days, analgesics and antibiotics were prescribed.
- 2.For 2 weeks, a mouthwash containing 0.2% chlorhexidine was adviced to use twice a day.
3. After 14 days, the sutures were removed.

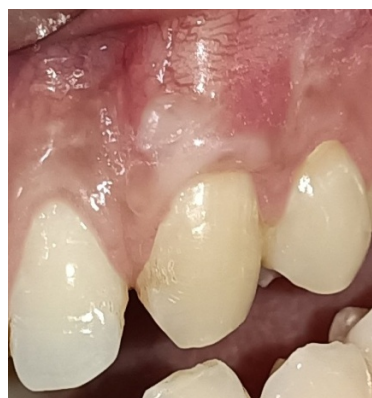Patient was followed up after 14 days (figure 6),1 month (figure 7),4 months (figure 8) and 8 months (figure 9)



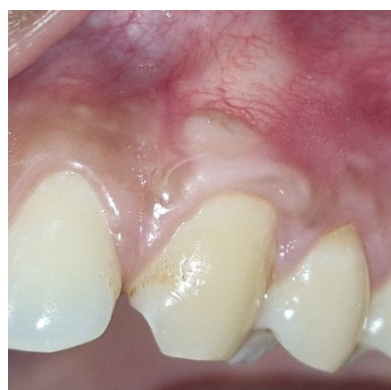**Figure 6 :-** 14 days follow up.



**Figure 7 :-** 1 month follow up.



**Figure 8 :-** 4 month follow up.



**Figure 9 :-** 8 month follow up.

On 8 month follow up, pocket depth was found of 2 mm and a CAL gain of 4 mm. Complete root coverage was achieved. The keratinized tissue width increased from 2 mm to 3 mm. The patient showed good colour match, dense, healthy tissue and full root coverage. The patient was pleased with the recession coverage surgery's overall outcome and appearance.

	RECESSION DEPTH	PROBING POCKET DEPTH	CAL	KERATINIZED TISSUE WIDTH
BEFORE TREATMENT	3	1	4	2
AFTER TREATMENT (ON 8 MONTH FOLLOW UP)	0	2	0	3

(all dimensions are in millimeter)

### Discussion :-

Gingival recession is a prevalent clinical disease marked by the apical displacement of the gingival margin, potentially resulting in aesthetic issues, dentin hypersensitivity, and an elevated risk of root caries (10). Miller's Class I recession defects, with no loss of interdental bone or soft tissue have complete root coverage potential, present an ideal scenario for surgical root coverage procedure (11).

The main goal of treatment for gingival recession is complete root coverage. Furthermore, clinicians anticipate improvements in the tissue's natural look, keratinized tissue width (KTW), clinical attachment level (CAL) and long-term stability of the result.

The treatment of isolated gingival recession has become more predictable with the development of mucogingival surgical techniques that aim for long-term aesthetic and functional stability in addition to root covering. CAF alone is beneficial for correcting Miller's Class I and II deficiencies; however, its combination with CTG specially where the gingival thickness is  $\leq 0.8\text{mm}$ . yields enhanced results regarding root coverage, augmentation of keratinized tissue width and long-term stability due to thick tissue biotype produced by CTG.(12) The connective tissue graft acts as a biologic matrix that promotes revascularization and supports the overlying flap, leading to improved tissue thickness and better aesthetic integration.(6) Recent research has also highlighted the importance of soft tissue phenotypic alteration, which can be achieved due to addition of CTG.

In this instance, whole root coverage was attained, and the patient indicated an enhancement in aesthetic satisfaction and a decrease in dentin hypersensitivity. Similar findings have been reported by Harris (1997) (8), who observed higher mean root coverage and increased thickness of keratinized tissue when CAF was combined with CTG, compared to CAF alone.

Furthermore, the selection of connective tissue graft (CTG) obtained from the palate is considered the gold standard (13) owing to its enhanced integration and reduced likelihood of graft necrosis (14). The donor site healing was uneventful in the case, and patient discomfort was minimal, highlighting the importance of meticulous surgical technique and post-operative care.

Long-term studies have demonstrated that the combination of CAF and CTG not only provides root coverage but also maintains stability over time (15). Our case adds to this body of evidence, supporting the predictability and effectiveness of this approach for treating single tooth Miller's Class I defects.

### Conclusion :-

This case shows that a coronally advanced flap and connective tissue graft can successfully cover roots. The best clinical and aesthetic results might result from a meticulous case selection process that follows biologic principles. This case study highlights the need of personalized treatment planning and the choice of approaches that enhance both practical and aesthetic results.

**Source of Funding**

None.

**Conflict of Interest**

None.

**References:-**

1. Mucogingival Deformities - Prato - 1999 - Annals of Periodontology - Wiley Online Library.
2. Periodontal Conditions of Sites Treated with Gingival-Augmentation Surgery Compared to Untreated Contralateral Homologous Sites: A 10- to 27-Year Long-Term Study - Agudio - 2009 - Journal of Periodontology - Wiley Online Library.
3. Long-Term Outcomes of Untreated Buccal Gingival Recessions: A Systematic Review and Meta-Analysis - Chambrone - 2016 - Journal of Periodontology - Wiley Online Library.
4. The Evolution of Buccal Gingival Recessions in a Student Population: A 5-Year Follow-Up - Dapri - 2007 - Journal of Periodontology - Wiley Online Library.
5. Periodontal plastic surgery for treatment of localized gingival recessions: a systematic review - Roccuzzo - 2002 - Journal of Clinical Periodontology - Wiley Online Library .
6. Subepithelial Connective Tissue Graft Technique for Root Coverage - Langer - 1985 - Journal of Periodontology - Wiley Online Library.
7. Guided Tissue Regeneration Versus Mucogingival Surgery in the Treatment of Human Buccal Gingival Recession - Prato - 1992 - Journal of Periodontology - Wiley Online Library.
8. A Short-Term and Long-Term Comparison of Root Coverage With an Acellular Dermal Matrix and a Subepithelial Graft - Harris - 2004 - Journal of Periodontology - Wiley Online Library .
9. Evaluation of the Safety and Efficacy of Periodontal Applications of a Living Tissue-Engineered Human Fibroblast- Derived Dermal Substitute. II. Comparison to the Subepithelial Connective Tissue Graft: A Randomized Controlled Feasibility Study - Wilson - 2005 - Journal of Periodontology - Wiley Online Library
10. Löe H, Anerud A, Boysen H, Morrison E. Natural history of periodontal disease in man. Journal of Clinical Periodontology. 1986;13(5):431–40.
11. Miller J. A Classification of Marginal Tissue Recession. | EBSCOhost.
12. Treatment of gingival recession with coronally advanced flap procedures: a systematic review - Cairo - 2008 - Journal of Clinical Periodontology - Wiley Online Library
13. Chambrone L., et al. “Root coverage procedures for treating single and multiple recession-type defects: An updated Cochrane systematic review”. Journal of Periodontology 90.12 (2019): 1399–1422.
14. Clinical Evaluation of a Modified Coronally Advanced Flap Alone or in Combination with a Platelet-Rich Fibrin Membrane for the Treatment of Adjacent Multiple Gingival Recessions: A 6-Month Study - Aroca - 2009 - Journal of Periodontology - Wiley Online Library
15. Periodontal plastic surgery - Zucchelli - 2015 - Periodontology 2000 - Wiley Online Library.