



RESEARCH ARTICLE

OBSTRUCTIVE LARYNGEAL DYSPNEA REVEALING A LARGE SUPRAGLOTTIC FIBROLIPOMA: A CASE REPORT

S. Idoubba, B. Hemmaoui, J. Oubenjah, A. Da Costa, M. Moujoud, F. Benariba and N. Errami

Manuscript Info

Manuscript History

Received: 01 May 2025

Final Accepted: 04 June 2025

Published: July 2025

Key words:-

Laryngeal Fibrolipoma, Supraglottic Mass, Airway Obstruction, Suspension Microlaryngoscopy, Benign Laryngeal Tumors, Case Report

Abstract

Background: Laryngeal fibrolipomas are exceptionally rare benign tumors composed of mature adipose and fibrous tissue. Their insidious growth and nonspecific symptoms can lead to delayed diagnosis and potential airway compromise.

Case Presentation: We report the case of a 56-year-old male with a history of chronic smoking who presented with progressive dysphonia, dysphagia, and inspiratory dyspnea over nine months. Nasofibroscope revealed a supraglottic mass obstructing the airway. CT imaging demonstrated a well-circumscribed, fat-density lesion suggestive of a fibrolipoma. Due to the risk of airway obstruction, a tracheotomy was performed prior to endoscopic excision via suspension microlaryngoscopy. A large pedunculated mass originating from the left aryepiglottic fold was completely resected. Histopathology confirmed the diagnosis of fibrolipoma. Postoperative recovery was uneventful, with complete symptom resolution and normal laryngeal healing at one-month follow-up.

Conclusion: Although rare, fibrolipoma should be considered in the differential diagnosis of supraglottic masses. Accurate diagnosis relies on combined clinical, radiologic, and histologic evaluation. Surgical excision remains the definitive treatment, and early recognition is essential to prevent life-threatening airway obstruction.

"© 2025 by the Author(s). Published by IJAR under CC BY 4.0. Unrestricted use allowed with credit to the author."

Introduction:-

Laryngeal fibrolipoma is an uncommon benign tumor of the larynx, histologically composed of mature adipose tissue interspersed with fibrous connective elements. It is classified as a rare mesenchymal tumor and accounts for approximately 0.6% of all benign laryngeal lesions. These tumors most frequently occur in males during their sixth decade of life.[1]

The clinical diagnosis of laryngeal fibrolipoma can be particularly challenging due to its often nonspecific or absent symptomatology. Patients may present with a range of manifestations, including exertional dyspnea, paroxysmal coughing, dysphagia, or features of obstructive sleep apnea. In certain cases, progressive tumor growth may lead to partial or complete upper airway obstruction, necessitating prompt evaluation and management.[2]

This case report aims to present the clinical course of a rare laryngeal fibrolipoma, with emphasis on the diagnostic process and a review of current strategies for both medical and surgical intervention.

Case Report :

We report the case of a 56-year-old male patient, a chronic smoker with a 20 pack-year history, referred for the management of a laryngeal fibrolipoma.

The patient reported a nine-month history of symptoms, initially presenting with dysphonia. Over time, progressive dysphagia and inspiratory dyspnea developed, prompting a nasofibrosopic examination. This revealed a supraglottic, exophytic mass arising from the larynx.

A cervical CT scan demonstrated a hypodense, fat-density lesion consistent with a supraglottic lipoma, measuring up to 4.77 cm in maximum diameter.

The patient underwent a tracheotomy under local anesthesia due to the obstructive nature of the mass, which contraindicated orotracheal intubation, followed by a suspension microlaryngoscopy under general anesthesia. Intraoperative examination revealed a large, pinkish, pear-shaped tumor attached by a pedicle to the left aryepiglottic fold. The vocal cords were visualized by gently retracting the mass to the left, and no involvement of the vocal folds was noted. Complete resection of the lesion was achieved via blunt dissection using standard laryngeal instruments. The excised specimen was sent for histopathological analysis.

Postoperative management included a six-day course of systemic corticosteroids and antibiotics. The patient's clinical condition improved progressively, and the tracheotomy site was closed on postoperative day 10 following endoscopic reassessment.

At the one-month follow-up visit, the patient reported complete resolution of symptoms and restoration of a normal voice. Follow-up pharyngolaryngoscopy confirmed excellent mucosal healing and a normal postoperative appearance.

Discussion:-

Laryngeal fibrolipomas are rare benign tumors, representing a histological variant of lipomas that contain both mature adipose tissue and fibrous connective tissue. Lipomas represent approximately 0.6% of all benign laryngeal tumors, with the supraglottic region, especially the aryepiglottic fold. They are the most commonly involved site due to its relative richness in adipose tissue.[1] These tumors are more frequently observed in middle-aged men and tend to grow slowly, often remaining asymptomatic until they reach a size that causes functional impairment.

Although lipomas are uncommon in the head and neck region, they can develop in a variety of anatomical sub-sites, including the tonsils, tongue, parotid gland, palate, and larynx.

Laryngeal lipomas are categorized into two main types: extrinsic and intrinsic.

Extrinsic lipomas typically involve the posterior aspect of the larynx, the piriform sinus, and the lingual surface of the epiglottis, while intrinsic lipomas are most often located in the false vocal cords, the laryngeal surface of the epiglottis, the aryepiglottic folds, and the subglottic larynx.[2]

The clinical presentation of laryngeal fibrolipoma is often nonspecific and may overlap with more common laryngeal pathologies and lead to diagnosis delays. Symptoms can include dysphonia, progressive dysphagia, inspiratory stridor, and signs of upper airway obstruction such as exertional dyspnea or sleep apnea. In some cases, sudden respiratory distress may occur, where the mass intermittently occludes the glottic inlet.

Imaging studies, particularly CT scan and MRI, are critical for preoperative evaluation. On CT, lipomas typically appear as well-circumscribed, hypodense lesions with fat attenuation. MRI offers superior soft-tissue resolution and can help differentiate lipomas from liposarcomas based on signal characteristics and the presence of internal septations or nodularity.

Histopathological examination remains the gold standard for definitive diagnosis. Fibrolipomas are characterized by lobulated masses of mature adipocytes interspersed with fibrous septa, lacking cellular atypia, mitotic activity, or

necrosis, these features help distinguish them from liposarcomas[3]. In infiltrative forms, malignant transformation remains a potential concern.

Given the rarity of fibrolipomas in the supraglottic larynx, establishing a correct diagnosis requires careful distinction from a range of benign and malignant lesions that may present with similar clinical and endoscopic findings.

The most relevant differential diagnoses, in addition to liposarcomas, include laryngocele, which is one of the most common benign mimics. It represents an air-filled dilation of the laryngeal saccule, often presenting as a cystic neck mass or intralaryngeal swelling. On CT imaging, it appears as an air- or fluid-filled lesion without solid components, in contrast to the fat-density seen in fibrolipomas.[4]

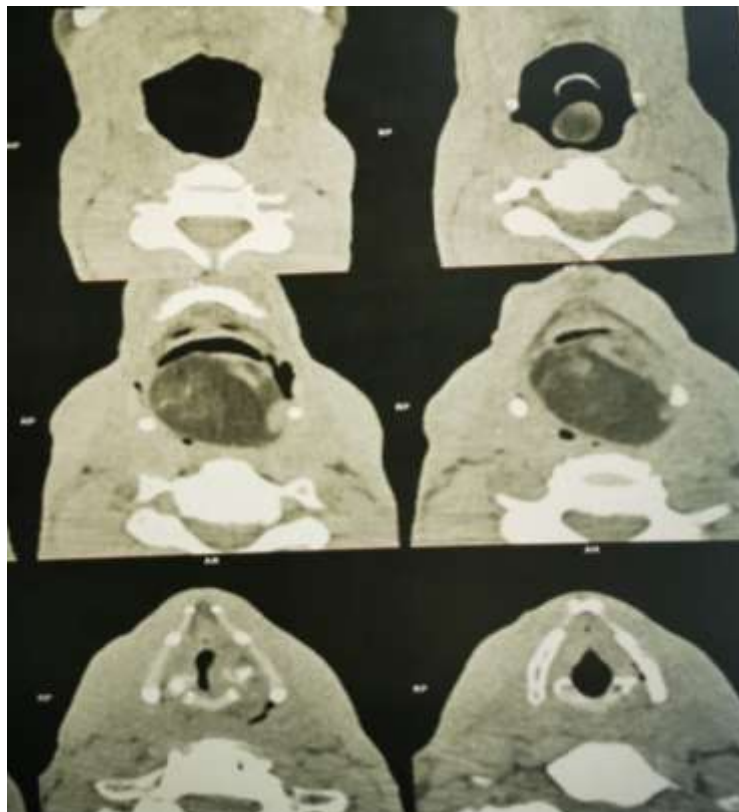
Another important consideration is hemangioma, a benign vascular tumor that enhances with contrast and may appear bluish on endoscopy. It is composed histologically of proliferating blood vessels, distinguishing it clearly from fibroadipose tissue.

Chondromas are also part of the differential diagnosis. These cartilaginous tumors are typically firm and may show calcifications on imaging. [3][5]

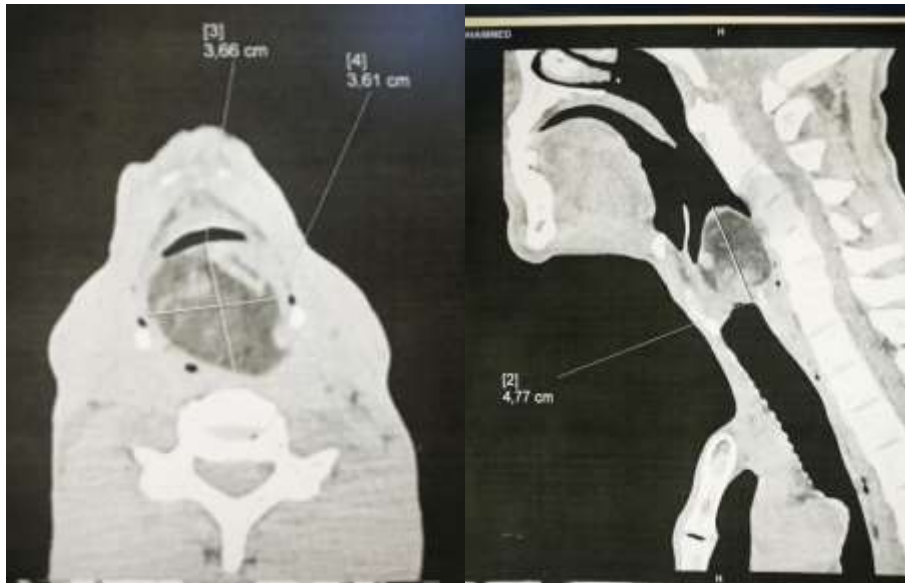
Finally, neurogenic tumors, including schwannomas and neurofibromas, although uncommon, can also occur in the supraglottic region and should be taken into account during diagnostic evaluation.[5]

Complete surgical excision is the treatment of choice, with the approach tailored to tumor size, location, and airway status. Endoscopic resection via suspension microlaryngoscopy is feasible for most lesions, offering excellent visualization and preservation of surrounding structures. In cases of large or obstructive tumors, a preliminary tracheotomy may be required to secure the airway, as in the present case. Or an external surgical approach is preferred for tumors exceeding 2cm diameter.[6]

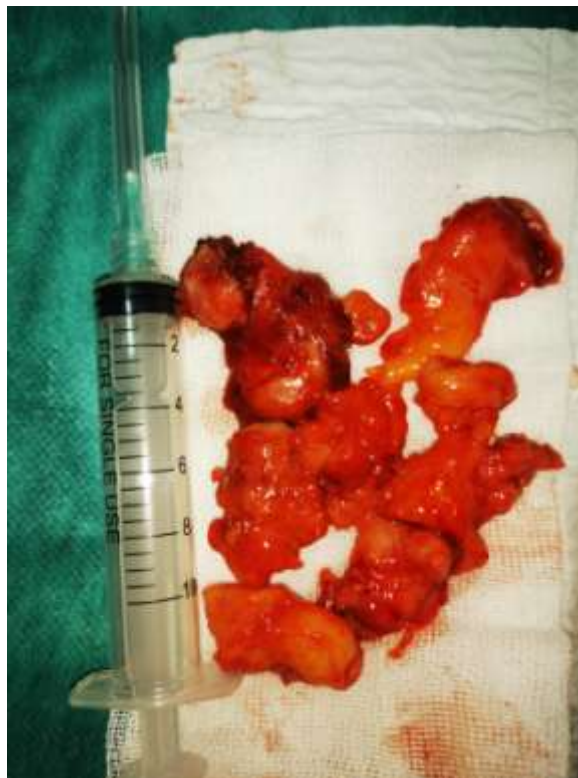Postoperative outcomes are typically excellent, as observed in our case, with low recurrence rates and restoration of normal voice and swallowing function. However, regular follow-up is advisable to monitor for recurrence or delayed complications such as scarring or granuloma formation.[7]



Axial views showing the supraglottic laryngeal mass without evidence of cartilaginous erosion.



Axial (left) and sagittal (right) CT scan of the neck showing a supraglottic fibrolipoma measuring $4.77 \times 3.66 \times 3.61$ cm.



Resected fibrolipoma.

Conclusion:-

The evaluation of a supraglottic mass should include fibrolipoma in the differential diagnosis, especially when imaging demonstrates a well-defined, homogeneous, fat-density lesion. Accurate diagnosis relies on a multidisciplinary approach combining clinical examination, endoscopic visualization, cross-sectional imaging, and confirmatory histopathological analysis. Distinguishing fibrolipoma from other entities such as laryngoceles, liposarcomas, or vascular and neurogenic tumors is essential for determining the appropriate surgical and therapeutic strategy.

References:-

1. **Azar SS, Buen F, Chia JJ, Ma Y, Caron J, Dry S, Bhuta S, Abemayor E.** Spindle Cell Lipoma Arising from the Supraglottis: A Case Report and Review of the Literature. *Head Neck Pathol.* 2021;15(4):1299–1302.
2. **J.-R. Lechien, S. Hans, M. Remacle.** Tumeurs bénignes du larynx .
3. **Kumar S, Ghosh A, Suri V, et al.** Large Laryngeal Lipoma with Extra Laryngeal Component Mimics Mixed Form Laryngocele: A Case Report. *Ear Nose Throat J.* 2019;98(7):E20–E23.
4. **López-González MA, Rodríguez-Campo FJ, González-Moles MA, et al.** Laryngeal Fibrolipoma: A Case Report. *Acta Otorrinolaringol Esp.* 2010;61(4):292–294.
5. **Kumar S, Ghosh A, Suri V, et al.** Dyspnea and Dysphagia Associated with Hypopharyngeal Fibrolipoma: A Case Report. *Case Rep Otolaryngol.* 2017;2017:1–4.
6. **Santos-Silva AR, Oliveira-Neto HH, Lima Júnior LC, et al.** An Atypical Lipomatous Tumor of the Hypopharynx, a Unique Entity? A Rare Case Report. *Case Rep Otolaryngol.* 2021.
7. **Joyson Kodiyan, B.S, Jason R. Rudman, M.D., David E. Rosow, M.D., Giovana R. Thomas, M.D.** Lipoma and liposarcoma of the larynx: case reports and literature review.