

 <p>ISSN NO. 2320-5407</p>	<p>Journal Homepage: - <a href="http://www.journalijar.com">www.journalijar.com</a></p> <p><b>INTERNATIONAL JOURNAL OF ADVANCED RESEARCH (IJAR)</b></p> <p>Article DOI: 10.21474/IJAR01/21297 DOI URL: <a href="http://dx.doi.org/10.21474/IJAR01/21297">http://dx.doi.org/10.21474/IJAR01/21297</a></p>	 <p>INTERNATIONAL JOURNAL OF ADVANCED RESEARCH (IJAR) ISSN 2320-5407</p> <p>Journal Homepage: <a href="http://www.journalijar.com">http://www.journalijar.com</a> Journal DOI: 10.21474/IJAR01</p>
---	--	---

### RESEARCH ARTICLE

## MYCOPHENOLATE MOFETIL INDUCED GINGIVAL ENLARGEMENT IN A PATIENT WITH LUPUS ENTERITIS AND NEPHRITIS: A RARE CASE REPORT

Hanaa A P<sup>1</sup>, Argha Rudra<sup>2</sup>, Ha U Niwan Laloo<sup>1</sup>, Sabyasachi Bhowal<sup>1</sup>

1. PGT, Department of Periodontics, Dr. R. Ahmed Dental College and Hospital
2. Professor, Department of Periodontics, Dr. R. Ahmed Dental College and Hospital

### Manuscript Info

#### Manuscript History

Received: 06 May 2025  
Final Accepted: 09 June 2025  
Published: July 2025

#### Key words:-

Gingival Enlargement, Gingivectomy,  
Immunosuppressant.

### Abstract

Mycophenolate mofetil (MMF), an immunosuppressant commonly used to prevent organ rejection and treat autoimmune diseases, has been associated with various side effects. Here, we present a rare case of MMF-induced gingival enlargement in a 36-year-old female patient diagnosed with lupus enteritis and nephritis. The patient, who was on MMF therapy, presented with complaints of swollen and bleeding gums. Clinical examination revealed significant gingival enlargement. The patient underwent nonsurgical treatment followed by gingivectomy and gingivoplasty. The MMF therapy was eventually discontinued by the patient's physician. At the one-year follow-up, the patient showed successful treatment outcomes with no recurrence of gingival enlargement. This case highlights the importance of monitoring oral health in patients on immunosuppressive therapy and the need for interdisciplinary collaboration between dental and medical professionals in managing such cases.

"© 2025 by the Author(s). Published by IJAR under CC BY 4.0. Unrestricted use allowed with credit to the author."

### Introduction:-

An excessive growth of the gingival tissues brought on by the side effects of several systemic drugs is known as drug-induced gingival enlargement. Calcium channel blockers, particularly nifedipine and amlodipine, immunosuppressants like cyclosporine, and anticonvulsants like phenytoin are the medication types most commonly linked (1). These medications cause excessive extracellular matrix deposition and tissue proliferation by changing the metabolism of gingival fibroblasts, which results in gingival hypertrophy. Usually manifesting as firm, fibrotic gingival tissue that may cover the teeth, this condition may lead to both aesthetic as well as functional problems, such as maintenance of oral hygiene and a higher risk of periodontal infections. Its evolution is greatly influenced by contributing factors such as genetic predisposition and oral hygiene status, even though the severity differs depending on individual susceptibility and medicine dosage. (2)

**Corresponding Author:- Hanaa A.P**

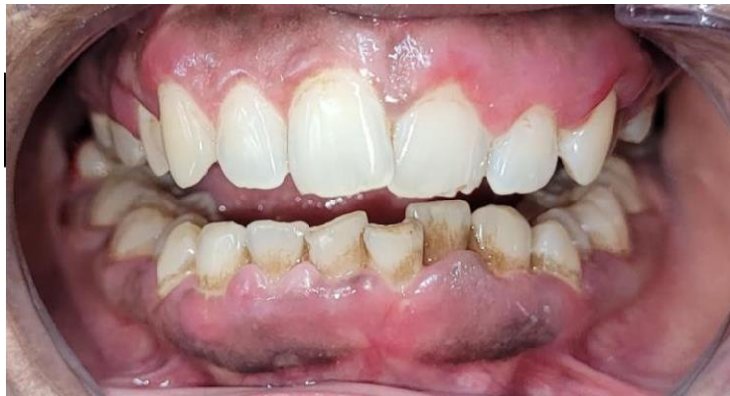**Address :** PGT, Department of Periodontics, Dr.R. Ahmed Dental College and Hospital.

Compared to other immunosuppressants like cyclosporine, mycophenolate mofetil (MMF), an immunosuppressant, is usually thought to have a preventive effect against gingival enlargement, while it is occasionally linked to the condition. (3) To add information to the literature and for better understanding the oral side effects of this medicine, we report a case of MMF-induced gingival enlargement in a patient with lupus enteritis.

### Case Report:-

A 36 year old female patient reported to the department of periodontics, Dr. R. Ahmed Dental College and Hospital, with complaints of swollen and bleeding gums since 2 years. Past medical history of patient revealed that, she was diagnosed with Lupus Enteritis along with Nephritis and Hypothyroidism 6 years ago. Since then she was taking immunosuppressant medications including Mycophenolate Mofetil (MMF) 520mg thrice daily which reduced to 360mg 2 months before the visit. She has completed 6 doses of cyclophosphamide 1g injection with an interval of 4 weeks. She was also taking Hydroxychloroquine 400mg since then which later is reduced to 200mg. Apart from these she is taking levothyroxine 100mg for management of hypothyroidism.

Upon intra oral examination, gingival enlargement noted in the lower anterior labial side with a probing pocket depth of 6mm with attached gingiva width of 9mm.( figure 1) surface of gingiva appeared smooth and erythematous with loss of stippling. Poor oral hygiene status was assessed with presence of local irritating factors surrounding the teeth.

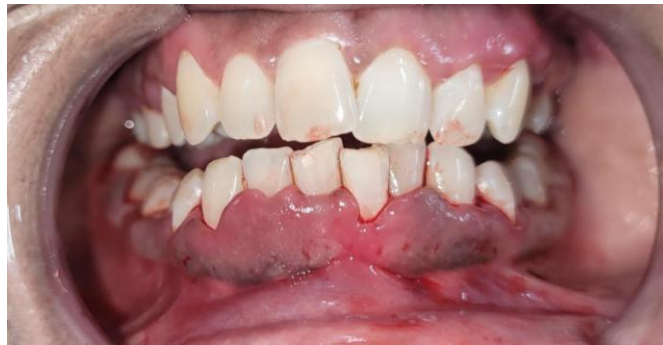

**Figure 1:-** Intra oral picture depicting enlargement and inflammation in the lower anterior region.

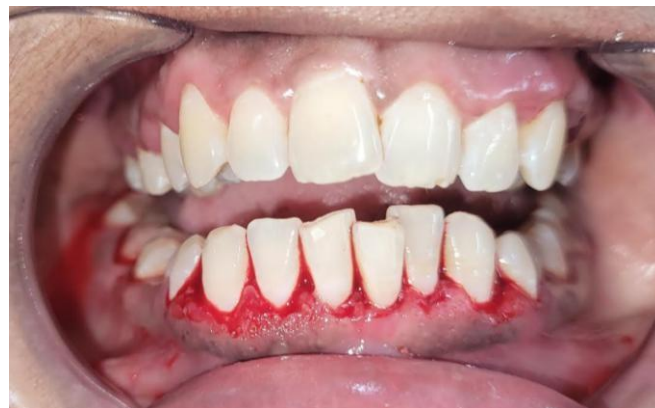Based on drug history and clinical examination of the patient, a provisional diagnosis of combined gingival enlargement was made. Complete hemogram of the patient was done, but all the parameters were within the normal range. Orthopantomogram was taken which revealed no significant bone destruction.

The treatment of the patient was started with nonsurgical approach. She was also instructed to maintain oral hygiene using Chlorhexidine mouth rinse. The patient's physician was consulted for opinion regarding the feasibility of surgical correction. Consequently gingivectomy procedure was planned.

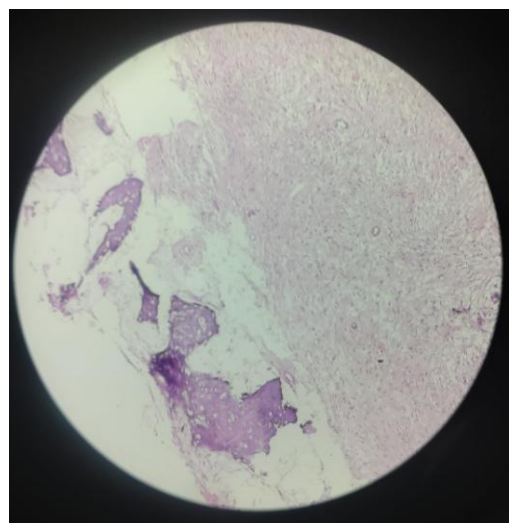
Under local anesthesia, bleeding points were marked with a pocket marker (Figure 2) and excess gingival tissue is removed using scalpel through gingivectomy and gingivoplasty procedures. (Figure 3) The specimen was sent for histopathology which revealed hyperplastic parakeratinized epithelium backed by dense stroma with many endothelium lined bloodvessels in diffuse chronic inflammatory cell infiltrate. (Figure 4)



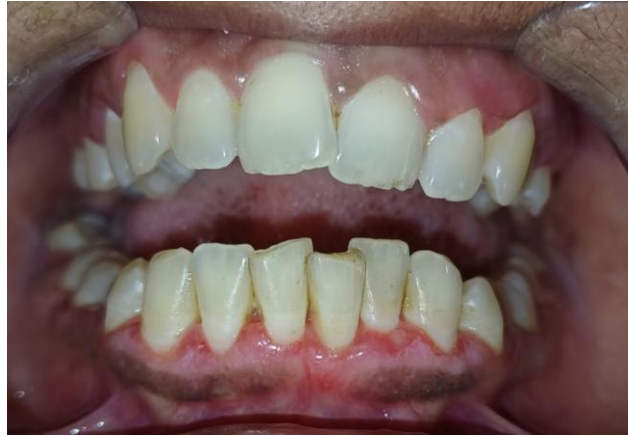**Figure 2:-** Bleeding points are marked using pocket marker.



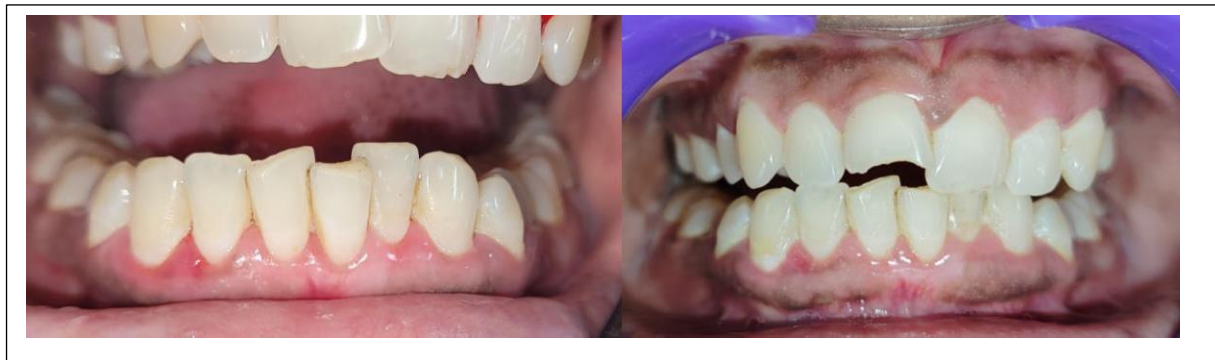**Figure 3:-** After removal excess tissue through gingivectomy.



**Figure 6:-** Histopathological Image.



**Figure 4:-** Follow up after 1 week.



**Figure 5:-** Follow up 3 months and 1 year respectively.

Correlating history, clinical examination, and investigations, final diagnosis of combined gingival enlargement (immunosuppressant induced and inflammatory) was made. The patient was followed up for more than a year. The physician has stopped immunosuppressant therapy 3 months after the surgical correction. A follow up after 1 year shows successful result and the patient is well satisfied with the treatment.

### **Discussion:-**

The term "lupus enteritis" describes vasculitis or inflammation of the small or large intestinal wall, which frequently manifests as vomiting, diarrhoea, and abdominal pain. Even in the absence of other common symptoms of Systemic Lupus Erythematosus (SLE), it may be an uncommon early indication of SLE (4). Lupus Nephritis can also result from renal inflammation brought on by SLE. Even though SLE frequently affects many organ systems, lupus enteritis and nephritis may be the sole symptoms that some individuals initially exhibit. Immunosuppressants are frequently used in the treatment of lupus enteritis, which is typically steroid-responsive. Immunosuppressants and other drugs are also used to treat lupus nephritis in order to control inflammation and kidney damage (5). The antimalarial medication hydroxychloroquine is also used to treat rheumatic and SLE conditions.

Gingival enlargement can be brought on by immunosuppressants, which are used to treat autoimmune disorders and prevent organ transplant rejection. The immunosuppressant most commonly associated with this illness is cyclosporine. The link between MMF and gingival enlargement is also supported by certain research (6). According to published research, there is no proof linking hydroxychloroquine to gingival hypertrophy. More common on the vestibular side of the maxillary and mandibular frontal regions, gingival enlargement first appears as a localised nodular enlargement on the interdental papillae before spreading to the dental crown (7). It has been shown that the enlargement linked to immunosuppressive medication is characterised by a high level of inflammation and mild fibrosis, in contrast to the gingival hyperplasia caused by anticonvulsants and calcium channel blockers. From a histological perspective, the gingival enlargement brought on by Cyclosporin A and MMF may be classified as a



connective tissue disorder. This condition is characterised by increased production of extracellular matrix proteins and interstitial collagen, infiltration of plasma cells, an increased inflammatory response (more inflammatory cells, including macrophages), and altered vascularization (8).

In a review of the pathophysiology of drug-induced gingival overgrowth, Seymour et al. expanded on the interaction between the drug and metabolite with the gingival fibroblasts by seeing it as a multifactorial model incorporating the interaction of multiple variables. Age, genetic susceptibility, pharmacokinetic factors, drug-induced changes in gingival connective tissue homeostasis, histopathology, ultrastructural factors and inflammatory changes, and drug-induced impact on growth factors are predisposing factors for these changes(2).

MMF functions by blocking the inosine monophosphate dehydrogenase (IMPDH) enzyme, which is essential for guanosine nucleotide synthesis. The growth of T and B lymphocytes, which are important components of immunological responses, depends on these nucleotides. Mycophenolate efficiently decreases the quantity of these immune cells and inhibits both antibody-mediated and cell-mediated immunological responses by inhibiting IMPDH (9). This decreased inflammatory response may change how tissue is repaired and remodelled. Mycophenolate is thought to interfere with the production or function of MMPs, which disrupts the normal turnover of collagen and other ECM components within the gingiva. This imbalance causes collagen and other ECM components to accumulate, though the precise mechanism is still being studied.

In contrast to cyclosporin A, certain data in the literature indicate that MMF may be able to lower the incidence of gingival overgrowth. Azathioprine and MMF both significantly prevent gingival enlargement, according to a study comparing the effects of many immunosuppressants, including cyclosporine, tacrolimus, sirolimus, and azathioprine. (10) More investigation is necessary to comprehend and prove the link between MMF and gingival enlargement as well as to create efficient treatment plans.

## Conclusion:-

In this case study, a patient with lupus enteritis experienced a rare episode of gingival hypertrophy brought on by mycophenolate mofetil. It emphasises the significance of keeping an eye on oral health in patients receiving immunosuppressive treatment and the necessity of interdisciplinary cooperation between medical and dental specialists. Patient outcomes can be greatly enhanced by early diagnosis and suitable therapy. More research is required to comprehend the causes behind this illness and create efficient management plans.

## Source of Funding

None.

## Conflict of Interest

None.

## References:-

1. Marshall, R. I., & Bartold, P. M. (1998). Medication induced gingival overgrowth. *Oral diseases*, 4(2), 130–151. <https://doi.org/10.1111/j.1601-0825.1998.tb00269.x>
2. Seymour, R. A., Thomason, J. M., and Ellis, J. S. (1996). The pathogenesis of drug-induced gingival overgrowth. *Journal of Clinical Periodontology*, 23:165-175. <https://doi.org/10.1111/j.1600-051X.1996.tb02072.x>
3. Lauritano, D., Moreo, G., Limongelli, L., Palmieri, A., & Carinci, F. (2020). Drug-Induced Gingival Overgrowth: The Effect of Cyclosporin AA and Mycophenolate Mophetil on Human Gingival Fibroblasts. *Biomedicines*, 8(7), 221. <https://doi.org/10.3390/biomedicines8070221>
4. Potera, J., Palomera Tejada, E., Arora, S., & Manadan, A. M. (2021). Lupus Enteritis: An Uncommon Presentation of Lupus Flare. *Cureus*, 13(9), e18030. <https://doi.org/10.7759/cureus.18030>
5. Janssens, P., Arnaud, L., Galicier, L., Mathian, A., Hie, M., Sene, D., Haroche, J., Veyssier-Belot, C., Huynh-Charlier, I., Grenier, P. A., Piette, J. C., & Amoura, Z. (2013). Lupus enteritis: from clinical findings to therapeutic management. *Orphanet journal of rare diseases*, 8, 67. <https://doi.org/10.1186/1750-1172-8-67>

6. Lauritano, D., Moreo, G., Limongelli, L., Palmieri, A., & Carinci, F. (2020). Drug-Induced Gingival Overgrowth: The Effect of Cyclosporin AA and Mycophenolate Mophetil on Human Gingival Fibroblasts. *Biomedicines*, 8(7), 221. <https://doi.org/10.3390/biomedicines8070221>
7. Moffitt, M. L., Bencivenni, D., & Cohen, R. E. (2013). Drug-induced gingival enlargement: an overview. *Compendium of continuing education in dentistry (Jamesburg, N.J. : 1995)*, 34(5), 330–336.
8. Trandafir, D., Trandafir, V., & Gogalniceanu, D. (2013). Gingival overgrowth induced by Immunosuppressive treatment with cyclosporine A and Mycophenolate Mofetil in a patient with Kidney transplant-A case report and literature review. *Int J Med Dent*, 3, 183-7.
9. Allison A. C. (2005). Mechanisms of action of mycophenolate mofetil. *Lupus*, 14 Suppl 1, s2–s8. <https://doi.org/10.1191/0961203305lu2109oa>
10. De la Rosa García, E., & Mondragón Padilla, A. (2009). Efecto del micofenolato de mofetilo y azatioprina sobre la hiperplasia gingival asociada al uso de Ciclosporina A en pacientes con trasplante renal [The effect of mycophenolate mofetil and azathioprine on gingival enlargement associated with Cyclosporin AA use in kidney transplant patients]. *Nefrología : publicacion oficial de la Sociedad Espanola Nefrologia*, 29(5), 474–478. <https://doi.org/10.3265/Nefrologia.2009.29.5.5413.en.full>