



Journal Homepage: - www.journalijar.com

INTERNATIONAL JOURNAL OF ADVANCED RESEARCH (IJAR)

Article DOI: 10.21474/IJAR01/10539

DOI URL: <http://dx.doi.org/10.21474/IJAR01/10539>



RESEARCH ARTICLE

PREVALENCE OF DEVELOPMENTAL DYSPLASIA OF THE HIP (DDH) BY USING THE ULTRASOUND AMONG NEW BORN BABIES AT MATERNITY & CHILDREN HOSPITAL (MCH) IN AL-MADINAH CITY SAUDI ARABIA, 2018: A CROSS-SECTIONAL STUDY

Albelady Ayed Rehab

Manuscript Info

Manuscript History

Received: 17 December 2019

Final Accepted: 20 January 2020

Published: February 2020

Key words: -

Developmental Dysplasia of The Hip,
Infant, Ultrasound, Saudi Arabia

Abstract

Purpose: Developmental dysplasia of the hip (DDH) is one of the most common musculoskeletal problems in infants. It is also known as congenital hip dysplasia, but actually this is a misnomer. It is a developmental disease. The early detection of DDH by Ultrasonography within the first six weeks of babies' life and treatment for hip dysplasia has a higher probability of success. Therefore, the present study aimed to raise the issue of cost-effectiveness included US as a screening tool in neonatal screening by measuring the prevalence of hip dysplasia.

Methods: A cross-sectional study was conducted on 50 infants to measure the prevalence of Developmental dysplasia of the hip among infants at Maternity & Children hospital (MCH) in Al-Madinah city by using the ultrasound.

Results: According to the study design, 50 patients were included in the study; the majority of the patients (47%) on the age group of (More than two months to three months) with 1:2 male to female ratio. The percentage of infants with developmental dysplasia of the hip is 78 % among all infants and two third of infants with developmental dysplasia of the hip had unilateral dysplasia of the hip.

Conclusion: This study identified a high prevalence of developmental dysplasia of the hip among infants at Maternity & Children Hospital (MCH) in Al-Madinah city. Developmental dysplasia of the hip among infants commonly affected female infants and frequently with unilateral hip dysplasia.

Copy Right, IJAR, 2020,. All rights reserved.

Introduction: -

Developmental dysplasia of the hip (DDH) is a spectrum of abnormalities ranging from mild acetabular dysplasia with reducible subluxation to irreducible subluxation or dislocation of the femoral head. Synonymously, congenital hip dislocation used to be a medical term of DDH, but usually, most dislocations are evident at birth; therefore, the terminology has changed from congenital dysplasia of the hip to developmental dysplasia of the hip. ⁽¹⁾

Physiologically, the femoral head and acetabulum must articulate with each other for normal hip development. If there is a hip subluxation or dislocation, the acetabulum becomes shallow and steep rather than cup-shaped, because it will lack the stimulus of the femoral head for development. Therefore, in chronic subluxation or dislocation, the joint capsule will get stretched, acetabulum will fill with fibrofatty tissue (pulvinar), and the labrum will invert. ⁽¹⁾

Researchers ^(2,3) indicated that family history and abnormal intrauterine position are risk factors that contributed to the development of DDH. However, the risk of having DDH is 6 % if one of the siblings has the condition and reach up to 36 % if both of the parents have it. Furthermore, DDH is also six times more frequent after breech delivery than after vertex delivery ⁽⁴⁾. The extreme flexion associated with a breech delivery produces a shortened and contracted iliopsoas muscle, which tends to promote dislocation.

In Saudi Arabia ⁽⁵⁾, the incidence rate of DDH was found to be 3.5/ 1000 live births; only 32.4% of DDH diagnosed during the first six months of life. The mean age at diagnosis was one year, while the mean age at which the participants had undertaken the treatment was three years. Majority of the cases were female with (78.3%), and the Delivery was by spontaneous vaginal delivery in 89.3% of cases. Furthermore, 46% of the children had treated surgically, 42% had treated conservatively, and managed by both 12%.

However, the diagnosis of DDH is suspected clinically when physical examination reveals asymmetric skin folds, limited abduction of the hip, or an abnormal Barlow or Ortolani maneuver. The Barlow maneuver ⁽⁶⁾ used to do by flexing and adducting the hip with pushing the knee posteriorly and superiorly, thus will produce a palpable vibration or "clunk" that indicate. Furthermore, the Ortolani maneuver ⁽⁷⁾ used to do by hip flexing in 90 degrees and abducting the hip in a frog-leg position, thus will cause palpable "clunk" and indicate the presence of DDH.

For diagnostic purposes, the sonography is superior to conventional radiography in evaluating hip disorders in neonates and young infants because it demonstrates the cartilaginous and soft tissue components of the hip joint, particularly the femoral head and labrum, which are not visible on conventional radiography. ⁽⁸⁾ There are dynamic stress technique and the static Graf technique that are the two sonographic methods of evaluating the hip, based on the identification of femoral and acetabular landmarks. ⁽⁹⁾

The dynamic technique includes a dynamic assessment of the hip in addition to assess the anatomical structure. The Graf technique used to be on a single direct coronal sonogram of the hip, the image obtained with a linear array transducer, and with the infant in the lateral decubitus position and the femur extended. ⁽¹⁰⁾ As a consequence, the Graf classification of hip dysplasia is mainly based on the morphology of the iliac bone; first three points of interest need to be identified in the ultrasound image, Centre of labrum, Lower limb of the iliac bone (=Undersurface of the medial border of the acetabulum where the iliac bone meets the triradiate cartilage) and Bony rim of acetabulum. Graf classification is based on the alpha-angle, which is a measurement of the bony roof of the acetabulum, mainly determines the hip type and for classification purposes, the beta angle is only used to differentiate between type Ia and Ib (both normal hips) and between type IIc and type D). ⁽¹¹⁾

In the present study, the prevalence of Developmental dysplasia of the hip among newborn babies had been estimated by using the ultrasound which is a valid, reliable and widely used for screening and diagnostic purposes. The researchers of the present study only relied on the normality of acetabular roofs. However, findings on Ultrasound for the cases of the Developmental dysplasia of the hip show shallower and more vertical acetabular roofs, whereas in normal acetabular roofs are delineated as curvilinear hyperechoic lines on screen.

From the above disclosure and based on previous studies that concluded that the early detection of DDH by Ultrasonography within the first sex week of babies' life and treatment for hip dysplasia has a higher probability of success. Therefore, the present study aimed to raise the issue of cost-effectiveness included US as a screening tool in neonatal screening by measuring the prevalence of dysplasia and revealed the related risk factors.

Methodology:-

Objectives:-

To measure the prevalence of Developmental dysplasia of the hip among infants at Maternity & Children hospital (MCH) in Al-Madinah city by using the ultrasound.

Study Design:

This study was cross-sectional.

Study Settings:

The study conducted at Maternity & Children Hospital (MCH) in Al-Madinah city, Saudi Arabia.

Study Population:

The inclusion criteria were as follows:

1. Infants at Maternity & Children Hospital (MCH) in Al-Madinah city
2. Infants who were male or female at any age or nationality.

Sample Size:

Babies who born at Maternity & Children Hospital (MCH) in Al-Madinah city, Saudi Arabia, during October, November, and December 2018 (n=50) and met the inclusion and exclusion criteria had recruited in our study after reviewing hospital database.

Data Collection:

The questionnaire of this study has consisted of two sections:

The first section included the following information:

1. Age and gender.

Second section included:

2. Result of Radiology examination by Ultrasound: Presence / Absence
3. Site of Developmental dysplasia of the hip (DDH): unilateral/bilateral

Work plan:

1. Fulfill the criteria of Infants who born during October, November, and December of 2018 at Maternity & Children Hospital (MCH) in Al-Madinah city, Saudi Arabia.
2. Data collection had started after getting permission from the ethical and scientific committee in Maternity & Children Hospital (MCH) in Al-Madinah city, Saudi Arabia.
3. Every infant in the present study had approached by informed consent form one of the parents. The patient confidentiality was also under keen observation, and the data was kept highly confidential along the course of the research.

Outcome Measures:

Prevalence of Developmental dysplasia of the hip among infants by using the ultrasound, which is valid, reliable and widely used for screening and diagnostic purposes. Findings on Ultrasound for the cases of the Developmental dysplasia of the hip show shallower and more vertical acetabular roofs, whereas in normal acetabular roofs are delineated as curvilinear hyperechoic lines on screen.

Ethical Consideration and Confidentiality:

Approval for research data collection of required authorities and institutions was obtained. These data will be confidential and used just for research purposes.

Data Analysis:

SPSS 20.0 statistical software package (IBM Corporation, Somers, New York) was used. Quality control was done at the stages of coding and data entry. Data were presented using descriptive statistics in the form of frequencies and percentages for qualitative variables and means and standard deviations, medians, and interquartile ranges for quantitative variables.

Result report:

According to the study design, 50 patients were included in the study; the majority of the patients (47%) on the age group of (More than two months to three months) with 1:2 male to female ratio (Table 1).

Figure 1 displays that the percentage of infants with developmental dysplasia of the hip is 78 % among all infants and two third of infants with developmental dysplasia of the hip had unilateral dysplasia of the hip.

Discussion:-

Developmental dysplasia of the hip (DDH) is one of the most common musculoskeletal problems in infants. Using the ultrasound is necessary to assess and evaluate the hip bone of a newborn patient.

The present study showed that the most common age of diagnosis was three months, this finding comes in line with the survey⁽¹²⁾ that aimed to do automatic assessment of developmental dysplasia and high prevalence of infants had been diagnosed on age less than three months. Diagnosis of Developmental dysplasia of the hip in another study⁽¹³⁾ was in age exceeding the eight months.

Furthermore, the present study showed that the majority of the cases were female with (68%), this finding comes in line with those from previous studies conducted nationally⁽⁵⁾, regionally and internationally, which concluded that developmental dysplasia of the hip used to be common among female patients.

Our results show that two-third of infants with developmental dysplasia of the hip had unilateral dysplasia of the hip. However, previous study⁽¹⁴⁾ observed that there is a predominance of left-sided (64.0%) and unilateral disease (63.4%). This study is almost similar to our current study

Our study has some limitations. The present study carried out in single- institute and multicenter approach may increase the sample size. Another limitation is that the used questionnaire was limited in data and must be revised to include more data related to risk factors of developmental dysplasia of the hip and more ultrasound detailed measurement according to Graft classification.

Conclusion:-

This study identified a high prevalence of developmental dysplasia of the hip among infants at Maternity & Children Hospital (MCH) in Al-Madinah city. Developmental dysplasia of the hip among infants commonly affected female infants and frequently with unilateral hip dysplasia.

Table 1:- General characteristics of the Patients (n=50).

Demographic characteristics	Frequency(n)	Percent (%)
Age		
Less than one month	1	2
More than one month to two months	12	24
More than two months to three months	23	47
More than three months to four months	10	21
More than four months to five months	2	4
More than five months to six months	1	2
Gender		
Male	16	32
Female	34	68

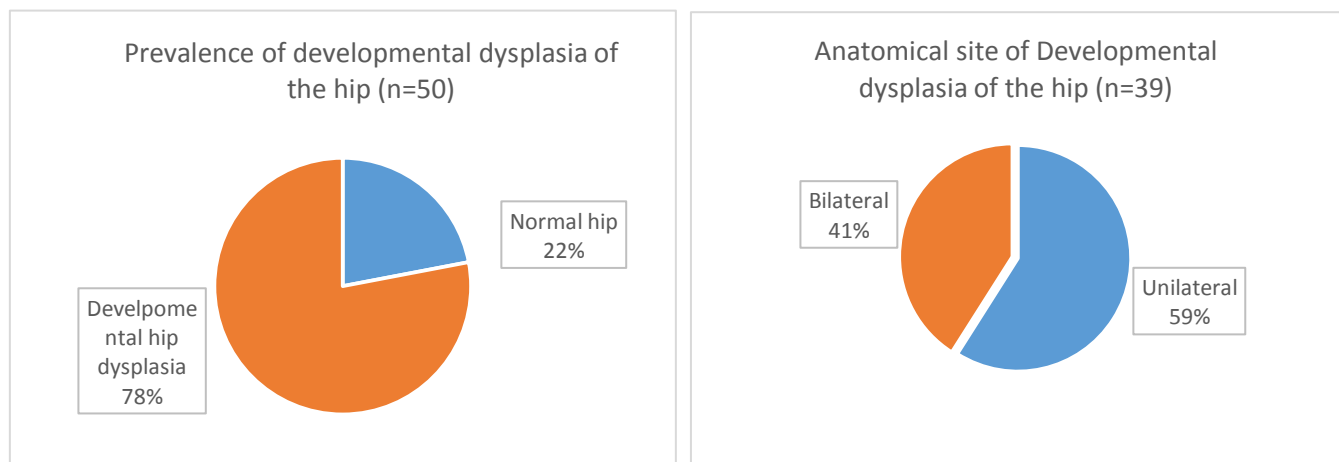


Figure 1:- Percentages of infants with Developmental dysplasia of the hip.

References:-

1. Marilyn J. Siegal, Pediatric sonogram. 4th edition. Wolters Kluwer & Lww. 2011. Page 607
2. Paul HY, Ganta A, Hussein KI, Frank RM, Jawa A. Readability of arthroscopy-related patient education materials from the American Academy of Orthopaedic Surgeons and Arthroscopy Association of North America Web sites. *Arthroscopy: The Journal of Arthroscopic & Related Surgery*. 2013 Jun 1;29(6):1108-12.
3. Shaw BA, Segal LS. Evaluation and referral for developmental dysplasia of the hip in infants. *Pediatrics*. 2016 Dec 1;138(6):e20163107.
4. Woodacre T, Ball T, Cox P. Epidemiology of developmental dysplasia of the hip within the UK: refining the risk factors. *Journal of children's orthopaedics*. 2016 Dec 1;10(6):633-42.
5. Albaqawi AS, Altaleb FF, Aljaber DA, Aljaber HA. Pattern of Congenital Dislocation of the Hip in Arar City, Northern Saudi Arabia.
6. Fabry G. Clinical practice. *European journal of pediatrics*. 2010 Feb 1;169(2):143-8.
7. Gelfer P, Kennedy KA. Developmental dysplasia of the hip. *Journal of pediatric health care*. 2008 Sep 1;22(5):318-22.
8. Bond CD, Hennrikus WL, DellaMaggiore ED. Prospective evaluation of newborn soft-tissue hip "clicks" with ultrasound. *Journal of Pediatric Orthopaedics*. 1997 Mar 1;17(2):199-201.
9. Roposch A, Wright JG. Increased diagnostic information and understanding disease: uncertainty in the diagnosis of developmental hip dysplasia. *Radiology*. 2007 Feb;242(2):355-9.
10. Rosendahl K, Markestad T, Lie RT, Sudmann E, Geitung JT. Cost-effectiveness of alternative screening strategies for developmental dysplasia of the hip. *Archives of pediatrics & adolescent medicine*. 1995 Jun 1;149(6):643-8.
11. Radiology Assistant: Developmental Dysplasia of the Hip - Ultrasound. Available at <https://radiologyassistant.nl/pediatrics/developmental-dysplasia-of-the-hip-ultrasound>; accessed March 8, 2018.
12. Quader N, Hodgson AJ, Mulpuri K, Schaeffer E, Abugharbieh R. Automatic evaluation of scan adequacy and dysplasia metrics in 2-D ultrasound images of the neonatal hip. *Ultrasound in medicine & biology*. 2017 Jun 1;43(6):1252-62.
13. Woolacott NF, Puhan MA, Steurer J, Kleijnen J. Ultrasonography in screening for developmental dysplasia of the hip in newborns: systematic review. *bmj*. 2005 Jun 16;330(7505):1413.
14. Loder RT, Skopelja EN. The epidemiology and demographics of hip dysplasia. *ISRN orthopedics*. 2011 Oct 10;2011.