

 <p>ISSN NO. 2320-5407</p>	<p>Journal Homepage: - www.journalijar.com</p> <h2 style="text-align: center;">INTERNATIONAL JOURNAL OF ADVANCED RESEARCH (IJAR)</h2> <p style="text-align: center;">Article DOI: 10.21474/IJAR01/9799 DOI URL: http://dx.doi.org/10.21474/IJAR01/9799</p>	 <p>INTERNATIONAL JOURNAL OF ADVANCED RESEARCH (IJAR) ISSN 2320-5407 Journal Homepage: http://www.journalijar.com Article DOI: 10.21474/IJAR01/9799</p>
---	--	---

RESEARCH ARTICLE

TWIN PREGNANCY INVOLVING A MOLAR PREGNANCY AND LIVING FETUS: ABOUT TWO CASES.

Imane Benchiba , Mohamed karam saoud , Nissrine Mamouni, Sanaa Errarhay, Chahrazed Bouchikhi and Abdelaziz Banani.

Obstetrics and Gynecology I - HASSAN II University Hospital – Fez- Morocco.

Manuscript Info

Manuscript History

Received: 16 July 2019

Final Accepted: 18 August 2019

Published: September 2019

Key words:-

Dichorionic twins; Hydatiform mole;
Live fetus.

Abstract

The co-existence of hydatiform mole with living fetus is a rare phenomenon with an incidence of 1 in 22 000 to 1 in 100 000 pregnancies it is a rare situation and a challenge for diagnosis. Results related to fetal outcome and maternal risk of subsequent gestational trophoblastic neoplasia (GTN) are controversial. Our objective is to investigate the clinical features and natural history of twin conceptions consisting of complete hydatidiform mole and a coexisting fetus.

Copy Right, IJAR, 2019,. All rights reserved.

Introduction:-

Gestational trophoblastic disease (GTD) represents a spectrum of abnormal conceptions with variable malignant potential. Hydatiform mole represents the benign form of GTD with a favourable prognosis. The co-existence of hydatiform mole with living fetus is a rare phenomenon with an incidence of 1 in 22 000 to 1 in 100 000 pregnancies [1]. The true occurrence is difficult to determine since cases are usually only submitted for histologic examination in the presence of macroscopic abnormalities in the placenta. Careful clinical evaluation and detailed ultrasonic examination of the placenta, as well as a chromosomal analysis, are needed when prenatal diagnosis is attempted. The condition is a dilemma with respect to the diagnosis and to the management of associated maternal and fetal complications.

Case report:

Case 1 : The patient was a 28-year-old woman, gravida 2, para 0, with one previous spontaneous abortion. The pregnancy was achieved following one course of hMG/hCG treatment. An ultrasonographic examination, which was performed at 6 weeks of gestation, revealed a single living fetus at 11 AS obstetrical ultrasound revealed a bichoreal twin pregnancy with a gestational sac containing a live fetus of 11 AS and another gestational sac containing an amniotic cavity with a honeycomb mass of 6x5.6 cm in diameter (Figure 1). Patient did a spontaneous abortion at 15 weeks . The expulsion product was made from a live fetus of 15 AS with its own trophoblast associated with a 13cm vesicular mass (Figure 2) which on histological examination corresponded to a complete hydatiform mole. The monitoring of the plasma beta-HCG were followed weekly until they were negative.

Case 2: of dichorionic twin pregnancy gravida two, para one was diagnosed in a 29-year-old, on routine ultrasound at 12 weeks, and vaginal bleeding. ultrasound examination revealed a dichorionic, twin pregnancy of 12 weeks gestation with live foetuses another gestational sac containing an amniotic cavity with a honeycomb mass of 8x7.5 cm in diameter. Recurrent vaginal bleeding continued in the second trimester. Ultrasound examination was repeated at 19 weeks of pregnancy which revealed structurally normal foetuses corresponding, to the period of gestation, with

Corresponding Author:-Imane Benchiba.

Address:-Obstetrics and Gynecology I - HASSAN II University Hospital – Fez- Morocco.

normal amount of amniotic fluid. However the placentae of both sacs were separate and large (Figure 3). The risk of possible fetal malformations and subsequent malignant sequelae were explained to the couple and they were counselled for termination in the absence of a prenatal diagnosis. But they decided to continue this pregnancy. The patient declined any invasive prenatal testing to confirm the karyotype of the fetus. At 32 weeks of gestation, she was admitted to the hospital in early labor and had a normal spontaneous delivery of a 2125-g normal female infant with Apgar scores of 9 and 10. The placenta delivered spontaneously (Figure 4). The placenta was sent for pathological examination. The pathologic examination of the placenta revealed a placental disc, weighing 280 g and measuring 14[^]20[^] 2.5 cm. Small vesicles, 0.4 cm in average diameter, occupied a marginal crescent-like zone. Histology revealed small mature appearing villi, which were adjacent to large villi. The large villi were partially necrotic and showed central cisterna and circumferential trophoblastic proliferation of moderate degree the patient was discharged in good condition. The patient's b-HCG values were followed weekly until they were negative, which was after 8 weeks.

Discussion:-

The diagnosis of molar pregnancy coexistent with live fetus early in the first trimester is difficult due to its rarity. High resolution ultrasonography may miss molar changes in placenta in as many as 40% of cases [2]. They are usually misinterpreted as hematomas [3,4] In most reported cases, the diagnosis of a coexisting mole and a fetus was suspected after ultrasonographic examination, prior to delivery [3,10,11,12]. Stellar et al. [3] reported that among 19 cases where US was carried out, 13 cases were successfully diagnosed by US and, in 5 additional cases, abnormal placental echoes were described. Differential diagnoses were partial hydatidiform mole and mesenchymal dysplasia [13].

There are three possible types of pregnancy resulting in coexistence of a live fetus with molar placenta: (i) Dizygotic twin with complete hydatiform mole and normal fetus (ii) partial hydatiform mole and (iii) coexistence of a blighted ovum with diffuse hydropic changes and normal fetus.

There have been a large number of cases describing live fetus coexisting with hydatiform mole [5,6], but the distinction between complete and partial moles was established in very few. Advances in cytogenetic techniques, including DNA flow cytometry and polymorphism help to resolve this issue [7]. It is very important to distinguish multiple pregnancy involving a complete mole from that involving a partial mole or blighted ovum. There is evidence that partial mole with coexisting live fetus have high chances of fetal malformation and growth restriction because of associated triploidy. Most presenting symptoms of molar pregnancy coexistent with live fetus (CHCF) are similar to those of singleton hydatidiform mole and include bleeding, inappropriate uterine growth, and a sudden appearance of hypertension or preeclampsia in the first or second trimester [8,9]. However, there are several clinical features that distinguish between singleton hydatidiform mole and CHCF.

It is expected that, with the increase in the utilization of ovulation induction therapy, the rate of multiple gestations containing hydatidiform mole will rise.

Complete hydatidiform mole and coexistent fetus is a rare occurrence and is associated with an increased risk of persistent gestational trophoblastic tumor. Compared to singleton complete molar gestation, a twin pregnancy with complete mole and coexisting fetus was diagnosed at a later gestational age, had higher preevacuation beta-hCG levels, and had a greater propensity to develop persistent gestational trophoblastic tumor. Based on currently available information, it seems that in the presence of a stable pregnancy, normal karyotype, and a normal sonogram it is reasonable to allow the pregnancy to continue. Prenatal testing for fetal karyotype is therefore essential in deciding continuation and prognosis of the pregnancy. The CHCF have a high risk of spontaneous abortion, but about 40% result in livebirths [14].

Conclusion:-

Our findings indicate that patients with complete hydatidiform mole and coexisting fetus are at high risk for developing persistent gestational trophoblastic tumor. It seems that in the presence of a stable pregnancy, normal karyotype, and a normal sonogram it is reasonable to allow the pregnancy to continue. hydatiform mole coexisting with live fetus is a rare condition and requires serial follow-up with serum bHCG until it is negative.

Conflicts of interest :

The authors do not declare any conflict of interest

Figure 1:-Ultrasound examination at 15 weeks of twin pregnancy with co-existing hydatiform mole in each sac. P, normal placenta, area of hydatiform mole

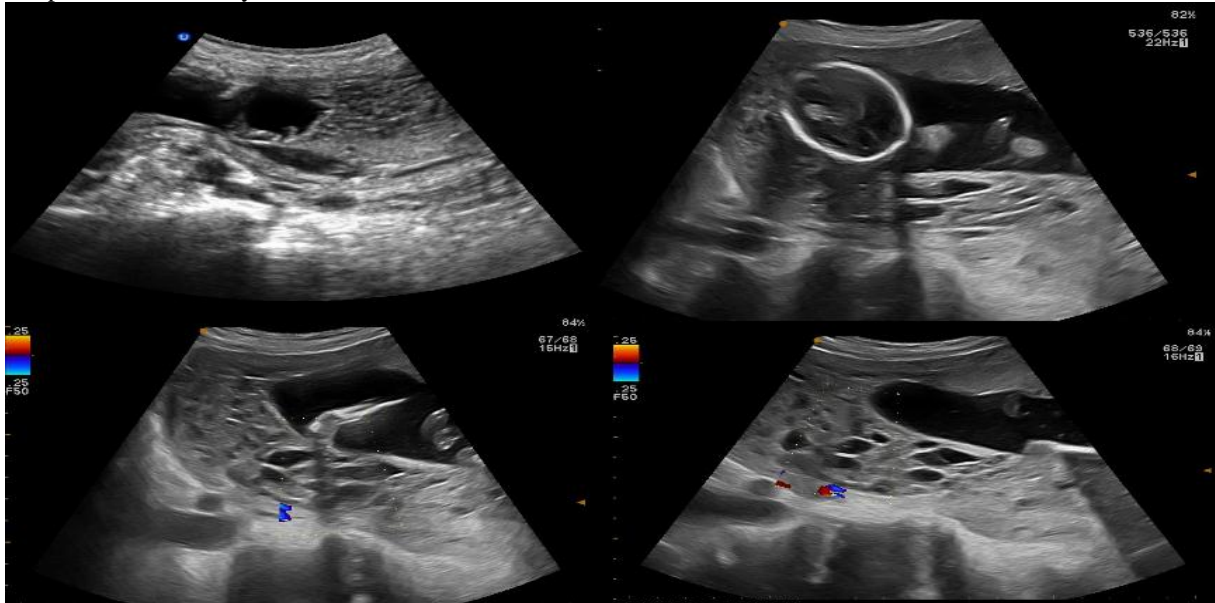


Figure 2:-Gross specimen after abortion depicting first fetus with the normal placenta. The molar placenta with fluid filled vesicles is attached to normal placenta.

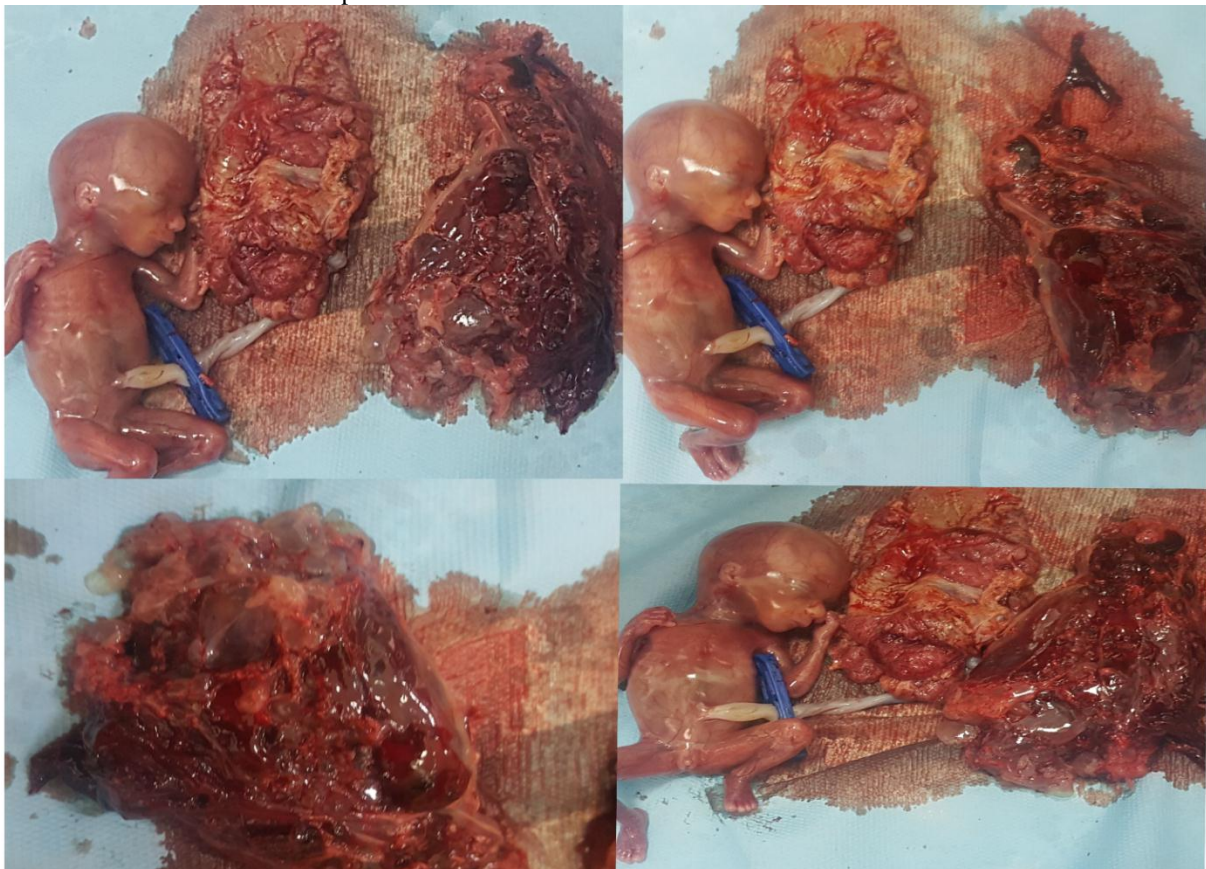


Figure 3:-Ultrasound examination at 12 and 19 weeks of twin pregnancy with co-existing hydatiform mole in each sac. P, normal placenta, area of hydatiform mole

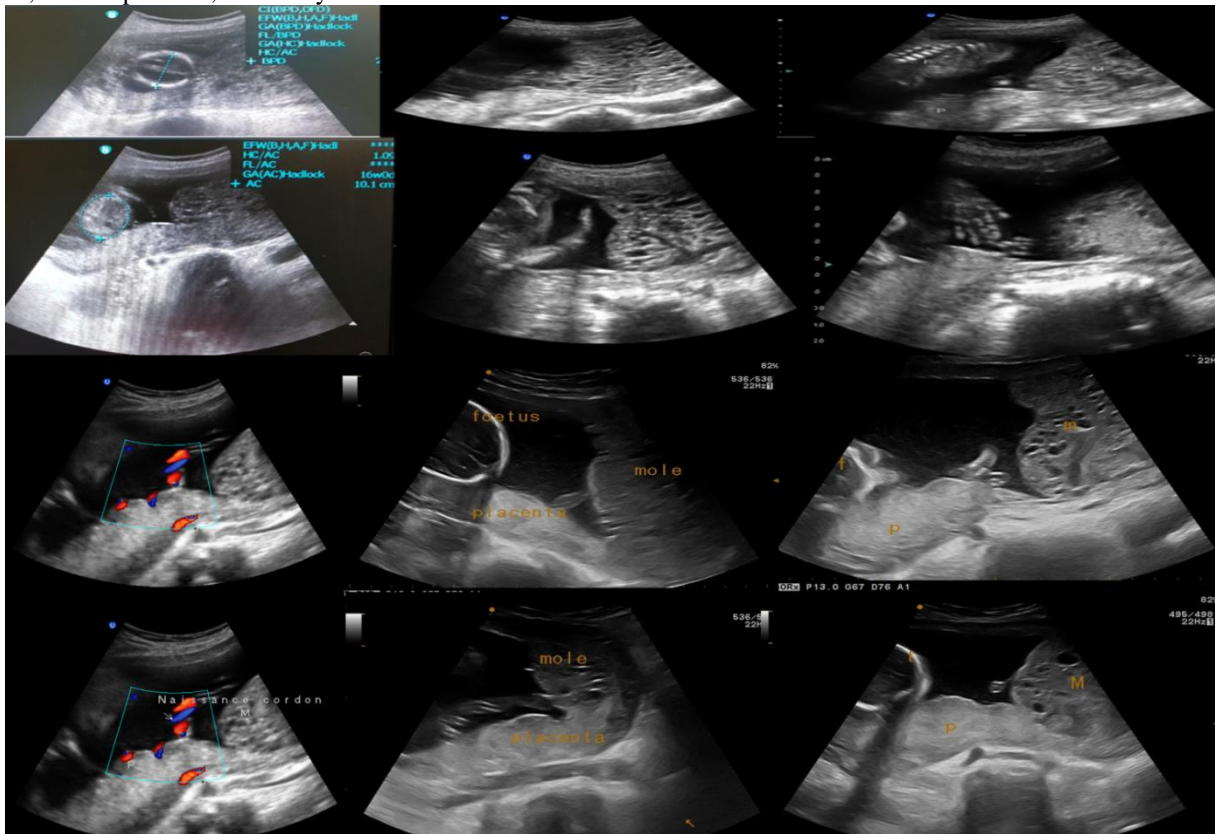
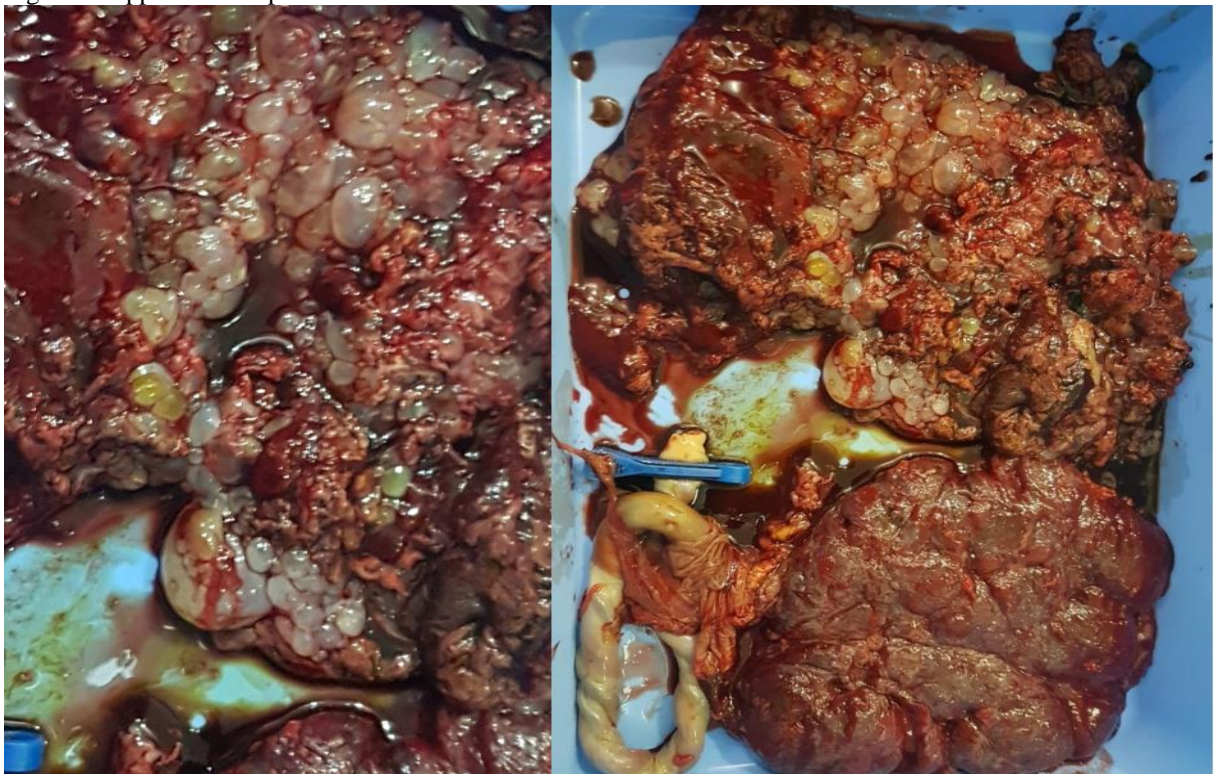


Figure 4: Appearance of placenta after childbirth



a)

Reference:-

1. Jones WB, Lauersen NH. Hydatiform mole with co-existent fetus. *Am J Obstet Gynecol* 1975;122:267–72. M.C. Sharma * a Department of Obstetrics and Gynaecology, All India Institute of Medical Sciences, New Delhi 110029
2. Lindholm H, Flam F. The diagnosis of molar pregnancy by sonography and gross morphology. *Acta Obstet Gynecol Scand* 1999;78:6–9.
3. Stellar MA, Geneset DR, Bernstein MR, Lage JM, Goldstein DP, Berkowitz RS. Natural history of twin pregnancy with complete hydatiform mole and coexisting fetus. *Obstet Gynecol* 1994;83:35–42
4. Luukkonen ES, Sundstrom H, Jorma P, Joupilla P. Hydatiform mole co-existent with a live fetus. *Acta Obstet Gynecol Scand* 1997;76:380–1
5. Vejerslev LO. Clinical management and diagnostic possibilities in hydatiform mole with co-existent fetus. *Obstet Gynecol Surv* 1991;46:577–88.
6. Beischer NA. Hydatiform mole with co-existent fetus. *Aust NZ J Obstet Gynecol* 1966;6:127–41
7. Osada H, Iitsuka Y, Matsui H, Sekiya S. A complete hydatiform mole co-existing with a normal fetus was confirmed by variable number tandem repeat (VNTR) polymorphism analysis using polymerase chain reaction. *Gynecol Oncol* 1995;56:90–3.
8. Miller D, Jackson R, Ehlen T, McMurtie E: Complete hydatidiform mole coexistent with a twin live fetus. Clinical course of four cases with complete cytogenetic analysis. *Gynecol Oncol* 50:119–123, 1993 5.
9. Niemann H, Sunde L, Petersen LK. Department of Clinical Genetics, University Hospital of Aarhus, Aarhus, Denmark Evaluation of the risk of persistent trophoblastic disease after twin pregnancy with diploid hydatidiform mole and coexisting normal fetus. *Am J Obstet Gynecol*. 2007
10. Block MF, Merrill JA: Hydatidiform mole with coexistent fetus. *Obstet Gynecol* 60:129–134, 1982
11. Zbella EA, Vermesh M, Deppe G, Friberg J: Coexistent complete hydatidiform mole and fetus after therapy with human menopausal gonadotropin. *J Reprod Med* 29:760–762, 1984
12. Ohama K, Katasunori V, Okamoto I, Fujimura A: Two cases of dizygotic twins with androgenic mole and normal conceptus. *Hiroshima J Med Sci* 34:371–375, 1985
13. Massardier J, Golfier F, Journet D, et al. Twin pregnancy with complete hydatidiform mole and coexistent fetus: Obstetrical and oncological outcomes in a series of 14 cases. *Eur J Obstet Gynecol Reprod Biol*. 2009;143(2):84–87. [PubMed] [Google Scholar]
14. Sebire NJ, Fokkett M, Paradinas FJ, Fisher RA, et al. Outcome of twin pregnancies with complete hydatidiform mole and healthy co-twin. *Lancet*. 2002;359(9324):2165–2166. [PubMed] [Google Scholar]
15. Bruchim, M.D.,* D. Kidron, M.D.,† A. Amiel, Ph.D.,‡ M. Altaras, M.D.,* and M. D. Fejgin, M.D.* Complete Hydatidiform Mole and a Coexistent Viable Fetus: Report of Two Cases and Review of the Literature, Israel Received October 5, 1999
16. Fishman DA, Padilla LA, Keh P, et al. Management of twin pregnancies consisting of a complete hydatidiform mole and normal fetus. *Obstet et Gynecol*. 1998;91(4):546–50. [PubMed] [Google Scholar].