



ISSN NO. 2320-5407

Journal homepage: <http://www.journalijar.com>
Journal DOI: [10.21474/IJAR01](https://doi.org/10.21474/IJAR01)

INTERNATIONAL JOURNAL
OF ADVANCED RESEARCH

RESEARCH ARTICLE

Accidental Detergent Soap-Bar Ingestion: a rare case of poisoning in an adult with pulmonary involvement.

Dr. Bodhisatwa Choudhuri¹, Dr. Indraneel Dasgupta² and Dr. Indranil Mitra³

1. Resident, Peerless Institute of Emergency Medicine & Trauma Care, Peerless Hospital, Kolkata.
2. Clinical Director, Peerless Institute of Emergency Medicine & Trauma Care, Peerless Hospital, Kolkata.
3. Associate Consultant, Peerless Institute of Emergency Medicine & Trauma Care, Peerless Hospital, Kolkata.

Manuscript Info

Manuscript History:

Received: 12 May 2016
 Final Accepted: 19 June 2016
 Published Online: July 2016

Key words:

Household Detergent; Caustic;
 Soap-bar; Ingestion; Aspiration;
 Pulmonary; Chemical pneumonitis

*Corresponding Author

Dr. Bodhisatwa Choudhuri

Abstract

Caustic detergent ingestions, intentional or accidental, remains a significant health hazard in underdeveloped parts of the world. We came across an unusual presentation of an elderly male with accidental detergent soap-bar ingestion who developed immediate oropharyngeal ulcerations. Although he did not have any immediate esophageal or gastrointestinal involvement, he developed chemical pneumonitis, which required hospital stay with conservative management. This case highlights the features of pulmonary involvement in detergent soap-bar ingestion in a small amount and the value of aggressive emergency and intensive management which can result in a favorable clinical outcome. In our knowledge and subsequent literature searches, this is probably the first case report of this unusual presentation.

Copy Right, IJAR, 2016., All rights reserved.

Introduction:-

Although accidental liquid or powder-based detergent ingestion has been well documented in previous literatures among pediatric population [1-3], accidental solid detergent bar ingestion in adult population is a very rare phenomenon which has not been documented previously. Here we wish to report a case of an 84 year old male with accidental detergent bar ingestion and discuss the possible consequences and considerations in management of caustic detergent ingestion. In our knowledge and subsequent literature search, this is probably the first case report of such unusual presentation.

Case History:-

An 84 years old male patient presented to our Emergency department (ED) with confusion, multiple episodes of diarrhea and excessive salivation. 2 hours prior to arrival to the hospital, the patient mistakenly ingested half bar of detergent soap (Vim bar) at home, thinking it to be a boiled apple. Immediately after this incident, he complained of burning sensation and pain in his mouth, chest and abdomen, followed by excessive salivation and 2 episodes of diarrhea. His mouth was immediately washed using cold water and he was allowed to drink a glassful of cold water at home. There was no history of any vomiting, hematemesis or melena following the incident.

He had a past history of dementia with progressive loss of memory for last 1.5 years. He also had chronic hypertension and benign hyperplasia of prostate. He was on regular medications, such as – Donepezil, Memantine, Citicoline, Piracetam, Amlodipine, Telmisartan, Tamsulosin and Finasteride.

On arrival at ED, he was confused, mildly disoriented, but was able to communicate with the examiner. There were excoriations and swelling of his lips and multiple oozing ulcerations & inflammatory changes in his oral cavity. He was febrile on presentation, axillary temperature was recorded at 101.2°F, mildly tachycardic (112 beats/min) and tachypnoeic (26/min). Oxygen saturation in room air was 96% and blood pressure was recorded as 160/90 mm of Hg in his right upper arm. Capillary blood sugar recorded was 124 mg/dl. There was mild epigastric distension with tenderness, peristaltic sounds were heard normally. Few scattered rhonchi were heard throughout his both lungs. Other systemic examinations were unremarkable. Venous blood gas analysis done in ED revealed pH 7.438, pO₂

41.4, $p\text{CO}_2$ 33.2, HCO_3 21.9, base deficit 1.4. His initial set of laboratory parameters revealed mild anemia and neutrophilic leukocytosis (Hb 13.9 g/dl, PCV 42.8%, WBC 16340 cells/mm³, Neutrophils 90%, Lymphocytes 8%, Monocytes 2%, Platelets 315000/mm³). Serum Creatinine was 0.99 mg/dl, Sodium 141 mEq/L, Potassium 4.6 mEq/L. Liver function tests and urine routine examinations were essentially normal. Electrocardiogram (**Figure-1**) and Chest X-ray (**Figure-2**) done in ED were normal.

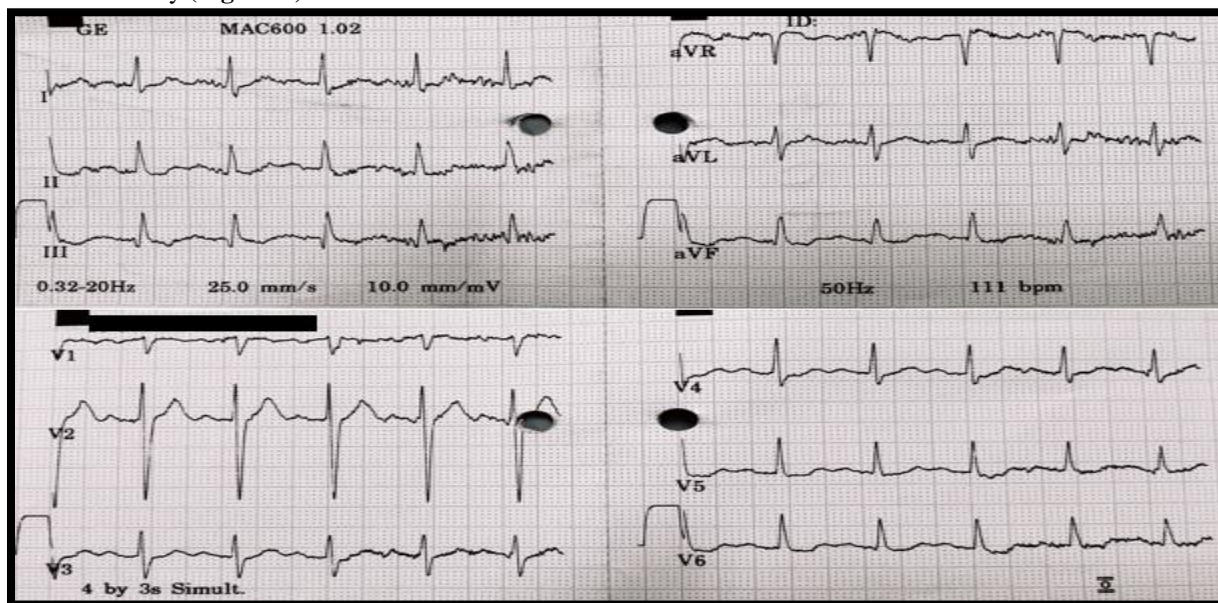


Figure-1: Electrocardiogram – non-specific changes

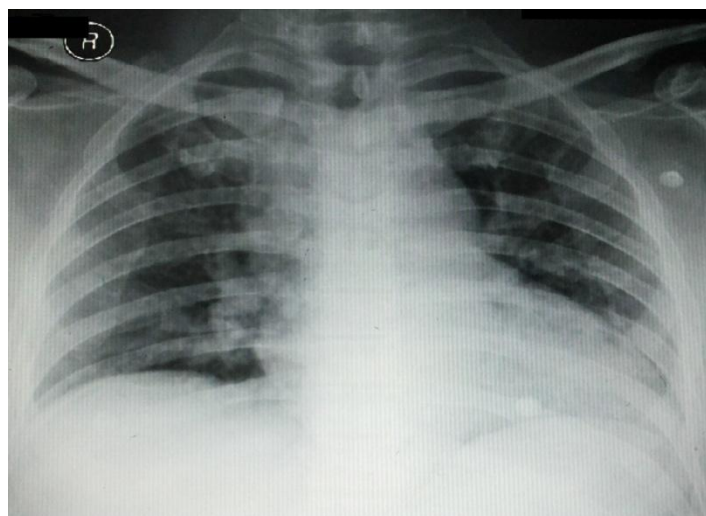


Figure-2: Chest radiogram – No significant abnormality apart from few scattered infiltrates bilaterally

In view of excessive oral secretions, regular suctioning and thorough local toileting was done. He was kept nil per mouth and was hydrated with intravenous normal saline. He was treated with intravenous hydrocortisone and H₂ blocker (ranitidine) and nebulized with salbutamol, budesonide & adrenaline, which significantly improved his perioral edema and tachypnoea. Intravenous antibiotic (amoxicillin – clavulanic acid) was initiated in ED and he was shifted to intensive care for observation. Upper GI endoscopy did not reveal any acute changes apart from atrophic gastritis (**Figure-3**). He was allowed liquids orally post-procedure and was shifted to ward after 24 hours of observation in intensive care unit. But he continued to be febrile (100.2°F), while his other hemodynamic parameters remained stable. Chest auscultation revealed bilateral coarse crepitations. Subsequent investigations revealed gradual resolution of leukocytosis, but raised C-reactive protein and normal procalcitonin level (Hb 13.1 g/dl, PCV 40.3%, WBC 11300 cells/mm³, Neutrophils 83%, Eosinophil 1%, Lymphocytes 13%, Monocytes 3%,

Creatinine 0.98 mg/dl, Sodium 140 mEq/L, Potassium 3.4 mEq/L, CRP 130.8 mg/L, Procalcitonin <15 ng/ml). Repeat chest x-ray on day 3 showed bilateral basal opacifications. His ultrasound of lower abdomen did not reveal any significant abnormality apart from grade II prostatomegaly.

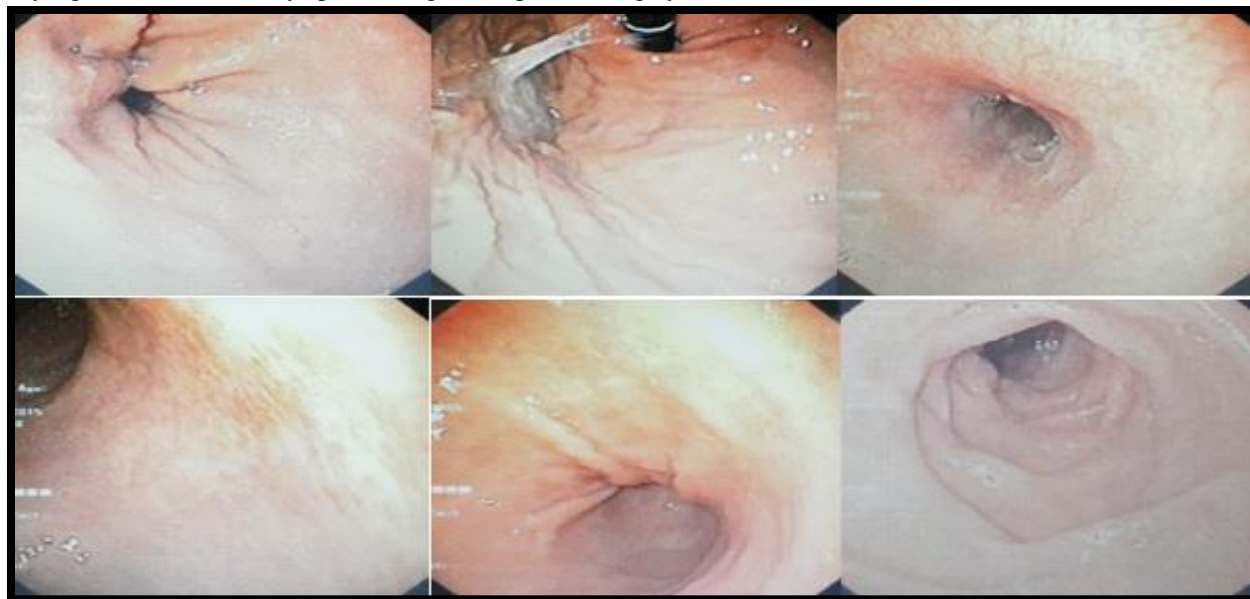


Figure-3: Upper Gastrointestinal Endoscopy - No acute inflammatory changes, incidental finding of atrophic gastritis

A diagnosis of chemical pneumonitis was made and intravenous antibiotics were continued. His condition gradually improved and he became afebrile on day 5 since admission. His CRP reduced on day 6 to 67.8 mg/L, he continued to be afebrile and hemodynamically stable. His perioral edema had reduced and oral ulcerations healed significantly. He was discharged on day 6 with continued oral antibiotics (amoxicillin – clavulanic acid) and his old medications. During his hospital stay, he remained febrile for total of 4 days.

Discussion:-

Alkalis tend to cause significant injuries at a pH>11. Common household detergents such as Vim-bar have a pH higher than 12, but because the titratable base content is significantly less, there is less risk of injury after ingestion. Although grade 1 esophageal injuries do not progress to stricture, 15 to 30% of all grade 2 burns and up to 75% of circumferential grade 2 injuries of the esophagus develop strictures. With full-thickness third-degree burns (grade 3), up to 90% result in stricture [4].

Airway edema and esophageal & gastric perforations are the most emergent issues. Direct injury to the respiratory tract may occur via aspiration of the caustic or vomitus or from inhalation of fumes, resulting in aspiration or chemical pneumonitis [5]. Patients can have wheezing and coughing, stridor, dysphonia and chest pain [6]. Large amount ingestion can lead to severe respiratory dysfunction resulting in acute respiratory distress syndrome and subsequently death [7], whereas small amount of ingestion as in our patient, can initially produce minimal symptoms. Even inhalation can cause potential damage to respiratory tract leading to late-onset stridor and increased work of breathing [8]. Visible burns to the face, lips, and oral cavity may be seen due to spillage or secondary contamination after vomiting. Peritoneal signs suggest hollow viscus perforation or contiguous extension of the burn injury to adjoining visceral areas. Tracheal necrosis is one of the most frequent causes of death after caustic ingestion [9]. Intentional ingestions are associated with higher grades of GI tract injury, with or without clinically obvious signs [10]. Oropharyngeal burns alone do not appear predictive of more distal injury, but prolonged drooling and dysphagia predict significant lesions with 100% sensitivity and 90% specificity [9]. Vomiting and stridor also suggest burn injury. Dysphagia usually subsides in 3 to 4 days. Patients with significant esophageal burns, particularly those that are circumferential, may develop esophageal stricture; 80% of strictures become apparent in 2 to 8 weeks.

After a caustic ingestion, little can be done to attenuate the severity of the tissue injury. Early endotracheal intubation or upper airway endoscopic examination is warranted when there are indications of upper airway injury: hoarseness or muffling of the voice, odynophagia, drooling, or tongue or pharyngeal edema. If significant exposure has occurred, intubation is undertaken early in the course of evaluation, before edema and secretions both threaten the airway and make intubation difficult or impossible. Blind nasotracheal intubation is contraindicated due to the potential for exacerbating airway injuries. When oral intubation is anticipated to be difficult or impossible because of edema and anatomic distortion, awake fiberoptic or video intubation or primary surgical cricothyrotomy may be necessary. Although no studies have directly assessed the role of dexamethasone in oropharyngeal edema due to caustic injury, some toxicologists recommend that a single dose of dexamethasone, 10 milligrams IV (0.6 milligram/kg in children), be administered in such cases. In our case, a single dose of IV Hydrocortisone 200 mg produced significant improvement of airway edema.

Patients should have vigorous intravenous fluid resuscitation. Attempts to neutralize the ingested corrosive with weak acids can cause possible thermal reactions and worsen the injury. Induction of emesis, administration of activated charcoal, and performance of gastric lavage are not indicated [11].

Chest radiography can rule out pulmonary complications. Early endoscopy permits early grading of injuries and helps to determine treatment plan and disposition and nutritional support. It is generally agreed that patients with intentional caustic ingestions should undergo early endoscopy because ingestions with suicidal intent carry the highest risk of clinically important injury. In unintentional ingestions, early endoscopy is recommended in patients with any obvious signs or symptoms of serious injury such as stridor or significant oropharyngeal burns and/or vomiting, drooling, or food refusal, with or without oropharyngeal burns [12]. Thoracoabdominal computed tomography, ultrasonography and serial lactic acid or C-reactive protein measurement can be useful in evaluation and follow up of GI injuries after caustic ingestions [13].

Surgical exploration is indicated for free air, peritonitis, increasing and severe chest and abdominal pain, and hypotension [14]

Asymptomatic patients can undergo endoscopy in the emergency department or be discharged home with close follow-up monitoring. Children or elderly with a questionable history of ingestion should be observed even if they are asymptomatic and have no oropharyngeal burns.

Conclusions:-

Although the management of any caustic ingestion whether it produces immediate airway edema or late complications, the role of emergency care and intensive management leading to favorable outcome cannot be overemphasized. Emergency physicians should be aware of the risk of household caustic ingestions as intentional or accidental poisoning and the life-threatening complications that may follow. Apart from endoscopic evaluation to rule out gastrointestinal injuries, strong suspicion of pulmonary complications should be kept in mind by treating physicians, which may be predominant even in a small amount ingestion as was the case with this patient. It also stresses the importance of early aggressive treatment to combat such complications and improve clinical outcomes.

References:-

1. Bonney AG, Mazor S, Goldman RD: Laundry detergent capsules and pediatric poisoning. *Canadian Family Physician* 2013;59:1295
2. Williams H, Bateman DN, Thomas SH, Thompson JP, Scott RA, Vale JA: Exposure to liquid detergent capsules: a study undertaken by the UK National Poisons Information Service. *Clin Toxicol (Phila)* 2012;50(8):776-80
3. McKenzie et al: Household Cleaning Product-Related Injuries Treated in US Emergency Departments in 1990 – 2006. *Pediatrics* 2010;126:509-51
4. Bicakci U, et al: Minimally invasive management of children with caustic ingestion: Less pain for patients. *Pediatr Surg Int* 2010; 26:251
5. Karnak I, Tanyel FC, Bukupamukcu N, et al: Pulmonary effects of household bleach ingestions in children. *Clin Pediatr* 1996; 35:471
6. Turner A, Robinson P: Respiratory and gastrointestinal complications of caustic ingestion in children. *Emerg Med J* 2005; 22:359

7. Kamiyo Y, Soma K, Inoue A, Nagai T, Kurihara K: Acute respiratory distress syndrome following asthma-like symptoms from massive ingestion of a monoethanolamine-containing detergent. *Veterinary and Human Toxicology* 2004; 46(2):79-80
8. Wheeler D S, Bonny A E, Ruddy R M and Jacobs B R: Late-onset respiratory distress after inhalation of laundry detergent. *Pediatr. Pulmonol.* 2003; 35:323–325
9. Nuutinen M, et al: Consequences of caustic ingestions in children. *Acta Paediatr* 1994; 83:1200
10. Ertekin C, Alimoglu O, Akyildiz H, et al: The results of caustic ingestions. *Hepatogastroenterology* 2004; 51:1397
11. Chyka PA, Seger D, Krenzelok EP, Vale JA: American Academy of Clinical Toxicology; European Association of Poisons Centres and Clinical Toxicologists. Position paper: single-dose activated charcoal. *Clin Toxicol (Phila)* 2005; 43: 61
12. Celik B, Nadir A, Sahin E, Kaptanoglu M: Is esophagoscopy necessary for corrosive ingestion in adults? *Dis Esophagus* 2009; 22:638
13. Ryu HH, et al: Caustic injury: Can CT grading system enable prediction of esophageal stricture? *Clin Toxicol (Phila)* 2010; 48:137
14. Keh SM, Onyekwelu N, McManus K, McGuigan J: Corrosive injury to upper gastrointestinal tract: still a major surgical dilemma. *World J Gastroenterol* 2006; 12:5223