



ISSN NO. 2320-5407

Journal homepage: <http://www.journalijar.com>

INTERNATIONAL JOURNAL  
OF ADVANCED RESEARCH

## RESEARCH ARTICLE

## Standard Herniorrhaphy, Polypropylene Mesh and Tension Band for Repair of Perineal Hernia in Dogs

Adel. M. Al-Akraa

Department of Surgery, Faculty of Veterinary Medicine, Benha University, Egypt.

### Manuscript Info

#### Manuscript History:

Received: 15 August 2015  
Final Accepted: 22 September 2015  
Published Online: October 2015

#### Key words:

Perineal hernia, Herniorrhaphy,  
Polypropylene Mesh, Tension  
Band, Dogs

#### \*Corresponding Author

Adel. M. Al-Akraa  
Alakraa63@yahoo.com

### Abstract

Thirty seven intact male dogs were presented by perineal hernia. Nine of them were suffered from bilateral (24.3%) and the remaining cases were unilateral condition (75.7). All cases were subjected to repair of the perineal hernia, standard herniorrhaphy (28cases), implantation of polypropylene mesh (8cases), and placement of tension band (3cases). Recurrence was recorded in two cases 4 months after initial surgical intervention. Castration was performed in 32case and the other five cases were not castrated according to the owner judgment. Follow up of the previous cases were undertaken. Both sides of bilateral conditions and simultaneous castration were operated at same time. Perineal hernia mostly suspected clinically and confirmed by radiographic assessment. In our study, we are review the etiology, clinical signs, radiographic picture, postoperative complications and synthetic herniorrhaphy to aid in the successful closure of the pelvic diaphragm.

Copy Right, IJAR, 2015,. All rights reserved

## INTRODUCTION

Perineal hernia is a protrusion of the pelvic organs into the ischioanal fossa as a result from failure of pelvic diaphragm muscles to support the rectal wall Aliabadi and Dehghani, 2007. The pelvic diaphragm consists of the external anal sphincter, the levator ani, coccygeus, internal obturator muscles and the sacrotuberous ligament. It occurs commonly in middle aged or aging intact male dogs and rarely in females Pratummintra et al, 2013.

Approximately 59% of the perineal hernias are unilateral while 41% are bilateral Bongartz et al, 2005. The actual cause of perineal hernia usually unspecific but may be obtained from conservative management including the use of stool softeners, periodic enemas and digital fecal removal Pekcan et al, 2010

Perineal hernia may be associated with sacculation, dilatation, deviation and diverticulation of rectum, retroflexion of urinary bladder or urethral obstruction Bongartz et al, 2005; Vnuck et al, 2006 and Vnuck et al, 2008.

Perineal swelling is the most obvious clinical signs; chronic tenesmus may lead to caudal displacement of the prostate and urinary bladder Hedlund, 2013.

Most cases require surgical treatment to prevent life-threatening complications from the incarceration of herniated organs, especially the urinary bladder. Suturing of the muscle of the pelvic diaphragm was the commonest technique for repairing of perineal hernia Gobbetti, 2012.

Herniorrhaphy utilizing biological materials obtained from other patient's own tissues for closing the defect include transposition of the superficial gluteal muscle Spreull, and Frankland, 1980; Szabo et al, 2007, semitendinosus muscle Chambers and Rawlings, 1991 and fascia lata Bongartz et al, 2005 Tunica vaginalis communis Pratummintra et al, 2013.

The synthetic materials that have been reported for perineal hernia repair in dogs are a polypropylene mesh Clarke, 1989, Vnuk et al, 2006; Szabo et al, 2007.

The purpose of this study was to describe the clinical and radiographic aspects of perineal hernia and its possible complications. It also aimed to describe a new technique of perineal hernioraphy by using tension band.

## Materials and Methods

### *Animals:*

Thirty seven dogs included in this study were presented with perineal hernia to the Educational Veterinary Hospital, Faculty of Veterinary medicine, Benha University, and private clinic at Alexandria city. The animals ranged in age between 7-12 years. The recorded cases were intact male dogs and admitted for perineal hernia repair between 2008-2015.

History, signalment, physical and radiographic examinations of the perineum and postoperative complications were recorded. Nine of the recorded cases were affected by bilateral perineal hernia, while, 28 dogs were suffered from unilateral perineal hernia. Out of the unilateral cases right perineal hernia were recorded in 19 cases.

### *Radiographic Examination:*

Plain lateral and ventrodorsal radiographic projections were made (fig. 1A) by using Simply Hp machine at the Department of Surgery, Faculty of Veterinary medicine, Benha University.

### *Anesthesia:*

The animal was pre-medicated with Atropine sulphate at the rate of 0.04 mg/kg body weight followed by Xylazine hydrochloride (xylaject, Adwia com. Egypt) at the rate of 1.5 mg/kg body weight, both given intramuscularly at 10 minutes interval. General anaesthesia was induced with Ketamine hydrochloride (ketamax-50, Troikaa pharmaceuticals Ltd, India) given at the rate of 5 mg/kg body weight intramuscularly. Anaesthesia was maintained by intravenous administration of thiopental sodium (Thiopental Na, Epico. Comp, Egypt) in a dose rate of 20mg/kg body weight, 2.5% solution

### *Surgical repair:*

The dogs were restrained in ventral recumbency and caudally elevated. The perineal region was shaved and prepared for aseptic surgery. The caudal part of the rectum was evacuated and anal sacs were manually expressed and an anal purse-string suture was placed before surgery. The urethra was catheterized to allow identification of the urethra during surgery. Paramedian curvilinear skin incision was performed over the hernia sac (fig. 1B). The hernia content was identified by thoroughly blunt dissection; the important structures (internal pudendal artery, vein and pudendal nerve) should be exposure and carefully isolated.

The prolapsed organs (bladder, prostate, intestine and pelvic fat) (fig. 1C, 1E & 1F) were repositioned and the excess fat was amputated (fig. 1D). Starting dorsally, the external anal sphincter muscle was joined to the levator ani muscle, the coccygus muscle, the sacrotuberal ligament then ventrally to the internal obturator muscle with interrupted 2/0 Vicryl suture (Ethicon Ltd. U.K).

In cases where the hernia cannot be primarily closed (9 bilateral cases) and in recurrent cases (2 cases), the defect was covered with polypropylene mesh which is anchored in the surrounding tissues with 2/0 interrupted suture (8 cases) (fig. 2A, 2C). The tension band was used to co-apitated the defect in 3 cases (fig. 2B, 2D). As regards a second suture row, the perineal fascia was mobilized in either side and sewn together with interrupted 2/0 suture (fig. 2E). After removal of surplus skin, the subcutaneous and skin sutures were performed as usual (fig. 3A, 3B).

In bilateral cases, both sides were operated at the same time. Simultaneous castration was performed in 32 cases and 5 case not performed according to their owner permission. Follow up of the operated dogs were conducted in 26 cases for 6months, while the other cases all trails for communication were failed.

## Results

All dogs presented in this study were intact male, their age were 7-12 years. Nine (24.3%) dogs had bilateral perineal hernia, while, 28 (76.7%) dogs showed unilateral herniation. Out of the unilateral cases right perineal hernia were recorded in 19 (67.9%) dogs.

According to the owner, the swelling was observed initially and increased in size gradually lateral to the anal opening. The animal showed tenesmus, periodic difficulty in defecation or constipation and stranguria or anuria. By palpation of the swelling, it was found to be generally doughy in consistency with a few hard masses and could be reduced into to the pelvic cavity on applying moderate pressure. In cases of the urinary bladder retroflexion, the swelling was very firm, not reducible and the dog was suffered from anuria, the dogs were catheterized and the urine was relieved.

The rectal examination showed, the rectal wall could be found deviated into the subcutaneous tissue lateral to the anus. Hard fecal materials were usually found in the deviated part of the rectum.

Plain radiographic film revealed a perineal swelling and dorsally displaced rectum containing hard fecal matter.

In this study, postoperative complications were local sepsis (3dogs), partial dehiscence (2 dogs), suture sinus (2 dogs) and seroma in one dog. No adverse effect of postoperative complication occurred; local treatment resulted in complete healing. No evidence of suture misplacement through the rectal wall, anal sac or the pelvic urethra was found in any dogs.

Perineal muscle appositional technique was performed in all unilateral cases (28) of perineal hernia; recurrence of the condition was detected in two cases 4 months after surgery. Herniorraphy by placement of polypropylene mesh to repair the pelvic diaphragm defect was carried out in 8 bilateral cases. The tension band was used to renovate perineal hernia in the 2 recurrent cases and one bilateral.

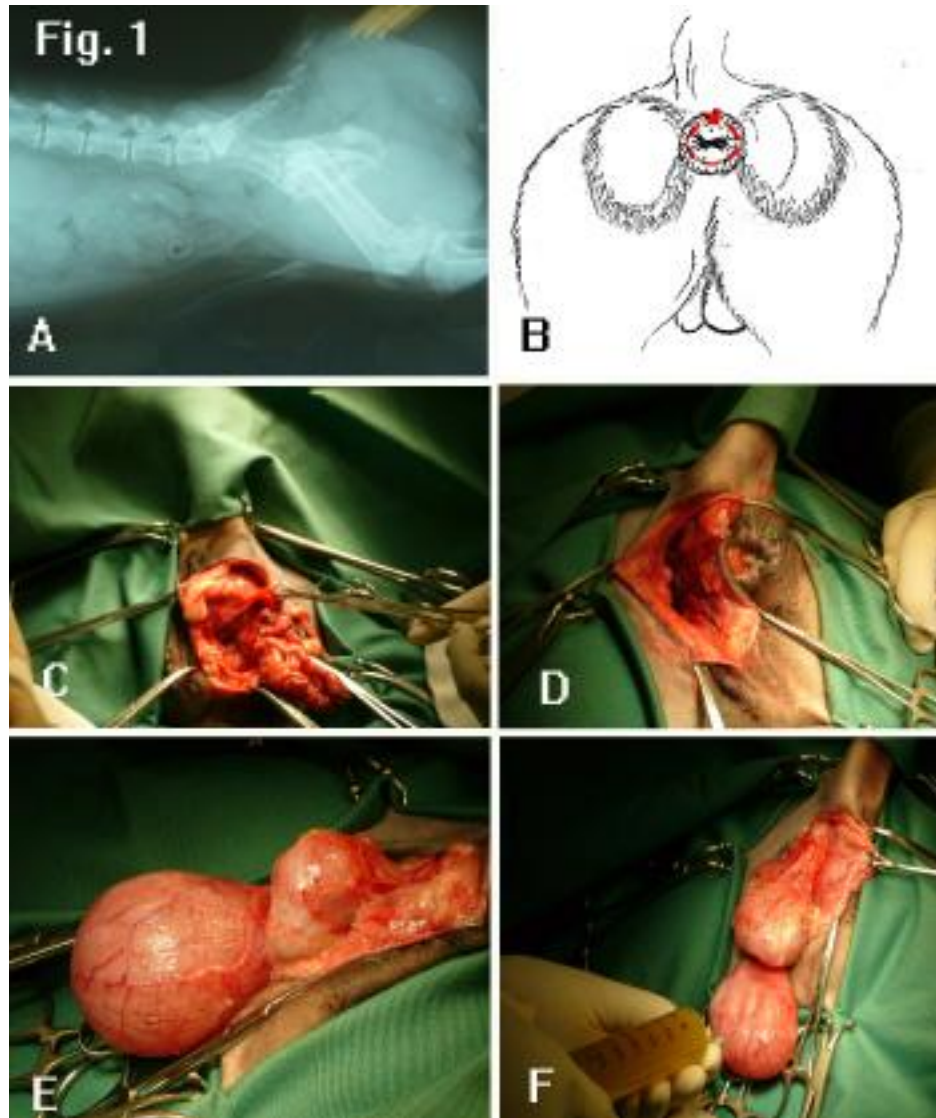


Fig (1) A. Latero-medial radiographic view showing dilatation and sacculatation of the caudal part of the rectum containing a hard fecal material.

B. Diagram illustrating that the site of curve linear incision of the hernial swelling

C. Unilateral Incision of the perineal hernia showing a mass of fat immerges from the defect of the perineal diaphragm

D. The same case after repositioning of hernial content, Notice the defect of the pelvic diaphragm

E. Retroflexion of the urinary bladder and prostate gland in chronic case of perineal hernia

F. Evacuation of the urinary bladder to facilitate its repositioning to its normal position.

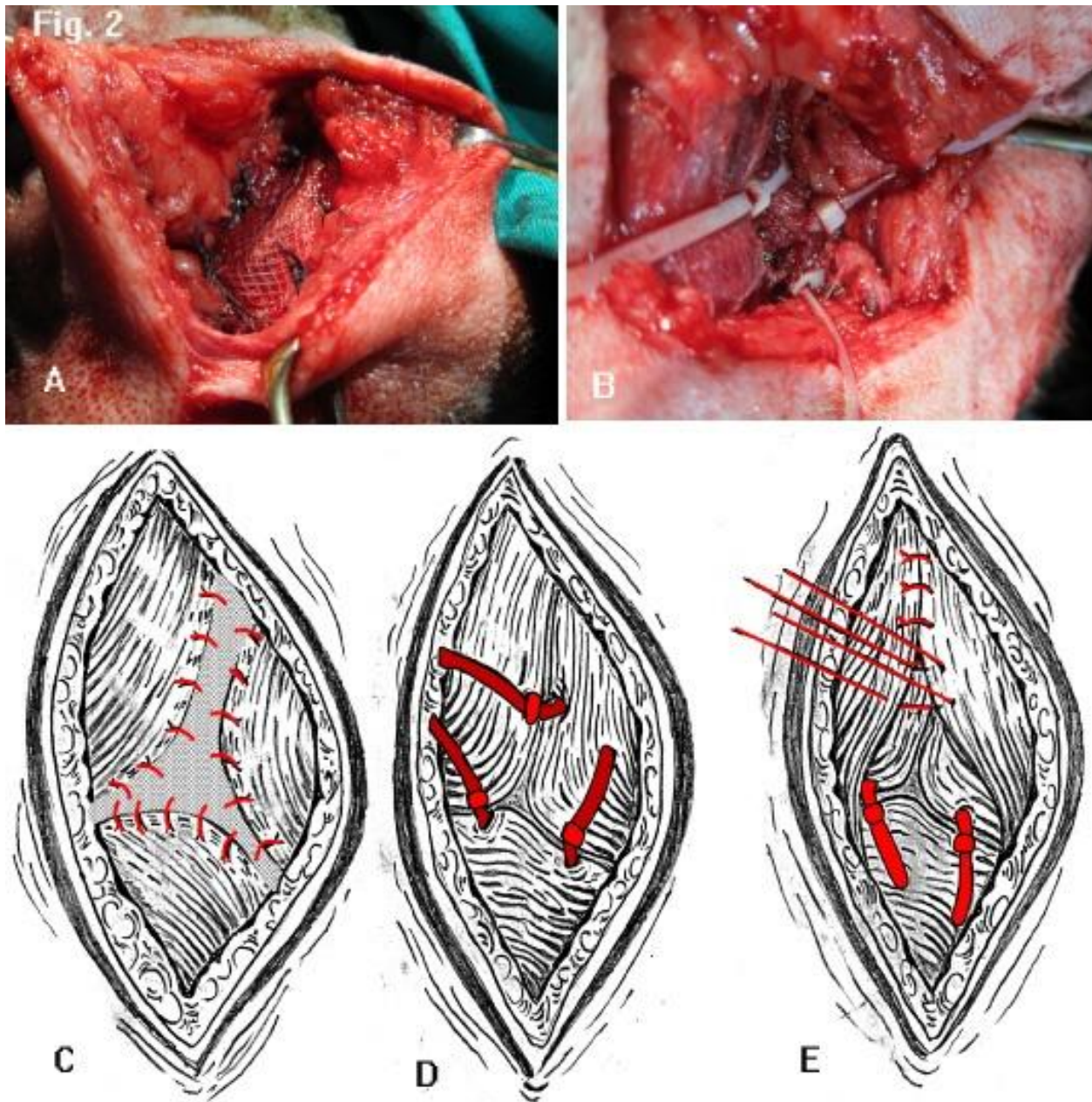


Fig (2) A. Closure of the defect of perineal diaphragm by implantation of polypropylene mesh.

B. Closure of the defect of perineal diaphragm by using of tension band

- C. Schematic drawing of pelvic diaphragm closure using polypropylene mesh
- D. Schematic drawing of pelvic diaphragm closure using tension band
- E. Closure of perineal fascia by simple interrupted suture pattern using 2/0 Vicryl suture material.

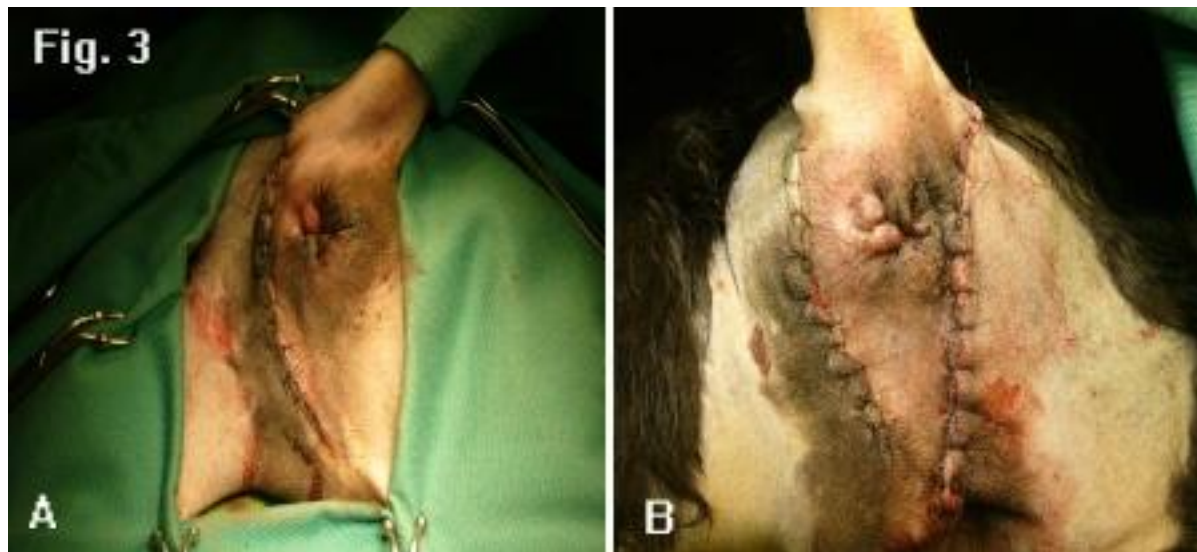


Fig (3) A. Closure of the unilateral incision by simple interrupted suture pattern using 2/0 non absorbable suture material

B. Closure of the bilateral incision by simple interrupted suture pattern using 2/0 non absorbable suture material

### Discussion

Perineal hernia normally results when there is a breach in the continuity of the pelvic diaphragm. The pelvic diaphragm is the vertical closure of the pelvic canal through which the rectum passes Evans and Christensen 1979. It is composed of the levator ani muscle medially and the coccygeus muscle laterally, and the confluence of these structures with the external anal sphincter muscle completes the diaphragm Evans and Christensen 1979; Szabo et al, 2007. With the loss of the lateral support, there is a progressive rectal enlargement and dilation Rockat and Mann 1998, they added that hernia may be complicated by inclusion of pelvic and peritoneal fat, loops of small intestine and in -sever case- by retroflexion of the bladder with or without the prostate gland.

The result of our work revealed that all cases are male ranged in age between 7- 12 years, suffered from chronic constipation, tenismus, straining to defecate and perineal swelling. This in close agreement with Aliabadi and Dehghani, 2007; Pratummintra et al, 2013. They reported that the median values of animal age were 10 years (range, 5–11). They added that, on presentation, most dogs had combined clinical signs, initially managed by diet change, bowel lubricants and referred for surgery after unsuccessful treatment of the constipation. On the other hand Bellenger and Canfield 1993, Risselada and Kramer 2003, Sontas et al, 2008 mentioned that the etiology of perineal hernia was unspecific, but it is thought to occur as a result of a combination of contributing factors; continuous and sudden surges of increased intra-abdominal pressure because of coughing and constipation, congenital predisposition, and pelvic fractures are considered to be causative factors in the development of most cases of perineal hernia. While, Rocket and Mann, 1998, stated that, the high incidence rate of perineal hernia in entire male dogs and the beneficial effects of castration on the recurrence of the affections suggest that quantity of androgen sex hormones (testosterone and oestradiol 17- $\beta$ ) receptors in pelvic diaphragm muscles play an important role in the aetiopathogenesis of the condition.

The result of present study revealed that the perineal hernia was accurately diagnosed either by clinical symptoms, physical examination and radiographic assessment. These results came closely agree with that reported by

Farag et al, 1995; Peckan et al, 2010 and Martin et al, 2012. Who explained that radiographic examination aid in assessment the condition of the rectum and outline the hernial content.

Emptying the perineal space provides several technical advantages; better anatomic observation, ease of suture placement, and decreased risk of trauma to the external anal sphincter and caudal rectal nerves. This method came in contact with that reported by Gobbetti, 2012; he added that this technique improves the postoperative finding and subsequent decreased fecal incontinence and recurrence rate.

In brief, our study suggested that the external anal sphincter was secured to the levator ani muscle, coccygeus muscle and sacrotuberous ligament with interrupted 2 -0 vicryl sutures. This finding agrees with Brissot et al, 2004 , they added that, the use of this placement manner of suture material prevent the ventral defect, so there was no sutures placed from the external anal sphincter to the internal obturator muscle.

Muscle appositional techniques (standard hernioraphy) used in closure of the pelvic diaphragm with success rate 94.6% in our cases. This result agrees with that discussed by Niles and William, 1999, they explained that, the hernioraphy was successfully used to repair the early and unilateral diagnosed cases of hernia with success rate 90%. They added that hernioraphy result in excessive tension on the external anal sphincter and are not recommended in case of bilateral herniation or muscle atrophy or tears.

The implantation of polypropylene mesh used in this study for management of 8 bilateral cases of perineal hernia which gave good outcomes and no recurrence of such cases. This agrees with that reported by Anderson et al, 1998; Risselada and Kramer, 2003; Abu- Seida et al, 2011; Das et al, 2013. They recorded that the polypropylene mesh considered as an ideal material for hernia repair, and promote host tissue in growth resulting in healing repair with strength equal to normal tissue, provides resistance to infection, elicits no enhanced inflammatory response, inhibits adhesion or fistula formation. On the other hand Clarke, 1989 stated that out of 17 operated dogs with polypropylene mesh only one dog has a recurrence 12 months after surgery. He added that the advantages of this mode of repair were less tension, less deformity of the external anal sphincter and helps for closure of the ventral aspect of the hernia.

The tension band used for closure of the pelvic diaphragm in 3 cases (2 recurrent unilateral dogs and one of bilateral cases), no evidence of recurrence among these cases was recorded. This agrees with Gadalla and Etman, 2009; Gobbetti, 2012. They explained that, the advantages of this technique were strong pelvic diaphragm and quickness, inexpensive, technically easy to use; good long-term results and save time. They added also that this technique can be recommended in muscle weakness and atrophy.

In the present study, no evidence of suture misplacement through the rectal wall. The same judgment, reported by Stoll et al, 2002 and Das et al, 2013 they stated that, misplaced sutures into the rectal mucosa can lead to excessive straining and development of recto-cutaneous fistula and recurrence of perineal hernia.

Our study recorded some postoperative complications, which were similar to that mentioned by Brissot et al, 2004; Martin et al, 2012. They attributed the wound complications due to the proximity of the anus (the feces contaminate the wound), imperfect closing of dead space and use of drain is advisable for possible ascending infection.

The bilateral hernia was repaired at the same time. This finding agrees with Pekcan et al, 2010. However, some surgeons prefer waiting for 4-6 weeks between repairs to decrease the stress and distortion of the external anal sphincter muscle; Szabo et al, 2007 and Martin et al, 2012.

Our results revealed that the recurrence of perineal hernia was takes place in two cases after 4 months and mainly attributed to that the dogs suffered from constipation and these dogs were not castrated according to owner permission. This observation resembles to that reported by Stoll et al, 2002; Pekcan et al, 2010. They explained that postoperative continual straining for a long time before healing can lead to recurrence of herniation.

The castration was adapted in 32 cases, while the other 5 dogs were not castrated according to their owner judgment. Rockat and Mann 1998 reported that castration is traditionally considered part of the therapeutic approach to the management of perineal hernia in male dogs. Weaver and Omamegbe (1981) and Snell et al, (2015) suggest a causal link between intact males and perineal hernia recurrence. They also added that ageing testicles secrete excess estrogen, relaxing the pelvic diaphragm.

Follow up of the cases included in this study was conducted until 6 months in 26 cases, only 2 dogs had recurrence 4 months after first surgery with success rate of 94.6%. The bilateral conditions (9) and recurrent case (2) were successfully repaired by polypropylene mesh and tension band. This results agree with Vunck et al, 2006; Vunck et al, 2008; Pekcan et al, 2010; Gobbetti, 2012. They stated that, the material used for perineal hernia repair either synthetic or biological material. They added that, multi factors decrease the success rate when use the biological materials such as failure of internal obturator muscle transposition most commonly occurs in the ventromedial aspect of the transposed muscle, using a muscle flap was too weak to hold sutures as tunica vaginalis or procine small intestine submucosa. Morello et al, 2015 discussed another disadvantage like, extra time taking during surgery for harvesting the biological materials, high infection rate, while Bongartz et al, 2005 reported that, lameness of

grade 4 (obvious lameness) in the donor limb was recorded in cases repaired by autogenous fascia lata graft and semitendinosus muscle.

### Conclusion

On the basis of our results, the author concluded that, the surgical treatment of perineal hernia still represents a challenge; these aspects reflect the complexity of the affection. Early diagnosis and quick surgical intervention increase the success rate of healing. The herniorraphy is advisable technique for unilateral perineal hernia. The polypropylene mesh used for repair of bilateral case to decrease tension on the external anal sphincter muscle. Placement of tension band for perineal hernia repair obtained strong pelvic diaphragm, good long-term results, time sparing and can be used in case of weakness and atrophy of the muscle. Special attention must be paid to the lower part of the wound area in order not to injure the internal pudendal artery, vein and pudendal nerve which run there. Simultaneous castration and bilateral perineal hernia repair should be conducted at the same time.

### Acknowledgement

I would like to Acknowledge the efforts of the following sites [www.bu.edu.eg](http://www.bu.edu.eg) and [www.eul.edu.eg](http://www.eul.edu.eg).

### References

- Abu- Seida, A.M., Ayad, A., Shaban, N., Elmarzouky, M. and Hassan, M. (2011) A Comparative Study between Different Kinds of Meshes on Postoperative Adhesions in Dogs. *Kasr El Aini Journal of Surgery*, 12 (3): 101-106.
- Aliabadi, A. and Dehghani, S. (2007). Internal Obturator Transposition Herniorraphy of Three Perineal Hernia Cases in Dogs. *IJVR.2* (3). 84-90.
- Anderson, M.A., Constantinescu, G.M., Mann, F.A. (1998). Perineal hernia repair in the dog. In, Bojrab MJ (Ed): *Current Techniques in Small Animal Surgery*. 4th ed. pp. 555-564, Williams & Wilkins Baltimore.
- Bellenger C.R., Canfield, R.B. (1993). Perineal hernia. In, Slatter D (Ed): *Textbook of Small Animal Surgery*. 3rd ed., pp. 487-498, Saunders Philadelphia.
- Bongartz, A., Carofiglio, F., Balligand, M., Heimann, M. and Hamaide, A. (2005). Use of autogenous fascia lata graft for perineal herniorrhaphy in dogs. *Vet. Surg.* 34: 405-413.
- Brissot, H.N., Dupre, G.P., Bouvy, B.M. (2004). Use of laparotomy in a staged approach for resolution of bilateral or complicated perineal hernia in 41 dogs. *Vet Surg*, 33, 412-421.
- Chambers, J. N. and Rawlings, C. A. (1991). Applications of a semitendinosus muscle flap in two dogs. *J. Am. Vet. Med. Assoc.* 199: 84-86.
- Clarke, R. E. (1989). Perineal herniorrhaphy in the dog using polypropylene mesh. *Aust. Vet. Pract.* 19: 8-14.
- Das, J. Behera, S.S. and Senapati, M.R. (2013). unusual perineal hernia in a dog and its surgical management. *Indian Journal of Canine Practice*. Volume 5 Issue 1, 171-172.
- Evans, H. E. & Christensen, G. C. (1979). Muscles. In: *Anatomy of the Dog*, 2nd edition. W. 6. Saunders, Philadelphia. pp 33&337
- Farag, K.A., Berbish, E.A., El-Zomor, S.T., Gadalaah, S.M. (1995). Perineal hernia in dogs: clinical and radiographic study and surgical treatment. *J. Egypt. Vet. Med.Ass.* 54 (1) 2: 673-682.
- Gadalla, S.M. and Etman, A.H. (2009). Commercial plastic ties repair of abdominal hernias and defects. *J Egypt. Vet.Med.Assoc.* 69 (4).
- Gobbetti, D.M. (2012). Tension band herniorrhaphy in canine perineal hernia: evaluation of the role of colopexy on surgical and clinical outcome. PhD thesis. Università degli Studi di Milano.

- Hedlund, C. S. (2013). Surgery of the male reproductive tract. pp. 747–754. In: *Small Animal Surgery*, 4th ed. (Fossum, T. W., Hedlund, C. S., Johnson, A. L., Schulz, K. S., Seim, H. B., Willard, M. D., Bahr, A. and Carroll, G. L. eds, Mosby, St. Louis.
- Martin, K. D. J., Sarangom, S.B., Philip, S. B., and Kankonkar, A. P. (2012). Repair of recurrent perineal hernia using polypropylene mesh in a dog *J. Vet. Anim.Sci.* 43 : 59-61.
- Morello E, Martano M, Zabarino S, Piras LA, Nicoli S, Bussadori R, Buracco P. (2015). Modified semitendinosus muscle transposition to repair ventral perineal hernia in 14 dogs. *J Small Anim Pract.*56 (6):370-6.
- Niles, J.D. and William, J.D. (1999). Perineal hernia with bladder retroflexion in a female cocker spaniel. *J of Small Animal Practice*, 40, 92-94.
- Pekcan, Z., Besalti, O., Sirin, Y.S., Caliskan, M. (2010). Clinical and Surgical Evaluation of Perineal Hernia in Dogs: 41 Cases *Kafkas Univ Vet Fak Derg* 16 (4): 573-578, 2010.
- Pratummintra, K., Chuthatep, S., Banlunara, W and Kalpravidh, M. (2013). Perineal Hernia Repair Using an Autologous Tunica Vaginalis Communis in Nine Intact Male Dogs *J. Vet. Med. Sci.* 75(3): 337–341, 2013
- Risselada, M. and Kramer, M. (2003). Retroflexion of the urinary bladder associated with a perineal hernia in a female cat. *Journal of Small Animal Practice*, 44, 508-510.
- Rochat, M C., Mann F. A. (1998). Sciatic perineal hernia in two dogs. *Journal of Small Animal Practice* 39, 240-243.
- Snell, W.L., Orsher, R.J., Larenza-Menzies, M.P. and Popovitch, C.A. (2015). Comparison of caudal and pre-scrotal castration for management of perineal hernia in dogs between 2004 and 2014. *New Zealand Veterinary Journal*, 63 (5), 272-275.
- Sontas, B. H., Apaydin, S. O., Toydemir, T. S. F., Kasikci G. and Ekici, H. (2008). Perineal hernia because of retroflexion of the urinary bladder in a rottweiler bitch during pregnancy. *Journal of Small Animal Practice*. 49, 421–425.
- Spreull, J. S. A. and Frankland, A. L. (1980). Transplanting the superficial gluteal muscle in the treatment of perineal hernia and flexure of the rectum in the dog. *J. Small Anim. Pract.* 21: 265–278.
- Stoll, M.R., Cook, J.L., Pope, E.R., Carson, W.L., Kreeger, J.M. (2002). The use of porcine small intestinal submucosa as a biomaterial for perineal herniorrhaphy in the dog. *Vet Surg*, 31, 379-390.
- Szabo, S., Wilkens, B. and Radasch, R. M. (2007). Use of polypropylene mesh in addition to internal obturator transposition: a review of 59 cases (2000–2004). *J. Am. Anim. Hosp. Assoc.* 43: 136–142.
- Vnuck, D., Maticic, D., Kreszinger, M., Radisic, B., Kos, J., Lipar, M., Babic, T. (2006). A modified salvage technique in surgical repair of perineal hernia in dogs using polypropylene mesh. *Vet Med-Czech*, 51, 111-117.
- Vnuk, D., Lipar, M., Maticic, D., Smolec, O., Pecin, M. and Brkic, A. (2008). Comparison of standard perineal herniorrhaphy and transposition of the internal obturator muscle for perineal hernia repair in the dog. *Veterinarski Arh.* 78: 197–207.
- Weaver, A. D. and Omamegbe, J. O. (1981). Surgical treatment of perineal hernia in the dog. *J. Small Anim. Pract.* 22: 749–758.